



**DEDALUS - Acervo - FM**



10700054879

50









A MANUAL OF SURGICAL TREATMENT





# A Manual of Surgical Treatment

By

W WATSON CHEYNE

C.B., M.B., F.R.C.S., F.R.S.

Professor of Surgery in King's College, London; Surgeon to King's College Hospital, and  
The Children's Hospital, Paddington Green, etc.

and

F F BURGHARD

M.D. and M.S. (Lond.), F.R.C.S.

Teacher of Practical Surgery in King's College, London; Surgeon to King's College Hospital, and  
The Children's Hospital, Paddington Green, etc.

In Six Parts

PART V

*The Treatment of the Surgical Affections of the Head, Face, Jaws, Lips,  
Larynx and Trachea,*

and

*The Intrinsic Diseases of the Nose, Ear and Larynx*

By H. LAMBERT LACK

M.D. (Lond.), F.R.C.S.

Surgeon to the Hospital for Diseases of the Throat, Golden Square, and to the Throat and Ear  
Department, The Children's Hospital, Paddington Green

LONGMANS, GREEN AND CO.

39 PATERNOSTER ROW LONDON

AND BOMBAY

1901



To  
THE RIGHT HON.  
LORD LISTER, LL.D., P.R.S.,  
THE FOUNDER OF MODERN SURGERY,  
WITHOUT WHOSE WORK MUCH OF  
THIS BOOK COULD NOT HAVE  
BEEN WRITTEN.



## AUTHORS' PREFACE.

### GENERAL PREFACE.

THE subject of Surgery has now become so extensive that any work attempting to deal with it in an exhaustive manner must necessarily be so large and unwieldy as to be suitable only for purposes of reference, or for the use of those who devote themselves exclusively to its practice. In any text-book of convenient size the information given in certain branches of the subject must therefore be considerably condensed, and, as the first essential for the beginner is to have the fullest knowledge of the nature and characters of the diseases that he has to study, special stress is usually laid upon pathology, symptomatology, and diagnosis. For the practitioner, on the other hand, who is already acquainted with these points, the great essential is full and detailed information as to the best methods of treatment.

We have ourselves frequently experienced the want of detailed information, especially as regards the after-treatment of our cases, and have had to learn the best methods of procedure from experience. Nothing can of course replace experience, but it is often of the greatest advantage to have a detailed record of that of others upon which to base one's work. It is this want that the present work is intended to supply. We have tried to put ourselves in the place of those who have to treat a given case for the first time, and we have endeavoured to supply them with details as to treatment from the commencement to the termination of the illness. We have assumed that the reader is familiar with the nature and diagnosis of the disease, and we only refer to the pathology and symptoms in so far as it is necessary to render intelligible the principles on which the treatment is based, and the various stages of the disease to which each particular method is applicable.

We have purposely avoided attempting to give anything like a complete summary of the various methods of treatment that have from time to time been proposed: to do so would merely confuse the reader.

Only those plans are described which our experience has led us to believe are the best, but with regard to these we have endeavoured to state exactly and in detail what we ourselves should do under given circumstances. In some cases no doubt several methods of treatment are of equal value, and while we have only discussed at length that which we have ourselves been led to adopt, we have referred shortly to the others.

We have not mentioned all the exceptional conditions that may be met with, but we have endeavoured to include all the circumstances with which the surgeon is most commonly called upon to deal. The task has been one of some difficulty, the more so as we have had, to a certain extent, to break new ground. This must serve as our excuse for the many shortcomings in the work.

#### PREFACE TO PART V

FOR the sake of convenience in reference, the Intrinsic Diseases of the Nose, Ear and Larynx, have been grouped together to form one of the main divisions of the book. These subjects are dealt with by Dr. Lambert Lack, and to him we are deeply indebted. He wishes to express his thanks to Dr. C. A. Parker for help received in seeing the sheets through the press, to Messrs. Mayer and Meltzer for the loan of various instrument blocks, and to the Council of the Royal College of Surgeons of England for permission to reproduce various figures (Figs. 89-98, and 125) from his Jacksonian Prize Essay.

Dr. Arthur Whitfield has been good enough to write an account of electrolysis for superfluous hairs, which will be found on p. 104. To Prof. Rose we are indebted for Figs. 36-39, to the New Sydenham Society for leave to reproduce Fig. 11, to Prof. Arthur Robinson for the photographs from which Figs. 19, 21 23 are taken, and to Messrs. Down Bros. for the blocks of all the instruments in the first division of the volume. With the exception of these last, all the illustrations have been drawn by Mr. T. P. Collings from actual preparations or from rough sketches, and we wish to express our thanks to him.

LONDON, 1901.

# TABLE OF CONTENTS.

## PART V

### *DIVISION I.*

#### THE SURGICAL AFFECTIONS OF THE HEAD AND FACE.

##### *SECTION I.—AFFECTIONS OF THE HEAD.*

###### CHAPTER I.—AFFECTIONS OF THE SCALP.

	PAGE.
HAEMATOMATA : Subcutaneous—Sub-aponeurotic—Sub-pericranial,	1-5
WOUNDS : Treatment ; when superficial—when deep,	6-9
ERYSIPELAS AND ACUTE CELLULITIS,	9-10
BOILS AND CARBUNCLES : ULCERS : Simple and specific,	10
AIR TUMOURS : Emphysema—Pneumatocele,	11
TUMOURS : Atheromatous Cysts—Dermoid Cysts—Nævi—Cirsoid Aneurysm—Other Aneurysms,	11-16

###### CHAPTER II.—AFFECTIONS OF THE SKULL.

FRACTURES :	
OF THE VAULT : Of external table alone : Treatment—Of internal table alone : Treatment—Of both tables ; Fissured, depressed and punctured Fractures— <i>Treatment</i> : Of Fissures—Of simple and compound depressed Fracture—Of punctured Fracture,	16-26
OF THE BASE : Treatment,	26-30
ACUTE OSTEO-MYELITIS AND PERIOSTITIS : Treatment,	30-32
TUBERCULOSIS : Symptoms—Treatment,	32-33
SYPHILIS : <i>Treatment</i> : Sequestrotomy,	33-34
CRANIO-TABES : Treatment,	35-36
LEONTIASIS OSSIIUM : Treatment,	36-37
NEW GROWTHS : Exostoses—Sarcomata—Carcinomata,	37-38

## CHAPTER III.—INTRA-CRANIAL INJURIES.

	PAGE
CONCUSSION OF THE BRAIN : Symptoms and Treatment,	39-41
CONTUSION AND LACERATION OF THE BRAIN : Symptoms and Treatment,	41
COMPRESSION OF THE BRAIN BY INTRA-CRANIAL HÆMORRHAGE : <i>Rupture of Middle Meningeal Artery</i> : Symptoms, Prognosis and Treatment— <i>Sub-dural Hemorrhage</i> — <i>Hæmorrhage from Vessels of Pia Mater</i> : Treatment : <i>Hæmorrhage from other Vessels</i> : Symptoms and Treatment,	41-51

## CHAPTER IV.—INTRA-CRANIAL SUPPURATION.

INTRA-CRANIAL SUPPURATION FOLLOWING INJURY : <i>Extra-dural</i> : Treatment : <i>Sub-dural</i> : Localised Suppuration—Diffuse Lepto-meningitis— <i>Intra-cerebral</i> ,	52-56
INTRA-CRANIAL SUPPURATION RESULTING FROM DISEASE : <i>Symptoms</i> : Of Abscess of the Brain—Of Cerebellar Abscess—When Lepto-meningitis occurs—In Sinus Thrombosis— <i>Treatment</i> : Operation on the Mastoid Antrum—Exposure of the Lateral Sinus—Treatment of Sinus Thrombosis—Treatment of Extra-dural Abscess—Treatment of Abscess of the Brain,	57-69

CHAPTER V.—HERNIA CEREBRI : TUBERCULOUS MENINGITIS :  
SINUS THROMBOSIS.

HERNIA CEREBRI : Primary and Secondary : Treatment,	70-74
SINUS THROMBOSIS : Symptoms and Treatment,	74-75
TUBERCULOUS MENINGITIS : Treatment,	75-76

CHAPTER VI.—MENINGOCELE AND ENCEPHALOCELE : MICROCEPHALUS :  
HYDROCEPHALUS.

MENINGOCELE AND ENCEPHALOCELE : Treatment,	77-78
MICROCEPHALUS,	78
HYDROCEPHALUS : Pathology, Symptoms and Treatment,	79-82

## CHAPTER VII.—FOCAL EPILEPSY : TUMOURS OF THE BRAIN.

FOCAL EPILEPSY : Causes—Treatment,	83-85
TUMOURS OF THE BRAIN : Varieties—Symptoms—Treatment : <i>Medicinal</i> — <i>Operative</i> : Indications—Localisation of Fissures—Opening of Skull—Operation in two Stages—Opening the Dura Mater—Removal of Tumour—Osteo-plastic Procedures—After-treatment,	85-95

## SECTION II.—AFFECTIONS OF THE FACE.

CHAPTER VIII.—WOUNDS, INFLAMMATORY AFFECTIONS, ULCERS AND  
NEW GROWTHS OF THE FACE.

WOUNDS : Treatment—Complications,	96-97
SYPHILITIC AFFECTIONS : Primary, Secondary and Tertiary Lesions—Treatment,	97-98
TUBERCULOUS AFFECTIONS : <i>Ulcers</i> : Treatment— <i>Lupus</i> : Treatment : By Excision—By Scraping and Cauterisation—By Injection—Ointments and Plasters—Light-baths—Drugs,	98-102



	PAGE
INFLAMMATORY AFFECTIONS: Erysipelas: Treatment,	102
TUMOURS: <i>Sebaceous Cysts</i> : Treatment— <i>Dermoid Cysts</i> : Treatment— <i>Nævi</i> : Treatment—“Port-Wine Stains”— <i>Moles</i> : Treatment: Excision—Electrolysis: <i>Carcinomata</i> : Flat Epithelial—Tuberous Epithelial— <i>Rodent Ulcer</i> ,	103-108

## CHAPTER IX.—FRACTURES OF THE NASAL BONES.

FRACTURES OF THE NASAL BONES: Causes—Displacements—Complications— <i>Treatment</i> : Of the Fracture—Of Complications—Of Compound Fracture—Of long-standing deformity,	109-113
--	---------

## CHAPTER X.—AFFECTIONS OF THE LIPS.

WOUNDS: Treatment,	114
INFLAMMATORY AFFECTIONS: Cracks and Fissures—Hypertrophy,	114-115
TUBERCULOUS AFFECTIONS: Lupus—Tuberculous Ulcers: Treatment,	115-116
SYPHILITIC AFFECTIONS: Primary Sores—Mucous Patches—Treatment,	116-117
TUMOURS: <i>Nævus</i> : Treatment by Injections and Electrolysis— <i>Lymphangioma</i> : Treatment— <i>Cysts</i> : Treatment— <i>Epithelioma</i> : Treatment,	117-124

## CHAPTER XI.—TRIGEMINAL NEURALGIA.

TRIGEMINAL NEURALGIA: Treatment: In Secondary Cases—When no exciting Cause can be discovered: Drugs—Neurectomy: <i>Of First Division</i> : Supra-orbital Neurectomy— <i>Of Second Division</i> : Infra-orbital Neurectomy—Neurectomy of Superior Maxillary Nerve and ablation of Meckel's ganglion— <i>Of Third Division</i> : Neurectomy of Inferior Dental Nerve—Neurectomy of Gustatory Nerve—Neurectomy of Auriculo-temporal Nerve—Division of Inferior Maxillary Trunk at the Foramen Ovale— <i>Removal of Gasserian Ganglion</i> —Rose's method—Hartley's method—Horsley's method,	125-136
--	---------

## CHAPTER XII.—THE PLASTIC SURGERY OF THE FACE.

PLASTIC OPERATIONS ON THE FACE IN GENERAL: <i>Thiersch's Skin-grafting</i> — <i>Flap Methods</i> : Sutures and Dressing,	137-140
PLASTIC OPERATIONS ON THE LIPS: Restoration of the Lower Lip—Ectropion of the Lip—Restoration of the Upper Lip—Operation for Microstoma,	140-145
PLASTIC OPERATIONS ON THE CHEEK: <i>A fresh defect of Skin and subcutaneous Tissues</i> — <i>Destruction of the whole Thickness</i> : A small defect without closure of the Jaws—A small defect with plenty of Skin but closure of the Jaws—A large defect with no sound Skin and complete closure of the Jaws—Extensive and Irremedial closure of the Jaws,	145-151
DEFORMITIES OF THE EYELIDS: <i>Ectropion</i> : Treatment,	151-153
DEFORMITIES OF THE NOSE: Sinking-in of Bridge—Loss of the Cartilaginous Portion—Small partial Losses—Total destruction of the Nose— <i>Treatment</i> : Of Loss of the Bridge—When the Tip alone has been destroyed—Partial Losses of Ala—Loss of the whole Nose,	153-160

## CHAPTER XIII.—HARE-LIP AND CLEFT PALATE.

HARE-LIP: <i>Treatment</i> : Of an incomplete Cleft—Of a complete Cleft—Of unilateral Hare-lip with cleft of the Alveolus—Of double Hare-lip,	161-169
COLOBOMA FACIALIS,	169

	PAGE
CLEFT PALATE: Varieties—Treatment: Preliminary Measures—Operation: Paring edges of Cleft—Formation of muco-periosteal Flaps—Suturing the Flaps—Relief of Lateral Tension—Davies Colley's Operation—Treatment: Of Complications—Voice Training—Mechanical Treatment,	169-181
ACQUIRED PERFORATIONS: Treatment,	181

#### CHAPTER XIV —THE AFFECTIONS OF THE AURICULAR AND PAROTID REGIONS.

DEFORMITIES OF THE AURICLE,	182
MALIGNANT DISEASE OF THE AURICLE,	182-183
WOUNDS OF THE PAROTID GLAND: <i>Treatment</i> : Of Hæmorrhage—Of Division of the Facial Nerve,	184-185
WOUNDS OF THE SALIVARY DUCTS: Of Stenson's Duct—Treatment,	185-189
SALIVARY FISTULA: Treatment,	186-187
INFLAMMATION OF THE PAROTID GLAND: Treatment— <i>Mumps</i> : Treatment,	188-189
SALIVARY CALCULUS: Treatment,	189
NEW GROWTHS OF THE PAROTID GLAND: <i>The "Parotid Tumour"</i> : Treatment— <i>Malignant Disease</i> : Excision of the Parotid Gland,	189-191

#### SECTION III.—AFFECTIONS OF THE JAWS.

##### CHAPTER XV —FRACTURES OF THE JAWS.

FRACTURE OF THE UPPER JAW: Varieties—Complications—Treatment— <i>Fracture of the Malar Bone</i> : Treatment— <i>Fracture of the Zygomatic Arch</i> : Treatment,	192-194
FRACTURE OF THE LOWER JAW: Causes—Varieties—Displacement—Complications— <i>Treatment of the Fracture</i> : When anterior to the last Molar Tooth—When situated behind last Molar—Fracture of the Condyle—Fracture of the Coronoid Process— <i>Treatment of Complications</i> ,	195-200

##### CHAPTER XVI.—AFFECTIONS OF THE TEMPORO-MAXILLARY ARTICULATION

DISLOCATION OF THE LOWER JAW: Causes—Treatment— <i>Unreduced Dislocation</i> : Treatment,	201-204
INFLAMMATORY AFFECTIONS: Treatment,	204
ANCHYLOSIS OF THE JAW: Treatment,	204-206

##### CHAPTER XVII.—INFLAMMATORY AFFECTIONS OF THE JAWS.

GINGIVITIS AND PYORRHEA ALVEOLARIS: Treatment,	207-208
OSTEITIS AND PERIOSTITIS: <i>Periostitis and Alveolar Abscess</i> : Treatment— <i>Acute Osteo-myelitis</i> : Treatment,	208-210
TUBERCULOUS DISEASE—PHOSPHORUS NECROSIS—ACTINOMYCOSIS,	211

##### CHAPTER XVIII.—TUMOURS OF THE JAWS.

DENTAL CYSTS: <i>Dentigerous Cysts</i> — <i>Simple Cysts</i> — <i>Multilocular Cysts</i> —Treatment,	212-213
NEW GROWTHS:	
EPULIS: Treatment,	213-214

	PAGE
MALIGNANT TUMOURS OF THE UPPER JAW : <i>Carcinomata</i> — <i>Sarcomata</i> :	
Symptoms—Excision of the Upper Jaw—Modified Operations,	214-221
INTRA-NASAL MALIGNANT TUMOURS : Rouge's Operation — The External	
Operation,	221-223
MALIGNANT TUMOURS OF THE LOWER JAW : <i>Treatment</i> : Removal of one half	
of the Jaw—Removal of the Horizontal Ramus alone—Removal of the	
Symphysis—Removal of the entire Jaw,	223-227
CHAPTER XIX.—TUMOURS OF THE NASO-PHARYNX.	
TUMOURS OF THE NASO-PHARYNX : Treatment,	228-231
SECTION IV—THE LARYNX AND TRACHEA.	
CHAPTER XX.—CONGENITAL AFFECTIONS : INJURIES.	
PERSISTENT THYRO-GLOSSAL TRACT : <i>Treatment</i> : Of a Fistula—Of a Cyst,	232-233
ENLARGEMENT OF THE THYRO-HYOID BURSA : Treatment,	233
INJURIES OF THE LARYNX :	
FRACTURES OF THE HYOID BONE : Treatment,	233-234
FRACTURES OF THE CARTILAGES : Treatment,	234-235
CHAPTER XXI.—CUT THROAT.	
CUT THROAT : <i>Treatment</i> —Of Wounds not implicating the Air-passages—Of Wounds	
involving the Air-passages—Of Complications,	- 236-241
CHAPTER XXII.—FOREIGN BODIES IN THE AIR-PASSAGES.	
FOREIGN BODIES IN THE PHARYNX : Treatment,	242-243
FOREIGN BODIES IN THE LARYNX AND TRACHEA : Symptoms— <i>Treatment</i> : Of	
Foreign Bodies in the Larynx—Of Foreign Bodies in the Trachea—Of Foreign	
Bodies in the Bronchus,	243-247
CHAPTER XXIII.—THE OPERATIONS UPON THE LARYNX AND TRACHEA.	
TRACHEOTOMY : <i>The High Operation</i> : Tubes— <i>The Low Operation</i> : Difficulties—	
Complications—Tracheotomy for Diphtheria,	248-256
LARYNGOTOMY,	257
CHAPTER XXIV.—CANCER OF THE LARYNX.	
CANCER OF THE LARYNX : Symptoms—Treatment—Thyrotomy—Laryngectomy—	
unilateral and complete,	258-264

*DIVISION II.*THE INTRINSIC DISEASES OF THE NOSE, EAR AND  
LARYNX.

BY DR. LAMBERT LACK.

*SECTION I.—AFFECTIONS OF THE NOSE.*

## CHAPTER XXV.—THE ANATOMY OF THE NOSE.

	PAGE
THE VESTIBULE.	265
THE NASAL FOSSÆ,	265-267
THE SEPTUM,	267-268
THE MUCOUS MEMBRANE: The Functions of the Nose,	269
THE ACCESSORY SINUSES: The Maxillary Antrum—The Frontal Sinus—The Infundibulum—The Ethmoidal Cells—The Sphenoidal Sinuses,	269-275

CHAPTER XXVI.—METHODS OF EXAMINATION OF THE NOSE AND  
ACCESSORY CAVITIES.

ILLUMINATION: Electric Light—Gas—The Oxy-hydrogen Lime-light—The Head Mirror—POSITION OF THE PATIENT,	276-278
ANTERIOR RHINOSCOPY: Specula—The Use of the Probe,	278-279
POSTERIOR RHINOSCOPY,	279-282
TRANS-ILLUMINATION,	282
NASAL THERAPEUTICS: Methods of Cleansing the Nose—The Use of Oils,	282-284
NASAL ANÆSTHESIA: Cocaine and Eucaine—The Suprarenal Extract,	284-285
NASAL ANTISEPSIS,	285-286
ARREST OF HÆMORRHAGE,	286

CHAPTER XXVII.—DEFORMITIES OF THE NOSE—FOREIGN BODIES  
IN THE NOSE.

DEFORMITIES OF THE SEPTUM: Pathological conditions—Treatment: <i>Methods of operating</i> : In Cases of Simple Deflection without Thickening—Removal of Horizontal Spurs or Ridges—Removal of Vertical Spurs and Ridges—Complicated Cases,	287-290
ADHESIONS BETWEEN THE SEPTUM AND THE INFERIOR TURBINATE: Causes—Treatment of Recent and Established Cases,	291
ABSCESS OF THE NASAL SEPTUM: Causes—Symptoms—Treatment,	291-292
CONGENITAL MALFORMATIONS: Treatment,	292
COLLAPSE OF THE ALÆ NASI: Treatment,	292-293
FOREIGN BODIES IN THE NOSE: Treatment—RHINOLITHS,	293-294

CHAPTER XXVIII.—INFLAMMATORY AFFECTIONS OF THE NASAL FOSSÆ  
AND THEIR SEQUELÆ.

	PAGE
ACUTE INFLAMMATIONS :	
<i>Simple Acute Rhinitis</i> : Treatment—After-treatment,	295-297
<i>Rhinitis in the Specific Fevers and Gonorrhæal Rhinitis</i> : Treatment,	297
<i>Traumatic Rhinitis</i> : Symptoms—Treatment,	297-298
<i>Fibrinous or Croupous Rhinitis</i> : Symptoms—Treatment,	298-299
CHRONIC INFLAMMATIONS :	
<i>Chronic Catarrhal Rhinitis</i> : Causes—Pathology—Symptoms—Results—General and Local Treatment,	300-302
<i>Hypertrophy of the Inferior Turbinate</i> : Pathological Changes—Symptoms— Treatment : In cases associated with undue narrowness of the Nasal Fossa— Anterior Turbinectomy—Removal of Posterior End of Inferior Turbinate— Removal of the whole Inferior Turbinate,	302-308
<i>Rhinitis Sicca</i> : Varieties and Causes—Pathological Results—Symptoms— <i>Treat-</i> <i>ment</i> : General—Local—Of Epistaxis—Of Perforating Ulcer of the Septum,	308-311
<i>Atrophic Rhinitis</i> : Causes—Pathology—Treatment, Constitutional and Local,	311-315
<i>Nasal Polypus</i> : Structure—Site of Origin—Tendency to Recur,	315-316
<i>Osteitis and Periostitis of the Ethmoid</i> : Clinical Features—Treatment of the Three Stages,	316-322

CHAPTER XXIX.—CHRONIC INFECTIVE DISEASES OF THE NOSE.

SYPHILIS OF THE NOSE : <i>Primary—Secondary—Tertiary</i> : Results—Treatment— <i>Inherited</i> : Treatment,	323-325
TUBERCULOSIS : Symptoms—Treatment,	325-326
RHINO-SCLEROMA : Treatment,	326
TUMOURS : Papilloma — Fibro-angioma of the Septum — Fibroma — Malignant Neoplasms,	327-328

CHAPTER XXX.—NASAL NEUROSES.

HAY FEVER : Symptoms—Pathological Changes—Treatment,	329-331
PAROXYSMAL SNEEZING OR RHINORRHŒA : Symptoms—Causes—Treatment,	331
IDIOPATHIC RHINORRHŒA : Treatment,	331-332
NASAL ASTHMA : Treatment,	332-333
ANOSMIA : Treatment,	333-334
PAROSMIA,	334

CHAPTER XXXI.—INFLAMMATORY AFFECTIONS OF THE ACCESSORY  
CAVITIES OF THE NOSE.

ACUTE INFLAMMATION AND SUPPURATION : Etiology—Symptoms— <i>Treatment</i> : Constitutional—Local,	335-338
CHRONIC SUPPURATION : Etiology—Symptoms— <i>Treatment</i> : In Maxillary Antrum— In Ethmoidal Cells—In the Sphenoidal Sinus—In the Frontal Sinus,	338-357
MUCOCELE OR CYSTIC DISEASE : Causation—Treatment,	358
PT. V.	b

## CHAPTER XXXII.—DISEASES OF THE NASO-PHARYNX.

	PAGE
ACUTE NASO-PHARYNGITIS OR ACUTE POST-NASAL CATARRH,	359
CHRONIC POST-NASAL CATARRH: Treatment,	359-360
POST-NASAL ADENOID GROWTHS: Pathology—Symptoms— <i>Treatment</i> : Palliative— Operative,	360-366

## SECTION II.—AFFECTIONS OF THE EAR.

## CHAPTER XXXIII.—GENERAL METHODS OF EXAMINATION AND TREATMENT.

EXAMINATION: Of the Tympanic Membrane—Of the Eustachian Tubes: Valsalva's Method—Politzer's Method—The Eustachian Catheter—Eustachian Bougies,	367-372
ESTIMATION OF THE HEARING POWER: Tuning Forks,	372-373

## CHAPTER XXXIV.—AFFECTIONS OF THE EXTERNAL AUDITORY MEATUS.

IMPERFORATE MEATUS: Treatment— <i>Traumatic Stricture of Meatus</i> ,	374-375
FOREIGN BODIES: Treatment,	375
OBSTRUCTION OF THE MEATUS: Treatment,	375-376
CIRCUMSCRIBED INFLAMMATION OR FURUNCLE: Symptoms—Treatment,	377-378
ACUTE DIFFUSE INFLAMMATION: Symptoms—Treatment,	378
ECZEMA: Treatment,	378
OTOMYCOSIS: Treatment,	379
TUMOURS: <i>Exostosis</i> : Treatment,	379-381

## CHAPTER XXXV.—AFFECTIONS OF THE MIDDLE EAR.

INJURIES OF THE TYMPANUM: Treatment,	382
ACUTE OTITIS MEDIA: Causation—Pathology—Symptoms—Treatment— <i>Recurrent</i> <i>Acute Catarrh</i> ,	383-386
CHRONIC NON-SUPPURATIVE CATARRH: Pathology—Symptoms—Prognosis— Treatment,	386-390
SCLEROSIS: Pathology—Symptoms—Treatment,	390-391
CHRONIC SUPPURATION OF THE MIDDLE EAR: Pathology—Symptoms— <i>Treatment</i> : Of the Otitis—Of Complications— <i>Sequelæ</i> : Permanent perforation of Membrane— Intra-tympanic Adhesions,	391-401

## CHAPTER XXXVI.—SUPPURATION IN THE ANTRUM AND MASTOID CELLS.

SUPERFICIAL MASTOID ABSCESSSES: Treatment,	402
ACUTE SUPPURATION IN THE MASTOID ANTRUM: Symptoms—Treatment,	402-409
CHRONIC SUPPURATION IN THE MASTOID ANTRUM: Treatment,	409-410
CEREBRAL COMPLICATIONS—PYEMIA,	410

CHAPTER XXXVII.—AFFECTIONS OF THE INTERNAL EAR AND PER-  
CEPTIVE APPARATUS OF HEARING.

	PAGE
AFFECTIONS OF THE INTERNAL EAR: Hyperæmia and Pressure on the Labyrinthine Fluid—Drug Deafness—Labyrinthine Hæmorrhage or Menière's Disease—Acute Inflammation—Syphilis—Mumps and Specific Fevers—Boilermakers' Deafness—Senile Deafness,	411-415
AFFECTIONS OF THE AUDITORY NERVE AND CENTRES: Treatment,	415-416
NEURASTHENIA: Treatment,	416

SECTION III.—AFFECTIONS OF THE LARYNX.

CHAPTER XXXVIII.—GENERAL METHODS OF EXAMINATION AND  
TREATMENT.

METHODS OF EXAMINATION: <i>Laryngoscopy</i> : In Adults—In Children,	417-420
GENERAL METHODS OF TREATMENT: Anæsthetisation—Cleansing—Steam Inhalations—Insufflations—Intubation,	420-424

CHAPTER XXXIX.—INFLAMMATORY AFFECTIONS OF THE LARYNX.

ACUTE CATARRHAL LARYNGITIS IN ADULTS: Causes—Pathology—Symptoms—Treatment, -	425-426
ACUTE LARYNGITIS IN CHILDREN: Symptoms—Treatment,	426-427
CHRONIC LARYNGITIS: Pathology—Treatment,	427-429
LARYNGITIS SICCA: Causes—Symptoms—Treatment,	429-430
ACUTE ŒDEMATOUS LARYNGITIS: Causes—Symptoms—Treatment,	430-432
ŒDEMA OF THE LARYNX: Treatment,	432-433
PERICHONDRIITIS, NECROSIS OF CARTILAGE AND LARYNGEAL ABSCESS: <i>Acute Perichondritis</i> : Symptoms—Treatment— <i>Chronic Perichondritis</i> : Symptoms—Treatment, -	433-434

CHAPTER XL.—TUMOURS OF THE LARYNX.

BENIGN TUMOURS: Varieties—Symptoms—Prognosis—Treatment: <i>Of Papillomata—Of Fibromata and Myxomata—Of Cysts—Of Angiomata—Of Chondromata—Of Lipomata,</i>	435-439
MALIGNANT TUMOURS: <i>Intrinsic Laryngeal Cancer</i> : Treatment— <i>Extrinsic Laryngeal Cancer</i> : Treatment,	439-441

CHAPTER XLI.—SYPHILIS OF THE LARYNX.

SYPHILIS OF THE LARYNX: <i>Secondary Syphilis</i> : Treatment— <i>Tertiary Syphilis</i> : Treatment, -	442-444
--	---------

CHAPTER XLII.—TUBERCULOSIS OF THE LARYNX.

LARYNGEAL PHTHISIS: Varieties—Symptoms— <i>Treatment</i> : Of the Pre-tuberculous Stage—Of Isolated Tuberculous Tumours—Of Intrinsic Laryngeal Tuberculosis—Of Extensive Disease with Ulceration, Œdema, Perichondritis, etc.,	445-449
LUPUS OF THE LARYNX: Symptoms—Treatment,	449-450

CHAPTER XLIII.—NEUROSES OF THE LARYNX : MALFORMATIONS OF THE  
LARYNX.

	PAGE
ALTERATIONS OF SENSATION : Anæsthesia—Hyperæsthesia—Neuralgia—Treatment,	451
FUNCTIONAL PARALYSIS : Treatment,	452-453
FUNCTIONAL LARYNGEAL SPASM : Treatment,	453-454
ORGANIC LARYNGEAL PARALYSIS : Treatment,	454-455
SPASM OF THE TENSOR MUSCLES OF THE VOCAL CORDS,	455
SPASM OF THE GLOTTIS IN INFANTS : LARYNGISMUS STRIDULUS : Symptoms— Treatment—REFLEX SPASM Treatment,	455-457
LARYNGEAL VERTIGO : Treatment,	457
MALFORMATIONS OF THE LARYNX	
CONGENITAL LARYNGEAL OBSTRUCTION : Symptoms—Treatment,	457-458
CONGENITAL WEB OF THE LARYNX,	458
INDEX,	459



# LIST OF ILLUSTRATIONS.

## PART V

FIG.		PAGE
1.	Ice-Caps,	3
2.	Method of Applying Pressure to a Hæmatoma of the Scalp,	4
3.	Methods of removal of Sebaceous Cysts,	12
4.	Method of Removing a Depressed Fragment of the Skull in a Depressed Fracture,	21
5.	Forceps for Elevating Depressed Portions of the Skull,	21
6.	Hoffman's Forceps,	22
7.	Trephines,	23
8.	Removal of the Diploë in Acute Osteo-myelitis of the Skull,	31
9.	Exostoses of the Skull,	37
10.	Gigli's Saw,	38
11.	Middle Meningeal Hæmorrhage ( <i>Helperich</i> ),	43
12.	Method of Securing a Ruptured Middle Meningeal Artery in the Dura Mater,	46
13.	The "Parting Tool" for Operations upon the Skull,	47
14.	Incision of the Dura Mater for Sub-Dural Hæmorrhage,	49
15.	The Operation upon the Mastoid Antrum,	61
16.	Exposure of the Upper Surface of the Petrous Bone,	65
17.	Horsley's Dura-Mater Separator,	66
18.	Exploration of the Cerebrum and Cerebellum through the same opening in the Skull,	67
19.	Drainage of the Fourth Ventricle,	75
20.	Incisions for Craniectomy,	78
21.	The Relations of the various Cranial Sutures, Cerebral Convolution and Cortical Centres,	86
22.	Reid's Method of Cerebral Localisation,	88
23.	The Relations of the Middle Meningeal Artery to the Sutures of the Skull,	89
24.	Horsley's "Rolandometer,"	90
25.	Horsley's Brain Knife,	93
26.	Cranial Chisel,	94
27.	A Method of forming an Osteo-Plastic Flap in Operations upon the Brain,	95
28.	Forceps for Straightening the Nasal Septum,	111
29.	Nasal Plugs,	111
30.	Mason's Method of supporting the Bridge of the Nose after Fracture,	112

FIG.		PAGE
31.	Temporary Strangulation of a Nævus,	117
32.	Incisions for the Removal of a small Epithelioma of the Lower Lip,-	120
33.	Incisions for the Removal of an Epithelioma of the Lower Lip and the Sub-Maxillary Glands,	121
34.	Incision for the Removal of the Sub-Mental Lymphatic Glands,	122
35.	Incisions for the Removal of an Epithelioma occupying the Bulk of the Lower Lip,	123
36.	Incisions for Exposure of the Third Division of the Fifth Nerve and for Removal of the Gasserian Ganglion ( <i>Rose</i> ),	130
37.	Section of the Zygoma and the Coronoid Process in Removal of the Gasserian Ganglion ( <i>Rose</i> ),	132
38.	Exposure of the Foramen Ovale ( <i>Rose</i> ),	133
39.	Position of the Trephine Hole in Removal of the Gasserian Ganglion ( <i>Rose</i> ),	134
40.	Restoration of the Lower Lip by means of Rectilinear Incisions,	139
41.	"          "          by means of Curved Incisions,	140
42.	"          "          by Masseteric Incisions,	141
43.	Operation for Ectropion of the Lower Lip,	142
44.	Operation for Restoration of Part of the Upper Lip,	143
45.	Operation for Restoration of the Entire Upper Lip,	143
46.	Dieffenbach's Operation for Microstoma,	144
47.	Plastic Operations upon the Mouth,	145
48.	Plastic Operation on Mouth when there is no Anchylosis of the Jaws,	147
49.	Gussenbauer's Plastic Operation on the Mouth,	148
50.	Operations for Ectropion of the Lower Eyelid,	151
51.	Flap Operation for Ectropion of the Lower Eyelid,	152
52.	Restoration of the Bridge of the Nose,	154
53.	Syme's Operation of Restoration of the Soft Parts of the Nose,	157
54.	Partial Rhinoplastic Operations,	157
55.	The Indian Method of Rhinoplasty,	158
56.	Method of Forming a New Columella,	159
57.	The Italian or Tagliacotian Method of Rhinoplasty,	159
58.	Operation for Simple Hare-Lip without widening of the Nostril,	163
59.	"          "          with widening of the Nostril,-	164
60.	Mirault's Operation for Hare-Lip,	164
61.	Modified Mirault's Operation,	165
62.	Nélaton's Operation,	166
63.	V-shaped Incision in the Septum for projecting Pre-Maxilla,	167
64.	Operation for Double Hare-Lip,-	168
65.	Various Hare-Lip Operations,	168
66.	Smith's Gag,	171
67.	Rose's Gag,	171
68.	Lane's Gag,	172
69.	Paring the Edges of the Cleft in the Palate,	173
69A.	Needles and Needle holders for Cleft Palate Operations,	175
70.	Methods of Introducing the Sutures in a Cleft Palate,-	176
71.	The Relief of Lateral Tension in the Soft Palate,	177
72.	Davies Colley's Operation for Cleft Palate,	178
73.	Plastic Operations upon the Auricle,	183
74.	Hammond's Wire Splint for Fractures of the Jaw,	197
75.	Gags for Anchylosis of the Jaws,	205
76.	Incision for Removal of the Upper Jaw,	217
77.	Lines of Bone-Section in Removal of the Upper Jaw,-	218
78.	Incision for Removal of the Lower Jaw,	225

LIST OF ILLUSTRATIONS.

xxi

FIG.		PAGE
79.	Laryngotomy Tube,	234
80.	Hahn's Cannula,-	238
81.	Trendelenburg's Tampon Cannula,	239
82.	Golding Bird's Tracheal Dilator,	246
83.	Parker's Tracheotomy Tube and Pilot,-	250
84.	Durham's Lobster-Tail Tracheotomy Tube,	250
85.	Fuller's Bivalve Cannula and Inner Tube,	250
86.	Morrant Baker's India-rubber Tube,	252
87.	Parker's Automatic Tracheal Dilator,	254
88.	Parker's Tracheal Aspirator,	255
89.	Vertical Antero-Posterior Section of the Head passing through the Right Nasal Fossa immediately to the Outer Side of the Septum,	266
90.	Vertical Antero-Posterior Section through the Nasal Fossæ somewhat to the Left of the Middle Line,	267
91.	Vertical Transverse Section of the Nose in the Plane of the Eyeballs and Second Molars, viewed from behind,	268
92.	Vertical Transverse Section through the Nasal Fossæ in the Plane of the Optic Nerves and the Third Molars, viewed from the Front,	268
93.	Horizontal Section of the Nose, about half an inch above its Floor, viewed from above,	270
94.	A Semi-diagrammatic Figure showing Asymmetry of the Antral Cavities,	271
95.	The Relations of the Ethmoidal Cells and the Maxillary Antrum to the Surface,	271
96.	Horizontal Section through the Upper Part of the Nose, viewed from below,	273
97.	" " " " " above,	273
98.	Vertical Section of the Nose through the Body of the Sphenoid, near the Middle Line posteriorly, and passing obliquely forwards through the Outer Wall of the Nose, the Orbit and the Alveolar Border anteriorly,	274
99.	Greville MacDonald's Lamp for Laryngoscopy,	277
100.	Mackenzie's Lamp for Laryngoscopy,	277
101.	Browne's Nasal Speculum,	279
102.	Thudichum's Nasal Speculum,	279
103.	Lack's Tongue Depressor,	280
104.	The Post-Nasal Space as seen by Posterior Rhinoscopy,	280
105.	Trans illumination of the Maxillary Antrum,	281
106.	Glass Tube for Irrigating the Nose,	283
107.	Bosworth's Saw,-	288
108.	The Operation for Deflected Septum,	288
• 109.	Delstanche's Nasal Clamp for Deflected Septum,	289
110.	Lack's Snare,	303
111.	Panza's Scissors for Anterior Turbinectomy,	305
112.	Removal of the Anterior End of the Inferior Turbinate,	305
113.	Result of Removal of the Anterior End of the Inferior Turbinate,	305
114.	Removal of the Posterior End of the Inferior Turbinate,	306
115.	Carmalt-Jone's Spokeshave,	307
116.	Grünwald's Nasal Cutting Forceps,	317
117.	Removal of the Anterior End of the Middle Turbinate,	318
118.	Morell Mackenzie's Snare,	319
119.	Blake's Snare for Nasal Polypi,	319
120.	Meyer's Original Adenoid Curette,	320
121.	Antrum Drill,	341
122.	Lichtwitz's Trochar and Cannula,	342
123.	Krause's Antrum Trochar,	343

FIG.		PAGE
124.	The Radical Operation upon the Maxillary Antrum,	354
125.	A Dissection to Illustrate the Relations of the Frontal Sinus,	354
126.	India-rubber Plug for Frontal Sinus,	356
127.	Modified Gottstein's Post-Nasal Curette,	363
128.	Juracz's Post-Nasal Forceps,	363
129.	Dalby's Aural Speculum, -	367
130.	Gruber's Aural Speculum,	367
131.	The Membrana Tympani,	368
132.	Vertical Transverse Section of the Ear,	369
133.	Siegle's Speculum,	370
134.	Lister's Ear Hook,	375
135.	Cotton-wool Mop,	394
136.	Delstanche's Malleus Hook,	396
137.	Lake's Attic Curette,	396
138.	Set of Minor Ear Instruments, -	396
139.	The Complete Post-Aural Operation on the Mastoid, -	405
140.	Method of Examining the Larynx,	418
141.	O'Dwyer's Instruments for Intubation of the Larynx, -	422
142.	Mackenzie's Cutting Laryngeal Forceps,	437
143.	Dilator for Laryngeal Stenosis,	444
144.	Krause's Nasal Snare and Laryngeal Cutting Forceps,	447
145.	Hering's Laryngeal Curettes and Knives,	447

DIVISION I.  
THE SURGICAL AFFECTIONS OF THE  
HEAD AND FACE.

*SECTION I.—AFFECTIONS OF THE HEAD.*

CHAPTER I.

AFFECTIONS OF THE SCALP.

THE results of injuries of the head vary according to the cause producing the injury, its situation and its severity. They include extravasations of blood or hæmatomata, incised or contused wounds of the scalp, fractures of the skull, concussion and laceration of the brain, intra-cranial hæmorrhage or suppuration, and various sequelæ such as focal epilepsy supervening at a later date. In the present chapter we shall deal only with the effects of injuries in so far as they concern the soft tissues overlying the bone.

HÆMATOMATA OF THE SCALP.

Injuries to the scalp may either produce an open wound, or the scalp may remain unbroken. In the former case various kinds of scalp wounds result; in the latter, hæmorrhages under different conditions, classed together under the name of hæmatoma. These hæmatomata may occur beneath the skin, beneath the tendon of the occipito-frontalis muscle or beneath the pericranium, the last form being often distinguished by the special name of cephal-hæmatoma.

(a) **THE SUBCUTANEOUS HÆMATOMA.**—Hæmorrhage beneath the skin presents no special points of importance. It does not differ in

any material point from bruises elsewhere, nor is its treatment different from that of an ordinary bruise.

**Treatment.**—In the first instance, *the application of an evaporating lotion*, such as the *lotio plumbi*, will usually suffice. When, however, the effusion of blood is more extensive, *an icebag* may be desirable in order to check further hæmorrhage. As a rule it is unnecessary to shave the head or even to cut the hair, unless there happens to be some abrasion of the surface in addition to the contusion; this will then bring the case into the category of a scalp wound. These subcutaneous hæmatomata practically always disappear in the course of a few days without any trouble.

(b) **THE SUB-APONEUROTIC HÆMATOMA.**—This is an important form. In some cases the blood effused is large in amount, for owing to its situation, it may spread freely beneath the muscle over a large area, and such an amount may be poured out as to be difficult of subsequent absorption. This form of hæmatoma is also important because in it,—though not to the same extent as in the next variety,—a mistaken diagnosis is not uncommon, in that a depressed fracture may be suspected. After the blood is effused, the margin of the hæmatoma usually becomes hard from the presence of the coagulum in the tissues, while the centre may remain soft and fluctuating. When the collection of fluid in the centre is small, the finger pressed over it seems to pass into a depression in the bone. As a matter of fact, however, no depression exists, as the finger first passes over the raised edge of the hæmatoma and thus, when the bone is felt through the central collection of fluid, the idea of a depressed fracture is imparted.

Under such circumstances a hæmatoma proper, or a blood-cyst may form and prove very slow in absorption; in fact, in some cases the skin over it gradually gets thinned and gives way, and its contents may discharge without any suppuration having occurred. In other cases again, especially when there has been an abrasion of the skin, suppuration may take place.

**Treatment.**—The treatment of these cases consists 1. in limiting the effusion of blood; 2. in promoting rapid absorption of the blood already effused; and 3. in taking measures to prevent infection of the collection of blood and consequent suppuration in the hæmatoma.

1. **To limit the effusion.**—If the case be seen directly after the accident, it is well to *apply an icebag or an ice-cap*<sup>1</sup> *at once* (see Fig. 1); unless there be a wound it is not necessary to shave the head. The patient must be confined to bed, or at any rate to the horizontal position. The cold should be continued until there is no further increase in the size of the tumour; generally it will be required for about 24

<sup>1</sup>An ice-cap can easily be improvised, if there be enough indiarubber tubing available, by coiling the tubing around the head over some form of night-cap to which the coils are stitched to keep them in position.

hours. After that, if the hæmatoma be small and there be no reason to suspect any other injury, such as a fracture of the skull, little further need be done. The patient may be allowed to go about, but should be cautioned to avoid irritating the part by the pressure of the hat or by accidental scratching of the surface when combing the hair, etc. Absorption of the fluid usually takes place quite readily.

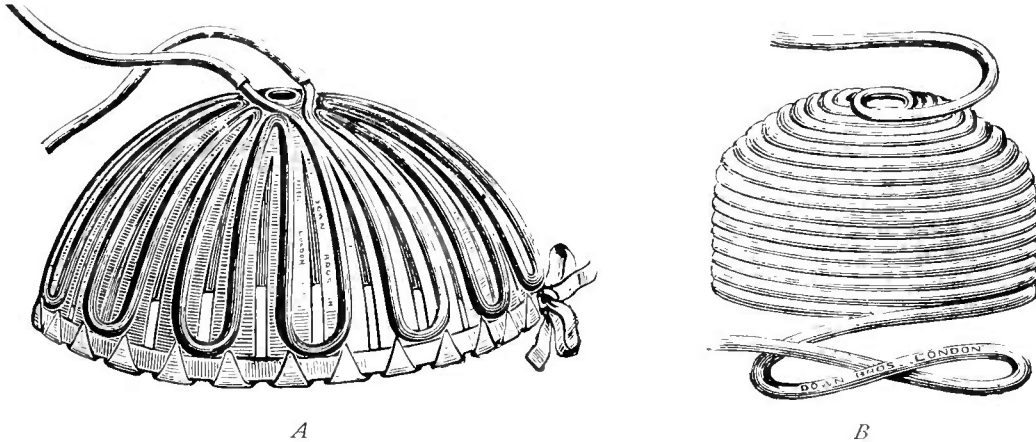


FIG. 1.—ICE-CAPS. *A* is the improved form of Leiter's metal ice-cap, *B* the one made of spirally arranged tubing.

**2. To hasten absorption.**—When absorption does not occur, which is most likely to happen when the hæmatoma is large, a blood-cyst may result and the treatment of that condition is more troublesome. When absorption has come to a standstill, the first additional treatment should be *the application of pressure*, which is best exerted by means of an elastic bandage outside a large mass of cotton wool previously applied over the swelling in order to diffuse the pressure. This arrangement should be kept on for two or three days and then reapplied if absorption has not taken place. When no elastic bandage is available, pressure may be applied by means of an ordinary bandage put on in the following manner. A large mass of cotton-wool several inches thick and large enough to overlap the hæmatoma in all directions for at least a couple of inches is in the first instance applied over the surface. About eight or ten strips of stout unbleached calico bandage three inches wide and about a yard long, are then laid over the scalp in such a way that the ends radiate from the centre of the sagittal suture over which the centre of each strip is placed; the ends of each strip hang down on opposite sides of the head. The strips are next firmly fixed in place by a few horizontal turns of a bandage encircling the skull from the root of the nose in front to below the external occipital protuberance behind. After this has been fastened, the corresponding ends of each strip are taken one by one in each hand and pulled upon tightly so as to stretch the bandage and make it exert powerful pressure over the cotton-wool. The two ends of each strip are then taken up in succession around the horizontal bandage and knotted together over the cotton-wool (see Fig. 2). In this manner very firm pressure, equally diffused in all directions,

can be exerted over the tumour. At the same time it must be admitted that the pressure obtained in this way is not nearly so good as that obtained by means of an elastic bandage. The pressure may be continued for about a fortnight or even longer, provided absorption goes on steadily.

In some cases, however, it will be found that, in spite of time and pressure, absorption comes to a standstill, that the central portion of the clot becomes fluid and that a blood-cyst is formed. Under such circumstances the cure will be expedited by *evacuating the fluid portion of the swelling* and then applying pressure. The evacuation can readily be done by means of a full-sized aspirating needle, but great care must be taken to purify the scalp in the vicinity of the puncture, as otherwise the needle may carry in infective material from the skin and suppuration may result.

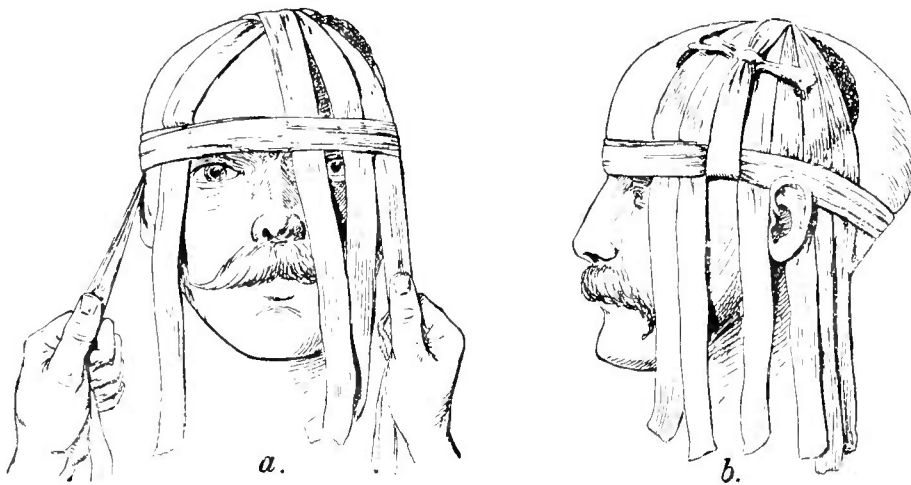


FIG. 2.—METHOD OF APPLYING PRESSURE TO A HÆMATOMA OF THE SCALP. In *a* the strips of bandage are shown in position and kept in place by the horizontal turns. The two ends of one particular strip are being pulled upon preparatory to turning them up and knotting them over the pad of wool as in *b*.

It is not, as a rule, necessary to shave the part to be punctured, but it is well to clip away a few hairs around the point where the needle will enter and then to thoroughly scrub the scalp with the ordinary disinfecting solution, *i.e.* "strong mixture" (see Part I., p. 46). A small incision should be made through the skin through which the aspirating needle is inserted into the cyst. A catgut stitch will close the wound afterwards, and a small antiseptic dressing should be fixed on with collodion. A mass of wool may then be placed over the hæmatoma and pressure applied as before.

Except in old-standing hæmatoma of considerable size, this treatment will generally lead to a cure. Occasionally, however, the fluid reaccumulates after tapping in spite of carefully applied pressure and it will then be necessary to *drain the cyst*. A small incision is made at the most dependent part of the tumour and a small drainage tube (No. 5 or 6) is inserted into its cavity. As a rule, it is well before putting in the drainage tube to introduce a sharp spoon and scrape away as much of the blood-clot on the



wall as possible. This not only removes material which is slow in organising but also enables the walls of the cyst to come together more readily. Great care must be taken with the aseptic management of the case for suppuration beneath the occipito-frontalis is a serious matter: it is well therefore to shave a considerable area of the scalp in the vicinity of the hæmatoma before operating and then to purify it scrupulously in the usual manner (see Part I., p. 161). The cyanide paste (*vide infra*) and antiseptic dressings are applied and are changed daily for the first two or three days. At the end of the third day the drainage tube can generally be left out and satisfactory healing will usually be obtained.

**3. To prevent infection.**—When there is a wound of the scalp in the vicinity of the hæmatoma, it should be treated as an ordinary scalp wound (see p. 6) even though it be a mere abrasion, as otherwise a violent and dangerous suppuration may be readily set up. Should suppuration occur in a hæmatoma, it must be freely opened and drained, the lining wall and all breaking down blood-clot being scraped away with a sharp spoon. Should the patient strongly object to the necessary shaving, the hair may be thoroughly impregnated with the double cyanide of mercury and zinc powder mixed into a paste with 1-20 carbolic lotion. If the hair be first thoroughly disinfected with strong mixture and then have a quantity of this paste plastered into it it practically becomes an antiseptic dressing and therefore need not be removed to any great extent.

**(c) THE SUB-PERICRANIAL HÆMATOMA.**—A hæmatoma underneath the pericranium occurs most frequently in young children, not uncommonly at birth. In the latter case it may be due to the compression of the foetal head, with consequent fracture of the external table of the parietal or frontal bone and rupture of the veins of the diploë. It is more common over the parietal bone than elsewhere. The extravasation is usually limited by the sutures and does not extend beyond the particular bone over which it first occurred. The characters of these extravasations, especially when absorption fails and a true blood-cyst forms, are the same as those already described in the sub-aponeurotic form, and it is especially in these cases that a mistake in the diagnosis between a blood cyst and a depressed fracture takes place. The absence of signs of compression and the absence of symptoms arising when the bone in the centre of the swelling is pressed upon imply that the case is one of cephal-hæmatoma rather than of depressed fracture.

**Treatment.**—The treatment of cephal-hæmatoma is in every way similar to that just described, and it is well to obtain rapid absorption of these swellings as soon as possible, as otherwise permanent injury to the bone may result. Indeed, in some cases the bone may become absorbed and perforated. Hence, if absorption of the fluid does not occur in the course of a week or ten days, resort should generally be had to puncture or drainage without further delay.

## SCALP WOUNDS.

Wounds of the scalp may be punctured, incised or contused, and may vary from a small abrasion or incision to detachment of the greater part of the scalp. A point common to all scalp wounds, and especially noticeable in the severer forms, is their great liability to sepsis, which is partly accounted for by the facts that micro organisms are very numerous upon the scalp, and that hair and scurf are generally driven into the wound, and partly by the fact that the wound is frequently produced by some dirty instrument and is usually more or less contused. Hence, there is a great risk of suppuration in all these cases, and this should be carefully borne in mind because suppuration beneath the scalp is a very serious complication, for not only may the pus extend far and wide beneath the aponeurosis, but there is also a great risk of thrombosis extending to the veins of the diploë and subsequently to the sinuses of the skull; moreover, even without any thrombosis, the affection may extend to the interior of the cranium and produce a suppurative lepto-meningitis. Hence, great pains must be taken in the disinfection.

From the point of view of treatment, scalp wounds may be divided into three degrees of severity: 1. those in which the wound is only through the skin; 2. those in which the aponeurosis of the occipito-frontalis muscle is divided and the pericranium or the cranial bones laid bare; and 3. those in which there is detachment of considerable portions of the scalp. In the first two cases the wounds may be either incised, contused or punctured; in the third they are almost always more or less contused.

**Treatment.**--In all cases of scalp wound there are three points of primary importance: 1. the arrest of the hæmorrhage; 2. the disinfection of the wound; and 3. the union of the cut edges.

**1. When the wound is only through the skin.**—The treatment here is quite simple. The hair in the immediate vicinity of the wound is clipped away, the scalp shaved for about half an inch around it, vigorously scrubbed, and the cyanide of mercury and zinc paste already alluded to (see p. 5) rubbed into the hair around. The wound itself should be scrubbed with strong mixture (see Part I., p. 46) and afterwards washed with 1-2000 sublimate solution. In these superficial wounds the bleeding as a rule stops spontaneously. In some cases, however, it may go on from one end of the wound as the result of incomplete division of a vessel, and under such circumstances a slight extension of the incision will cut the vessel completely across and permit of its retraction and the consequent cessation of the hæmorrhage. If there be any separation of the edges of the wound, one or two stitches, preferably of silkworm gut, should be inserted so as to bring them together. When the wound is small, a drainage tube is not usually necessary as the disinfection is generally satisfactory. An antiseptic dressing should be applied for the first 24 hours at any rate.

When the wound is quite small, the patient will usually wish to go about his business after 24 hours, and under such circumstances the larger dressing applied in the first instance should be removed, a small piece of gauze or salicylic wool fixed with collodion over the line of incision, a quantity of the cyanide paste (see p. 5) rubbed into the roots of the hair in the vicinity of the wound and the rest of the hair combed over this so as to prevent it showing. This dressing is allowed to dry and may be left untouched for ten days or even longer.

**2 and 3. When the aponeurosis of the occipito-frontalis is divided,** even greater care must be taken in the disinfection of the wound than where the wound is merely superficial. If the wound has been caused by a blunt instrument, hair is usually driven into it and is found sticking over its surface, and this, if left, is of course a certain source of infection. In many cases also the bleeding is fairly severe.

**Disinfection of the scalp.**—In the first instance, disinfection of the wound and the scalp around should be carried out, the hair being cut and shaved and the scalp immediately around disinfected: then the hair and dirt must be removed from the surface of the wound, which should be thoroughly soaked with strong mixture. If bleeding is going on, however, the disinfection is materially interfered with, and, therefore, when the wound is large and the bleeding gives trouble, and when the wound is much soiled, it is well to arrest the bleeding temporarily until disinfection has been carried out and then to tie the vessels. If the vessels be tied before the wound is thoroughly disinfected the ligatures themselves are apt to become infected and to be a source of subsequent danger.

**Temporary hæmostasis.**—The bleeding may however be readily controlled in wounds over the vault by taking a piece of indiarubber tubing and passing it two or three times round the skull from the glabella to beneath the occipital protuberance so as to act as a tourniquet. Should an indiarubber bandage not be available, a tourniquet can be made out of a piece of wetted calico bandage passed around in the same position and subsequently twisted up tight by means of a metal rod. This temporary arrest of hæmorrhage in large wounds is important, not only because it permits of proper disinfection of the wound, but in some cases because of the free bleeding which is taking place.

**Disinfection of the wound.**—Having arranged for the temporary arrest of hæmorrhage and having shaved the scalp in the vicinity, the wound is thoroughly exposed, opened up if necessary, and carefully cleaned. All hair is removed from it and any portions of tissue which are actually dirty are clipped away: in fact, when the wound has been caused by a blunt instrument and its edges are badly soiled, it is well to cut away a thin slice of the raw surface. In this way a healthier wound will be left which will more readily unite by first intention.

**Removal of contused bone.**—In bad cases, where a flap of skin has

been torn off, as for example when a cart-wheel has passed over the head or when the scalp has been cut in machinery accidents, it may happen that the bone beneath is fractured, or at any rate contused and soiled. The treatment for a fracture of the bone will be presently considered (see Fractures of the Skull). Where, however, as sometimes happens, especially in the injuries caused by cart-wheels, the external table of the skull is bruised and soiled without being fractured, it is well to chip away the obviously soiled surface with a chisel. The instrument should of course only go deep enough to take away the actually soiled area and should not open the diploë. Unless this be done, infection is apt to spread from this contused area and lead to very serious results. After the thin layer of soiled bone has been chipped away, the surface left may be touched with undiluted carbolic acid so as to disinfect it more effectually.

**Permanent hæmostasis.**—After the wound has been thoroughly cleaned with a nail brush and strong mixture, any portions of soiled tissue clipped away and the contused edges pared, the tourniquet may be relaxed and the bleeding points tied. If there be profuse bleeding from several points, a sponge may be packed under the flap, and by pressing the sponge and flap against the skull, the hæmorrhage can be arrested except at any given point where the surgeon is actually searching for the bleeding vessels.

In some situations it is by no means easy to stop the bleeding. For example, in wounds of the temporal artery, where the fascia is divided, the vessel may retract under the fascia to such an extent that it is a matter of extreme difficulty to catch the divided ends. In fact, in some cases it has been found necessary to tie the external carotid artery in order to arrest the bleeding. This is however a very severe procedure and is not really necessary except when secondary hæmorrhage takes place from the vessel. Under ordinary circumstances the proper procedure is to control the bleeding temporarily by digital compression of the trunk of the temporal artery as it passes over the zygomatic arch, and then to slit up the fascia and search for and tie the divided ends of the artery.

**Approximation of the edges of the wound.**—After having disinfected the wound and arrested the hæmorrhage, the edges should be brought together by a few interrupted sutures. The best material is probably silk-worm gut, which is firm, soft and flexible and at the same time does not absorb moisture and is not therefore likely to become a septic stitch. A drainage tube should be inserted at one angle of the wound, because it is impossible to be quite sure that the disinfection has been thoroughly carried out. If a large flap of scalp has been torn down so that the lowest limit of the separation is below the angles of the wound, the best plan is to make a small counter-opening through the centre of the flap at the lowest point and insert the tube through this.

A large dressing should be applied over the whole scalp and fixed on in the usual manner. If at the end of two or three days it be found that infection has not occurred, the drainage tube should be removed and the

wound allowed to close. In the case of these large wounds it is well to keep the patient in bed for three or four days and in the first instance to administer a purge and restrict the diet. But, if no adverse symptoms arise by the end of the fourth day, these restrictions may be removed and the case may be looked on as in a fair way to recovery.

#### ERYSIPELAS OF THE SCALP

Erysipelas of the scalp was formerly a very common complication of scalp wounds, but nowadays, when greater care is taken in disinfection, it has become less frequent. It may also arise as an extension from erysipelas of the face or neck, or in connection with a boil or other septic affection of the skin. Erysipelas of the scalp presents the ordinary features of erysipelas which have been already described in Part I., p. 216. Its gravity in this region is owing to the great tendency of the inflammation to spread to the skull and lead to septic meningitis or septic thrombosis.

**Treatment.**—The treatment of erysipelas of the scalp is practically the same as that of erysipelas elsewhere. It is well to shave the head and thoroughly disinfect the skin, and then to carry out treatment on the lines laid down in Part I., p. 218.

#### ACUTE CELLULITIS OF THE SCALP

Acute cellulitis of the scalp is also a common result of scalp wounds that have become infected, and it sometimes also occurs in combination with erysipelas. It is a very grave condition, because in the first place the pus tends to spread beneath the fascia over a large area of the head, and in the second place it is extremely liable to lead to sinus thrombosis with pyæmia or septic lepto-meningitis.

**Treatment.**—The treatment of this condition has already been described in speaking of diffuse cellulitis in Part I.; when this affection occurs in the scalp, the treatment must be even more energetic than elsewhere, owing to the rapid manner in which the inflammation may spread over the vertex, and owing to the tendency to the formation of independent collections of pus. *Free incisions* must be made through the occipito-frontalis aponeurosis, usually in a vertical direction, and they must extend well below the inflammatory area. *Boracic fomentations* should be applied after the scalp has been shaved, or in bad cases *irrigation* may be employed, the head and neck being surrounded by a mackintosh in such a way as to carry off the fluid without soiling the bed. In employing irrigation in cases in which there is any tendency to meningitis, the water may be cold, so as to effect not only irrigation of the wound but diminution in congestion owing to the use of cold. When the inflammation has become limited, the irrigation may be given up and an antiseptic ointment, such as boracic, may be substituted.

## BOILS AND CARBUNCLES OF THE SCALP

Boils and carbuncles are not very common on the scalp, but they are sometimes met with about the back of the head or over the mastoid process, and, like other septic inflammations, they are very dangerous, more especially carbuncles, owing to the fact that they are apt to give rise to sinus phlebitis or meningitis. It is well to *incise and scrape out the carbuncles freely* and apply pure carbolic acid, and at the same time to attend to any constitutional affection, such as diabetes, that may be present (see Part II., p. 147).

## ULCERS OF THE SCALP

Ulcers of the scalp may occur in connection with acute inflammations followed by sloughing of portions of the scalp, in connection with sloughing after burns or lacerations, or they may be of specific origin, especially syphilitic or tuberculous.

**SIMPLE ULCERS.**—When the ulcers are due to loss of tissue, as for example after burns or lacerations, the slowness in healing is due to the difficulty in contraction of the wound. When a large area of the soft tissues has been lost, the granulations which spring up fix the edges of the wound and very soon prevent the diminution of the sore by contraction. The result is that after a time healing ceases, or, if healing does occur, the scar is very thin and delicate and constantly breaks down.

**Treatment.**—Bearing this fact in mind, the best practice is, as soon as all the sloughs have separated and the wound is granulating, to *skin-graft the whole surface* in the manner already described (see Part I., p. 50). So long as the operation is not delayed until the healing process has ceased owing to the failure of contraction, the grafts take well and a sound scar is left. If the grafting be not done until late in the course of the case, the grafts do not obtain such a good hold, owing to the fixation of the granulation tissue to the bone.

**SPECIFIC ULCERS.**—The ulcerations of the scalp resulting from syphilis or tuberculosis are usually secondary to syphilitic or tuberculous disease of the skull and seldom begin in the scalp itself. When **gummata** commence in the scalp they usually readily yield to the employment of anti-syphilitic remedies (see Part I., p. 235). The most common form of tuberculous disease of the scalp is **lupus**, but it is very rare as a primary disease, and even where there are lupoid ulcers in neighbouring parts of the face, the disease does not tend to spread over the scalp so readily as in other directions. The treatment of tuberculous ulcers of the scalp, whether lupoid or the ordinary variety, is that recommended for tuberculous ulcers in general (see Part II., p. 152), and consists essentially in thoroughly *scraping* the ulcer and applying nitric acid or undiluted carbolic acid, or in *excision and grafting*.

## AIR TUMOURS.

Collections of air beneath the scalp are sometimes met with after injuries about the head; they may occur in two forms. There may be a condition of emphysema of the scalp in which the air is diffused through the cellular tissue, or there may be a more localised tumour containing air, commonly termed a pneumatocele.

**EMPHYSEMA OF THE SCALP.**—Emphysema of the scalp is not very uncommon and is usually associated with fractures, more especially of the nasal or ethmoid bones, or of the anterior wall of the frontal sinus. Under these circumstances air is driven into the cellular tissue when the patient blows his nose and may give rise to considerable emphysema of the scalp.

**Treatment.**—As a rule no treatment is required for this condition, but, should there be any undue distension, the skin may be punctured in order to allow the air to escape.

**PNEUMATOCELE.**—Of much greater importance, although of greater rarity, is the condition known as pneumatocele, in which there is a cavity distended with air and communicating with air-cells in the bone beneath. These tumours have been met with especially in the region of the mastoid process and also sometimes about the frontal sinus. They arise in connection with defects in the bone, such as sometimes occur over the mastoid region, so that a communication is established with the air cells beneath. As a result, air is forced from the middle ear through the opening by violent efforts, such as sneezing; this raises the pericranium and thus in the course of time a tumour may be developed. These bony defects may be congenital or acquired: if congenital, they are generally the result of incomplete closure of the squamo-mastoid suture. The tumours do not as a rule give rise to any special symptoms.

**Treatment.**—Punctures and incisions have been employed; apparently the best results have followed *puncture and the subsequent injection of iodine*. Unless however the tumour is of such a size as to cause deformity it is best not to interfere with it.

## TUMOURS OF THE SCALP.

**ATHEROMATOUS CYSTS.**—A variety of tumours may be met with in the scalp, the most common of which is the atheromatous or sebaceous cyst, also popularly called a wen. These cysts are usually multiple and some of them may reach a considerable size. They are generally thick-walled and, unless inflammation has occurred from irritation of the hat, etc., the wall of the cyst is usually separated easily from the surrounding parts. These sebaceous cysts may however, as the result of pressure, be accompanied by inflammation of the skin, or by suppuration in the tissues around the cyst, and under these circumstances its wall becomes

attached to the bed in which it lies and the removal of the tumour is by no means an easy matter. In some cases also sebaceous cysts have been the starting point of an epithelioma.

**Treatment.**—The treatment of these cysts is *excision*, and, seeing that they will steadily increase in size, it is best to remove them while they are still small. As a rule it is hardly necessary to shave the skin over the tumour; at most a few hairs along the line of incision may be cut away. The scalp and hair in the neighbourhood should however be thoroughly disinfected and a quantity of the cyanide of mercury and zinc paste (see p. 5) should be well rubbed in. A straight, narrow-bladed bistoury is then pushed through the cyst, with the edge directed upwards, and the knife is made to cut upwards so as to divide the outer half of the cyst wall. If now a little pressure be made on each side, the cyst wall will be seen to protrude from the bed in which it lies and can be seized with forceps and with a little care can be pulled out from the

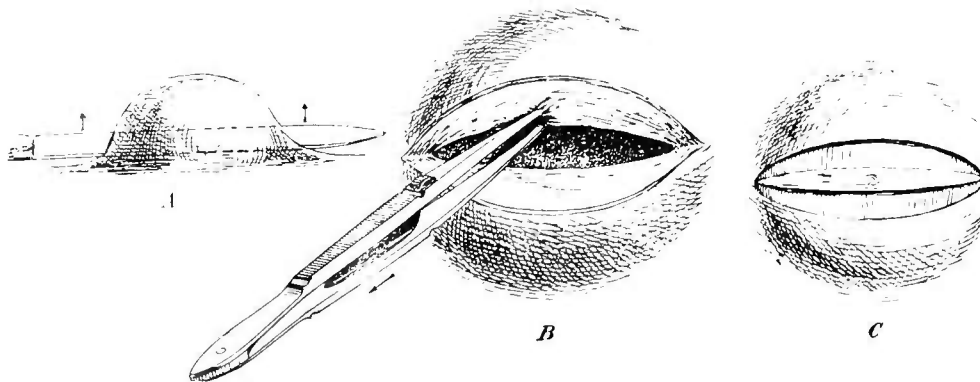


FIG. 3.—METHODS OF REMOVAL OF SEBACEOUS CYSTS. In *A* and *B* are shown the stages of the removal when the cyst wall is thick and firm, *e.g.* on the scalp. The cyst is first cut across by transfixion, and its contents squeezed out; then, as shown in *B*, the wall is laid hold of by catch-forceps and traction exerted. The wall pulls out and only a mere touch of the knife is required. In *C* the cyst is dissected down upon from outside, a portion of the thinned skin being included in the elliptical incision.

tissues around (see Fig. 3). When the tumour is larger, it is well to make an elliptical incision enclosing a sufficient amount of the thinned and superfluous skin, and then, when the cyst wall is reached, to shell out the cyst by means of a blunt dissector without opening it. A small vessel may require twisting at the bottom of the cavity, and then one or two points of interrupted catgut suture may be applied so as to bring the skin edges together. As these edges are very thin, they are apt to curl inwards, and this must be borne in mind in putting in the sutures.

In cases of fairly large cysts it is well for the first twenty-four hours to apply a pad of antiseptic gauze over the area of the operation and to fasten it on with a firm bandage so as to arrest the oozing into the cavity. Unless this be done, there is apt to be a collection of blood-clot distending the cavity which may render the healing slow, or, should infection take place, may break down and suppurate. At the end of twenty-four hours the bandage and pad may be taken off, a small collodion dressing fixed on,



some of the cyanide paste rubbed into the scalp, and the hair combed over the dressing. At the end of a week the dressing may be picked off and the wound will be found to have healed.

*When the cyst wall has become inflamed* and adherent to the surrounding parts, the tumour must be cleanly dissected out, and great care must be taken not to leave any part of the cyst wall behind. A general anæsthetic will usually be necessary, and it is well early in the operation to define some part of the cyst wall, preferably the deeper part where the inflammation is less, and then, by passing a dissector around the wall from this region, it will generally be possible to get an indication of the limits of the cyst and so to remove it without opening it. A drainage tube must be put in for two or three days in case the wound should become infected as the result of the previously existing suppuration.

**DERMOID CYSTS.**—Dermoid cysts are not uncommon on the scalp and are most frequently found about the external angular process of the frontal bone, the root of the nose and the fontanelles. The chief point of interest in connection with these cysts is their differential diagnosis from meningocele, with which they are apt to be confounded. They are not, however, influenced in size by pressure, they do not diminish during sleep, and their contents are not so fluid as those of meningoceles.

**Treatment.**—The treatment of these cysts is *removal by dissection* and not by incision of the cyst as described in speaking of sebaceous tumours. It must be remembered that a dermoid cyst does not lie in the skin as a sebaceous cyst does, but in the subcutaneous cellular tissue, and an incision must therefore be made through the skin over the tumour until the cyst wall is reached, when it is usually quite easy to shell it out intact with a blunt dissector. The other details as to disinfection and subsequent dressing are the same as those just mentioned for sebaceous cysts.

**NÆVI.**—A variety of other tumours which do not require any special mention occur about the scalp: such are fibromata, lipomata, papillomata, horny growths, etc. The only tumours which require special notice are the vascular group. The scalp is a very common seat of nævus, the subcutaneous variety being probably the most frequent. Nævi may occur anywhere over the hairy scalp, but they are most common about the anterior fontanelle and in the frontal region. In the neighbourhood of the fontanelle the tumour may reach a considerable size and may sometimes extend to the dura mater.

**Treatment.**—The treatment of nævi has already been described (see Part I., p. 265). The ideal treatment, when the nævus is quite small, is *excision*, but, when the tumour is large and the child very young, the loss of blood entailed by the operation may be too severe, and under such circumstances electrolysis is the better procedure. A very large number of nævi of the scalp can however be quite safely excised, the principal point of importance in the performance of the operation being to remove

the tumour very rapidly, cutting quite wide of its limits. When this is done, the main vessels can be immediately controlled by pressure until they are picked up and tied. This is a much better plan than wasting valuable time in attempting to secure the vessels as the operation proceeds.

In applying *electrolysis* for nævus of the scalp care must be taken not to use too strong a current (20-40 milliampères), especially when the tumour is situated in the neighbourhood of the fontanelles. Indeed, unless the nævus be growing rapidly, it is well to wait until closure of the fontanelle has taken place before commencing treatment. If too strong a current be employed, or if it be increased too rapidly, severe and even fatal shock may result. When the electrolysis is finished, the current must be gradually reduced to zero and must not be shut off at once.

**CIRSOID ANEURYSM.**—The scalp is one of the favourite seats of the curious condition known as cirroid aneurysm, which most usually affects the auriculo-temporal region. In cirroid aneurysm there is a varicose condition of the arteries which become elongated as well as dilated and tortuous. The capillaries are also dilated and the accompanying veins may likewise be involved. The result is the formation of a blood tumour with tortuous vessels in its neighbourhood. The cause of this condition is practically unknown. Sometimes there is a history of injury, in other cases the condition apparently arises spontaneously.

**Treatment.**—The treatment of these cases is a matter of considerable difficulty, and a great variety of methods have been employed. The best of all is of course *extirpation*, whenever the situation or the size of the tumour permits of its employment. In carrying out the extirpation of the tumour the main trunks of the arteries feeding it should be first exposed and ligatured. In the ordinary situation, the trunk of the temporal artery must be exposed as it passes over the root of the zygoma, and after it has been tied, the skin may be dissected off the tumour, removing of course any redundant portion over the most prominent part; any outlying large vessels are clamped, and the mass of dilated vessels is then removed.

The only limit to the applicability of excision is the extent of the tumour. When this is very large and much skin has to be taken away, the space may be filled up by skin-grafts. In cases which are not suitable for excision, various other methods of treatment have been recommended, such as ligature of the main trunk of the external or the common carotid artery, the application of caustics, the use of electrolysis, the injection of coagulating materials and so forth, but these as a rule are more or less ineffectual.

**OTHER ANEURYSMS.**—True aneurysms of the arteries of the scalp are rare, and if they occur they can generally be attacked by the direct operation (see Part II., p. 310). False aneurysms, the result of injury,

may however be met with, and in former times were not very uncommon. They were usually found on the anterior branch of the temporal artery and arose in connection with phlebotomy of that branch. Under similar circumstances also aneurysmal varix has arisen from puncture of the accompanying vein as well as the artery. The treatment of these conditions is excision of the sac, just as in the case of traumatic aneurysm elsewhere (see Part II., p. 297).

## CHAPTER II.

### AFFECTIONS OF THE SKULL.

#### FRACTURES.

FRACTURES of the skull vary in character and gravity according to the situation of the fracture, viz., whether it is chiefly in the vault or in the base; according to its extent; according to whether the fracture is complete, or whether only one table is injured; whether the broken pieces are depressed, etc.; lastly, it also varies with the instrument inflicting the injury.

The effects of injuries sufficiently severe to produce a fracture of the skull are not as a rule limited to the mere fracture. Various complications ensue, some more and some less frequently; among the most important are concussion, laceration, and compression of the brain; various septic complications, such as erysipelas and cellulitis of the scalp; osteo-myelitis of the skull, lepto-meningitis, cerebral abscess: paralyse of motion, sensation or special sense: hernia cerebri; subsequent mental derangements, persistent headaches, or traumatic epilepsy. These complications will be considered in detail later on. In the present chapter we shall simply deal with fractures *per se*. As regards situation, fractures of the skull are divided into those of the vault and those of the base.

#### FRACTURES OF THE VAULT OF THE SKULL.

These fractures are generally due to direct violence, though sometimes they are merely upward extensions of a widespread fracture of the base; the whole thickness of the skull may be involved or one table only may be broken.

**FRACTURE OF THE EXTERNAL TABLE ALONE.**—In some cases, especially when the injury has been inflicted with a sharp instrument and the blow has fallen obliquely upon the skull, the outer table alone may be injured. This form of injury may also occur in situations where there is a considerable interval between the outer and inner tables, notably over the frontal sinus, or the mastoid process. The fracture most commonly

occurs over the frontal sinus, the anterior wall of which may be readily broken in without causing any fracture of the base or the neighbouring parts of the skull.

The importance of these fractures is mainly determined by whether or not they are compound. When compound, they are naturally prone to become the seat of the various septic complications, and, as a matter of fact, except for some cases of fracture of the anterior wall of the frontal sinus, fractures of the outer table alone are almost always compound.

**Treatment.**—(a) **Of simple fracture.**—When the fracture is not compound—*e.g.* fracture of the anterior wall of the frontal sinus—the treatment is comparatively simple. All that is necessary is to keep the patient at rest for a few days and to syringe the nose gently from time to time with boracic lotion or a weak solution of sanitas or Condy's fluid. As a rule simple fractures of the outer table both here and in the mastoid region unite rapidly and satisfactorily.

(b) **Of compound fracture.**—When the fracture is compound, the treatment must be a combination of that required for a scalp wound and that for a compound fracture. The scalp and the wound in the soft parts must be thoroughly disinfected in the manner already described (see p. 7), after which the surface of the skull is carefully examined, any loose or projecting portions of bone removed and any obviously soiled area gouged or chiselled away. The bone and the soft parts are then swabbed freely with undiluted carbolic acid and a drainage tube of sufficient size is inserted before putting in the sutures. The dressing should be similar to that employed for scalp wounds and, if no septic complications occur within three days, the case may be looked upon as doing well and the drainage tube may be left out.

**FRACTURE OF THE INTERNAL TABLE ALONE.**—It is only very rarely indeed that the internal table is broken without the external one being simultaneously fractured, but a few cases of the kind have been put on record.

In children there may be a sort of green-stick fracture of the skull in which, as the result of a blow, the internal table gives way and the external table is simply bent inwards, thus giving rise to a *saucer-like depression* of the bone. Under such circumstances there are not necessarily any symptoms, unless there be a hæmorrhage accompanying the injury to the skull.

**Treatment.**—Unless the fractured portion of the internal table gives rise to symptoms of cerebral irritation or unless there be signs of compression produced by some co-existing hæmorrhage, the condition will of course not be recognised. Should these symptoms arise, the treatment appropriate to them must be had recourse to. Reference will be made to these cases presently.

Usually if the cases of saucer-like depression in children be left alone and the child simply put to bed and an icebag applied, no symptoms

arise. The bone is soft and the depression is generally spontaneously obliterated in a comparatively short time. Of course, if there should be any symptoms of compression or cerebral irritation, it is best to cut down upon the depressed area, trephine the bone, remove or elevate any portions of the inner table which may be displaced and arrest the hæmorrhage; but it is seldom that the operation is called for.

**FRACTURE OF BOTH TABLES OF THE SKULL**—Fractures of both tables of the skull vary in character according to the nature of the instrument which causes the fracture, and according to the direction in which the force is applied, etc. They are usually divided into three great groups, namely, fissured fractures, depressed or comminuted fractures and punctured fractures, such as those caused by a bayonet wound or a sword-cut.

**1. Fissured fracture.**—When a fissured fracture is examined, no difference in level is found between the two portions of the bone. All that is seen from the outside is a crack in the skull. The fissures through the two tables seldom correspond exactly; usually the internal table is more broken up than the external. It may also happen that portions of the former may project downwards on to the dura mater. These fissured fractures, unless they lead to rupture of one of the meningeal arteries and thus cause hæmorrhage between the dura mater and the bone, are not as a rule recognised, unless there is also a scalp wound communicating with the fracture. When there is no wound, the existence of a fissure can only be suspected when complications, such as intra-cranial hæmorrhage, supervene.

**2. Depressed fracture.**—Depressed fractures may be simple or compound, but, as a rule, a degree of violence sufficient to break up a portion of the bone and cause marked depression is also sufficient to rupture the scalp as well. The bone is broken up into several fragments according to the degree of violence producing the fracture; some of these fragments may be loose, so that there is a true comminuted fracture; others again may be only partly broken across and may still remain attached at some part. The degree of comminution and detachment of the fragments varies of course with the character of the force, but, even when the fragments are not detached, they may be bent downwards so as to exert considerable pressure on the brain. In addition, it is usual to find fissures of the skull radiating from the area of comminution.

The internal table is always more extensively broken up and more detached than the external, so that the amount of injury evident externally does not fully indicate the amount of injury in the deeper parts. These fractures are naturally always associated with more or less hæmorrhage, and the amount of blood effused beneath the skull is the chief cause of the symptoms of compression which follow. It is but seldom that the bone is sufficiently depressed to cause general compression symptoms, although when the depression is over a motor area it may give rise to paralysis or irritation

of that area. When the general symptoms characteristic of compression are associated with a depressed fracture it will generally be found that some vessel has been torn and that there is, in addition to the depression of the bone, a collection of blood between the latter and the dura mater. The hæmorrhage in these cases may be severe and usually occurs from branches of the middle meningeal artery. It may also result from laceration of one of the sinuses of the brain; this condition of intra-cranial hæmorrhage will however be better considered separately (see p. 42).

**3. Punctured fracture.**—Punctured wounds of the skull are those caused by some sharp instrument, such as a bayonet, a sword, etc. The wounds are always compound and the bone is not so comminuted as in the previous case. The inner table of the skull is however more completely broken up and is often extensively fractured as compared with the external. In a punctured fracture—such, for instance, as one caused by a bayonet—there is visible from the outside only the hole in the external table, along the groove of which small fragments of the bone are driven in; the internal table however is usually considerably detached and projects against the dura mater, which it may even perforate, so that its sharp edge projects into the brain itself. It is very important to remember in these punctured fractures that, however insignificant the external wound may appear, there is practically certain to be considerable and serious damage to the internal table, which must be remedied if the patient is to be restored to complete health. In these cases also, the instrument itself is very likely to puncture the dura mater and lead to hæmorrhage from the vessels in it or even from the vessels on the surface of the brain. In cases of sword or axe-wounds the essential conditions are the same, except that, instead of a hole in the external table, there is a long cut—the so-called “gutter fracture.” The internal table is extensively broken up and depressed. As these fractures are always compound, they are specially liable to be followed by suppuration.

**Treatment. 1. Of fissure of the skull.**—In fissure of the skull very little in the way of active treatment is required. As has been already said, these fissures, unless accompanied by some intra-cranial injury, are only recognised when the fracture is compound, and the treatment is essentially the same as that already described for scalp wounds (see p. 7). The disinfection of the wound should be especially thorough, but, beyond keeping the patient quiet in bed for a few days and seeing to the asepsis of the wound, there is practically nothing necessary.

In some cases however these fissures give rise to intra-cranial affections, more especially to intra-cranial hæmorrhage or to intra-cranial suppuration, and then appropriate treatment must be adopted. Unless however there be symptoms of compression or of intra-cranial suppuration nothing need be done in the first instance in the way of operation on the bone. Sometimes, when the fissures are extensive and numerous and when there is any irregularity about the edges, it may be well to remove a portion of the

outer table with a chisel, so as to ascertain the condition of the internal table. The procedure is the same as that to be immediately described for other forms of fracture.

**2. Of depressed fracture.**—It may be laid down as an axiom that the depressed fragments should be elevated or removed, any detached portions of bone taken away, and all hæmorrhage arrested without waiting for cerebral symptoms to supervene; besides this, when the fracture is compound the parts should be thoroughly disinfected. Hence in all cases of depressed fracture—with the exception of the saucer-like depressions in young infants already alluded to—operation is advisable, whether the fracture be simple or compound, and if operation is to be done, the sooner it is performed after the patient has recovered from the shock the better.

**Simple depressed fracture.**—We shall consider first the treatment of simple depressed fractures. The first procedure here is to *shave the scalp* thoroughly over a large area, preferably over the whole head, and to thoroughly disinfect it in the manner already described (see p. 7). The area of the fracture must next be thoroughly exposed, and this is best done by raising a semi-lunar flap rather than by the crucial incision which was formerly used. The semi-lunar flap has the great advantage that the skin incision is made well away from the line of fracture, so that after the operation there is a sound layer of skin and fascia over the opening in the bone; in the older incision the apices of the four triangular flaps made by it came absolutely in the centre of the wound, so that if there were a tendency to hernia cerebri, the hernia could readily escape through the wound. The flap must be so arranged that it well overlaps the depressed area; as a rule half an inch should be allowed beyond the area from which bone will be taken away. The flap should be cut so that the main vessels enter at its base; as a rule its convexity is upwards and the flap is therefore turned downwards. The incision should be carried at once through the skin and pericranium, and the latter should be raised with a periosteum detacher along with the flap. When the flap has been turned down, the fractured area is exposed to view, and the bleeding must first be stopped, most of it temporarily, by catching up the vessels in Spencer Wells' forceps.

*Removal of bone.*—The further procedure will depend largely upon the amount of comminution and the presence of loose fragments. In some cases of badly comminuted fracture, loose portions of the bone can be lifted out and access thus at once obtained to the rest of the depressed area. An elevator should then be gently insinuated between the dura mater and the bone and the remaining depressed portions elevated. If any of the fragments are completely detached, it is well to remove them, so as to get a better view of the deeper parts, and in any case any sharp projecting fragments of the internal table should be clipped away, which can be easily done with punch forceps. In all cases it is well, in removing detached fragments, to take care not to tilt them, as otherwise



the sharp edges may lacerate the dura mater; they should be removed very gently, and drawn out as nearly as possible parallel to the level of the skull (see Fig. 4). This point is also specially important in cases of

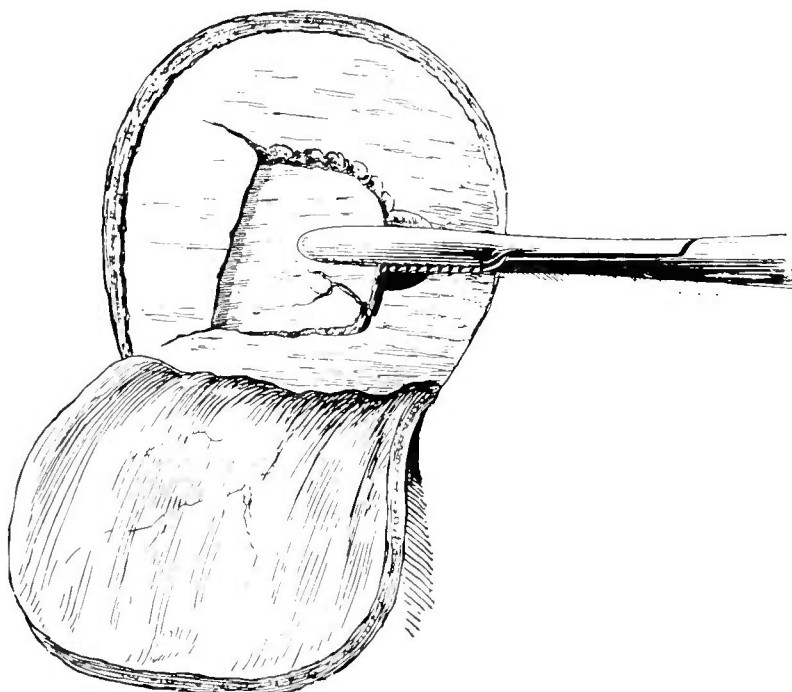


FIG. 4.—METHOD OF REMOVING A DEPRESSED FRAGMENT OF THE SKULL IN A DEPRESSED FRACTURE. A large flap has been turned down and a half-circle of the sound skull has been removed with a trephine. Through the aperture thus made the blade of a pair of forceps is introduced beneath the depressed fragment, which is then removed, the forceps being kept flat against the skull during the removal. In the case depicted above it was necessary to cut away some of the sound skull above the fragment with Hoffman's forceps in order to allow of extraction.

gutter fracture where, if the dura mater be not actually torn, fragments of the internal table are generally sticking into its outer surface. Forceps suitable for this purpose are shown in Fig. 5.

Should sufficient space not be obtained by the removal of the comminuted fragments, it is usually quite easy with a pair of Hoffman's

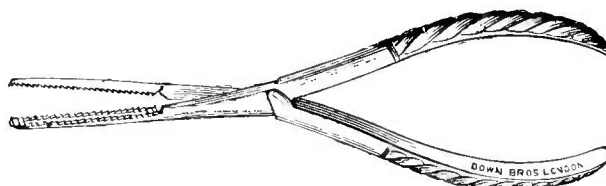


FIG. 5.—FORCEPS FOR ELEVATING DEPRESSED PORTIONS OF THE SKULL. The blades are flattened and powerful; the teeth are directed backwards so as to ensure good grip on the bone and to prevent slipping.

forceps (see Fig. 6) to punch out further portions of the bone so as to give enough room. It must be remembered that the chief object of the operation is to raise all the depressed bone and to remove any sharp edges of the internal table which may be projecting against the dura mater, and therefore sufficient space must be obtained to make sure that this object has been attained before the wound is stitched up. When the fracture is not compound, the loose fragments of the bone removed and the por-

tions punched out should be kept in order that they may be replaced at the end of the operation. The best way of keeping them is to raise the flap a little at one side with the handle of the knife and to push the fragments of bone under the flap until they are required. In this way the bone is kept bathed in serum and blood at the temperature of the body, and the bone cells are less likely to lose their vitality than if the

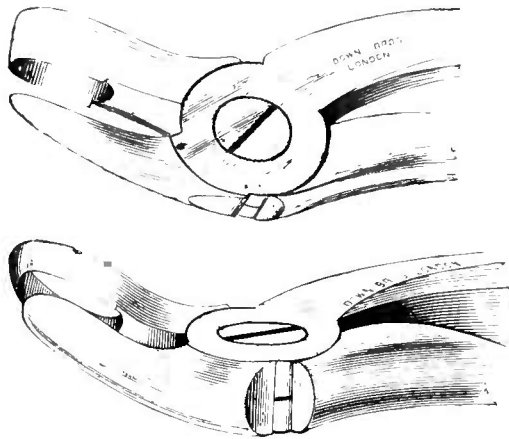


FIG. 6.—HOFFMAN'S FORCEPS. These forceps are very frequently used for cutting away portions of the skull piecemeal. They are very powerful punch forceps, the lower solid blade fitting into the hollow of the upper hollow one. They are made in all sizes and degrees of strength, and the beaks of the instruments are variously curved so as to facilitate their application.

fragments were placed in warm boracic lotion or warm salt solution as is usually recommended. Of course, the latter procedure may be followed should the circumstances of the case preclude the adoption of the plan we recommend.

In some cases, however, it will be found on cutting down on the fracture that there are no actually detached fragments, and it will then be necessary to open up the depressed area by removing a portion of the bone with the trephine. The pin of the trephine must be applied on firm bone close to the line of the fracture, and rather

more than a half circle of the uninjured bone is taken away (see Fig. 4). This gives free access to the deeper parts and permits elevation of the depressed fragments and removal of any detached portions of the internal table, etc., in the manner above described. The portions of bone removed with the trephine should be preserved and subsequently replaced in the wound.

In *trephining*, it is well to use a bevelled trephine with a loose pin (see Fig. 7) and a crown of about an inch in diameter, and it is well to have the trephine attached to a centre-bit so as to enable it to be worked more quickly and smoothly. When a fairly deep groove has been cut in the bone, the pin is withdrawn and the sawing of the bone continued. The skull varies in thickness at different parts, and, being convex, the trephine is apt to bear more markedly on one side than on the other, and hence one part of the circle may be sawn through before the others. Unless care be taken, the result will be that the dura mater is lacerated on that side, and even the brain may be injured. Therefore, after the trephine has got well into the diploë, it should be removed and the end of a flattened probe or a quill should be passed around the groove to ascertain whether at any point the bone is nearly or entirely cut through. Should this be the case, the pressure must be made to tell on the thicker portions, and thus the bone can be sawn through without injuring the dura mater. When the division

of the circle is almost complete, the introduction of an elevator of suitable size will generally force out the circle of bone, which should then be pushed under the scalp and kept there until the end of the operation. The subsequent steps of the treatment are the same as those already described; the depressed fragments of bone are elevated, the internal table is examined, and any projecting fragments are removed.

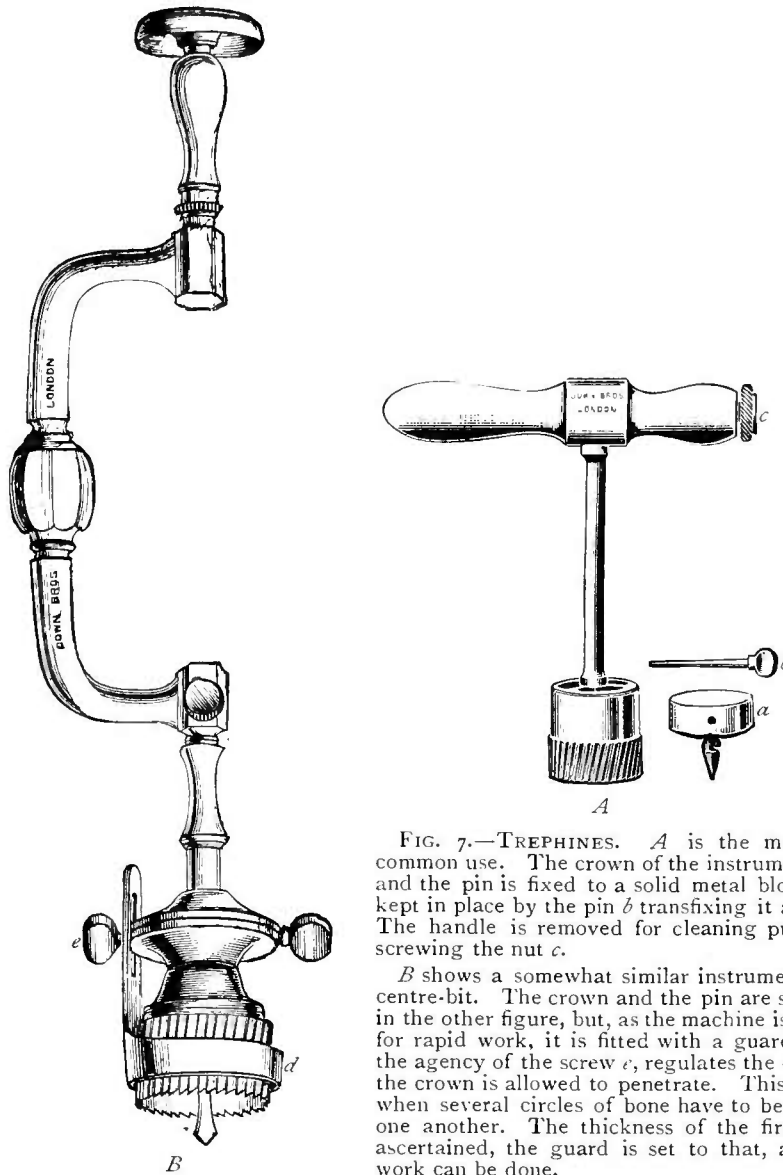


FIG. 7.—TREPHINES. *A* is the modern form in common use. The crown of the instrument is bevelled, and the pin is fixed to a solid metal block *a*, which is kept in place by the pin *b* transfixing it and the crown. The handle is removed for cleaning purposes by unscrewing the nut *c*.

*B* shows a somewhat similar instrument worked as a centre-bit. The crown and the pin are similar to those in the other figure, but, as the machine is here intended for rapid work, it is fitted with a guard *d*, which, by the agency of the screw *e*, regulates the depth to which the crown is allowed to penetrate. This is most useful when several circles of bone have to be removed near one another. The thickness of the first circle being ascertained, the guard is set to that, and very rapid work can be done.

*Arrest of bleeding.*—Special attention must be paid to the arrest of any hæmorrhage from the meningeal vessels; in some cases this is much more important and difficult than the treatment of the depressed fragments. Any blood-clot between the dura mater and the bone must be cleared away and any active bleeding looked for. If blood wells up from the depths of the wound, an attempt must be made to arrest it, and this will usually entail the removal of further portions of the bone: this is most easily and rapidly done with a pair of strong Hoffman's forceps. The case at this stage very closely resembles one of extra-dural hæmorrhage after the

clot has been turned out, and the further steps necessary to arrest the bleeding are identical. They will be found fully described in the chapter dealing with intra-cranial hæmorrhage, to which they more properly belong. (See Chap. III.)

*The replacement of the bone.*—After having arrested the bleeding, the surgeon next has to see to the closure of the wound, in which the chief question of importance is whether the portions of bone removed should be replaced or not. That these fragments will unite and fill up the gap in the skull is amply proved, and apparently union occurs equally well whether the circle removed by the trephine be replaced entire or whether it be first broken up into smaller fragments. It is perhaps better on the whole in these cases to break up the fragments into smaller pieces, but they should not be cut up too small. In cases of meningeal hæmorrhage, however, if the bleeding has gone on for any time, the brain may not immediately expand, and unless it does so the bone, of course, will not have a proper substratum to rest upon. Hence the question of the replacement of the bone will depend upon the expansion of the brain; if the dura mater bulges into the opening in the skull, the portions of bone should be replaced.

The replacement of the bone is even more important when the dura mater has been lacerated and cannot be closed, because the replaced bone would form an obstacle to protrusion of the brain. In these cases, however, the cerebral cortex is apt to become adherent to the torn edge of the dura mater or to the bone itself, and these adhesions are known to be a potent cause of epilepsy or even of certain forms of insanity. With the object of avoiding such a complication, various substances have been placed between the brain and the skull. Oiled silk, Lister's protective and other materials have been used. The best seems to be thin gold-foil, which is placed over the surface of the brain beneath the dura mater and extending beyond the torn edges of the latter for a quarter of an inch or more: this does not seem to cause any trouble, while it effectually prevents adhesions. The bone is not replaced when gold-foil is used.

The flap may be stitched down with a continuous suture and in most cases it is not necessary to put in a drain. Should oozing be still going on from the cut surfaces of the bones however, it will be advisable to put a drainage tube beneath the flap for 24 hours. As a rule however it is better not to use a drain unless there be a risk of so much bleeding as would reproduce the symptoms of compression.

*After-treatment.*—The patient should be kept in bed in a dark room, and noise and disturbance of all kinds should be avoided. The bowels should be freely opened by means of a purge (calomel, grs. iv.-vii.), stimulants should be avoided and a liquid diet maintained for a few days. If no drainage tube has been inserted, the dressing need not be changed for about ten days, otherwise the tube should be removed at the end of 24 hours.

**Compound depressed fracture.**—When a depressed fracture is compound the conditions are not nearly so favourable, for there is certain to be septic material in the wound and the fractured surfaces are probably extensively soiled. The first point, after having shaved the head and thoroughly disinfected the scalp, is to open up the wound in the skin in any direction needful to fully expose the injured area. The skin is raised with the pericranium attached to it and held aside so as to expose the fracture. Before proceeding to deal with the bone itself, the best plan is to thoroughly disinfect the edges and deeper parts of the wound in the manner already described (see p. 7), and to apply undiluted carbolic acid to the raw surfaces in addition. Any bleeding vessels are then clamped and the fracture is next dealt with. The entire fractured area should be opened up completely, either by the removal of loose fragments or by a preliminary trephining in the immediate neighbourhood (see p. 22). The loose fragments should all be removed and the fractured surfaces cleaned from dirt and blood-clot and touched with undiluted carbolic acid.

It is usually best not to replace the detached fragments in these cases; they are soiled and must be disinfected thoroughly and their vitality may be thereby so seriously impaired that they may fail to unite afterwards. At the same time, decalcified bone if at hand, may be cut up into fragments and spread over the dura mater, and, if this does not afterwards separate, it will lead to the formation of a strong fibrous membrane over the opening in the bone. In all cases of compound fracture the wound should be stitched up over the line of fracture, but an opening should be made for drainage at the most dependent part because it can never be certain that the disinfection has been successful.

**3. Of punctured fracture.**—A case of punctured fracture must always be operated upon in order to remove the detached portions of the internal table of the skull which are almost certain to be projecting against and irritating the dura mater. The same holds good with regard to “gutter fractures” produced by swords, axes, etc.

The best plan is to turn down a flap which has the hole in the skin about its centre, and the opening in the skin itself should be thoroughly disinfected as already described (see p. 7). The trephine is then applied with the pin just at the edge of the puncture in the bone so that the circle of bone removed includes the punctured portion; when the circle of bone has been taken away, the detached fragments of the internal table must be removed. If the dura mater be injured, it will be advisable to enlarge the opening in it, because fragments of the internal table are apt to be carried on into the brain; these must be carefully sought for and removed. If possible, the opening in the dura should be closed by catgut stitches, and in most cases it is not advisable to put back the circle of bone or any portions of it. It will often be found in these cases that it is only necessary to go through the external table with the trephine, the broken-up inner table being thus at once exposed. The wound is stitched up and

a drainage tube inserted at the most dependent part; a stitch should also be put in the puncture through the scalp. In the case of gutter fractures it may be impossible to turn aside a flap, and the opening must simply be enlarged as much as may be necessary and the edges of the wound held aside. The fracture is then dealt with as described above, the trephine being applied to the side on which there is the greater depression.

*After-treatment.*—The chief danger is septic infection of the wound followed by suppuration between the skull and the dura mater, beneath the latter (*i.e.* lepto-meningitis), or in the brain itself, and also possibly by hernia cerebri. The treatment of these conditions will be considered in due course and we need only refer to them here. Their avoidance will of course depend essentially on the care with which the disinfection of the wound is carried out, and if this be successful, septic inflammation will not occur. At the same time, when the dura mater is torn, even though the wound be aseptic, a certain amount of protrusion of the brain may take place and be difficult to deal with because the wound in the soft parts probably lies directly over the rent in the dura. In aseptic cases, however, this protrusion as a rule gives rise to comparatively little trouble and diminishes as the wound contracts.

It is well to change the dressing on the day following the operation and subsequently according to the amount of discharge. The drainage tube should be removed about the fourth day, provided there be no sign of septic inflammation. The bowels should be kept open from the first and the patient should be restricted to a fluid diet without any stimulants. At the end of a few days, if there be no signs of cerebral irritation or inflammation, such as increased frequency of the pulse, persistent headache, elevation of temperature, or delirium, the diet may be cautiously increased and the patient gradually allowed to sit up and in the course of two or three weeks to get out of bed.

#### FRACTURES OF THE BASE OF THE SKULL.

Fractures of the base are generally fissured fractures, although sometimes, when the injury has been very severe, portions of the base may actually be loose and very extensively comminuted. The fissures are generally widespread both about the base of the skull and also up the sides and even towards the vault (see Fig. 11). In almost all there is considerable hæmorrhage from the torn vessels, part of which escapes externally and part of which accumulates within the skull. When the dura mater is torn, as it usually is, there is also escape of cerebro-spinal fluid from the sub-arachnoid space, and there may also be an escape of brain substance. The fractures are almost always compound in some part of their course and consequently there is a great risk of septic complications. Many open into the ear or the nose, and sub-dural abscess or suppurative lepto-meningitis may occur.

These fractures of the base are very serious injuries both on account

of the lesions already referred to and more especially on account of the septic complications; their gravity is still further increased because the fractures generally occur in the neighbourhood of important parts of the brain, and the injured parts are more or less inaccessible. The fractures, as has been already said, are not necessarily limited to a single fossa of the skull. At the same time it is usual to divide them into fractures of the anterior, middle or posterior fossa, according to the region in which the greatest damage has occurred. The line of fracture most frequently runs through the middle fossa, breaking the petrous bone at its weakest part, that is to say in the neighbourhood of the middle ear. From this point the fissure usually runs forwards and inwards across the sphenoid. In fractures of the anterior fossa the roof of the orbit is generally broken; the line of fracture may run backwards into the middle fossa. In other cases the fracture is chiefly in the posterior fossa, the fissure running downwards behind the mastoid process.

The situation of a fracture at the base of the skull depends to a great extent on the position of the original injury. Much discussion has arisen as to the way in which these fractures are caused. They usually follow falls upon the vertex or blows upon the side of the head. The original view was that in falls upon the vertex the fracture of the base occurred by transmission of the violence through the arches of the skull towards the base, or "fracture by *contre-coup*." It was however noticed that the fissures were not limited to the base, but extended up towards the vertex, and another view was suggested, viz., that fractures of the base were really direct continuations from fractures of the vault and that, when the patient fell upon the vertex, a fissure was produced which radiated downwards extensively through the base. While it is probable that fracture is thus produced in a certain number of cases, it does not satisfactorily account for the majority, and of late the elasticity of the skull has been looked on as the chief factor in its production. When the patient falls upon the top of the head, the elasticity of the skull permits a certain diminution in the vertical diameter of the head, the result being that the bone in the lateral areas near the base is bulged outwards. If the bulging be carried too far, fracture occurs at this point and fissures run thence downwards towards the base and also to a lesser extent upwards on to the vault. Thus these fractures start, not from the point of impact, but from the point of greatest bending and then run upwards and downwards. The condition is very similar to that in the ribs: when an antero-posterior force is applied to the chest, the ribs are bent until ultimately they break, and the fracture generally occurs about the angle.

The complications of fracture of the base are the same as those which accompany fracture of the vault and have been already enumerated (see p. 16). The two chief complications are compression of the brain and, more especially, septic complications owing to the communication of the fissure with the exterior.

The diagnosis can generally be made from a study of the various phenomena produced. In *fractures of the anterior fossa*, blood accumulates in the fat and connective tissue of the orbit and comes forward beneath the conjunctiva, usually showing first over its lower segment. There is almost always epistaxis, from fracture of the cribriform plate, and later on there is an escape of cerebro-spinal fluid from the nose. There is also frequently some injury to one of the ocular nerves as it emerges from the skull.

In *fractures of the middle fossa*, hæmorrhage occurs from the ear, provided that the membrana tympani be ruptured. Blood may also run down the Eustachian tube into the pharynx and may appear in the nose. The amount of blood thus lost may be considerable. It must, however, never be forgotten that an uncomplicated injury to the tympanic membrane may produce bleeding which may simulate that due to a fracture of the base; in the former case, however, the hæmorrhage is usually slight and transitory. Cerebro-spinal fluid also escapes freely from the ear, sometimes in large quantities; in the latter case there can be very little doubt about the diagnosis. The amount of cerebro-spinal fluid lost is larger in fractures of the middle fossa than in the others. When the quantity of fluid is very small it may be simply serum, or possibly fluid from the labyrinth; it may be very difficult to collect sufficient to test. The escape of brain matter from the ear may also occur in very bad fractures and in a few instances emphysema of the skin over the mastoid process has been noticed.

In *fractures through the posterior fossa*, extensive ecchymosis may occur about the mastoid process and in the neck. When the blood has escaped among the deeper cervical muscles, the ecchymosis may not show itself for several days.

**Treatment.**—There are three main points in the treatment of cases of fracture of the base of the skull. (1) To arrest the hæmorrhage; (2) to diminish the inflammatory reaction; and (3) to avoid sepsis.

**Arrest of hæmorrhage and abatement of reaction.**—With the view of attaining the first two objects, the patient should be placed in bed with the head slightly raised and fixed between sandbags, and a Leiter's coil (see Fig. 1) should be applied to the head,<sup>1</sup> the water being about 40° F. The room should be darkened and free from noise and the patient kept absolutely quiet. It is well to administer a purge immediately; five grains of calomel placed on the back of the tongue is readily swallowed and will usually produce a satisfactory action. When this does not suffice, one or two drops of croton oil on a piece of sugar or bread may be administered. The patient, who is generally in a state of shock when first seen, should be covered with warm blankets, and hot bottles should be applied to his feet and sides. The use of stimulants should be avoided, as they tend to increase the hæmorrhage. At the same time subcutaneous injections of strychnine (gr.  $\frac{1}{5}$ th) are of value if the patient be very much collapsed. In

<sup>1</sup>The head need not be shaved; if the hair be very thick it should be cut short.



fact, the treatment at this stage is that which will be presently described in speaking of the treatment of concussion of the brain (see Chap. III). Retention of urine is extremely common, and a soft catheter should always be passed soon after the injury.

Very frequently these measures are insufficient to check the hæmorrhage and the patient suffers from a state of compression due to the intra-cranial bleeding. In many of these cases it is unfortunately impossible to do much for the relief of this compression. In fractures through the anterior fossa, however, operations for the removal of the clot and for the arrest of the bleeding have been successfully performed. The operations have been chiefly successful when the bleeding has come from the middle meningeal artery, and in cases of fracture of the anterior fossa with compression, clearly due to intra-cranial hæmorrhage, it is quite justifiable to trephine with the view of clearing out the clot and if possible arresting the bleeding. The best situation for applying the trephine is in the temporal fossa just in front of the ear and just above Reid's base line (see Chap. IV.). This gives good access to the base of the skull and, by lifting up the dura mater, it may be possible to wash out the blood-clot with a gentle stream of boracic lotion or sterilised salt solution<sup>1</sup> or to turn it out with a scoop. If the bleeding comes from the middle meningeal artery that vessel can usually be secured after a little enlargement of the opening in the bone. Bleeding from sinuses however is not uncommon, and, should the blood be found to be of a venous character, the best procedure, after having removed the clot, will be to introduce strips of gauze beneath the dura mater up to the bleeding point so as to exercise pressure on it; the strips are removed at the end of about 24 hours.

**Avoidance of sepsis.**—The third great point is to guard against the occurrence of sepsis as far as possible. This is difficult as, owing to the situation of the fracture, no proper disinfection of the wound in the soft parts or the bone can be carried out; at the same time there is not necessarily as much soiling of the fractured area as there is in a compound fracture of the vertex. Hence, if the subsequent entrance of sepsis can be avoided, the patient may escape septic complications.

*In fractures of the anterior fossa*, this can be done by gently washing out the nose with warm boracic lotion so as to prevent blood-clot accumulating and undergoing putrefaction. After the irrigation, some sterilised iodoform should be blown well up the nose and, as fresh bleeding will almost certainly occur, the douching should be repeated several times daily for the first few days. No force must be used, or otherwise the fluid may be forced between the edges of the fracture; the object of the douche is not to disinfect anything, but to wash away material which might otherwise undergo decomposition. As a rule the bleeding will stop of itself, but it is well to introduce a little iodoform gauze into the anterior nares:

<sup>1</sup> This is normal saline solution (.75%) made by adding 1 drachm of common salt to the pint of water, which is then sterilised and used at about the body temperature.

this should not be pushed up to the region of the fracture but should simply plug the orifices so as to act as a sort of filter for the air and should be frequently changed.

*In fractures of the middle fossa*, the external auditory meatus may be thoroughly swabbed out with 1-2000 sublimate solution as far back as the membrana tympani, and all clots washed out of the ear with a fine-nozzled irrigator. Great care must be taken to avoid douching under pressure as the fluid cannot escape freely. Some iodoform is then blown in and the meatus is packed with iodoform gauze which should be changed and the douching repeated several times a day.

*After-treatment.*—The after-treatment is similar to that already described for fractures of the vault (see p. 26).

#### ACUTE OSTEO-MYELITIS AND PERIOSTITIS.

This disease usually follows a compound fracture in which there has been septic infection of the diploë, but it may also be due to extension from a septic scalp wound—probably from thrombosis of the veins,—from middle ear disease or even from inflammations of the skin, such as boils or carbuncles; sometimes, though very rarely, it may occur idiopathically.

The pathological characters are practically the same as those of the disease elsewhere. In the skull, however, the disease is even more dangerous than it is in the extremities, for it is especially prone to be followed by sinus phlebitis and pyæmia, by intra-cranial suppuration or by abscess in the brain, and the great majority of these cases end fatally. The affection is apt to extend rapidly over the entire bone first attacked, but it generally stops at the sutures although it may pass on to the periosteum of adjacent bones.

The disease is usually ushered in by a rigor followed by a localised swelling marked by œdema and tenderness of the soft parts over it,—a condition described by Pott in connection with injuries of the skull and named after him ‘Pott’s puffy tumour.’ Such a condition in connection with a wound of the scalp following an inflammation in the vicinity should at once arouse a suspicion of acute osteo-myelitis. When the disease occurs in connection with a compound fracture there is generally a marked diminution in the amount of the discharge, the edges of the wound become everted, the granulations are unhealthy, and the periosteum recedes from the bone and leaves it bare.

**Treatment.**—The immediate opening up of the medulla is essential, and if necessary the whole thickness of the bone must be removed; the sooner and the more thoroughly the operation is performed, the better is the patient’s chance. The opening may be effected with a large trephine applied over the inflamed area after the wound has been enlarged; a flap must be turned down when there is no wound. The trephine is carried through the outer table of the skull, which may be detached by means of

chisel and the diploë exposed without using any force. The latter should then be thoroughly gouged out wherever it is found infiltrated with pus or reddened by inflammation; should the first trephining not expose the whole of the inflamed area, as is highly probable, there should be no hesitation in enlarging it and stripping off the requisite amount of the external table, even if it involves exposure of an entire bone. After all the infected diploë has been removed, undiluted carbolic acid is applied freely to

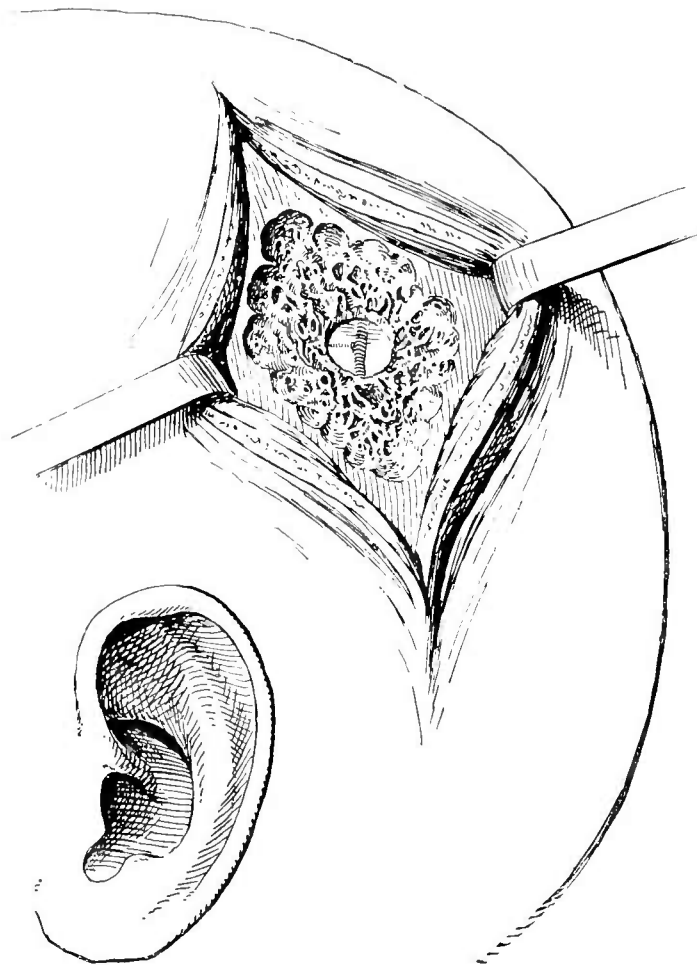


FIG. 8.—REMOVAL OF THE DIPLOË IN ACUTE OSTEO-MYELITIS OF THE SKULL. The wound has been enlarged and the soft parts fully retracted. The outer table has been cut away, partly with a trephine and partly with a gouge. The diploë has also been freely gouged away, and in the centre is seen the trephine hole through the internal table for the purpose of inspecting the condition of the dura mater.

the exposed bone surface as in a compound fracture; this is also applied to the whole wound after scraping away the granulations on the surface.

It is well at the centre of the inflammatory area to remove a circle of the inner table, taking great care not to injure the dura mater (see Fig. 8); the object of this is to see whether there is suppuration between the dura and the bone. If the former be healthy, it should not be stripped away from the bone, but the wound should be closed, after providing efficient drainage. When, however, pus is found beneath the bone, or when the dura mater is affected, the whole of the skull superficial to the affected area should be cut away with Hoffman's forceps. In bad cases the wound

may be stuffed with iodoform gauze for two or three days until it is evident whether the inflammation will pass off or not. In the former case, drainage tubes may then be introduced and the flaps brought together.

#### TUBERCULOSIS OF THE SKULL.

Tuberculous disease of the skull is not common except in connection with the mastoid and petrous portions of the temporal bone. In the vault it is comparatively rare, but it may affect any of the flat bones, most often the frontal and the parietal. In the frontal it most usually occurs in the neighbourhood of the orbital margin and of the external angular process. The disease chiefly affects young adults, and as a rule is secondary to tuberculous disease elsewhere. Indeed tuberculosis of the flat bones of the skull usually only occurs in the course of a similar severe disease in other bones. It may begin in several parts of the skull at the same time, but it usually commences at one spot, and is frequently preceded by an injury. When the case is one of multiple tuberculosis of the skull, the prognosis is very bad, and in any case the disease is very serious.

In the flat bones the disease most often commences in the diploë, either as a soft deposit or as a sequestrum. The sequestra are small, and usually involve the whole thickness of the skull, the inner table being more extensively affected than the outer. The dura is often separated from the bone over a considerable area by a mass of tuberculous material undergoing caseation. There is also a tendency to thickening of the dura mater—the condition known as tuberculous pachymeningitis. The gravity of the disease depends partly on the danger of infection of the membranes, and consequent tuberculous meningitis, and partly on various septic risks, such as pyæmia, sinus thrombosis, acute osteo-myelitis, acute meningitis or cerebral abscess.

**Symptoms.**—The disease usually commences with a dull aching pain in the head and tenderness on pressure over the affected part. The pain is presently followed by a soft swelling which very soon develops into a chronic abscess. After the abscess bursts or is opened, the bone is felt to be bare and soft, and in most cases small necrosed fragments may be found. Sometimes, however, the disease extends more towards the deeper surface of the bone, so that, after the pain has lasted for some time, symptoms of cerebral compression may arise from the collection of pus between the dura mater and the skull.

**Treatment.**—As the condition is very serious, it is important to take energetic operative measures as soon as the diagnosis has been made, for the chances of recovery without operation are small. The *operative measures* must be on the lines already laid down for the treatment of tuberculous disease of bones in general (see Part III.). The affected area should be freely exposed, either by a large flap going wide of the diseased region in cases where there is no external opening, or by excision of any tuber-

culous ulcer present and sufficient enlargement of the wound. The periosteum over the diseased area should not be turned down with the flap, but must be left *in situ* and removed with the bone: all caseating material or granulation tissue between the scalp and the bone should be carefully dissected away. The whole area of the skull affected should then be cut away, either with a trephine or by any other suitable means, and it is well in the majority of cases to remove the whole thickness of the bone and expose the dura mater. This should be done even though large portions may require removal, as otherwise the risk of extension of the tuberculous disease remains. When the dura mater is healthy it should not be opened. The raw surface left should be carefully cleaned, the bone surfaces touched with undiluted carbolic acid and the wound closed.

The dura, if affected, should be cut away, and any commencing disease in the underlying membranes should be removed. The removal of the dura causes a certain risk of hernia cerebri, but, if the wound be aseptic, this can generally be prevented, while the removal of the tuberculous disease is of paramount importance. The treatment, prophylactic and otherwise, of hernia cerebri will be subsequently described (see p. 71), but when there is no external wound it is well, with the view of obviating the risks of hernia, to turn down an exceptionally large flap of skin so as to carry the line of incision in the skin to a considerable distance from the opening in the bone, so that if the brain does protrude, the hernia will be prevented from increasing to any great extent by the pressure of the flap.

When tuberculous disease affects the base of the skull, more especially the mastoid region, the removal of the tuberculous tissue cannot as a rule be so complete. When the disease occurs in the usual situation, namely, in the petrous portion of the temporal bone, it manifests itself as a middle ear affection with discharge from the ear, usually foul and caseous, and with subsequent disease of the antrum and all the consequences which, with their appropriate treatment, will be referred to later. The treatment consists in opening up the antrum and the tympanic cavity freely and removing sufficient bone to give free access to the interior. The tuberculous material is then cleared away with a flushing gouge and any carious bone within reach is freely taken away. A very considerable area of bone may be removed safely if the surgeon bears in mind the anatomical relations of the part, more especially the situation of the lateral sinus and of the facial nerve. In these tuberculous cases the cavity left in the bone should be packed with iodoform gauze, and it is always well to lay the antrum and the tympanic cavity into free communication with the external meatus so that one large cavity is left (see p. 61).

## SYPHILIS OF THE SKULL.

*In the secondary stage* of syphilis, periosteal nodes are not uncommon. They are chiefly found over the frontal bone and usually affect the external surface. A condition of syphilitic periostitis may also be met with in the interior, most frequently perhaps about the foramina through which the various cranial nerves issue from the skull, the resulting pressure leading to paralysis of the nerves involved.

**Treatment.**—The treatment in the secondary stage is practically the same as that for secondary bone lesions elsewhere, *i.e.* a mercurial course both internally and locally, with, towards the later period of the secondary stage, the administration of iodide of potassium in addition (see Part III., p. 203).

*In the tertiary stage*, the skull is one of the favourite seats of syphilitic bone disease and it may occur either in the form of a chronic osteitis or of gummatous disease, the latter frequently resulting in necrosis. In most cases, indeed, the two processes are combined, the original trouble being the formation of a gumma in the periosteum or the diploë with subsequent osteitis around. Gummatous disease of the bones most often affects the frontal bone, and the condition used to be spoken of as “*corona veneris*.” The whole thickness of the bone or only the external surface may be affected, and the gummata are usually multiple. Very soon the gummatous infiltration spreads to the soft tissues, which ultimately give way and lead to characteristic tertiary syphilitic ulcers with dead bone at the bottom. Gummatous disease of the skull may be very serious on account of the risk of various complications, such as erysipelas, sinus thrombosis, septic meningitis, etc.

**Treatment.**—In the earlier stages, the treatment will be that appropriate for tertiary bone lesions elsewhere (see Part III., p. 204), namely the administration of large doses of iodide of potassium combined with mercury, and, when ulceration is present, the local application of mercurial ointment or, if that be not deemed necessary, of some antiseptic ointment such as boracic acid. When there is necrosis of the skull, however, the question of operative treatment may arise, for in a considerable number of instances large doses of iodide of potassium employed for a long time may produce very little amelioration of the symptoms, and the necrosed fragment may remain adherent to the living bone for a lengthened period. It may therefore become advisable to remove the necrosed fragment with portions of the thickened bone in the vicinity, so as to leave a fairly healthy wound which will heal readily under the anti-syphilitic remedies.

*Sequestrotomy.*—The removal of the sequestrum is usually fairly easily effected as follows. In all the cases there is an ulcer which must be dealt with first. The scalp should be thoroughly purified in the usual manner, and it is well to scrape the ulcer and pare away its margins; after arresting the bleeding, the raw surface is impregnated with undiluted carbolic

acid, for it is very important to obtain a wound as aseptic as possible. The opening is then enlarged in any direction that may seem most suitable, the flaps are turned aside and the diseased area is exposed. The simplest plan is to apply a trephine larger than the necrotic area and to saw through the outer table of the skull. Very frequently the sequestrum does not go deeper than this and in that case it is advisable not to interfere with the internal table. After the trephine has been made to divide about half the thickness of the skull, the whole necrotic area may be gently chipped away with a chisel and hammer. Should the disease be found to extend deeper, the trephine can be re-applied and the remaining portion of the circle of bone removed. The bone is often very dense and difficult to cut through and, should the opening not be sufficient, it is not at all easy to enlarge it with cutting forceps; it will generally be necessary to make additional trephine openings. Great care should be taken not to injure the dura mater, because of the danger of septic meningitis. Therefore, unless any important symptom calls for it, the dura should not be opened. The cut surfaces of bone left should be sponged with undiluted carbolic acid.

As these operations are usually undertaken in cases of open wounds, it is not easy to close the wound again, and usually it must be packed with iodoform gauze. This is probably the best treatment when the internal table has not been removed, and it should be continued until the whole wound is covered with healthy granulations. Then skin-grafting should be employed (see Part I., p. 50) otherwise there may be great delay in the healing of the wound owing to the difficulty of contraction.

When however the whole thickness of the bone has been cut through and the dura has been exposed, it is better to attempt to close in the exposed dura mater at once by some form of plastic operation. In some cases the edges can be brought together by loosening the scalp freely. In others it may be necessary to make a curved incision outwards and downwards from one angle of the wound so as to allow a portion of the scalp to be turned in over the wound (see Part I., p. 179). With this treatment the patient is much more likely to recover and to escape complications than when medicinal treatment alone is adopted.

The syphilitic bone diseases of infancy and childhood do not call for special mention. The treatment is that of congenital syphilis (see Part III., p. 205), and, so long as the skin has not ulcerated, it will in most cases suffice to employ the ordinary anti-syphilitic treatment.

#### CRANIO-TABES.

Very little need be said about congenital defects in the skull because there is practically nothing to be done for them. In some cases there may be so much atrophy of the skull as actually to lead to the formation of perforations in the bone. This condition is common in the skulls of aged people and cannot be averted.

Cranio-tabes is a localised thinning of the skull in infants which is essentially due to rickets. By some authorities it has been ascribed to congenital syphilis, but it seems probable that rickets is the chief factor in its production. The condition of cranio-tabes shows itself either by imperfect ossification of the skull or by subsequent malformations of portions of the cranium in which ossification has already taken place. The result is that the cranial bones become thickened in some parts, while in others, especially where they are subject to pressure, they become extremely thin and openings through the bone may actually form. The condition is most marked over the parietal and occipital bones where the head is subject to pressure, the result being that the skull is usually flattened posteriorly. Along with cranio-tabes, signs of rickets may be found in the bony skeleton elsewhere, and also various nervous symptoms, such as laryngismus stridulus, which are characteristic of the ricketty condition and which may in part be ascribed to actual irritation of the cerebral cortex by pressure.

**Treatment.**—The treatment of this condition is the treatment of rickets (see Part III., Chap. XIII.). When an infant shows a tendency to rickets, care should be taken that its position is frequently changed, so that there is no prolonged pressure on any individual cranial area; if the bone has actually become thinned, some arrangement, such as a celluloid or aluminium shield, or a ring-pad, must be devised to take off pressure altogether.

#### LEONTIASIS OSSIUM.

This condition is the reverse of the preceding one; in it the bone is immensely thickened from causes which are not definitely determined. A somewhat similar condition of hypertrophy of the skull may also occur in osteitis deformans, but we need say no more about it here as there is practically no treatment for it (see Part III., p. 217).

Leontiasis ossium consists of thickening of the bones of the skull, which are much distorted in appearance owing to the presence of local osseous deposits. It sometimes gives rise to a sort of leonine aspect, hence the name, Leontiasis. These new-formed bosses of bone may occur on the cranial bones or in connection with the jaws,—especially the upper; they give rise to remarkable deformities and to various pressure symptoms. For example, when the bosses are on the upper jaw or the frontal bone, the pressure is very apt to be exerted in the orbit and this may lead to loss of sight. When the vertex is affected, the pressure may cause various brain symptoms.

**Treatment.**—The disease is very slow in its progress and we know of no means of checking it. In some cases however surgery may be of value for the relief of the pressure symptoms. For example, when a tumour is growing towards the orbit and interferes with vision, or when it presses on the brain, the removal of the particular boss of bone is indicated.



At the same time it must be remembered that the operation is a purely temporary expedient; it is merely employed to relieve the symptoms, and does not in any way lead to a cure of the disease.

#### NEW GROWTHS OF THE SKULL.

Tumours of the various types which are met with in other bones occur in connection with the skull.

**EXOSTOSES.**—Among the commonest tumours of the skull are probably exostoses, of the hard or ivory form. They occur chiefly on the

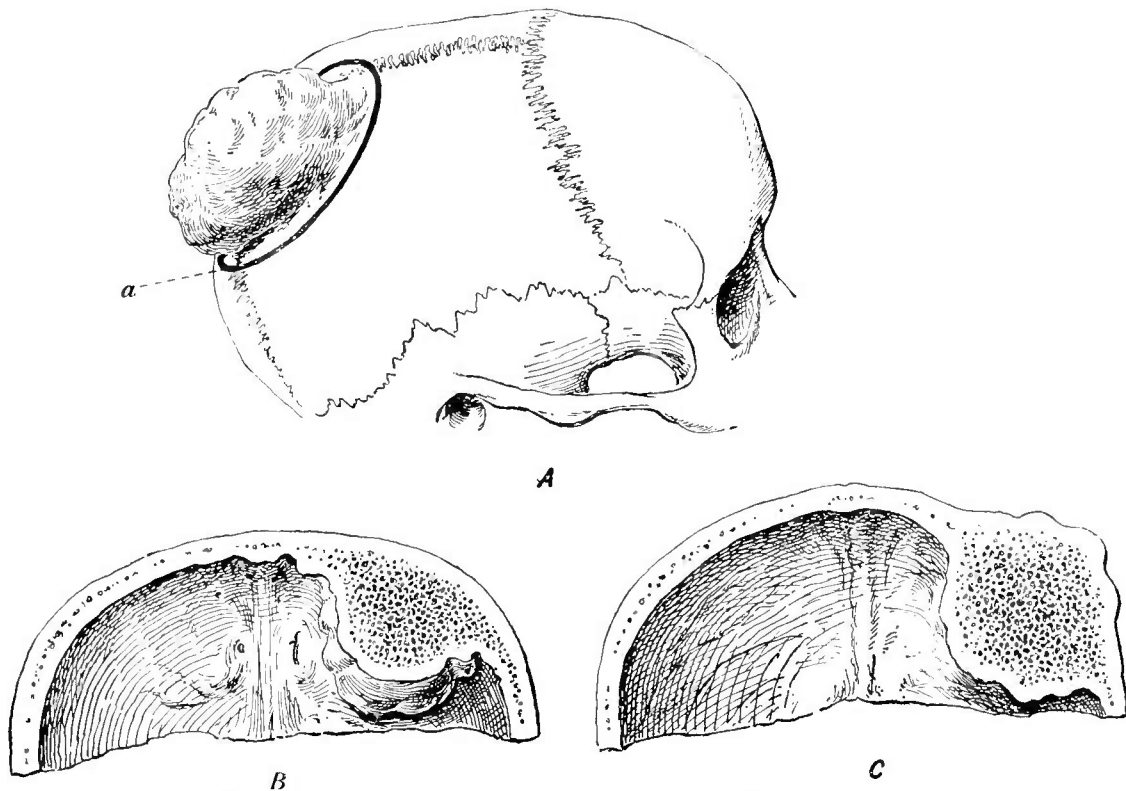


FIG. 9.—EXOSTOSES OF THE SKULL. *A* shows the ordinary form of the ivory exostosis affecting the outer table only; the thick black line *a* represents the incision in the skull necessary for its removal. This may be made with a gouge, a parting tool, or a circular saw. If the growth be small enough, the circle may be made with a trephine. *B* is the same form of growth springing from the inner table, while in *C* the growth (usually spongy) affects the entire thickness of the bone.

frontal bone, or in the bony auditory meatus. Usually they grow from the external table of the bone and do not give rise to any symptoms; sometimes, however, they may arise in the neighbourhood of the orbit and may cause serious pressure on the optic nerve. If the exostosis be in the external auditory meatus, the latter may be blocked and hearing seriously interfered with.

**Treatment.**—These ivory exostoses grow very slowly, and, as a rule, unless they are causing deformity or pressure symptoms, they need not be interfered with. Their removal is very difficult and not altogether free from risk owing to the extreme density of the growth. Any attempt to chisel away the mass—as is done in spongy exostosis—requires a force that may cause serious jarring of the brain and possibly also fracture of the skull.

When the exostosis is quite small and can be enclosed in the circle of a trephine, a circle of the bone including the exostosis should be taken out. When however the tumour is large and irregular in shape, the best plan is to

remove it by means of a burr, or a saw worked by a dental engine, keeping just outside the area of the tumour so as not to have to cut through the very dense bone (see Fig. 9).



FIG. 10.—GIGLI'S SAW. The saw is a finely tempered wire with a low screw-thread round it. This is introduced (by a special introducer if necessary) between the dura and the bone between two trephine holes. The handles are then hooked on and the bone is rapidly divided. It is a most useful saw for many purposes, as its fineness enables it to be passed where others will not go. See also Part I L, p. 22.

**SARCOMATA.**—These tumours are rarely removable, but in some cases, when they have originated in the interior of the bone, it may be worth while attempting an operation. Under such circumstances a large flap of skin only, avoiding the deep fascia, must be turned down well beyond the area of the tumour, and by means of a circular saw, or a Gigli's saw (see Fig. 10), the skull is cut through at a distance of about an inch beyond the growth and the whole mass removed with the tumour attached. When the tumour is growing from the diploë or the external table, this operation may be successful, and even when the inner table is depressed by the growth it is worth trying, provided that the operation be done before serious pressure on the brain has been caused, and before the dura mater has become involved.

When however the skin over the tumour is so thinned or infiltrated that it has to be removed, the operation cannot be performed, because a large gap would be left with the brain exposed and without any likelihood of healing. No doubt in some cases, when the defect is small, it might be possible to fill it by means of a flap from the arm, as in the method of repairing the nose (see "Plastic Surgery of the Face"), but when the tumour has attained such a size as to involve the skin to any considerable extent, its removal is practically hopeless.

**CARCINOMATA.**—Carcinomata found on the skull are of course secondary to carcinomata elsewhere and cannot be dealt with surgically.

## CHAPTER III.

### INTRA-CRANIAL INJURIES.

THE effect of a severe injury to the head is not limited to the scalp or the skull but is also exerted on the contents of the cranium; various intracranial affections may arise according to the force, the situation and the nature of the injury, and especially according to whether or not there is a simple or a compound fracture of the skull. The chief of these intracranial affections are, concussion, contusion or laceration of the brain, compression of the brain from various causes, of which the chief is intracranial hæmorrhage, and various inflammatory phenomena, such as extra-dural, sub-dural or cerebral abscess, lepto-meningitis, phlebitis and thrombosis of the sinuses.

#### CONCUSSION OF THE BRAIN.

By concussion of the brain is meant a state of unconsciousness into which a patient falls after a severe injury and before enough hæmorrhage has taken place to cause symptoms of compression. Concussion of the brain is, in fact, practically a condition of shock resulting from disturbance of the nervous centres. There has been much discussion as to what happens in concussion of the brain. The original idea was that an alteration took place in the functions of the brain without any actual lesion, but much dispute has arisen as to the possibility of this. It has been found that in patients who have died during the stage of concussion there has always been more or less hæmorrhage into the substance of the brain, and in some cases distinct laceration has existed; some authors have therefore asserted that in all cases of concussion there is an actual lesion of the brain. On the other hand, it certainly seems reasonable to suppose that when force is applied to the head the semi-fluid brain and the cerebrospinal fluid would be forcibly thrown into commotion and that, as the result of these violent oscillations of the brain substance, temporary disturbance, ending in more or less complete suspension of function of the

brain cells, may result without there being necessarily any actual lesion. The amount of cerebro-spinal fluid present in the skull at the time of the injury apparently should have a considerable determining effect on the lesions that occur. According to Bouchard, if a blow be received during inspiration, when the brain is more or less completely surrounded by cerebro-spinal fluid, the condition of concussion would be produced, whereas if it were received during expiration, when there is less cerebro-spinal fluid in the cranial cavity, the protection of the water-bed would be diminished and the more serious condition of contusion would result.

**Symptoms.**—The symptoms resulting from this disturbance of the brain vary in degree from drowsiness to complete unconsciousness. In bad cases the respiration is very faint, the pulse is hard to feel and often unduly slow, and there are noises in the head, disturbances of vision, etc. The stage of concussion however does not last long. In the course of a time varying from a few minutes to three or four hours the pulse improves in volume, the respirations become deeper, the reflexes return and the patient begins to recover. Generally during recovery the patient vomits and may wander a little. In severe cases there is complete prostration; the surface of the body is cold, the breathing is shallow and quick, the pulse very feeble and there is frequent vomiting. Recovery in these cases is often accompanied by symptoms of cerebral congestion.

**Treatment.**—In the treatment of a patient in a state of concussion two things must be borne in mind. In the first place measures must be taken to get rid of the shock, while in the second place, great care must be taken to avoid bringing about too much reaction lest hæmorrhage should occur. The patient should be placed in the recumbent position, with a very small pillow beneath the head, which must not be too much depressed on account of the risk of increasing any hæmorrhage that may have begun. Warmth should be applied to the feet and limbs by means of hot blankets and hot-water bottles. Strychnine (gr.  $\frac{1}{5}$ th) may be administered subcutaneously and also camphor, and in bad cases it may be advisable to put the patient into a warm bath. The administration of alcoholic stimulants, or of ether should be avoided in all but desperate cases, on account of the great risk of increasing the reaction and bringing about internal hæmorrhage. The patient should be placed in a room free from noises and bystanders and a brisk purge should be administered while he is still unconscious (five grains of calomel placed on the back of the tongue or one or two drops of croton oil on sugar). In most cases of concussion there is retention of urine, especially during the stage of recovery, and this must be remembered and the urine drawn off with a soft catheter. Most cases of concussion will recover under this treatment; if recovery is possible, they will even recover without any special treatment at all.

When reaction begins to set in, it is well to cut the hair close and *to apply cold to the head* with the view of arresting any hæmorrhage. The patient should be kept in a dark room, should not be allowed to see

visitors or to talk, and an ice-bag, ice-cap or Leiter's tubes (see Fig. 1) should be applied to the head. The confinement to bed should be maintained for about a week, because up to that time it is impossible to be certain that hæmorrhage will not occur. During this time the cold should be kept applied to the head, the patient kept quiet, the bowels kept freely open by the daily administration of a saline purge, while the diet should consist of milk and should be restricted in quantity. From a pint and a half to two pints of milk daily will suffice in the first instance, and this may be gradually increased as the patient improves. As a rule at the end of a week the patient may be allowed to begin to get about and the chances of subsequent trouble are comparatively small.

#### CONTUSION AND LACERATION OF THE BRAIN.

In some cases the laceration of the brain of which we have spoken in connection with concussion is very marked, and this may occur with or without fracture of the skull itself. The injury to the brain may be just beneath the seat of the blow, or it may be on the opposite side of the skull ("*contre coup*"), and it may vary from a small tear to an extensive laceration of the cortex. The lacerations are most frequent about the convexity of the hemispheres, but they are also met with at the base when the brain has been violently jarred against the bony prominences there.

**Symptoms.**—The symptoms peculiar to severe lacerations are chiefly those of irritation of the brain. The patient, after recovering from the primary shock or concussion, shows symptoms of irritation of the cerebral cortex, such as irritability of temper, muscular twitchings, irregular movements, extreme restlessness, etc.; the occurrence of these symptoms soon after an accident always leads to the conclusion that the brain matter itself has probably been damaged.

**Treatment.**—The treatment of this condition is the same as that just described for concussion. In the first instance the concussion symptoms must be treated, and then great care must be taken during recovery to avoid excessive reaction and to diminish the risk of hæmorrhage into the brain. There is no special treatment required for the contusion of the brain substance. The patient must be kept quite free from all disturbing influences, and in a good many cases the irritable condition gradually passes off and the patient recovers completely.

#### COMPRESSION OF THE BRAIN.

After the symptoms of concussion have passed off, the patient may either continue well or he may again lapse into unconsciousness, from which it may be impossible to arouse him. This unconsciousness is due to compression of the brain, which may arise from various causes. Compression coming on a few hours after the injury is in all probability

due to intra-cranial hæmorrhage. When there is no reaction at all, the compression may be due to a depressed fracture (see p. 18), and is usually increased by some intra-cranial hæmorrhage. Again, the symptoms of compression may supervene at a later period, and are then probably due to cerebral inflammation and abscess. The diagnosis and appropriate treatment of these conditions are dealt with in Chapter IV.

*The general symptoms of compression of the brain* are profound loss of consciousness, stertorous breathing, slow pulse and unequal pupils, the one on the side of the effusion being usually widely dilated and fixed. If the pressure be not relieved, the patient may remain unconscious for some hours and then gradually die from heart failure. We shall here take compression due to intra-cranial hæmorrhage.

**INTRA-CRANIAL HÆMORRHAGE.**—This may be either extra-dural or intra-dural; an intra-dural hæmorrhage again may be meningeal, that is to say beneath the dura or into the pia mater, or actually into the substance of the brain. When the hæmorrhage occurs rapidly after an injury and in such amount as to give rise to marked compression, it is probably extra-dural and most frequently results from rupture of the middle meningeal artery or one of its branches. The next most frequent cause of compression due to intra-cranial hæmorrhage is probably rupture of one of the vessels of the pia mater; another is rupture of one of the large venous sinuses in the brain; in the latter case the symptoms are more gradual in onset, partly because the bleeding is slower and partly also because this condition is usually associated with fracture and the blood escapes under the scalp.

**Rupture of the middle meningeal artery.**—The middle meningeal artery is the largest branch of the internal maxillary trunk and enters the skull through the foramen spinosum, running upwards in a groove in the greater wing of the sphenoid. About one centimeter above the foramen it divides into an anterior and a posterior branch, of which the anterior is the larger and runs on in a groove across the greater wing of the sphenoid and thence across the anterior inferior angle of the parietal. It is then continued upwards almost parallel with the anterior border of the bone. It sends branches forwards and backwards over the frontal and parietal bones. The posterior branch passes more directly backwards over the squamous portion of the temporal bone and turns upwards near the posterior inferior angle of the parietal, running just in front of the posterior border of the bone. It extends towards the middle line and its branches run as far back as the lateral sinus. Throughout their whole extent both branches of the artery lie in grooves in the bone, converted into channels by the dura, and are much more adherent to the latter than to the bone. The anterior branch is the one usually torn.

The main branches of this vessel are in close relationship with various motor areas of the cortex, and thus hæmorrhage from them may cause direct pressure upon these areas and give rise to paralysis, which varies

according to the seat of the rupture and the extent of the hæmorrhage. It is very necessary to know the external surface markings which will enable the artery and its branches to be mapped out upon the scalp. The following are the chief landmarks: the anterior branch of the middle meningeal is situated about an inch and a half behind the external angular process of the frontal bone and about the same distance above

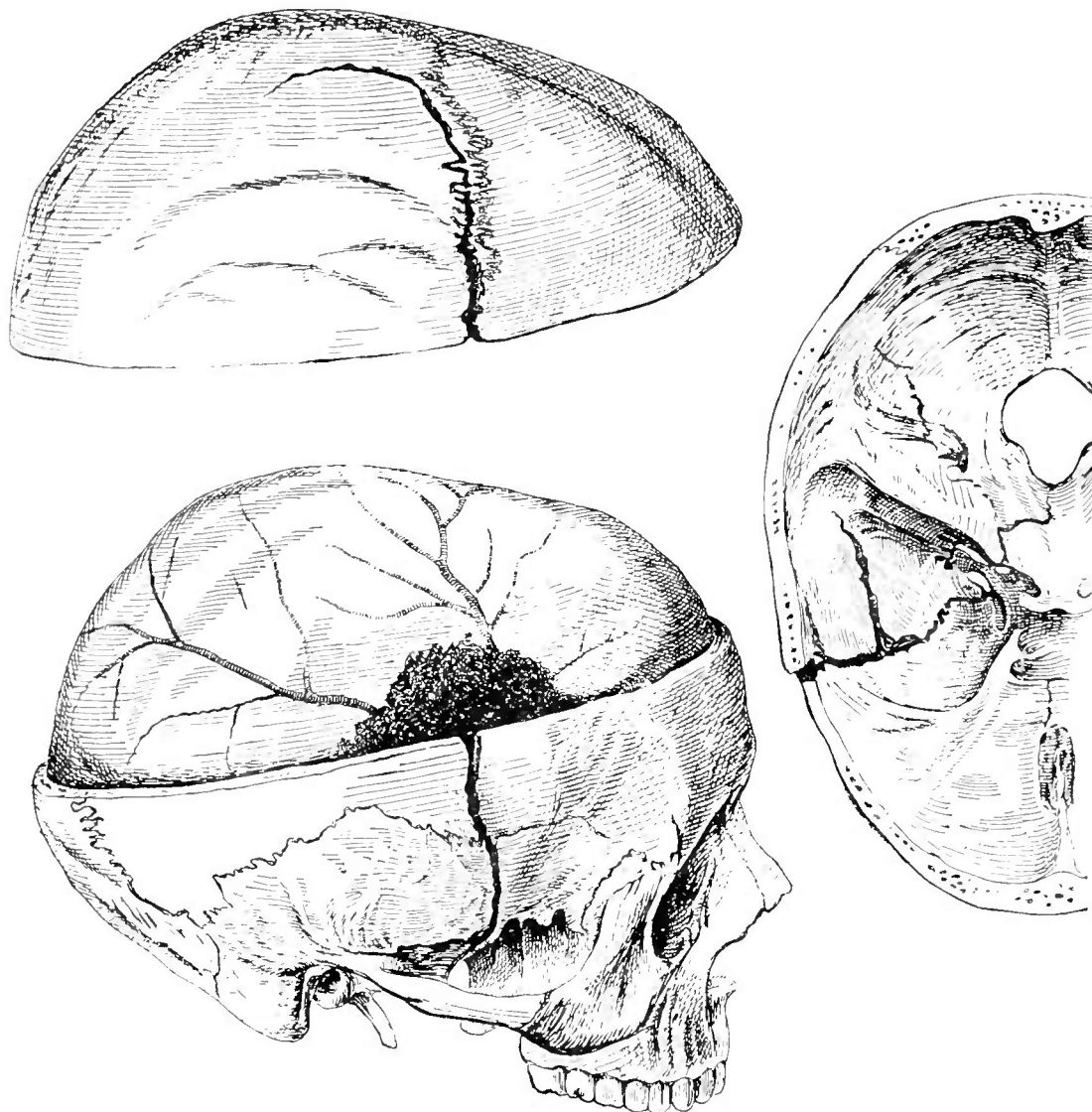


FIG. 11.—MIDDLE MENINGEAL HÆMORRHAGE. The fracture is seen to traverse both the vault and the base of the skull. The situation of the clot is the one usually met with. (*Helpferich.*)

the zygomatic process. Another method given is to draw a line from the middle of the glabella<sup>1</sup> to the apex of the mastoid process and at the mid-point of this line to draw another at right angles to it; the point where this line crosses one drawn from the glabella to the external occipital protuberance will indicate the position of the artery (see Fig. 23). The posterior branch crosses the posterior inferior angle of the parietal at a spot corresponding to the point of intersection of a base line drawn

<sup>1</sup>The glabella is the smooth space directly above the root of the nose, midway between the two superciliary ridges.

from the glabella backwards to the external occipital protuberance and another drawn at right angles to this slightly behind the tip of the mastoid process.

Rupture of the middle meningeal artery generally occurs in connection with a fracture of the vault or the base of the skull, the line of fracture traversing the groove in which the artery lies (see Fig. 11) or crossing the foramen spinosum itself and tearing the vessel. Rupture of the artery may however occur without any fracture and is then probably due to forcible detachment of the vessel from its groove in the bone due to the alteration in the shape of the skull resulting from the sudden application of violence, the artery being torn in the process of detachment. Hæmorrhage of this kind without fracture occurs most commonly in adults, probably because in children the dura mater is more closely adherent to the bone and therefore less easily separated from it when the skull is compressed.

The blood from the torn vessel is poured out between the dura mater and the skull and rapidly detaches the former from the bone. This blood soon clots and, according to the amount of clot, pressure is exercised upon the subjacent brain. The amount of clot may be twelve ounces or more and this will of course give rise to very serious compression of the brain. When the amount of clot is small, the effects of the pressure are manifested in one hemisphere only, the paralysis resulting from the pressure upon the motor areas being unilateral and possibly limited to particular centres. As the clot increases in size, however, the entire hemisphere shows the effect of pressure and in extensive hæmorrhages the opposite hemisphere is affected as well. As a rule the tendency of the blood is to spread downwards towards the base of the skull, and one of the typical symptoms, namely, dilatation of the pupil on the affected side, is probably due to clot passing downwards and pressing upon the third nerve. Should the rupture of the artery be accompanied by fracture of the skull, some of the blood escapes beneath the scalp and may form a distinct hæmatoma. Should the fracture be compound, there may be free escape of the blood externally, in which case the pressure symptoms may be absent or very slight.

**Symptoms.**—When hæmorrhage from the middle meningeal artery follows a fracture of the skull there is usually a history of temporary concussion followed by reaction and a lucid interval. This lucid interval varies from a few minutes to a few hours, and then occurs gradually increasing drowsiness, finally ending in coma. The duration of the lucid interval, and indeed its existence, depends of course on the rapidity with which the blood is poured out and also on whether there is a laceration of the brain accompanying the injury. When the hæmorrhage occurs rapidly or when there is also laceration of the brain, the patient may not have rallied from the primary shock before the amount of blood poured out has become so great as to produce compression.

When the compression is complete, the patient lies in a comatose con-



dition characterised by a slow and usually full pulse, by slow and often stertorous respiration, with dilated and fixed pupils, the dilatation being most marked and sometimes indeed only present on the side of the hæmorrhage. Other symptoms are paralysis, which varies with the position of the clot and is due to pressure on the motor areas of the cortex. In some cases there may be spastic contractions of various muscles with twitchings or even epileptiform convulsions; when these occur, some laceration of the brain substance is generally also present. Following this period of irritation there will be paralysis if the clot be over one of the motor centres, limited at first to that centre but extending later and perhaps involving the whole body.

**Prognosis.**—The prognosis of intra-cranial hæmorrhage is bad: unless operative measures be adopted it is hopeless. The case, if left to itself, usually ends fatally within a few hours from the intra-cranial pressure; in the few cases that have recovered the patient has generally been left in a state of mental or physical disability, or subject to epileptiform convulsions. Hence the earlier the hæmorrhage is arrested and the clot removed the better, for, even though the compression may be relieved and the patient's life saved by operation at a later period, the brain will probably be unable to expand, or fatal œdema of the brain may result.

**Treatment.**—The head should be entirely shaved, and the scalp scrupulously purified (see p. 7). When the patient is comatose, no anæsthetic is necessary: chloroform should be chosen in preference to ether when one is required as it causes less cerebral congestion. Even where an anæsthetic is employed it is only required for the skin incision as a rule, an occasional whiff being all that is necessary afterwards. The head is turned to the opposite side and steadied on a sandbag.

Unless the symptoms or the situation of the fracture point to rupture of the posterior branch of the middle meningeal, the anterior division should first be exposed. This is most conveniently found about an inch and a half behind and about the same distance above the external angular process of the frontal bone. A large semilunar flap with its convexity upwards should be rapidly turned down with its centre opposite this spot, the pericranium, the temporal fascia and the temporal muscle being carried down with the flap. The bleeding vessels are seized with pressure forceps and usually will not require ligature; the weight of the forceps keeps the flap out of the way. A fissure should be looked for, and if found the trephine should be applied over it, the pin being inserted just to one side of it, about an inch above the level of the zygomatic process. Usually the presence of a fissure is indicated as soon as the flap is turned down by extravasation of blood into the temporal muscle. It is always best to trephine over the fracture first, because the blood may come from one of the smaller twigs and not from the main branch. When no fissure can be seen, the pin of the trephine should be applied over the anterior inferior angle of the parietal bone. The trephine should have a conical crown so that it cannot slip into the cranial

cavity after the bone has been divided (see Fig. 7). It should be remembered that in this situation the bone is usually very thin; if, however, the diagnosis be correct, there will be little risk to the dura, which is widely separated from the bone by the clot. The operation of trephining has been already fully described (see p. 22). The circle of bone removed should be placed temporarily beneath the scalp (see p. 24) in case it should be required afterwards.

As a rule the clot is at once exposed and bulges into the opening, but

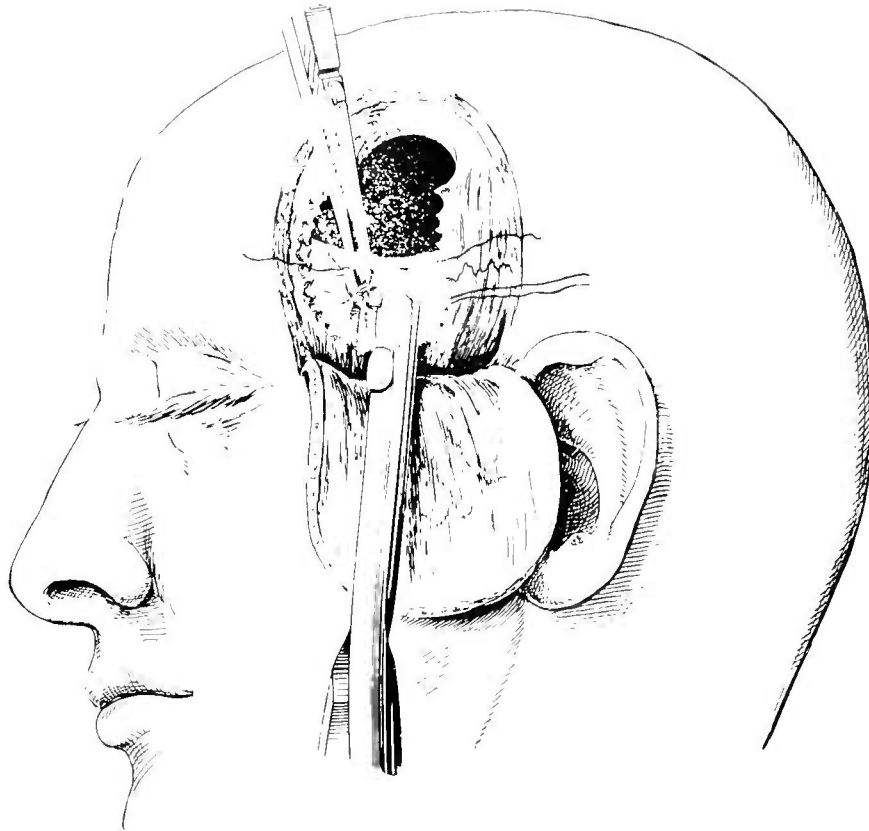


FIG. 12.—METHOD OF SECURING A RUPTURED MIDDLE MENINGEAL ARTERY IN THE DURA MATER. The trephine hole is seen above exposing the clot. The bone has been rapidly removed in the downward direction by Hoffman's forceps and the bleeding point thus exposed. This is seized in catch forceps and the vessel under-run above and below. The upper thread is seen in place, the lower one is being inserted.

does not usually pulsate: should it do so, it generally means that free hæmorrhage is going on, the pulsation being communicated not from the brain but from the open end of the torn artery. The clot should now be gently removed with a blunt scoop or an egg-spoon, and any debris can be flushed out with a weak solution of sublimate (1-8000) at about the body temperature. Care should be taken that the irrigation is not applied under pressure, as otherwise it might detach the dura still further: the escape of the fluid must be perfectly free. Should the torn vessel not be sufficiently exposed—which usually means that the rupture is lower down—portions of the skull should be rapidly cut away downwards in the cours

of the vessel with Hoffman's forceps. In the meantime, should the bleeding be free, it may be temporarily arrested by thrusting the finger between the dura and the bone in the direction from which the blood comes, while the skull is being cut away with the forceps. Except when the vessel is torn very low down, it is generally easy to get at it by the removal of sufficient bone. It is, however, often extremely difficult to apply a ligature to the vessel, as it lies on the dura mater deep down in the wound, and the best plan is to under-run the vessel on each side of the rent, using a fully-curved Hagedorn needle threaded with fine catgut, the needle being passed through the dura mater beneath the vessel and the ligature tied over it (see Fig. 12).

Should the vessel be injured at a point where it is not quite free from the groove in the bone it can usually be easily detached with a probe or, if necessary, more bone may be removed. In some cases the groove in the parietal bone has been converted into a canal, which may be continued upwards for some distance from the foramen spinosum, and it may then be necessary to chip the bone away gradually until the bleeding



FIG. 13.—THE "PARTING TOOL" FOR OPERATIONS UPON THE SKULL. By means of this instrument a groove or furrow can be very quickly cut in the bone. The cross section of the cutting edge is seen in *S*.

point is exposed. This should be done either with a sharp gouge or with a parting tool (see Fig. 13), the advantage of the gouge being that a hammer is not required; the jarring caused by the hammer is apt to be prejudicial. When the parting tool is used—and this is sometimes more convenient—the hammer must be used very gently. These measures are successful in most cases, but, if the artery be lying far down in the canal, the best plan is to pack in a quantity of Horsley's wax,<sup>1</sup> forcing it down the canal with a plug of gauze and a probe. It is only extremely rarely that such a measure as ligature of the carotid will be required.

Should the anterior branch of the middle meningeal artery be intact, the posterior division should be exposed before completing the operation, and this is done, as has been said, at the point of intersection of a line passing from the external angular process of the orbit backwards to the occipital protuberance with one running vertically upwards from the posterior margin of the mastoid process. The steps of the operation are practically similar to those just described.

<sup>1</sup>This is a mixture of beeswax 7 parts, almond oil 1 part, and salicylic acid 1 part. It should be kept under 1 in 20 carbolic solution in a wide-mouthed stoppered jar and made ready for use by pinching off a fragment of suitable size and softening it by kneading with the fingers. It is left *in situ*.

After the clot has been removed and the artery secured, the next questions that arise are whether drainage shall be employed and whether the portions of the bone removed shall be replaced. The answers depend practically entirely on the expansion of the brain that follows removal of the clot. When the bleeding has quite ceased and the brain expands fully, so that the dura mater is again everywhere in contact with the bone, there is no need of drainage, and the portions of bone removed may be put back in place either as one large circle or in several small pieces. When, however, the brain does not expand at once, a cavity is left between the dura and the skull, into which oozing will take place and a clot may again form and again cause pressure; under these circumstances, therefore, it is advisable to insert a drainage tube, so as to allow of the escape of the fluid blood. Further, when the brain does not expand properly, it is of course out of the question to replace the bone removed by the trephine. When a drainage tube is employed, its end should lie over the hole in the skull, and it may generally be removed in two or three days. After the wound has been stitched up with a continuous suture the ordinary antiseptic dressings are applied and the patient put back to bed, propped up in the semi-recumbent position, and kept upon an entirely fluid diet.

**Sub-dural hæmorrhage.**—In the operation just described the dura mater is not opened, the entire procedure being extra-dural. In some cases, however, it is found after exposing the dura mater that there is no blood between the membrane and the bone, but that the dura bulges outwards into the wound, shows the presence of dark bluish-black clot beneath it and does not pulsate. It is then clear that hæmorrhage has occurred into sub-dural space either from the middle meningeal branches, the dura mater being torn and allowing the blood to escape inwards, or from the vessels of the pia mater. Under these circumstances the dura must be opened in order to remove the clot and secure the bleeding vessels. It is well to employ a curved incision in the dura so as to turn aside a semi-circular flap of the membrane with its convexity downwards; this takes the line of incision as far away as possible from that in the skin. The incision should run about a quarter of an inch from the margin of the bone, and should be made first with a sharp knife, and then with a blunt-pointed pair of scissors, such as are used in eye operations. This exposes the clot (see Fig. 14), which is removed in the manner above described; the bleeding vessel is secured either by picking it up in forceps or by under-running. The wound in the dura is stitched up again, and no drainage need be employed if the brain expands properly during the operation. In stitching up the dura, however, it is well not to use a continuous suture; it is better to put in a few interrupted stitches, leaving intervals between them through which blood and serum may escape outwards. If the brain does not expand properly, a fine horsehair drain should be introduced beneath the dura and brought out at one corner of the flap. This is kept in position for two or three days.

**Hæmorrhage from the vessels of the pia mater.**—In some cases the pia mater may be lacerated and hæmorrhage then takes place upon the surface of the brain, into its substance or between the convolutions. Usually a force sufficient to tear the pia mater also lacerates the brain, so that the case is one of laceration of the brain with hæmorrhage on the surface, and consequently the symptoms are those of concussion and laceration of the brain followed afterwards by slight symptoms of compression. The compression symptoms are not so severe as those produced by hæmorrhage from an artery such as the middle meningeal and they are more localised owing to the damage being confined to a portion of the cortex.

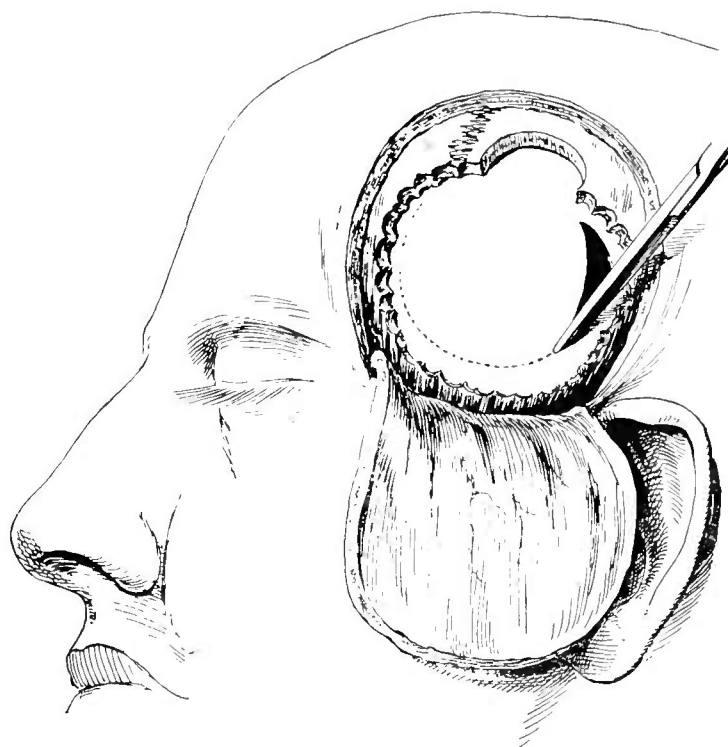


FIG. 14.—INCISION OF THE DURA MATER FOR SUB-DURAL HÆMORRHAGE. A small nick is first made in the dura with a knife and one blade of a pair of fine blunt-pointed scissors is inserted in it. The figure shows the clot exposed by opening the dura. The incision in the latter is indicated by the dotted line. It should be about  $\frac{1}{4}$  inch from the bony margin of the aperture.

**Treatment.**—The question of operation is determined by the amount of compression. If there be distinct evidence of pressure upon a particular centre, even though there be no general symptoms of compression, it is well to open the skull over that point and remove the clot. If left, the pressure of the clot may cause softening of the brain beneath and permanent damage; or the clot may be imperfectly absorbed, when a blood-cyst is produced, leading to permanent pressure on the brain; or, finally, the organisation of the clot may cause adhesions between the membranes leading to violent headaches, epileptiform convulsions, or mental derangement.

After removing the bone and dividing the dura mater, the clot should be removed by gentle irrigation with warm salt solution (see p. 29). Any

bleeding points present after removal of the clot should be taken up and twisted or tied. As a rule the hæmorrhage can be easily arrested by gentle pressure with a hot sponge. After the bleeding has quite ceased, the opening in the dura should be stitched up, a piece of sterilised gold-foil larger in circumference than the trephine opening being placed between the brain and the dura so as to prevent adhesions, the portions of bone replaced and the wound stitched up. In some cases it is well to put in a few threads of horsehair to act as a drain.

**Hæmorrhage from other vessels.**—Injuries of other vessels inside the skull are rare compared with rupture of the middle meningeal. Apart however from that artery other small vessels on the outer surface of the dura mater may be injured, or the internal carotid itself may be torn in fractures of the base, or there may be hæmorrhage from various cerebral sinuses, usually as the result of fracture. The longitudinal sinus is the one most commonly affected.

**Symptoms.**—The symptoms of bleeding from a sinus are those of intracranial hæmorrhage from other causes, but, as a rule, localising symptoms are not distinct, owing to the situation of the bleeding. The compression also is not so rapid as in hæmorrhage from the middle meningeal, nor is it so severe, owing to the lower pressure of the blood in the sinuses. Bleeding from the superior longitudinal sinus is always associated with fracture of the skull, and consequently it is usually accompanied by a diffuse hæmatoma of the scalp. The occurrence of a hæmatoma on the vertex associated with symptoms of compression is a valuable diagnostic point and may indicate where the rupture of the vessel has taken place.

Death does not necessarily follow in these cases, even when no operation is performed, owing to the slight pressure under which the blood is poured out. Various consequences may, however, follow, chiefly from adhesions, which may give rise to epileptic fits or mental disturbance at a subsequent period.

**Treatment.**—When the fracture runs across a sinus, such as the superior longitudinal, and there is a hæmatoma with signs of compression, the proper treatment is of course to open the skull in the situation of the sinus. It is well to make the trephine opening a little to one side of the sinus, and then, if necessary, to enlarge the opening in the bone by clipping away portions with Hoffman's forceps. In this way the risk of laceration of the sinus with the teeth of the trephine is avoided. On removing the bone, blood may be found between it and the dura, but it is generally advisable to open the latter in the manner already described (see p. 48), as there is usually sub-dural hæmorrhage as well. In some cases the opening in the sinus may be stitched up, or an attempt may be made to tie the vessel between two ligatures after opening the dura mater. That, however, is not at all an easy matter, and one is very apt to lacerate the sinus still further, so that in most cases where it is impossible to stitch up the opening in the dura mater the best plan is to plug the

wound with gauze and to re-apply the flap temporarily. After a couple of days the gauze may be removed and bleeding will not recur.

**After-treatment.**—In all these cases of hæmorrhage the patient may as a rule be allowed to sit up and be regarded as well when the wound has healed. After three or four days there is little or no probability of recurrence of the hæmorrhage, and after ten days, when the wound may be considered to be healed, any risk of inflammatory troubles will probably have completely passed away.

## CHAPTER IV

### INTRA-CRANIAL SUPPURATION.

THE following forms of intra-cranial suppuration may follow injuries, especially compound fractures: (1) suppuration between the dura mater and the skull; (2) localised suppuration beneath the dura; (3) diffuse leptomeningitis; and (4) cerebral abscess. These conditions may also arise as the result of suppurating wounds of the scalp or necrosis of the skull, and may follow suppuration in the frontal sinus, the middle ear, and the mastoid antrum. The processes are very similar whether they arise from injury or from disease, but it will be more convenient, as far as treatment is concerned, to speak first of intra-cranial suppuration as it arises after an injury, and subsequently of the affection as it originates from disease, notably of the middle ear.

#### INTRA-CRANIAL SUPPURATION FOLLOWING INJURY.

**EXTRA-DURAL SUPPURATION.**—This condition very rarely follows an injury unless there be an external wound, and it most often complicates compound fracture. Sub-dural abscess may, however, result from an acute osteo-myelitis subsequent to an injury without an external wound. The affection begins as an inflammatory thickening of the outer surface of the dura mater with effusion of fluid beneath it; in the majority of cases suppuration subsequently occurs between the membrane and the skull and leads to the formation of an extra-dural abscess.

When there is no external wound or when the inflammation occurs at a little distance from the wound, there is developed what is known as "Pott's puffy tumour" over the seat of the suppuration. This is a limited œdematous swelling of the scalp associated with symptoms of meningitis and subsequently of compression. The puffy tumour is due to the effusion of fluid beneath the pericranium accompanied by œdema of the tissues superficial to the affected part. It almost always indicates the formation of an abscess between the bone and the dura mater, and usually also



necrosis of the inner table, or, it may be, of the whole thickness of the skull. When there is a compound fracture, and consequently an open wound, this puffy tumour will not necessarily occur, but the wound as a rule becomes unhealthy, the granulations are pale and flabby, the secretion becomes diminished and foul, the pericranium is detached from the surface of the skull in the vicinity, leaving a considerable amount of bare bone exposed, and there is an œdematous condition of the parts around.

In connection with this local condition there is marked pyrexia, headache and very rapid pulse: there may be rigors, and, when the pus cannot escape externally, there is a gradually increasing drowsiness, often accompanied by delirium or epileptiform convulsions, ending in more or less complete coma. In fact, symptoms of compression set in as the collection of pus beneath the skull increases in size.

In compound fractures this condition usually comes on two or three days at least after the injury; sometimes it may occur at a later period. The first thing that happens after the fracture is concussion, which is usually followed by an interval of consciousness; symptoms of compression without fever, and due to intra-cranial hæmorrhage, may then arise, and subsequently suppuration of the clot takes place accompanied by fever, shivering, and the other symptoms already mentioned.

**Treatment.**—The treatment consists in immediate and thorough opening up of the inflamed area. When there is no external wound, a flap should be turned down exposing the centre of the puffy tumour, and it is well to make this flap large, as a considerable amount of bone may require removal. When, however, a wound already exists, and especially when there is a fracture or a fissure present, the wound must be enlarged in any direction that seems most desirable. The periosteum will be usually found detached, and a large circle of bone should be removed and the pus allowed to escape from between the dura mater and the skull. The state of the divided bone must be carefully examined for the presence of suppurative osteo-myelitis, and if the diploë be unhealthy at the point of section, the bone should be freely dealt with in the manner already described for acute osteo-myelitis (see p. 30). Unless the collection of pus be large and the diploë be healthy, it is well to make the opening in the bone almost co-extensive with the collection of pus beneath, so as to admit of proper drainage. By doing this also time is frequently saved, for it is not uncommon for the bone over the area of suppuration to be more or less completely necrosed.

After the inflamed region has been thoroughly opened up, the pus should be gently washed away with a stream of weak sublimate solution, when the dura mater will usually be found thickened and covered with lymph, or even actually sloughing. Some surgeons advocate scraping the cavity, but it must be borne in mind that the vitality of the dura mater, if not actually destroyed, is in a very precarious state, and that any rough treatment, such as scraping, may lead to perforation and infection of the

sub-dural tissues. Besides, scraping an acute abscess is not a satisfactory procedure, as it is apt to open up fresh paths for the penetration of the bacteria. It is well to touch the divided surfaces of bone with pure carbolic acid so as to shut off the Haversian canals from infection, but great care must be taken that the acid does not get on to the dura mater.

When a flap has been turned down, one or two large drainage tubes should be introduced at the corners of the flap and the remainder stitched up. On the other hand, when a wound has existed previous to operation, it is perhaps best to pack it lightly with cyanide gauze for three or four days and then, when granulation is progressing satisfactorily, to attempt to bring the edges together, making due provision for the drainage of the deeper parts. The risk in these cases is of extension of the disease in the bone or of infection of the meninges leading to a suppurative lepto-meningitis.

**SUB-DURAL SUPPURATION.**—This may occur either as a localised collection of pus or as a diffuse lepto-meningitis.

**Localised Sub-dural Suppuration.**—As a rule, the result of the inflammation of the dura mater is to cause adhesions between that membrane and the arachnoid, and thus, for a time at least, the sub-dural space may be shut off. Pus may then form among these adhesions, so that there may be a considerable abscess without any general infection of the sub-dural space. As this abscess enlarges, it causes ulceration and superficial suppuration of the cerebral convolutions beneath, or a fresh abscess may form somewhat deeper in the brain and not communicating with the sub-dural abscess. If the case be left to itself, the dura mater may slough and, if there has been a compound fracture, the pus may find its way externally, but as a rule the patient dies from cerebral compression, from extension of the affection to the general meningeal cavity, or from deeper-seated cerebral abscess.

The *symptoms* are practically the same as those already referred to, but it is not uncommon to have more cerebral irritation than in the preceding cases. It is however as a rule impossible to diagnose a sub-dural abscess from an extra-dural one until the parts have been fully exposed.

**Treatment.**—The abscess cavity must be freely opened, but care must be taken not to break down the adhesions about the dura mater and the arachnoid which shut off the sub-dural and sub-arachnoid spaces from the abscess cavity. The procedure in the early stage of the operation is the same as that just detailed (see p. 53) up to the clearing out of the extra-dural abscess. The sub-dural abscess may or may not be combined with an extra-dural abscess, but in any case, when the dura mater has been exposed it should be opened at about the centre of the circle and, if pus escapes, the opening should be freely enlarged. It is well to wash out the abscess cavity with weak sublimate solution (1-8000) or boracic lotion, but the greatest care must be taken to avoid using force that might break down the barrier around the abscess cavity. If the dura mater be sloughing, the necrotic area should be clipped away. Large drainage tubes should

be inserted, stitches put in the flap and an antiseptic dressing applied. Even when the case is one of compound fracture, it is well to bring the edges of the skin together if possible, after providing for free drainage, because there is a very great risk of the occurrence of hernia cerebri,—a condition which will be treated of more in detail later on.

*The after-treatment* of the case is simply that of an abscess, and if all goes on well, the patient generally recovers rapidly. If the contrary be the case it will be from extension of the suppuration to the meninges, from the formation of an independent cerebral abscess, or from the occurrence of hernia cerebri; these conditions must be treated in the manner described under their respective headings.

**Diffuse Lepto-Meningitis.**—When the inflammation extends to the sub-dural space and there are no adhesions to localise it, the disease rapidly spreads over the surface of the entire hemisphere; it is usually most marked about the seat of infection and spreads thence towards the base of the brain and then along the spinal cord. After a short time the brain becomes covered with pus and lymph, and it is probable that the surface of the brain is also involved in the inflammatory process; at any rate there is usually some softening with or without hæmorrhagic infiltration.

The disease is one of extreme gravity and is characterised by pyrexia, distressing headache, gradually increasing drowsiness and often by delirium and epileptiform convulsions. At first cerebration may be over-active and the intelligence unimpaired, but in the later stages the patient becomes more and more unconscious. The pulse is at first very rapid, but later on, when symptoms of compression appear, it becomes slow, full and bounding. There may be rigors, and the temperature, at first continuously high, may later on assume a hectic character. There may be various motor paralyses, especially affecting the cranial nerves. There is often a good deal of rigidity of the limbs and retraction of the head.

**Treatment.**—When the disease is once established there is very little prospect of effecting a cure. If there be a scalp wound with a fissure of the skull, the wound should be enlarged and the bone freely removed with the trephine and Hoffman's forceps. The dura mater is then laid widely open so as to provide the best possible opportunity for the escape of the pus. Additional trephine holes may be made towards the base of the skull, and an attempt may be made to wash out the pus with a gentle stream of sterilised salt solution (.75 per cent.) or warm boracic lotion. As a rule however no particular good will follow these operations in the true diffuse form of the affection; they are only likely to succeed when there is a more or less localised collection of pus. The disease is so extensive that it is impossible to cleanse the whole surface of the brain, which is itself œdematous and swollen and more closely in contact with the skull than usual, so that fluid introduced, even under considerable pressure, will not diffuse itself over the surface sufficiently to wash away the pus. Again, drainage, whether effected by tubes or by horsehair passed between the

openings, will only drain the immediately adjacent area and will be useless to the hemisphere at large. Hence, while it is worth while to open up the wound when one is present, in the hope that the affection may be more or less localised, the chances of doing good by any further operative measures are extremely slight if a diffuse general infection be found. If irrigation be attempted in these cases, great care must be taken not to employ it under pressure, as otherwise the fluid may find its way towards the base of the brain in such quantities as to cause fatal compression.

**INTRA-CEREBRAL SUPPURATION.**—After a compound fracture, or as a result of suppurative processes inside the cranium, suppuration may take place in the substance of the brain with or without an intervening inflammation of the cerebral membranes or adhesion of those membranes to one another. The result is an abscess in the brain which is usually situated in the white substance near the surface and generally underneath the seat of the injury. The infection usually takes place by direct continuity, the membranes becoming adherent and suppuration taking place not only between the brain and the dura mater but also deeper down in the substance of the brain itself. The abscesses of traumatic origin are most common in the frontal and parietal lobes, and in that situation they do not as a rule give rise to any definite localising symptoms.

**Symptoms.**—The classical symptoms produced by suppuration in the brain are those of increased intra-cranial pressure, and will be referred to presently in speaking of abscess as the result of disease. When the abscess occurs after an injury, the symptoms may be identical, but in some cases of compound fracture the symptoms of compression may not be so marked because the opening in the skull allows of the protrusion of brain substance, the condition known as *hernia cerebri*, and this to some extent prevents the occurrence of marked pressure symptoms. As a rule the pulse is slow and the pyrexia is not marked; in fact, when there is considerable pyrexia with a quick pulse, the probability is that the case is one of meningeal trouble rather than of cerebral abscess. Rigors are common and vomiting is not infrequent.

**Treatment.**—The treatment is of course to open and drain the abscess. As has been said, in most of these cases there is already *hernia cerebri* and the abscess is situated immediately underneath it. Under such circumstances, all that is usually required, both for diagnostic and operative purposes, is to introduce a pair of dressing forceps into the hernia and push it in various directions, expanding the blades from time to time until pus is reached. When the pus is let out, the adjacent portions of the brain, which are usually much infiltrated with inflammatory material, may be scraped away sufficiently to establish a free opening into the abscess cavity, which is then gently irrigated with warm boracic lotion. A drainage tube should be introduced, and the general treatment for *hernia cerebri*, to be presently mentioned, should be carried out.

## INTRA-CRANIAL SUPPURATION RESULTING FROM DISEASE.

As has been already mentioned, intra-cranial suppuration may, and perhaps most frequently does, occur in connection with disease, more especially of the middle ear and mastoid antrum. It may also, though more rarely, follow disease of the frontal sinus or the various sinuses connected with the nasal cavity. We shall here only take in detail disease of the middle ear, for that is by far the most common and most important.

In all these cases the three types of intra-cranial suppuration just mentioned may be met with, namely, the extra-dural, the localised or the diffuse sub-dural, and the cerebral abscess. In middle-ear disease these complications usually occur when the mischief has been of long-standing, and only comparatively rarely in connection with an acute middle-ear suppuration. In the old-standing cases the ear and the mastoid antrum become filled with granulations and foul pus, and the disease extends from the mucous membrane to the bony walls of the cavity. Indeed, in tuberculous cases, the disease may commence as a tuberculosis of the bone. This bone affection may extend in two directions, either upwards to the upper surface of the petrous bone about the roof of the attic, or backwards towards the groove of the lateral sinus. The bone becomes inflamed and the inflammation extends to the outer surface of the dura mater: in many cases pus ultimately forms between the latter and the bone.

It is not at all uncommon to find an extra-dural abscess over the roof of the attic which may attain a fair size, and may, if the bone be perforated, in part discharge through the middle ear or the antrum. In other cases the inflammation of the dura mater may lead to adhesion of the dura to the arachnoid over the temporo-sphenoidal lobe and the formation of a localised sub-dural abscess in that position. It is not infrequently accompanied by a certain amount of sloughing of the dura, so that the sub-dural abscess communicates with the bone. In other cases, again, the adhesions between the membranes may not be sufficient to prevent infection of the sub-dural and sub-arachnoid spaces, and a diffuse suppurative lepto-meningitis occurs. Lastly, an abscess may form in the temporo-sphenoidal lobe, either as the result of direct extension along adhesions between the membranes, or by infection by bacteria probably carried along the peri-vascular spaces. These abscesses usually occur near the surface of the convolutions and may be found in any part of the lobe. When arising by direct continuity, they are generally situated about the middle of the lobe, but in other cases the infective material may spread along the peri-vascular sheaths and set up the abscess at some distance from the affected membrane.

When the disease extends backwards from the antrum, the lateral sinus and the dura mater may be separated from the groove in the bone by pus which is apt to extend for a considerable distance along this groove both backwards and downwards. Under such circumstances also the vein becomes inflamed and ultimately thrombosed; this thrombus may become

infected with pyogenic organisms and may gradually break down and give rise to pyæmia. From the groove of the lateral sinus the inflammation may extend to the sub-dural space and may lead to a sub-dural abscess, to a lepto-meningitis or to a cerebellar abscess. The cerebellar abscess may form by direct infection from the inflamed membranes or without any adhesions of the membranes at all. It is usually situated towards the upper and anterior part of the cerebellum.

In cases of long-standing suppuration in the middle ear in the course of which symptoms of intra-cranial disease arise, one or more of the following conditions may be present in addition to the local disease in the middle ear and the mastoid antrum: 1. There may be disease of the bone either over the attic or about the lateral sinus; 2. pachymeningitis and extra-dural abscess may also occur in both these situations; 3. in addition to extra-dural suppuration about the lateral sinus, there may be phlebitis and septic thrombosis of the sinus itself; 4. localised sub-dural suppuration or diffuse suppurative lepto-meningitis may be met with; 5. and lastly, there may be an abscess either in the temporo-sphenoidal lobe or in the cerebellum.

The symptoms and treatment of the disease, in so far as it relates to the middle ear and the mastoid antrum, will be more conveniently discussed among the intrinsic diseases of the ear (see Division II.); we shall only deal here with symptoms which denote extension of the disease to the brain and its membranes.

The only points we need again refer to are in connection with abscesses of the brain, which, as has been said, occur usually in the temporo-sphenoidal lobe or in the cerebellum. The abscess is usually limited by a kind of pyogenic membrane and the pus is often extremely foetid, the most common cause of the foetor being the presence of the bacillus coli communis. Sometimes the pus is greenish in colour from the presence of the bacillus pyocyaneus; in other cases, again, the coloration is due to the presence of blood. In the pus are often sloughs which consist of the white matter of the brain. The abscess is generally single, although smaller abscesses are sometimes found in the vicinity of the main one.

**Symptoms.**—The symptoms of the various forms of intra-cranial suppuration occurring in connection with disease of the antrum are practically the same as those already described for similar conditions arising after injury; it is, however, often difficult to separate the various conditions from one another, and it is not at all uncommon for more than one to be present at the same time.

The chief symptoms of *abscess of the brain* are those due to pressure. The temperature is usually subnormal; in fact, if there be any marked pyrexia, meningeal complications may be feared. The pulse is very slow, sometimes thirty or forty per minute: the respiration is also slow. Rigors may occur and vomiting is more or less constantly present. The pain is often very marked, and may be continuous or intermittent; it is usually referred to the temporal region on the same side as the abscess. Percussion over the tem-

poral or cerebellar regions usually aggravates the pain. Cerebration is slow, and there is difficulty in concentrating the attention. Convulsions may occur, but they are not characteristic: in fact, when convulsive movements with rigidity are present, the pus has passed into the sub-dural space. Optic neuritis is frequently met with; the pupils in the first instance may be contracted, but before very long they become dilated and fixed, and this dilatation in the earlier stage is most marked, or indeed may only be present, on the affected side. The coma gradually increases, and the fatal result is generally due either to gradual deepening of the coma or to the occurrence of lepto-meningitis. Usually the temperature rises towards the end, the breathing becomes quick, and there is great prostration.

In some cases special symptoms may be present dependent on the situation of the abscess, but as a rule localising symptoms are absent because the abscesses usually form outside the motor area. It may happen that as abscesses in the temporo-sphenoidal lobe increase in size they may exert pressure on the lower part of the ascending frontal and parietal convolutions, and this pressure may gradually extend upwards until various motor centres are affected. An extending paralysis affecting first the face, then the arm, and finally the leg without loss of sensation, indicates with great probability the presence of an abscess in the temporo-sphenoidal lobe. Paralysis of individual nerves, such as the facial or the third nerve, as the result of the pressure is not common.

*Cerebellar abscesses* have few localising symptoms. The prominent features are retraction of the head and neck, slow, feeble pulse and respiration, subnormal temperature, yawning, slow speech, optic neuritis, dilated pupils, rigidity of the masseters, and a history of vertigo and vomiting.

When *lepto-meningitis* occurs, the temperature rises and remains high without marked remissions, the pulse becomes more rapid, and there is general irritability. In lepto-meningitis also the cranial nerves are more frequently implicated than in the case of abscess.

In *sinus thrombosis* the temperature is generally high with marked remissions, the pulse is rapid and feeble, there are frequent rigors followed by profuse perspirations, and later on there are symptoms of pulmonary embolism, diarrhœa, pain in the posterior triangles of the neck, tenderness in the sub-mastoid region and down the course of the jugular vein, and a general typhoid state.

**Treatment.**—The various conditions above described are so intermingled when complications follow upon a chronic otorrhœa that it is not possible to consider the treatment of any one of them without the others; moreover, as they all depend upon middle-ear disease, this must be treated first in every case. The first point therefore is to thoroughly open up the mastoid antrum and the middle ear. Any softened and diseased bone beyond the limits of the antrum should be gouged away, and in most cases it is well to extend the incision in the bone backwards so as to expose the lateral sinus and thus to ascertain the condition of the dura and of the sinus itself. The further steps of the treatment will depend upon the

conditions found. When extra-dural suppuration is found, the treatment may in many cases stop after the bone has been freely removed, provided always that the lateral sinus be unaffected. When pus is present in the sigmoid groove, the condition of the sinus must be very carefully investigated. As a rule it is possible by palpation to make out whether or not it is thrombosed, but in case of doubt it is quite permissible to puncture it with a needle; if it be healthy, it will bleed freely; if thrombosed, broken-down clot or pus may be found. Great care must naturally be taken to avoid introducing infective material into the interior with the needle, and therefore the wall of the sinus should be touched at the point of puncture with strong sublimate solution (1 in 500). Should free venous bleeding result, the sinus need not be further interfered with. On the other hand, should septic thrombosis have occurred, the sinus must be opened up and thoroughly cleansed; at the same time all connection between it and the lungs must be obliterated. Usually the operative procedures need not go further than this unless a cerebral or cerebellar abscess is quite certainly present. In suspected cases of abscess of the cerebrum or cerebellum it is often found that the symptoms subside after opening up the mastoid antrum and the sigmoid groove, and therefore in indefinite cases it is well to await developments for a day or two. Should symptoms pointing to suppuration either in the sub-dural space or in the brain continue, a further operation should be done.

We have thus to consider the following operations in connection with these cases: 1. the operation upon the mastoid antrum; 2. the exposure of the lateral sinus and its groove; 3. the methods of dealing with a thrombosed lateral sinus; 4. the steps necessary for opening extra-dural abscesses over the roof of the tympanum; 5. the treatment of sub-dural suppuration, both localised and diffuse; and 6. the methods of treating cerebral and cerebellar abscess.

The methods of treatment appropriate to each of these conditions will be described separately, but it should be clearly borne in mind that in actual practice the surgeon may be called upon to adopt several of them in succession at the same operation. In many cases of middle-ear disease with symptoms apparently pointing to intra-cranial mischief it may be quite impossible to diagnose the actual lesion present, and therefore to undertake the appropriate treatment for it. We shall describe the steps of the procedure that should be carried out in a case of this kind; it will be seen that the surgeon feels his way, as it were, from step to step, and that his further movements are dictated by the conditions found. Of course, when the particular lesion can be accurately diagnosed, the appropriate treatment should be at once adopted.

**1. The operation upon the mastoid antrum.**—In all cases with a history of long-standing discharge from the ear and symptoms of inflammatory intra-cranial mischief, the treatment must commence with the opening of the mastoid antrum, and that for the following reasons. In the first



place, the focus of the disease is in the antrum, and must be removed before any good result can be expected; in the second place, the direction in which the mischief has spread can very often be determined, and in any case can be more easily followed after the mastoid antrum has been opened; and in the third place, it sometimes happens that, even though the symptoms are very grave, the clearing out of the mastoid antrum and the neighbouring cells suffices to effect a cure. It is by no means always easy to diagnose the extent and situation of the mischief, and an acute inflammation in the antrum may give rise to symptoms which may be mistaken for those of grave intra-cranial mischief.

In exposing the mastoid antrum in these acute cases accompanied by doubtful cerebral symptoms, it is well to make a flap considerably larger

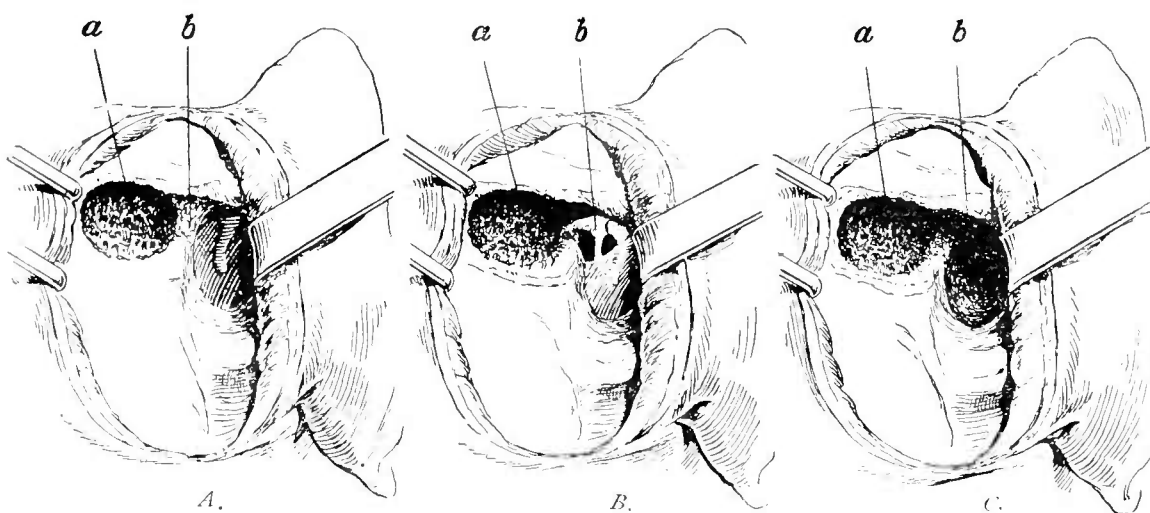


FIG. 15.—THE OPERATION UPON THE MASTOID ANTRUM. The three stages of the operation of clearing out the mastoid antrum are here depicted. In *A* the antrum *a* has been laid open and gouged out, and the bridge of bone *b* between it and the ext. auditory meatus is seen. In *B* this bridge of bone has been removed, laying the antrum and aditus freely open into the tympanum. In *C* the operation has been completed by removing the ossicles and smoothing off all the rough angles, scraping out the cavity, etc. It will be noticed that the incision here shown is smaller than that recommended in the text. It should be like the one shown in Fig. 16.

than that usually employed for the ordinary mastoid operation, as it may be necessary, not only to clear out the antrum, but to expose the lateral sinus freely, and even to explore the brain. The incision should commence about half an inch vertically above the external auditory meatus and be carried with a bold sweep backwards so that its convexity is well behind the posterior margin of the mastoid process, sweeping forwards below to end just in front of that structure. The incision should be carried directly down to the bone and all the soft parts, including the pericranium, should be turned well forwards with it. The antrum is on a level with the upper margin of the bony meatus and slightly less than half an inch behind it (see Fig. 15, *A*, *a*); its cavity lies about half an inch below the surface, and its outer wall should therefore be removed either with a burr driven with an electric motor, or, if that be not available, with a small gouge. The removal of the bone should always be carried out

below the temporal ridge, which can always be identified, and the incision should be deepened steadily above and anteriorly into the auditory meatus so as to avoid the risk of wounding the lateral sinus or the dura mater (see Fig. 15, *B*). Less bone should be removed as the opening is deepened. When the antral cavity is reached, it can at once be identified by passing into it a bent probe, which should run forwards and slightly upwards into the middle ear.

The opening should be sufficiently enlarged to allow the whole of the interior of the antrum to be scraped out, and the next step consists in dividing the bridge of bone left between the cavity and the external auditory meatus (see Fig. 15, *C*). This is best done with a very fine chisel; it should be used extremely gently, a bent probe being passed meanwhile from the cavity of the antrum through the attic into the middle ear, and this will both serve as a guide and help to protect the facial nerve from injury. When the granulations are being scraped out, great care must be taken not to use force, as the roof of the attic may be actually destroyed, and the granulations may spring from the under surface of the dura mater, and a risk may be run of perforating the latter, and causing septic infection of the sub-dural space.

Another structure that may also be injured in this manner, unless care be taken, is the facial nerve. This structure usually lies in a bony canal, but it is not uncommon to find this either incomplete or actually eroded by the inflammatory processes, so that the facial nerve is surrounded by a mass of granulations. If the nerve be exposed, it is generally easy, by touching it with a probe, to produce twitching of the face. The nerve should run no risk during the removal of the outer wall of the antrum, if care be taken not to deepen the incision unduly below; too low an incision will certainly damage it.

One of the principal difficulties in this operation is that blood wells up freely into the funnel-shaped cavity and obscures the view. This is best obviated by packing the cavity with a narrow strip of gauze by means of sinus forceps, and rapidly removing it, when a clear view is obtained. A number of strips of gauze of suitable size and width should always be kept handy during the operation. After the granulations have been scraped away, the wound is carefully dried, and, with a bent probe, the walls of the cavity are examined in all directions for the presence of a sinus leading either into the sub-dural space or backwards to the lateral sinus groove. If a connection with the sub-dural space be found over the roof of the attic, the bone must be carefully scraped away so as to permit free drainage, and at the same time to ascertain whether there is any collection of pus between the dura and the bone. Should there be a communication backwards to the lateral sinus, the bone must be freely opened up, so as to expose the latter. The ossicles are removed as in the operation for the chronic cases (see Div. II.).

When the cerebral symptoms are quite indefinite the operation may

end at this point, and the next step is to provide for drainage, and to sew up the wound. A knife is thrust through the cartilage and mucous membrane of the external auditory canal, and the latter is split up longitudinally along its posterior aspect. A better plan is perhaps to cut out a large elliptical portion, so as to provide free drainage without the necessity for introducing stitches to pull the lips of the longitudinal incision apart. These methods will be dealt with more in detail by Dr. Lack (see Div. II.), as will be also the after-treatment, the question of skin-grafting the cavity, etc. The incision through the skin is then closed with a few interrupted silkworm-gut sutures, and the cavity of the antrum is packed from the external meatus, through the opening in the cartilage, with narrow strips of cyanide gauze impregnated with iodoform emulsion.

It is often advisable to open up the antrum in cases of chronic ear disease, both in order to cure the ear trouble and also to avoid the risk of the complications of which we are speaking; full details of the indications for the operation under these circumstances and the best methods of carrying it out will be found in the section on the intrinsic diseases of the ear, by Dr. Lack.

**2. Exposure of the lateral sinus.**—The suppuration usually extends backwards; when the antrum is opened, pus may be found entering it from behind through a channel communicating with the sigmoid groove. In any case the removal of bone must be continued directly backwards from the antral cavity to the sigmoid groove, and it should be remembered that the latter lies much nearer the surface than does the antrum, and that therefore the bone must be very cautiously removed until the dura is exposed: a sharp gouge is the best instrument to use. The sinus must be exposed sufficiently freely to allow both its condition and that of the groove in which it lies to be accurately ascertained; if pus be present in the latter, the groove must be cut away both backwards and downwards until the infected area has been thoroughly exposed. In most of these cases the vein itself will be thrombosed; should it be still patent however, as will be shown by free bleeding when punctured with a needle, the operation may cease at this point, after the mastoid cells have been cleared out. The wound should be packed with iodoform gauze and left open, and the dressing should be changed every twelve hours. Unless some further intra-cranial complication exists, the patient will greatly improve within forty-eight hours.

**3. Treatment of sinus thrombosis.**—When the lateral sinus is thrombosed, the most important point is to determine whether the thrombus be infected. In the early stages this is not always easy, but to some extent the general symptoms are a guide. The presence of rigors, an intermittent temperature and other signs of pyæmia are of great help: additional information is afforded by ascertaining whether the clot in the sinus is firm and dark or whether it is softening and yellowish. *When no general symptoms of infective phlebitis exist, and the clot is firm and dark, the opera-*

tion may be completed for the time being in the manner mentioned in the preceding paragraph; should further symptoms arise, or should the febrile condition continue for more than 48 hours, the procedure mentioned in the following paragraph must be adopted.

*When the clot is breaking down*, the patient is in imminent danger of death from pyæmia. In some cases, it is true, the wall of the vein may have sloughed, so that the contents simply form part of a sub-dural abscess, but when this is so there are not the symptoms characteristic of a breaking-down thrombus: washing out the pus, with free exposure and drainage of the sub-dural space, will generally suffice for a cure in these cases. When, however, the vein is intact, but a puncture or small incision into it shows that it contains breaking-down clot, it is best, before dealing further with the local condition, to cut off all communication between the sinus and the general circulation. The best thing is to cover up the wound and disinfect the hands, and then, using fresh instruments, to expose the internal jugular vein in the neck and to ligature and divide it there.

*Ligature of the internal jugular vein.*—The incision for exposure of the internal jugular vein is the same as that for ligature of the common carotid artery above the omo-hyoid (see Part II., p. 320). The most convenient place to ligature it is opposite the bifurcation of the carotid; this point is easy of access and is almost always well below the limits of the thrombus. It is most essential that the ligature should be applied to a patent portion of the vein. The circulation through the vessel is interrupted by means of a double ligature passed round it and tied in two places; the vein is then divided between them.

After the vein has been tied, the wound behind the ear is uncovered, the lateral sinus is laid freely open and the clot washed out. When the latter extends down beyond the foramen lacerum medium, it is well to open up the upper part of the ligatured jugular vein and to wash out all clot with a stream of warm (1 in 2000) sublimate solution. Should the mastoid vein be thrombosed, the opening in the bone should be enlarged and the thrombus scraped out with a small spoon. Any clot extending backwards along the lateral sinus should also be removed by scraping and flushing until the entire thrombus has been cleared out, in fact until free bleeding occurs from the sinus. In order to lay the whole infected area freely open it may be necessary to continue the removal of bone for some considerable distance backwards. The bleeding is easily arrested by pressure with strips of gauze.

The cavity should next be packed with gauze, and as a rule nothing further need be done. It is best to wait and see whether the symptoms are relieved by what has been done, or whether further symptoms indicating a lepto-meningitis or cerebral abscess appear in the course of 48 hours. Should no such symptoms arise, the packing is removed daily until granulation is complete, when the skin flaps may be brought together, a drainage tube being substituted for the packing; the antral cavity may be grafted

(see Division II.). The jugular vein is not of course the only communication between the lateral sinus and the general circulation, but it is the main one and, as a matter of practical experience, it is found that, if the jugular be ligatured early in the course of the case, in the manner just described, a good result follows.

**4. The treatment of extra-dural abscess.**—When the general symptoms are very grave, and the lateral sinus and its groove are quite unaffected, it is advisable to carry the treatment further before closing the wound and to ascertain whether sub-dural suppuration exists. In some cases the roof of the attic is diseased, and there may even be an actual perforation from which pus is escaping. The bony roof of the attic must then be exposed and the dura mater lifted up from it; as much of the diseased

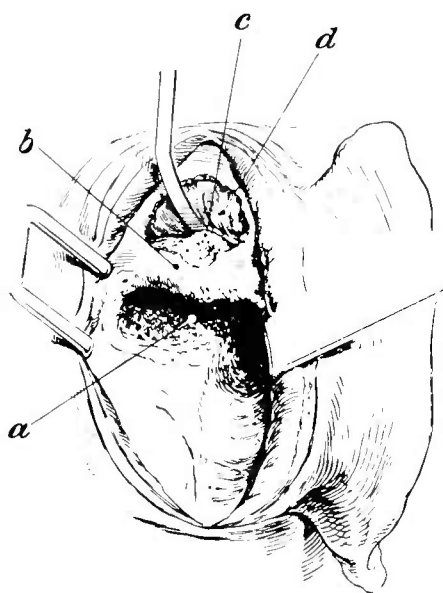


FIG. 16.—EXPOSURE OF THE UPPER SURFACE OF THE PETROUS BONE. The mastoid antrum *a* has been laid into the external auditory meatus. The cranial cavity has been opened above the temporal ridge *b*, and the dura mater *d* has been lifted up by a spatula. This exposes the upper surface of the petrous bone *c*. The bridge of bone *b* may be chipped away if desired.

bone as possible should be removed so as to provide free drainage. The best way to examine the condition of the dura mater over the roof of the attic and the adjacent part of the petrous bone is to enlarge the opening already made for exposure of the antrum directly upwards and possibly a little forwards. The prominent ridge formed by the posterior or horizontal root of the zygoma, which is prolonged backwards as the commencement of the temporal ridge, is easily identified, and serves as a landmark. It corresponds to the level of the under surface of the temporo-sphenoidal lobe and the upper surface of the petrous portion upon which it lies. The incision in the skull should therefore be carried well above this ridge (see Fig. 16, *b*), when the cranial cavity will be opened. The dura is now separated from the petrous bone with a suitable blunt spatula (see Fig. 17) and raised so that any pus between it and the bone can escape and so

that the adjacent surfaces of the dura mater and the bone can be examined and any diseased areas in the latter carefully cut or scraped away with a small gouge or sharp spoon. The semicircular canals must be strictly avoided. When there is pus in this situation, a strip of gauze should be packed between the dura and the bone at the end of the operation in order to maintain efficient drainage.

**5. Treatment of lepto-meningitis.**—The treatment of suppurative lepto-meningitis is extremely unsatisfactory and it is very seldom indeed that it is

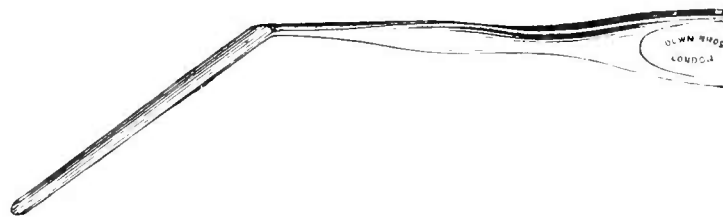


FIG. 17.—HORSLEY'S DURA MATER SEPARATOR.

successful. Attempts may be made to wash out the pus by making two or three trephine holes and opening the dura mater at the base of the skull, but it is very doubtful whether anything more than mere temporary relief can be obtained by them. By opening the skull low down in the occipital region and lifting the cerebellum up from the medulla oblongata so as to allow the escape of fluid from the fourth ventricle, very considerable, but usually only temporary, relief may be obtained. The fluid that escapes is not necessarily purulent, and its escape should be facilitated by the insertion of drainage tubes beneath the cerebellum (see p. 75).

**6. Treatment of abscess of the brain.**—As has been already said, it is difficult in many cases to localise these abscesses. When the roof of the attic is carious, the probability is that the abscess is in the temporo-sphenoidal lobe which should be first explored; failing the discovery of the abscess there, the cerebellum should be examined before the operation is concluded. When, on the other hand, suppuration occurs along the sigmoid groove, the abscess is probably in the cerebellum, which should therefore be explored first. It sometimes happens that a communication is found passing directly from an extra-dural abscess into a superficial abscess of the brain above it. Any such opening should be enlarged, the abscess washed out and treated in the manner to be described immediately without further removal of bone.

When the lateral sinus has been previously exposed (*vide supra*), and when the symptoms, instead of subsiding, lead to the suspicion of an abscess in the brain, the simplest plan is to enlarge the opening in the bone over the sinus sufficiently to enable both the temporo-sphenoidal lobe and the cerebellum to be explored if necessary. All that is necessary is to cut away bone above and below the sinus, the limits of which are easily known by the deep colour of its contents, and then to puncture the dura above

or below it, according as it is desired to explore the cerebrum or cerebellum (see Fig. 18). The method of exploring the brain is described below; in practising it under these circumstances, the greatest care must be taken to prevent the introduction of septic material from the antral region into the brain. The forceps are carried horizontally forwards above the sinus to explore the temporo-sphenoidal lobe, and forwards and inwards below that structure to explore the cerebellum.

In other cases, however, the symptoms may point so clearly to an abscess of the brain, that, after clearing out the focus of the disease in the

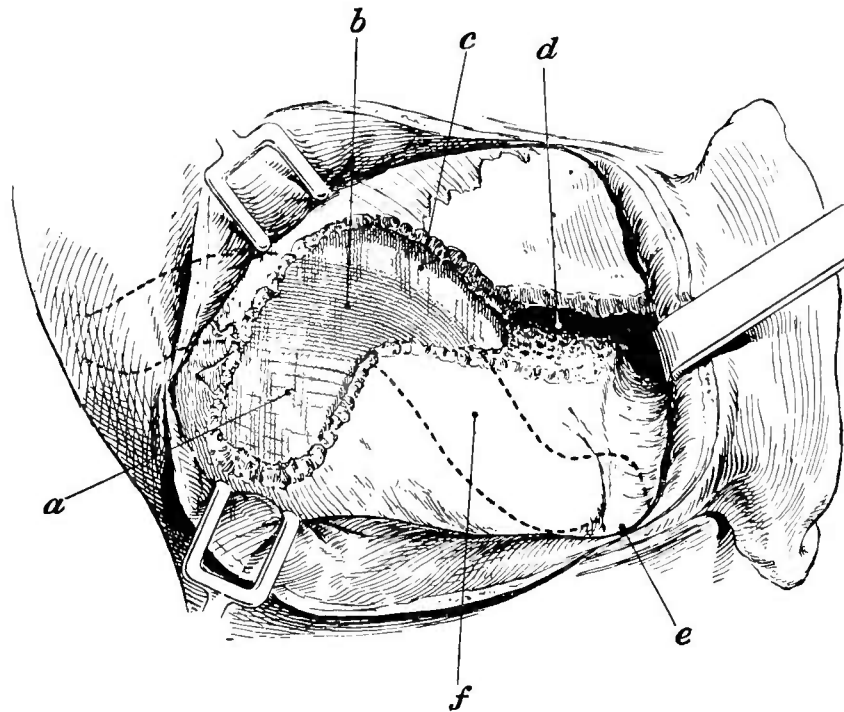


FIG. 18.—EXPLORATION OF THE CEREBRUM AND CEREBELLUM THROUGH THE SAME OPENING IN THE SKULL. By enlarging the incisions in the soft parts and the bone as shown above, the dura mater can be exposed on either side of the lateral sinus, and both the temporo-sphenoidal lobe and the cerebellum explored for an abscess. *a*, Dura mater over the cerebellum; *b*, lateral sinus; *c*, dura mater over the cerebrum; *d*, mastoid antrum laid into the auditory meatus; *e*, mastoid process; *f*, dotted outline of the lateral sinus.

ear, it will be unnecessary to proceed to expose the sinus, and the brain abscess should be sought for at once. The following methods may be tried:

In operating for *abscess in the temporo-sphenoidal lobe*, the best plan is to apply the pin of the trephine about an inch and a quarter above Reid's base line,<sup>1</sup> directly above the external ear. The dura mater, which bulges into the opening and does not pulsate, is incised and the temporo-sphenoidal lobe exposed. In incising the dura, any large vessels running across it should be avoided if possible or picked up in forceps as soon as the incision has been made. It is sufficient at first to make a small slit in the dura mater just large enough to admit sinus forceps, and this need not be enlarged unless pus be

<sup>1</sup>This is a straight line passing from the lower margin of the orbit to the centre of the external auditory meatus and prolonged backwards (see Fig. 22).

found. The exploration of the brain is best effected with a pair of sinus forceps, introduced closed: the blades are separated from time to time, when any pus they reach will escape along them and will certainly be found. If the exploration be made with a hollow needle or with a trochar and cannula, the channel is apt to be blocked with brain substance and the pus may not escape, even though the instrument passes into an abscess cavity. The forceps should be first introduced directly inwards. If they fail to reach pus there, they may be next directed upwards and backwards and finally downwards and forwards; in this way the three chief situations of temporo-sphenoidal abscess will be explored.

If pus be found, the opening in the dura should be enlarged and a pair of dressing forceps should be substituted for the sinus forceps; with a blunt scoop any sloughs present in the abscess cavity are removed. The nozzle of a fine syringe is then introduced into the abscess cavity and a gentle stream of warm boracic lotion flushed through it. Care of course must be taken not to use any pressure and to see that there is a free escape for the fluid, as otherwise serious damage may be done. When the abscess has been thoroughly cleansed, some surgeons simply withdraw the forceps and allow the cavity to close without drainage. For our own part, we prefer to put a drainage tube into the abscess cavity for at least two or three days. Where that is done, a hole can be made for it in the centre of the flap, which is stitched up with a continuous suture. At the end of two or three days the discharge will generally have practically ceased and the tube may be left out. The disadvantage of a drainage tube is that the brain may become adherent to the edges of the opening in the dura mater and to the under surface of the flap, and this may possibly be followed by epileptiform attacks. On the other hand this by no means necessarily occurs, and, where no drainage is employed or where it is not efficient, the abscess may re-form, may extend more widely and may not be so successfully dealt with on the second occasion. Indeed, it is often difficult to prevent the abscess from re-forming, even when a drainage tube is used. On the whole a glass tube, perhaps, answers best.

When no abscess is found in the temporo-sphenoidal lobe or when the symptoms indicate *cerebellar abscess*, the cerebellum must be explored. In cases in which the sigmoid groove has not been opened, this may be done by turning down a flap beneath the superior curved line on the side affected and then applying a trephine in the space bounded by the superior curved line above, the sigmoid groove in front and the middle line behind. After the trephine hole has been made, the further procedures are identical with those just mentioned. The abscess is usually found in the anterior and upper part of the cerebellum, and that is the direction in which the forceps should first be introduced. It is not uncommon for these abscesses to be found extending directly inwards from the lateral sinus, and in cases in which the sigmoid groove has been exposed it may only be necessary to cut away a little bone downwards and then, after incising the dura,



to introduce the forceps below the lateral sinus towards the upper and anterior part of the cerebellum.

When the abscess has been successfully opened and the case goes on well, the drainage tube may be removed in a couple of days, and the wound usually heals in a week or ten days. It is but seldom that any protrusion of brain takes place through the small opening left by the drainage tube, unless the suppuration be still active and the drainage imperfect.

## CHAPTER V

### HERNIA CEREBRI: TUBERCULOUS MENINGITIS : SINUS THROMBOSIS.

#### HERNIA CEREBRI.

As a result of various operations, injuries, and inflammatory processes in connection with the brain, we occasionally meet with this condition which, in its simplest significance, means a protrusion of cerebral substance through an aperture in the skull produced by injury or disease; it is thus differentiated from encephalocele, in which the protrusion takes place through an aperture resulting from a congenital malformation. *Hernia cerebri* is met with under two conditions: in the first place, the protrusion may occur immediately or very shortly after the injury or the operation,—in which case it is spoken of as a primary *hernia cerebri*; in other cases it may not occur until some days after the skull has been opened—when it is spoken of as a secondary hernia. It may follow trephining, compound fractures, or destruction of the cranial bones by syphilitic or tuberculous disease.

**PRIMARY HERNIA CEREBRI.**—This condition may follow after an operation or an injury in which a portion of the bone has been lost and the *dura mater* has been opened: such, for example, are operations for tumour, operations for the removal of blood-clot, compound fractures, etc. The healthy brain substance protrudes through the opening in the skull as the result either of a certain amount of œdema of the brain—which may happen when there has been a sudden relief of pressure after the removal of a blood-clot,—or of an unrelieved intra-cranial pressure—as after an operation for irremovable tumour of the brain; in this case the protrusion is practically immediate.

A primary *hernia cerebri* following an operation in which the cause of compression has been removed does not lead to any serious trouble. If the opening in the *dura mater* be large and the flap of skin has been replaced and completely sutured, the œdematous condition of the brain

soon subsides and, as healing occurs, the protrusion gradually retracts within the skull. Sometimes, however, the case does not follow this favourable course, for processes may occur which prevent the return of the brain. For example, when the opening in the dura is small, the protruded portion of the brain may be constricted at its base, its circulation interfered with and the œdematous condition of the protruded portion so much increased that it cannot return through the opening. A similar difficulty will also occur when the brain contracts adhesions to the margin of the opening so that, even if the œdema subsides, complete recession of the protruded portion will not take place. Moreover, when an operation has been performed for the relief of pressure due to a tumour and the tumour cannot be removed, it is of course obvious that any protrusion following the operation must remain permanent.

**Treatment.**—Bearing in mind the tendency to the occurrence of this condition whenever the dura mater has to be opened, all cerebral operations must be planned so as to avoid or control this accident. It is chiefly for this reason that the flap method of exposing the skull before trephining was introduced; the line of cicatrix in the soft tissues is thereby removed from the vicinity of the hernia, and this undoubtedly diminishes the risk of primary hernia. For this reason also, the dura is opened by a curved incision with the curve in the opposite direction to that of the flap in the skin (see Fig. 14). Further, the incisions in the dura are sewn up closely with fine catgut; when this is not possible, the gap in the membrane should be bridged with catgut somewhat in the way in which a stocking is darned, so as to provide a barrier to the escape of the brain. Finally, with the view of checking hernia and of preventing adhesions between the brain and the edges of the opening in the dura in these cases, it is well to introduce between latter and the brain a piece of gold-foil or other unirritating thin material larger in area than the opening in the dura, so as to prevent the two coming in contact. In operations carried out in this manner, primary hernia cerebri should not occur, especially where the dressing is so arranged as to form a support during healing; it is still less likely to occur after trephining in which the circle of bone has been replaced.

When a hernia has occurred, it is usually sufficient to wait for the subsidence of the œdema, keeping up pressure over the orifice in the skull meanwhile; as a rule the hernia will recede in the course of a few days. Should it not do so, however, the cause is usually too small an opening in the dura mater or adhesion between the latter and brain. Under such circumstances, it is well, after the lapse of four or five days, to turn down the flap again and to enlarge the opening in the dura mater, separating any adhesions between the margin of that opening and the brain so as to allow the protrusion to recede into the cranial cavity. When the opening in the dura has been enlarged, it is well to incorporate with the dressing a plate of sterilised block-tin or other firm material rather larger than the

opening in the bone, kept in place by the bandages fixing on the dressing, or if necessary by an elastic bandage. This will support the part, prevent the increase in the protrusion and lead to its gradual return into the cranial cavity.

The difficulty in the treatment is much increased when the hernia occurs after a compound fracture or some accidental wound, because in the first place the opening in the skin is usually over the hernia, and in the second place the tissues are likely to be infected. There are therefore the additional problems of how to close the opening in the skin so as to prevent the protrusion, and also how to arrange for the proper disinfection of the wound and the prevention of further infection. In some cases indeed it may be impossible to close the wound in the skin, or it may be necessary to remove a portion of the scalp owing to its soiled condition, and the hernia then protrudes not only through the opening in the skull but through that in the skin. Under such circumstances the best treatment, after having provided against constriction, is to cover the hernia completely with a piece of Lister's protective, and to apply outside that the ordinary gauze dressings in which a piece of block-tin is incorporated and kept in position by means of an elastic bandage. This dressing will require changing daily, and, if no infection occurs, the hernia will generally gradually recede, until in the course of a week or ten days, it may have entirely disappeared. As soon as the hernia has receded to any considerable extent, an attempt should be made to close the skin opening; by means of a plastic operation a flap of skin can usually be brought over the opening in the skull, and any raw surface left where the flap has been taken from can be covered by skin grafts.

In other cases, where no skin has been lost and where the hernia has not yet occurred, it is well, after cleansing the wound in the manner already described, to stitch the wound closely together, if necessary after undermining the scalp in the neighbourhood, or even by making an incision into the scalp at a little distance away from the edge of the wound. In these cases, however, it is hardly safe to close the wound completely on account of the possibility of sepsis, and it will therefore be necessary to introduce a drain, preferably of catgut, at one angle of the wound in the dura mater so as to prevent the accumulation of fluid. This drain will of itself usually prevent protrusion and does not materially complicate matters.

**SECONDARY HERNIA CEREBRI.**—The most serious form of hernia cerebri however is the secondary form occurring two or three days after an operation or an injury. In this case the protrusion of the brain is due to the surface becoming infiltrated with inflammatory exudation and also to the increase in intra-cranial pressure from the congestion of the brain beneath. The protruded portion in these cases usually contains comparatively little cerebral matter and is mainly composed of granulation tissue and lymph diffused among the cerebral cells, so that the amount

of brain substance protruded is in reality very much smaller than might be supposed. Suppuration generally occurs on the surface of the hernia and in some cases, especially when the swelling continues to increase, a collection of pus will be found in its interior or even extending into the skull and forming a superficial cerebral abscess.

These secondary herniæ vary in size and are generally somewhat mushroom-shaped, for they expand after emerging through the opening in the skull. They are usually very vascular and they have a more or less constricted pedicle corresponding to the opening in the dura mater. They are covered with granulations which discharge pus freely and are often gangrenous in patches. Too great pressure over these herniæ—as well as over the primary forms—may lead to convulsions. A spontaneous cure sometimes results either from gradual cicatrisation of the whole mass or from gangrene of the herniated portion and cicatrisation of the pedicle. As a rule, however, the condition is followed by septic inflammation of the deeper parts of the brain, by cerebral abscess, leptomeningitis or pyæmia.

**Treatment.**—The treatment is directed first to attempts to render the hernia aseptic and subsequently to reduce it within the cranial cavity. In the first instance, the surface of the protrusion should be thoroughly scraped with a sharp spoon: although the whole protrusion need not be scraped away, there need be no hesitation in removing a considerable portion, seeing that it contains very little healthy cerebral substance. The surface is next thoroughly swabbed with undiluted carbolic acid after the bleeding has been arrested by pressure and before adhesions are separated; this is important, as it avoids carrying septic material into the deeper structures. All this can usually be done without an anæsthetic because the protruded mass is insensitive. The surface may then be powdered with iodoform, and Lister's protective applied over it, outside which a large gauze dressing, overlapping the protective widely in all directions, is applied. A piece of block-tin may be incorporated with the dressings and additional pressure applied by means of an elastic bandage. If the sepsis has been got rid of in this way and if there be no intra-cranial inflammatory mischief going on, such as an abscess underneath, the surface of the herniated portion will often granulate and the protrusion may not recur: as granulation goes on, the hernia gradually shrinks and disappears. As soon as it is found that the wound is aseptic, an attempt should be made to cover in the hernia: either the edges of the wound may be freed for some distance so as to allow them to be stitched together, or, if there be much tension, a flap of skin may be turned in over the hernia and the space left skin-grafted as before described.

Occasionally the inflammation is not limited in this way but is accompanied by intra-cranial trouble, especially suppuration in the brain beneath. These cases are usually very hopeless: not only should the surface be scraped away, but forceps should be introduced into the brain beneath

and their blades expanded so as to ascertain if any pus be present. If so, the cavity should be washed out, drained and treated as already described (see p. 68).

#### SINUS THROMBOSIS.

The venous sinuses in the skull are probably more predisposed to the occurrence of thrombosis than are any other veins, owing to their anatomical characters and the peculiarities of the circulation through them. Two forms of thrombosis are met with, namely, non-infective or marasmic thrombosis, and the infective form. Of these the latter is the more common, and is in fact the only one for which active treatment can be employed.

**The marasmic form** chiefly occurs in the longitudinal sinus and affects weakly people, especially children or old subjects, after prolonged and debilitating illnesses. In children, exhausting diarrhœa is one of the most common causes, and the thrombosis generally appears during convalescence, the result being cerebral congestion and œdema. In bad cases the ventricles may be distended with serous fluid, and there may be subsequent cerebral softening.

**Symptoms.**—The symptoms are somewhat indefinite, but in children thrombosis may be suspected if convulsions occur after exhausting illnesses, and more especially if the symptoms be unilateral and accompanied by muscular rigidity, strabismus, etc.

**Treatment.**—There is nothing to be done beyond providing absolute rest and administering nutriment in the most concentrated and easily assimilated form. Any symptoms which arise may be appropriately treated, but there seems to be no scope for surgical intervention.

**The infective form.**—This condition is usually met with in the basal sinuses, especially in young adults. It is always secondary to some external lesion, and usually occurs at the nearest point to the source of infection. Among the causes which give rise to it are septic compound fractures, infective processes such as erysipelas, diffuse cellulitis, carbuncle, etc., about the face or scalp, or middle-ear disease. The condition has already been fully described in connection with thrombosis of the lateral sinus occurring after disease of the ear (see p. 59). Among the other sinuses which are not uncommonly affected are the cavernous and the transverse sinus.

**Symptoms.**—*When the cavernous sinus is involved* there are disturbances in the eye on the affected side, such as congestion of the veins, compression of the oculo-motor nerves, pain, small pupil, cloudy cornea, œdematous eyelid, and more or less exophthalmos. Later on, the pupil becomes dilated, and ulceration of the cornea may result. There is pain in the supra-orbital and frontal regions, which is increased on pressure. *When the transverse sinus is involved* the symptoms are chiefly connected with the vagus which is first irritated and later on paralysed.

**Treatment.**—The principles of treatment have been already fully discussed in connection with the lateral sinus (see p. 63). Unfortunately these principles cannot be fully carried out, either in the case of the cavernous or the transverse sinus, but they should be borne in mind in case it may be possible to carry them into effect in any particular instance.

#### TUBERCULOUS MENINGITIS.

In this condition there is a deposit of tubercles in the pia mater, especially about the vessels at the base of the brain. The result is in-

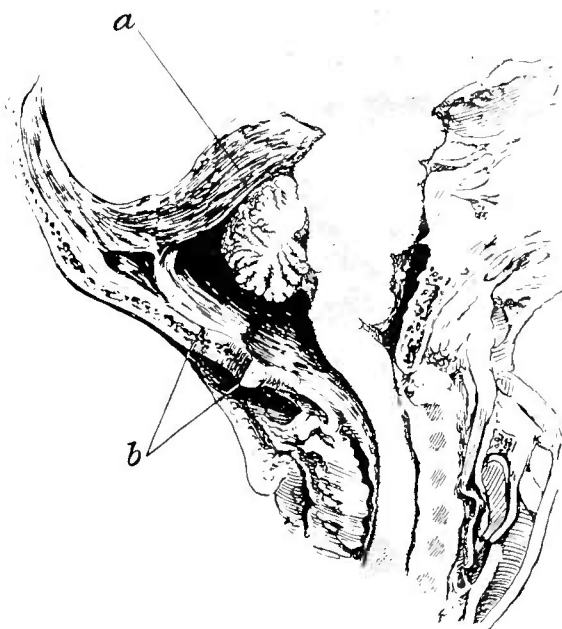

FIG. 19.—DRAINAGE OF THE FOURTH VENTRICLE. The drawing is made from a section of the skull of a foetus just before birth, and shows how the cerebellar sub-arachnoid space is tapped by opening the skull below the inferior curved line. After birth the cerebellum becomes proportionately larger and the space smaller. *a*, The opening in the skull; *b*, the tentorium cerebelli.

The preparation was made by Prof. Arthur Robinson of King's College.

flammation and effusion, acute distention of the ventricles with fluid, and increased intra-cranial pressure.

**Treatment.**—Attempts have been made to relieve this pressure by draining the ventricles, or by inserting a drain through the condyloid foramen, but, although immediate symptoms are often relieved by the drainage of the cerebro-spinal fluid, no permanent good can be expected of it. One or two cases have certainly recovered after drainage of this kind, but it is doubtful whether the condition was tuberculous or merely a simple meningitis. The following is the best procedure for draining the posterior part of the cranial cavity (see Fig. 19).

The head is shaved, scrupulously purified in the usual manner (see p. 7), and flexed as much as possible upon the sternum so as to render the occipital

region accessible. The patient should lie upon the opposite side, with a sand-bag beneath the neck. A semilunar incision with its convexity upwards is then made over the region of the inferior curved line on the side selected for drainage. As a rule the incision will start from the middle line well below the external occipital protuberance—which is often very slightly marked in young children—and will reach as high as the superior curved line. The flap thus marked out is retracted, the inner portion of the complexus either cut through or detached from the occipital bone and the inferior curved line exposed. With a rugine the rectus capitis posticus minor muscle is stripped from its attachment, and the skull is then opened just below the inferior curved line and to one side of the middle line in order to avoid the sinus. A trephine may be used, but a medium-sized sharp gouge is better. This exposes the dura mater which generally bulges into the opening and does not pulsate. In children it is so thin that the cerebellum can be clearly seen through it. The dura is opened at the lowest possible point by a mere nick of the knife and then a fine blunt spatula such as the dura mater separator (see Fig. 17) is passed beneath the lower edge of the cerebellum and the latter lifted gently up. The result generally is a free gush of fluid, which continues to flow and to pulsate in the opening. The greatest gentleness must be observed in lifting up the cerebellum, and the spatula must not be thrust in too deeply or the important structures in the floor of the fourth ventricle may be damaged.

Drainage is effected by passing an indiarubber tube (No. 6) through the hole in the dura and beneath the cerebellum, and a hole is made for it in the centre of the scalp flap, which is then sewn up with a continuous suture and the usual dressings applied.

The drainage of the cerebro-spinal fluid for the first two or three days is generally very free and necessitates frequent change of dressings; the child also markedly improves. The great difficulty is to maintain the drainage, as the tube, if of medium size, soon gets blocked, and if large, allows the semi-fluid cerebellum to escape.



## CHAPTER VI.

### MENINGOCELE AND ENCEPHALOCELE: MICROCEPHALUS: HYDROCEPHALUS.

#### MENINGOCELE AND ENCEPHALOCELE.

THESE congenital deformities are not uncommon. The protrusion may consist of the meninges alone, containing cerebro-spinal fluid—in which case it is termed a meningocele—or it may contain brain substance as well—in which case it is known as an encephalocele. Its most frequent situations are the middle line of the skull, in the occipital region, and at the root of the nose. The tumour may also project through the base of the skull into the naso-pharyngeal cavity between the ethmoid and the sphenoid.

The diagnosis is usually comparatively easy. The tumour may vary in size with respiration, and there is in addition marked cerebral pulsation when brain substance is present. The protrusion is generally partially reducible, but attempts at reduction often give rise to signs of irritation of the brain. The opening in the skull can often be felt. The prognosis is usually unfavourable. The tumour may vary in size from quite a small swelling to one involving the greater part of the cranial contents. The latter cases are especially unfavourable, and the children seldom survive more than a few days or weeks.

**Treatment.**—This practically follows the same lines as that of spina bifida, but it can seldom be carried out to the same extent. In large tumours and those containing much brain substance, *palliative* treatment with the view of avoiding ulceration and spontaneous rupture of the sac will generally be found best; this consists in protecting the tumour with a suitable shield, as already described in connection with spina bifida (see Part IV., p. 297), and in the use of antiseptic ointments where the skin is abraded.

Many forms of *radical* treatment have been attempted, but as a rule without success. Except in small tumours, it is better to leave the case

alone: should it be judged expedient to interfere, excision of the sac and suture of the scalp, much as for spina bifida, is the best practice. For very small tumours it may not be necessary to operate at all.

#### MICROCEPHALUS.

This condition has attracted much attention of late, but on the whole it cannot be said that any material benefit has resulted. In microcephalus the head is small and the general condition probably depends on the

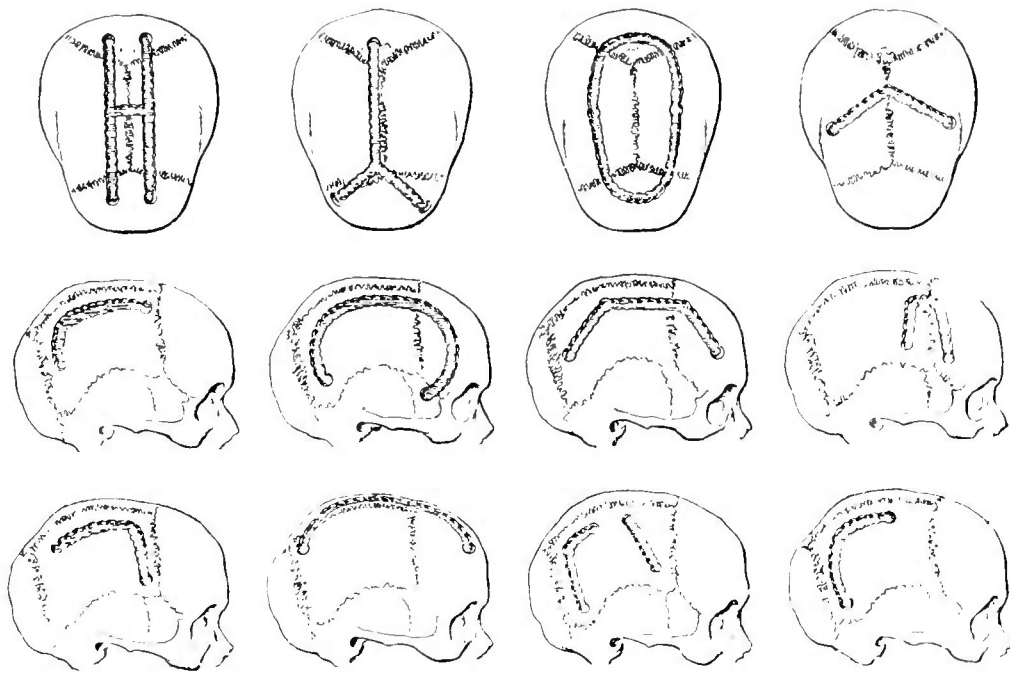


FIG. 20.—INCISIONS FOR CRANIECTOMY. A very large number of incisions have been employed, of which the above are perhaps the best.

imperfect development of the brain. The disease has been supposed by some to be due to a premature ossification of the skull preventing the due expansion of the brain, and on this theory extensive operations aiming at loosening portions of the skull, so as to allow of the expansion of the brain, have been undertaken. It is most probable, however, that the disease is primarily due to interference with the development of the brain, and that the early ossification is the result of the non-development of this organ. The operations cannot be said to have been followed by any marked success, and it is questionable whether they are really justifiable; we ourselves cannot advise their performance. The accompanying diagram shows the various methods by which the skull has been enlarged (see Fig. 20).

## HYDROCEPHALUS.

This is the term applied to abnormal collections of fluid within the cranial cavity accompanied by marked distension of the head. When the fluid is present in the ventricles of the brain the condition is known as *hydrocephalus internus*, when it is outside the brain, as *hydrocephalus externus*: the latter condition is probably very rare.

Hydrocephalus may be congenital or it may be developed during the early years of life. A good deal of discussion is still going on as to its pathology. The congenital cases are by some ascribed simply to imperfect development of the brain, and by others to meningitis occurring during intra-uterine life. It is probable that in some cases the first of these causes is present, and in others the second. Some writers have also attributed the occurrence of hydrocephalus internus to blocking of the foramen of Majendie, and the consequent retention of cerebro-spinal fluid in the lateral ventricles, but in many cases this foramen has been found not only patent but enlarged, so that this explanation does not apply universally.

**Pathology.**—The most constant pathological condition found in connection with hydrocephalus is one of meningitis, and it is probable that this is the cause in the great majority, both of the congenital and of the acquired cases. The meningeal inflammation is usually dependent either on syphilis or on non-tuberculous posterior basic meningitis. Recovery from the attack of meningitis is followed by the formation of adhesions which block the passage of the cerebro-spinal fluid at the foramen of Majendie, or above or below it, and thus is followed by distention of the lateral ventricles. It has been shown by various investigators, more especially by Dr. Leonard Hill, that the amount of cerebro-spinal fluid is regulated by absorption and exudation from the veins or the lymphatics of the membranes of the brain, more especially towards the base, and if any cause interferes with this normal regulation of the cerebro-spinal fluid, the result on the brain will be very serious. The occurrence of a meningitis interferes with this regulation, so that cerebro-spinal fluid accumulates in the ventricles and gives rise to the condition known as hydrocephalus. These forms of meningitis are more especially present around the base of the brain in the neighbourhood of the fourth ventricle, and thus there is an obstacle to the exit of fluid from the ventricles and to its proper absorption.

**Symptoms.**—The result of the retention of the fluid in the ventricles is an expansion of the cerebral substance which is pressed against the unyielding cranium; atrophy of the brain will gradually occur in consequence. When, however, the affection commences in infancy, the skull expands readily, and thus no marked symptoms of cerebral pressure arise. In older children, however, in whom the skull is rigid, all the symptoms of cerebral pressure follow the accumulation of fluid in the ventricles. The amount of fluid which may collect in the ventricles and in the

posterior sub-arachnoid space in infants is sometimes very large, and the brain itself may be reduced to an extremely thin membrane, the fissures and sulci being completely lost and the various ganglia being flattened out.

*In the congenital cases* and in those commencing during the first year of life, the head becomes enormously enlarged and many of the congenital cases also show other developmental troubles, such as club-foot, hare-lip, etc.: the development of the child is in every way interfered with. The digestion becomes imperfect, there is chronic constipation and emaciation, strabismus and nystagmus are common, the pupils are much dilated, the special senses are usually imperfect and the child very frequently dies during the first year or two of life. Usually as the disease advances there is rigidity and retraction of the head, with convulsions.

*In the acquired cases* developed after the first year of life, the symptoms are more severe because the skull cannot expand with the same rapidity. There are usually marked headaches, cramps, or paralyzes, crying out at night, emaciation, and after a time possibly some separation of the sutures and gradual expansion of the skull. Recovery is comparatively rare, and when it does take place, the brain power is generally greatly enfeebled.

**Treatment.**—Various methods have been employed to cure the disease but hitherto without any marked success. Apart from the medical treatment, which consists essentially in the use of anti-syphilitic remedies—more especially the inunction of mercury—and attention to the nutrition of the child, attempts have been made to prevent the expansion of the skull and to promote absorption of the fluid by compression of the head with bandages. In other cases puncture, either on a single occasion or on several, or repeated tappings have been employed, but very rarely with any beneficial result. Permanent drainage has been resorted to, but as a rule, even although care be taken to restrict the amount of fluid drained away, the result is generally death from pyrexia and convulsions due to the loss of cerebro-spinal fluid. Injections of Morton's fluid have been tried, but also without success.

Following the experiments of Dr. Leonard Hill as to the normal regulation of the cerebro-spinal fluid by absorption and exudation by the veins in the cerebral membranes, Dr. G. A. Sutherland and one of us have made an attempt to restore this normal regulation in these cases by establishing an opening between the lateral ventricles and the sub-dural space, our view being that, if such an opening could be established, the normal regulation of the cerebro-spinal fluid would be carried out by the portions of the meninges which have not yet been affected by pachy-meningitis and that thus we should get rid of the risk due to loss of the cerebro-spinal fluid and also obtain a permanent relief of the pressure instead of the temporary one following drainage. The results of our attempts have been already published in the *Clinical Society's Transactions*<sup>1</sup> and in the *British Medical Journal*.<sup>2</sup>

<sup>1</sup> *Clin. Soc. Trans.*, vol. XXXI., 1898, p. 166. - *Brit. Med. Journ.*, 1898, vol. 1., p. 758.

As regards the results of the procedure, we have found a marked difference between congenital and acquired cases. In the former, in so far as the relief of the brain pressure and the restoration of the normal regulation of the cerebro-spinal fluid are concerned, and the consequent diminution in the size of the skull, our attempts have been extremely successful, but in acquired cases, where the brain is thick, we have found it a matter of extreme difficulty to keep up a channel of communication between the ventricles and the sub-dural space for any length of time.

The operation which we have adopted in congenital cases is as follows: A flap is turned down and a small opening is made in the skull, usually at the upper and anterior angle of the parietal close to the anterior fontanelle. This piece of bone can be readily removed with a trephine or gouge, but in some cases, where the fontanelle has been exceptionally large we have opened the lower angle of the fontanelle itself without removing any bone. The dura mater is exposed, a small incision is made into it about the centre of the flap, and a catgut drain, consisting of about a dozen threads of fine catgut tied together at each end and from two to three inches in length, is introduced in the following manner. One end is seized with a pair of sinus forceps and insinuated downwards and backwards between the brain and the dura mater till about three-quarters of an inch is left projecting from the aperture in the dura mater. The free end of this projecting portion is then seized with the sinus forceps and pushed through the brain into the lateral ventricle. The result is that there is a catgut drain extending from the lateral ventricle into the sub-dural space. The opening in the dura mater is then carefully sutured with catgut and the skin flap re-applied.

As a rule after the operation there is a rapid and marked rise of temperature, even up to 104° or 105° F., but this gradually falls to normal in the course of a week or ten days, and in a very short time signs of diminution in the size of the skull become evident. This diminution goes on steadily to a most striking degree, the skull bones falling in and overlapping one another, and at the base, where the bones cannot fall in to the same extent, a sharp line of rigid bone is usually left. The result in the course of a few weeks is the entire disappearance of the distension of the head and the production of a most curiously deformed small skull.

The results of these attempts have clearly proved the truth of the views as regards the regulation of the cerebro-spinal fluid in the cranial cavity, and, in so far as the part played by the distension of the lateral ventricles in the production of hydrocephalus is concerned, our attempts have led to a complete cure of that affection. Nevertheless in these congenital cases the children have usually died at the end of about four months with symptoms, such as retraction of the head and rigidity, indicating continued extension of the basal meningitis and this in spite of energetic anti-syphilitic treatment.

When one comes to consider the subject of congenital hydrocephalus it is to be feared that the disease unless checked at quite an early period is incurable, and, even if the patients were to live, the brain is usually so badly developed and has been so injured by the pressure that any marked restoration of the cerebral functions can hardly be expected.

When however the brain has developed well and when the condition of internal hydrocephalus develops at a later period, the case is more hopeful. The essential injury here is due to the distension of the ventricles, and the establishment of such a regulation of the cerebro-spinal fluid as is described above is evidently well worth attempting. We have however only had two or three cases belonging to this class and so far our attempts to establish a permanent communication between the lateral ventricle and the sub-dural space have not been successful. The attempts have been made in the same manner as already described in connection with congenital hydrocephalus, namely, by the introduction of a catgut drain of varying thickness between the lateral ventricle and the sub-dural space, and the usual result has been that for the first two or three days there has been marked relief of the symptoms, and that then the drainage has apparently ceased, and the distension of the ventricles has recurred. The probability is that this is due to blocking of the capillary drain by the brain substance, which becomes squeezed in between the strands of catgut; and it seems evident that a capillary drain will not suffice for this condition. In one case Mr. Ballance obtained an excellent result, for a time at any rate, by the introduction of an indiarubber tube in place of a catgut drain, and his case, although it ultimately ended fatally, shows that the principle acts here just as in the congenital cases, and that what has to be found is the best procedure to be adopted. Whether it is advisable to leave an indiarubber tube permanently in the brain is a question which is open to doubt. We propose in any future case employing a decalcified bone tube, the interior of which is filled with strands of catgut, and in this way we shall have a capillary drain protected from the brain substance, and we hope that, as absorption of the bone tube and the catgut goes on, lymph channels will be formed which will suffice to carry on the communication between the ventricles and the sub-dural space. It certainly seems to us that, in these acquired cases, further efforts should be made in this direction.

## CHAPTER VII.

### FOCAL EPILEPSY: TUMOURS OF THE BRAIN.

#### FOCAL EPILEPSY.

A GREAT variety of operations, such as ligature of the vertebral arteries, division of the sympathetic trunk in the neck, etc., have been introduced for the cure of true epilepsy without any very marked benefit.<sup>1</sup> In cases of focal or Jacksonian epilepsy, however, operation is often of great benefit. In these cases the attack usually begins in a definite centre and the muscular spasms follow a definite order, commencing in one group of muscles and extending in regular sequence to others. It may or may not end in a general convulsion, and in some cases consciousness is not completely lost. The irritation appears to radiate from some particular point on the surface of the cerebrum and to extend downwards into its substance.

**Causes.**—A great variety of causes may give rise to this condition. Among these may be mentioned a depressed fracture, in which there is direct pressure by the depressed portion of bone, or by a subsequent osteitis; a localised pachymeningitis, especially the condition known as pachymeningitis interna, or pachymeningitis hæmorrhagica in which hæmatomata form on the surface of the brain; hæmorrhages upon the surface of the brain; cysts pressing on the brain; cicatricial contraction of the brain after operations; adhesion of the brain to the dura or to the skull, as may occur after opening a cerebral abscess; or even adhesion of a cicatrix in the scalp to the bone. The attacks may occur without obvious cause, and may usually be provoked by pressure over the affected area. The attacks may be followed by a certain amount of stupor or coma similar to the ordinary post-epileptic coma, and by temporary paralysis either of sensation or motion, by diplopia, or by other sensory phenomena.

<sup>1</sup>Comparatively recently Jonnesco of Bucharest has advocated the removal of the entire sympathetic chain in the neck, together with the three cervical ganglia on both sides. He claims to have had excellent results from the procedure. We should be inclined to await further information as to the permanence of the benefit before recommending this somewhat severe procedure.

**Treatment.**—The treatment of this form of epilepsy is essentially operative and consists in the removal of any cause of irritation of the cerebral centres. When there is a tender and adherent cicatrix on the scalp, excision of the scar followed by immediate primary union of the cut edges may cure the patient; indeed in some cases, its separation from the bone with a tenotomy knife has proved sufficient. In most cases however the lesion is deeper and it is necessary to open the skull. The precise spot at which the operation should be performed will be determined by the group of muscles in which the symptoms originate (see Fig. 21); additional aid will be afforded by the presence of a scar on the scalp, an irregularity of the bone or tenderness on percussion.

The procedure in these cases will depend upon what is found. Under any circumstances, however, removal of the bone with the trephine is the first thing and it is well to keep the portion of bone removed with the view of implanting it again if that be deemed advisable (see p. 24). When however the bone is thickened and inflamed, such implantation is not advisable, and the mere removal of the circle by the trephine will usually suffice to arrest the condition. When the dura mater is found to be thickened and adherent, the affected portion should be taken away. If the brain be adherent to the dura or to the bone, the adhesions should be separated. If there be a blood-cyst pressing on the surface of the brain, it should be removed.

If there be a cicatrix in the brain itself over the centre in which the disturbance originates, that portion of the brain with the cicatrix should be cut away. Naturally such an excision if extensive will be followed by paralysis, and it becomes a question in any given case whether it is worth the patient's while having a paralysed limb in place of these epileptic attacks. As a rule it will generally be found that it is so, and further, it often happens that some substitution of function takes place and that the paralysis seldom remains permanently complete. As a rule in these cases the tendency is to do too little rather than too much, more especially in the way of removal of bone, cicatrices or adhesions. A point that must be carefully attended to however is to avoid possible subsequent adhesion between the brain and the tissues over it after the operation, for this of course is very apt to occur when portions of the dura mater have to be removed, and, if it does occur, the epileptic symptoms will in all probability recur. Various means have been adopted to meet this difficulty, and the best plan seems to be to introduce between the brain and the skull a sheet of gold-foil (see p. 50); this seems to be non-irritating and to effectually prevent adhesions between the brain and the margins of the dura. Other materials have been employed, such as gutta-percha tissue or oiled silk protective, but after a time these materials become broken up and may act as irritants. The gold-foil seems to act well and to remain permanently in position, and in all operations, both for epilepsy and for the removal of tumours, etc., it is well to make use



of it. Of course under such circumstances it is impossible to replace the bone, because the substratum is non-vascular, and therefore the hole in the skull must be left open.

#### TUMOURS OF THE BRAIN.

**Varieties.**—Masses of new growth may occur in the brain, which may be either true neoplasms or of inflammatory origin, such as those that occur in tuberculous or syphilitic disease; the most common of all are tuberculous masses, the next most common are gliomata, then sarcomata, various cysts and syphilitic gummata. As the differential diagnosis of these conditions is not possible beforehand, it is well to deal with them together. Hence we shall consider not merely the true tumours but also tuberculous and syphilitic masses and the various cystic tumours. Perhaps the most common of the latter are the result of hæmorrhage; besides these there are echinococcus cysts or cysts due to degeneration of tumours. The chief point of value in diagnosing these conditions is the existence of similar disease elsewhere; thus in the case of tuberculous lesions the presence of tuberculous disease elsewhere, with evidence of multiple tumours in the brain, may give an indication of the true nature of the disease; on the other hand, a history of syphilis, evidence of thickening of the meninges, affections of individual nerves, etc., may lead to the diagnosis of a syphilitic gumma. As regards the tumours proper, it is usually quite impossible to predict the true nature of the tumour, but in some cases variations in intra-cranial pressure indicating variations in the vascularity of the tumour may lead one to suspect glioma.

**Symptoms.**—A tumour growing in or upon the brain presents two distinct and definite sets of symptoms. The first set are those common to all intra-cranial swellings and takes the form of increased intra-cranial pressure. This is indicated by such symptoms as headache, vomiting, optic neuritis, and later on coma. The other set of symptoms are localising symptoms due to the seat of the tumour and the destruction or irritation of the part of the brain in its immediate neighbourhood. It is both impossible and unnecessary to go here into the question of the differential diagnosis of the various forms of cerebral tumour or of the localisation of the growth. This would involve a long statement of the present position of our knowledge of the physiology of the brain and for this purpose a separate text-book on the subject must be consulted. All we can do is to indicate the various cortical centres (see Figs. 21 and 22).

**Treatment.—Medicinal.**—As it is very difficult to be certain as to the exact nature of the tumour in the first instance, it is usual to begin the treatment with a course of anti-syphilitic remedies, which should be pushed rapidly and in large doses and should consist not merely in the administration of iodide of potassium but also and more especially in inunction with mercury to the extent required to produce its physiological

effect. If, after a trial of these remedies for three or four weeks, no improvement be found, the probability is that the disease is not syphilitic or, if it be syphilitic, that it is not likely to benefit by anti-syphilitic treat-

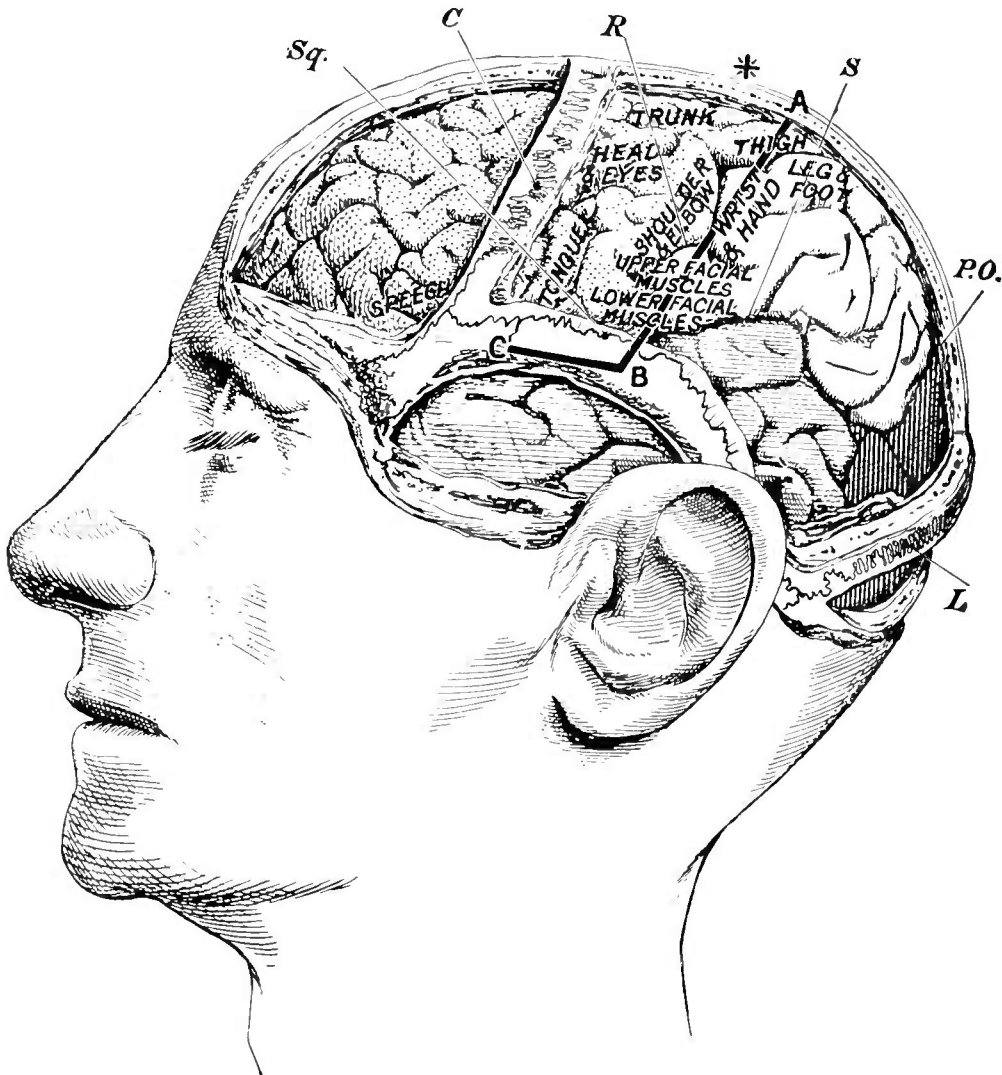


FIG. 21.—THE RELATIONS OF THE VARIOUS CRANIAL SUTURES, CEREBRAL CONVOLUTIONS, AND CORTICAL CENTRES. The line *AB* denotes the main direction of the fissure of Rolando, and is obtained in the following manner. The asterisk \* marks the bregma or central point of the line joining the glabella and the external occipital protuberance. A point *A* is then marked on the scalp 5 centimetres behind this spot, and corresponds to the upper end of the fissure of Rolando. The lower end of the fissure *B* is situated 1 inch behind the point *C*, which is the bifurcation of the Sylvian fissure, and is 2 inches behind and  $\frac{1}{4}$  inch above the external angular process of the frontal.  
*L*=Lambdoid suture. *P-O*=Parieto-Occipital fissure. *S*=Fissure of Sylvius. *R*=Fissure of Rolando. *Sq*=Squamous suture. *C*=Coronal suture. \* = Bregma.  
 The drawing is from a preparation made by Prof. Arthur Robinson of King's College.

ment. Hence the question of possible benefit from operative interference will arise.

**Operative.**—In the early days of localisation and brain surgery great hopes were placed on surgical procedures for dealing with these cerebral tumours. These hopes, however, have not been realised to the extent that one could wish, as unfortunately the great majority of tumours of the brain are not amenable to surgical treatment. In fact, it has been found

by *post-mortem* examination that at most 10<sup>3</sup>%, of tumours of the brain are removable, and in these the operation required would be so serious that a considerable proportion would not recover. Hence, as regards the radical treatment of tumour of the brain, the outlook is distinctly discouraging. In the case of tuberculous tumours, for example, it is usual to find around the main nodule a number of smaller tuberculous masses infiltrating the brain, which will subsequently increase in size and lead to the death of the patient. In cases of glioma there is no capsule, and it is most difficult to decide what is tumour and what is brain substance, and thus early recurrence after operation for glioma is practically the rule. The most favourable tumours are sarcomata with distinct capsules, but even then recurrence is very common. The best results have been obtained in cases of cysts or syphilitic gummata.

*Indications.*—The operative treatment of these cases may have one of two objects; in the first place, when the tumour is small, of slow growth, and superficially placed, the object of the operation is to remove the tumour and presumably therefore to cure the patient; in the majority of cases on the other hand, the tumour is large, very rapidly growing and diffuse or deeply seated and therefore not likely to be removed successfully; the question then arises whether operation may not be undertaken for the purpose of relieving the severe symptoms, such as headache, epileptiform convulsions, etc., which are caused by the increased intra-cranial tension. Much will depend on the urgency of the symptoms and on the probable prolongation of life which will result. When the tumour, while apparently diffuse, deep-seated and beyond the possibility of removal, is not causing very acute or painful symptoms, such as headache or epileptiform convulsions, there is no real object in operating. On the other hand, when the patient is still conscious and is suffering acutely from the pressure of the tumour, his condition will be made much more comfortable by opening the skull freely; and it is just possible that the tumour may be found to be of such a nature or in such a situation that it may be removed.

*Methods.*—The actual steps of the operation for removal of a tumour of the brain are as follows. In the first place, *the scalp should be completely shaved the night before the operation and thoroughly disinfected* in the manner already described (see Part I., p. 161). It is then necessary to mark out upon the scalp the chief localising points and the supposed area of the tumour in its relation to the convolutions. The important convolutions to mark out are those in front of and behind the fissure of Rolando, and there are various ways in which the position of this fissure may be ascertained. The principal points are the glabella at the root of the nose, the external occipital protuberance, the bregma half-way between these, the external angle of the orbit and the tip of the mastoid process.

*The methods of localising the Fissure of Rolando.*—The upper end of the fissure of Rolando is situated about five centimetres behind the bregma and it runs downwards and forwards, forming an angle with an antero-

posterior line between the glabella and the occipital protuberance of about 67°. It is about three and three-quarter inches long. Any variation in

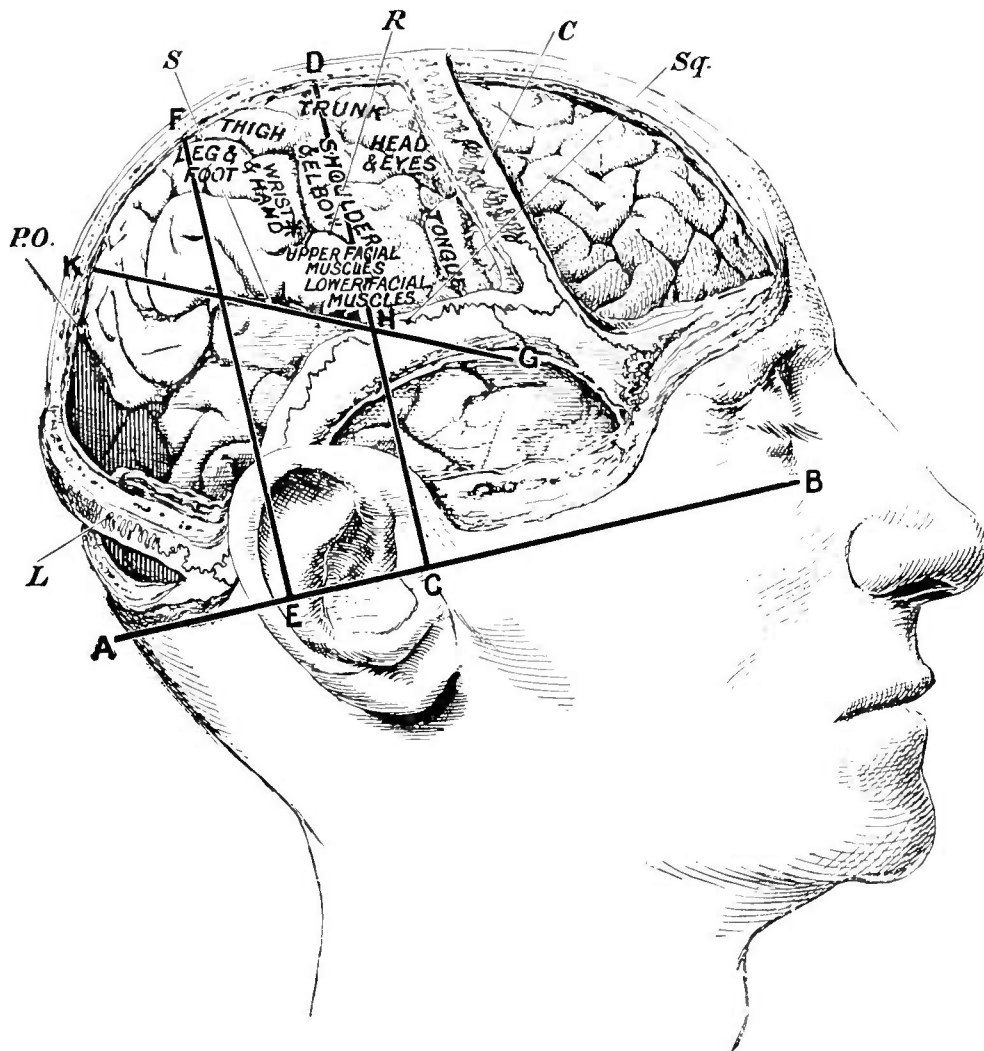


FIG. 22.—REID'S METHOD OF CEREBRAL LOCALISATION. *AB* is Reid's base line, and runs from the lower margin of the orbit backwards through the centre of the external auditory meatus. From this two lines are drawn upwards at right angles, one, *CD*, from the depression just in front of the ear to the middle line of the skull (from the glabella to the ext. occip. protuberance) and the other, *EF*, from the posterior border of the mastoid process to the same line. The line *GK* indicates the horizontal limb of the fissure of Sylvius, and runs from a point  $1\frac{1}{4}$  inch directly behind the external angular process of the frontal, to another point  $\frac{3}{4}$  inch below the parietal eminence. The point *K* at which this line meets the middle line of the skull, localises fairly accurately the mesial end of the Parieto-Occipital sulcus. The fissure of Rolando corresponds mainly to a line drawn from *F* to *H*, the point of intersection of the fissure of Sylvius with the vertical line *CD*. The bifurcation of the Sylvian fissure lies about  $\frac{3}{4}$  inch behind *G* on the line *GK*, and the vertical limb runs upwards from that point for about 1 inch.

*L*=Lambdoid suture. *P-O*=Parieto-Occipital fissure. *S*=Fissure of Sylvius. *R*=Fissure of Rolando. *Sq*=Squamous suture. *C*=Coronal suture.  $\wedge$ =Parietal eminence.

The drawing is from the same preparation as that used for Fig. 21.

its direction, which is not uncommon, is usually so slight as not to affect the operation because the trephine hole is large enough to include these variations. Various methods have been introduced with the view of localising the fissure. One of the first was Reid's method in which what is known as Reid's base line was drawn round the head from the orbit

to the external occipital protuberance (see Fig. 22). Two lines are drawn at right angles to this, one running upwards just in front of the external auditory meatus and the other running upwards from the posterior border of the mastoid process. The direction of the fissure of Rolando is from the junction of the upper end of the latter line with the antero-posterior line, down to the point of junction of the anterior vertical line with Reid's line marking out the horizontal limb of the Fissure of Sylvius which is a line drawn from a point  $1\frac{1}{4}$  inches directly behind the external angular process of the frontal to another point  $\frac{3}{4}$  inch beneath the parietal eminence.

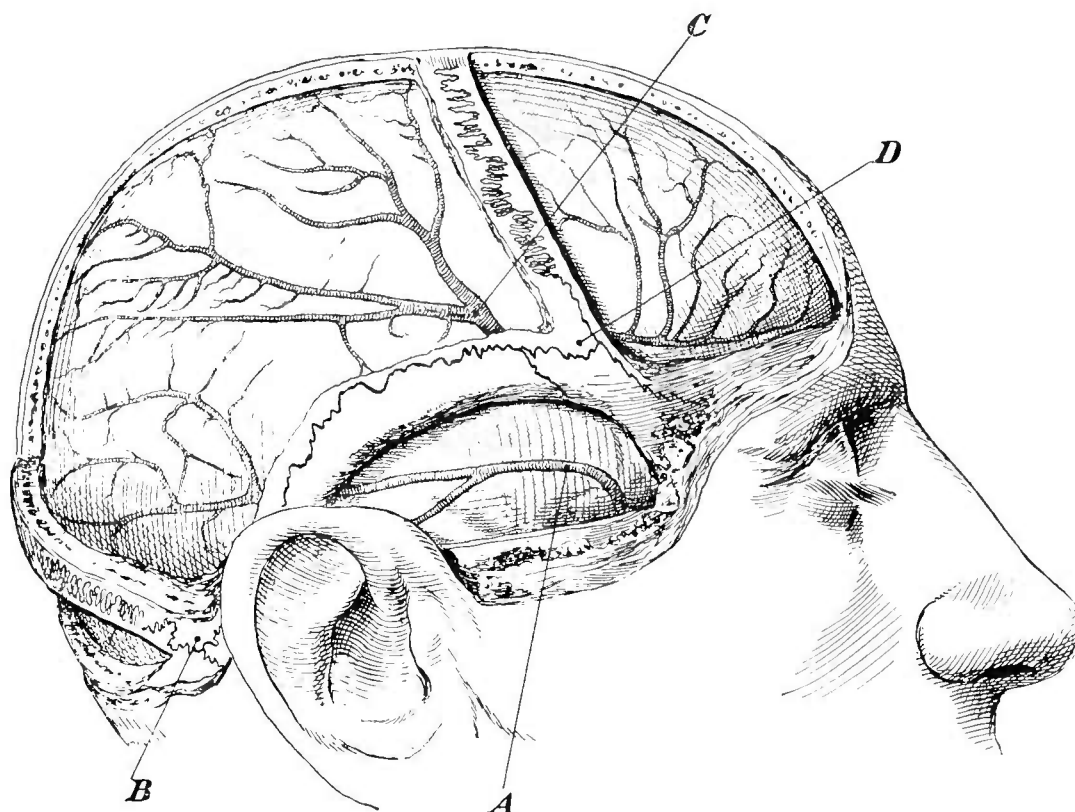


FIG. 23.—THE RELATIONS OF THE MIDDLE MENINGEAL ARTERY TO THE SUTURES OF THE SKULL.

*A* = Posterior branch of the middle meningeal. *C* = Anterior branch. *D* = Anterior inferior angle of the parietal bone. *B* = Posterior inferior angle of the parietal.

The drawing is made from a preparation by Prof. Arthur Robinson of King's College.

One of the easiest methods of locating the fissure of Rolando is by using the simple instrument suggested by Professor Horsley--the so-called "Rolandometer" (see Fig. 24). This is made of flexible metal so that it can be easily sterilised and adjusted to the surface of the skull. When the long limb is placed over the antero-posterior line of the skull with the smaller angle ( $67^\circ$ ) looking forward and the point of junction of the two limbs about 5 centimetres behind the bregma, the shorter limb will indicate sufficiently accurately the direction of the fissure. This arm is graduated so that the length of the fissure can be marked off on the scalp. Should this instrument not be available, a very easy means of replacing it is that suggested by Professor Chiene. He takes a square piece of paper and folds it diagonally so as to make a triangle whose lesser angles are  $45^\circ$

One side of this triangle is then folded back on to the base so that its angle is reduced to  $22\frac{1}{2}^{\circ}$ . This folded-down portion is cut away and the remainder of the paper is unfolded and forms a trapezium one of whose angles is  $45^{\circ} + 22\frac{1}{2}^{\circ}$ —that is to say  $67\frac{1}{2}^{\circ}$ . The paper is then placed with one side of this angle along the middle line of the skull, and its apex 5 centimetres behind the middle of this line, that is to say it is applied over the upper end of the fissure of Rolando. The other edge of the paper runs downwards and forwards at an angle of  $67\frac{1}{2}^{\circ}$  and thus indicates the line of the fissure. The fissure being three and three-quarter inches in length, the lower end of it can also be marked out.

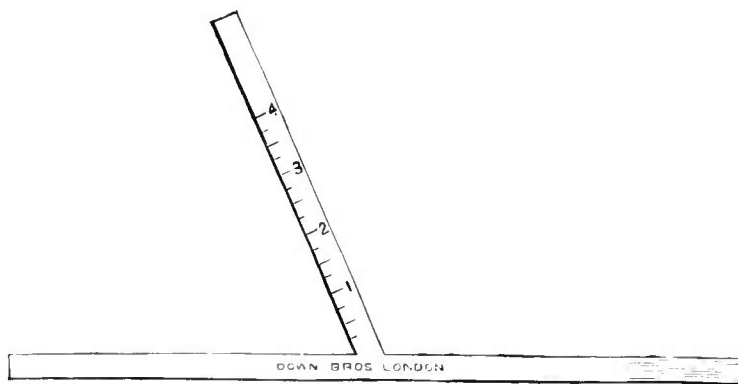


FIG. 24.—HORSLEY'S "ROLANDOMETER." The graduated limb is set at an angle of  $67^{\circ}$  to the other, which is placed along the vertical line of the skull from the root of the nose to the ext. occip. protuberance. The point of junction of the two limbs is applied 5 centimetres behind the centre of this line, so that the graduated limb slopes downwards and forwards; it then lies over the fissure of Rolando.

The position of *the fissure of Sylvius* may also require localising. Its bifurcation corresponds to a point two inches behind and about a quarter of an inch above the level of the external angular process of the frontal bone, and is situated just beneath the point of junction of the parietal, the great wing of the sphenoid, the frontal and the squamous bones. The anterior branch runs upwards and forwards beneath the line of the sphenoido-squamous suture and forms the anterior boundary of the so called motor region. Figs. 21 and 22 will show the relation of the convolutions to these fissures as well as the relation of the various centres.

Before disinfection it is well to mark out these lines on the scalp by means of nitrate of silver, a solution of thirty grains to the ounce being painted along the lines and allowed to dry, and when dry lightly brushed over with a solution of pyrogallic acid (five grains to the ounce). The characteristic silver stain is produced and is not washed away when the scalp is subsequently purified, as is the case with marks made with an aniline pencil.

Chloroform is the best *anæsthetic*, because it causes least congestion of the brain and, as suggested by Professor Horsley, it is advisable to administer a *hypodermic injection of morphine* (gr.  $\frac{1}{2}$ ), about half an hour before the operation is commenced. After the skin has been purified, it

is well before proceeding further to transfer the markings on the scalp to the skull by driving a fine bradawl or drill through the scalp into the skull at various points along the lines marking out the fissures and the supposed area of the tumour. *A large crescentic incision* is then made so that the opening in the bone shall lie in the centre of the flap, which must be large enough to permit of the removal of sufficient bone to fully expose the tumour. Before making a large flap of this kind it is well to compress its base so as to prevent loss of blood; when the incision is large it may be worth while to apply elastic tubing tightly round the skull, from the root of the nose in front and beneath the external protuberance behind. The incision is then carried down to the bone and the pericranium is raised with the flap. There is usually very little danger to the vitality of the flap, because the base is large, but it is always well to plan it so that the main vessels shall enter the base.

After the flap has been turned aside to some extent, the tourniquet should be released and the various bleeding vessels clamped. When the flap is large, the assistant can usually compress the greater part of the edge between his fingers, leaving a portion uncompressed, in which the surgeon rapidly clamps the vessels; another portion of the flap is released by the assistant and the vessels clamped, and in this way the loss of blood is reduced to a minimum. When the flap has been fully reflected and the hæmorrhage stopped, *the skull is opened*. The marks made by the bradawl are first identified and the amount of bone to be removed is decided upon. In some cases it is sufficient to make a single large trephine hole and then to enlarge the opening with Hoffman's forceps. This is however generally very tedious, especially when there is a large tumour, and in that case four small trephine holes should be made at what will be the angles of the opening, and these are then connected by means of Hoffman's forceps, or by a Hey's or a Gigli's saw<sup>1</sup> (see p. 38). The simplest of all, if it be obtainable, is a circular saw worked by an electric or a hand motor; this has the additional advantage that the incisions are made with great rapidity. If it be hoped to complete the operation at one sitting, the portions of bone removed may be kept either under the scalp (see p. 22), or in boracic lotion at a temperature of 100° F., with a view to replacing them at the end of the operation, but if, as is usually the case, the operation be divided into two stages, there is of course no necessity for doing this. The above method of opening the skull is applicable to the majority of cases met with in practice. There will rarely be any chance of replacing the bone and therefore the most rapid method of making a large enough opening will be the best. Occasionally, however, especially in small and non malignant tumours it may be possible to remove the tumour entirely, and it then

<sup>1</sup> If a Gigli's saw be used a thin copper spatula must be inserted between the dura mater and the saw after the latter is in position. Unless this be done, the under surface of the wire saw, which cuts as freely as the upper, will wound the dura, as the intra-cranial tension is sure to press it up against the saw.

becomes a point of great importance to close the defect in the skull. This is dealt with more fully later on (see p. 94).

*Operation in two stages.*—After the bone has been removed, the dura mater will bulge into the opening and will be somewhat yellowish in colour and devoid of pulsation. When this stage of the operation has been reached the surgeon will have to determine whether he will proceed with the remaining steps of the operation—*i.e.* the removal of the tumour—at once or defer them to another day. At any rate, before opening the dura mater he must see that the amount of skull removed is sufficient for the purpose of obtaining free access to the tumour, and, if the latter be at all large, it will generally be advisable to stop the proceedings at this stage and to complete the operation another time. In that case the flap is put back in place again, a few stitches are inserted, the ordinary dressings are applied, and the patient is put back to bed. The importance of dividing these operations into two stages depends on the fact that the shock and the loss of blood accompanying them are usually very great, so that, by the time the dura mater is exposed and examined, the patient is considerably collapsed; if to this be added the shock occasioned by interference with the brain and the loss of blood involved in the removal of the tumour, the patient may succumb upon the table. Hence the general rule will be to return the patient to bed and wait for a few days before proceeding with the further stages of the operation. When the operation is merely performed with the view of relieving pressure, the exposure of the dura mater of course ends the operative procedures.

*Opening the dura mater.*—After an interval varying, according to the condition of the patient, from four to ten days after the first operation, chloroform is again administered after a preliminary injection of morphine. The same precautions are taken as before with regard to asepsis, and every possible means of minimising shock is adopted (see Part I., p. 139). The sutures are removed, the flap turned down and the dura mater exposed. The latter should be opened so as to form a flap which is turned upwards. A small incision is made into the dura, about half an inch from the edge of the bone, and then, with a pair of blunt-pointed scissors, the incision is carried round parallel to the edge of the opening in the bone (see Fig. 14). Several small blood-vessels will probably be divided, but they can usually be seized and ligatured as they are cut; when the incision runs across large vessels it is well to under-run these with a small Hagedorn needle and tie them before they are divided (see Fig. 12). All hæmorrhage from the dura should be stopped before going further. It is well to avoid the use of any irritating lotion, and the only fluid that should be brought in contact with the dura mater or the brain should be either warm sterilised salt solution (see p. 29) or boracic lotion, preferably the former.

*Removal of the tumour.*—The brain is carefully examined, and if there be a tumour upon the cortex it will generally be manifest at once. If it be beneath the grey matter, the convolutions will be flattened and will present



a characteristic dull yellowish appearance, while the affected area gives a distinct feeling of resistance as compared with the healthy brain around. The removal of the tumour will vary much in difficulty according as it is situated upon the cortex or in the depth of the brain, and also according as it is encapsuled or diffuse. If the tumour be not felt at once, a blunt searcher may be passed into the brain in its supposed direction to see if it comes in contact with any firmer tissue, and if so, the convolutions can be split with a brain knife (see Fig. 25) or a spatula carefully introduced at right angles to the surface, so as to minimise injury to the vessels which run at right angles to the surface; then with the finger the tumour can be gently separated from the brain and shelled out. The bleeding, which is generally venous, and is due to tearing of the large veins which lie upon the surface of the brain, may be profuse at first; if it be at all alarming, pressure with a hot sponge for a few minutes will generally arrest it. Should any vessels of large size be divided, they should be tied or twisted. In the superficial and encapsuled growths it is generally easy to make out the demarcation between the tumour and the brain substance, and the former may be enucleated without much



FIG. 25.—HORSLEY'S BRAIN KNIFE. This is really a delicate spatula.

damage to the brain. In the softer tumours it is almost impossible to decide, even with the aid of touch, which is tumour and which is brain. In any case the sense of touch is preferable to attempts to ascertain the limits of the tumour by a blunt instrument, and therefore the finger should be employed to work round the growth in all directions.

When the tumour is found to be irremovable, it must be either left alone or portions of it may be removed. The latter procedure has little or no effect in retarding the progress of the disease and may even cause serious danger from hæmorrhage, but in some cases it may be advisable; for instance, the bulging of the brain may be so great that the dura mater cannot be united, nor the skin flap properly stitched, unless portions are removed. When a growth has been partially or entirely removed, a cavity is left which will rapidly fill, partly with blood and partly also by expansion of the vascular brain substance beneath. The bleeding generally stops on the application of pressure with a hot sponge, but in some cases it is advisable to pack the cavity for two or three days: in fact, some surgeons advocate that the cavity in the brain should always be packed with gauze. The bleeding, if troublesome, is most effectually controlled by gauze soaked in a sterilised antipyrin solution. A suture or two should be passed through the lips of the wound in the scalp where the packing emerges and the ends knotted loosely together: they are tied finally when the packing is discontinued, which is usually in about 48 hours. The objection to packing is that it must necessarily leave a hole in

the dura mater which cannot be subsequently closed, but this is minimised by stitching up as much of it as possible, so that the packing emerges only at one corner.

In the majority of these cases there is no question of replacing the bone ; for instance, if the operation be done in two stages, some days must elapse, and the bone is no longer alive. When the conditions are such that there is every prospect of the recovery of the patient, the question arises of how to guard against the danger entailed by the large defect in the skull. The mere implantation of fragments of decalcified bone over the surface of the dura mater is of little use, as that generally only leads to a little extra thickening of the fibrous tissue. Plates of aluminium, gold, or silver have been applied over the orifice and have healed in, but as a rule the most that can be done is to apply a moulded plate of silver or aluminium outside the scalp after the healing of the wound.



FIG. 26.—CRANIAL CHISEL. This instrument is provided with a shoulder to prevent injury to the dura mater. It can be introduced along the dotted line shown across the base of the osteo-plastic flap in the succeeding figure, and made to divide it. The shoulder is introduced between the dura and the bone. A chisel with a shoulder at each end of the cutting edge is sometimes used ; the object of this is to avoid damage to the soft parts over the bone in the same way that damage to the dura mater is avoided.

*Osteo-plastic procedures.* Some surgeons have advocated the use of an osteo-plastic flap, which has great advantages in cases where the tumour is to be removed ; a great objection is, however, the additional length of time which the operation takes and the difficulty in cutting the flaps. It is obvious that such a procedure can be employed only comparatively rarely, as it demands, in order to render the prolongation of the operation justifiable, the accurate diagnosis and localisation of a small and easily accessible tumour. If an osteo-plastic flap is to be employed, the scalp should be retracted only for about a quarter of an inch all round the edge of the incision, and then, with a Heys or a circular saw, the bone should be divided along the line of the incision in the soft tissues, that is to say in a semicircular form ; the division of the bone should be oblique from without inwards, so that the opening through the inner table is smaller than that through the outer, and the cut surface presents a bevelled edge ; if the flap of bone be replaced it will not sink into the skull. The difficulty is in cutting the base of the flap of bone : the bone is usually too thick to break easily, and, indeed, the attempt might cause a fracture of the skull. Probably the simplest procedure is to make a trephine hole on each side and pass a Gigli's saw beneath the base and partially saw the bone until it will bend or break. A chisel (see Fig. 26) slipped under the scalp to divide the bone is rather objectionable on account of the shock caused by the percussion of the hammer.

A somewhat easier plan of cutting an osteo-plastic flap is shown in

Fig. 27. It is done by making trephine holes at the angles of the bone-flap after turning the scalp aside to a small extent, and then clipping out vertical grooves between these holes. In this way a trench is formed, which is connected with its fellow along the top of the bone-flap by means of a saw-cut carried very obliquely through the two tables of the skull, lest the flap of bone when restored to place may fall in and press on the brain. The base of the bone-flap is divided as above. Where a bone-flap is employed, the entire flap should be turned down and kept out of the way until it is replaced at the end of the operation.

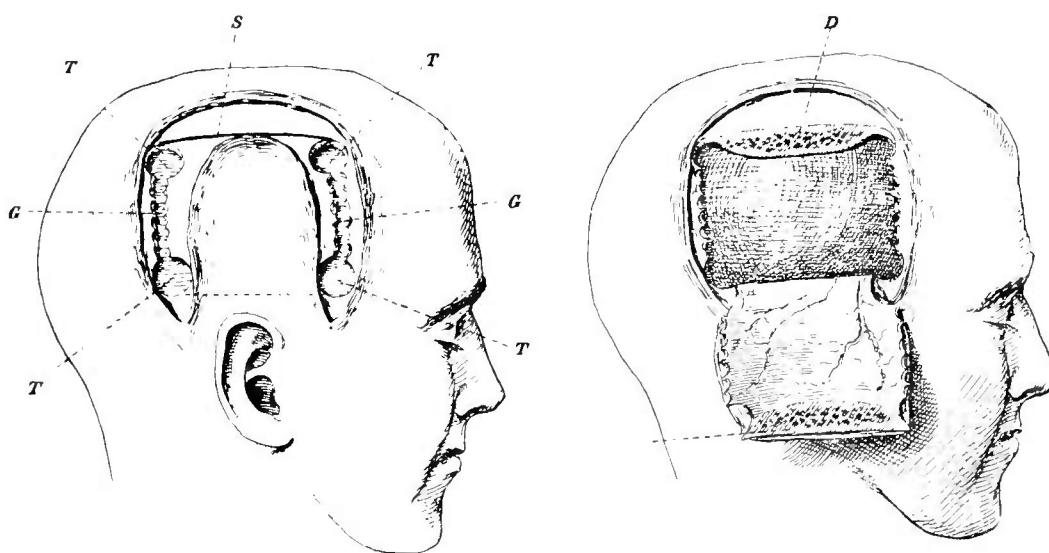


FIG. 27.—A METHOD OF FORMING AN OSTEO-PLASTIC FLAP IN OPERATIONS UPON THE BRAIN. The usual curved incision is made through the scalp. The square of bone to be turned down is then marked out by incisions through the pericranium along its superior horizontal and two vertical sides. The pericranium and the soft parts are retracted on either side of these lines, and four trephine holes, *T*, are made, one at each corner of the square. The upper hole on each side is connected with the corresponding lower one by a trench, *G*, made by Hoffman's forceps (see Fig. 6), a parting tool (see Fig. 13), a centre-bit, or by a series of overlapping trephine holes. The two upper trephine holes are now connected by a horizontal saw-cut, *S*, which is made with a circular or a Hey's saw held very obliquely to the surface of the skull. It now only remains to divide subcutaneously the base of the osseous flap across the dotted line. This may be done with a Gigli's wire saw (see Fig. 10), or the chisel figured above. In *B* the flap is turned down. The bone, retaining its full connection with the flap of soft parts unites well, and there is no tendency for it to slip into the cranial cavity, as the bevelled edge of the upper side of the aperture, *D*, forms a shelf for it to rest upon. In *A* the skin-flap appears small relative to the size of the bone-flap. This is because the scalp is retracted towards the centre as the bone incision is being made; it expands later.

In all these cases of removal of a tumour it is well to introduce between the surface of the brain and the skull a piece of gold-foil (see p. 71) in order to prevent adhesion of the brain to the skull.

*After-treatment.*—The after-treatment does not present any points of special importance. The shock resulting from the operation must be combated by appropriate measures, care being taken, however, not to employ alcohol. The patient must be kept perfectly quiet in a darkened room and must not be disturbed by noises or by the visits of friends. Restlessness must be met by mechanical restraint of the head and, if necessary, injections of morphine. After two or three days the dressings should be changed, and any packing or drainage tube removed.

## SECTION II.—AFFECTIONS OF THE FACE.

### CHAPTER VIII.

#### WOUNDS, INFLAMMATORY AFFECTIONS, ULCERS AND NEW GROWTHS OF THE FACE.

##### WOUNDS OF THE FACE.

THE only special points in connection with wounds in this situation are the æsthetic considerations involved in the question of scarring, and also the possibility of injury to the various important structures about the face, of which the chief are the facial nerve and Stenson's duct.

Wounds of the face heal with remarkable rapidity and are therefore less prone to septic complications than are those in many other parts of the body; the resulting scar is also much less unsightly than might be anticipated. At the same time, however, these wounds are specially liable to become attacked by erysipelas, which may spread to the scalp and may lead to the most serious complications from thrombosis of the diploic veins or the cerebral sinuses.

**Treatment.**—The chief point to be considered, apart from risk of infection common to all wounds accidentally inflicted, is the cosmetic result, and, with this end in view, the greatest care must be taken to remove any dirt that may have gained access to the wound and which might therefore cause suppuration and unsightly scarring; in the second place it is important to reduce stitch-marks to a minimum.

Under certain circumstances, even more care must be taken in the primary cleansing of the wound than is necessary for the mere avoidance of sepsis. Wounds on the face are not uncommonly caused by falls upon metallic or other substances which may be ground into the tissues and cause discoloration or tattooing of the parts. In some cases this may be so marked that it is necessary to excise the discoloured scar in order to get rid of the disfigurement. Hence under all circumstances the greatest care

must be taken to clean the wound thoroughly and to remove any foreign body from it; in the cases of which we have spoken it may even be necessary to remove a portion of the edges of the wound. This procedure has the advantage that, besides removing the colouring matter, it at the same time favours healing by first intention.

*Suturing.*—The question of how best to avoid stitch-marks has already been discussed (see Part I., p. 154). By the employment of the subcutaneous suture there described, reinforced by the use of strips of gauze fixed on the skin with collodion, the edges may be brought into accurate apposition without any stitch-marks being left. Should the condition of the wound demand the introduction of ordinary skin stitches, these should consist of the finest horsehair and should be introduced with a very fine Hagedorn needle close to the margin of the wound. Only the fewest possible stitches should be introduced, the approximation of the intermediate portions of the wound being effected by strips of gauze (see Part I., p. 154).

When the wound is contused, it is often better not to introduce stitches at all, or at most to employ only one or two to keep the edges in fair apposition, the actual approximation being effected by the strips of gauze referred to above. Outside the wound a small gauze dressing should be fastened on with collodion; if there be much oozing, a larger dressing may be fastened on outside this with a bandage for the first 24 hours, after which it may be left off and the small collodion dressing alone employed.

**Complications.**—*Bleeding* from these wounds usually stops either spontaneously or after very gentle sponge pressure or douching with iced water, and it is only necessary to apply a ligature when the larger vessels are wounded. *When the facial nerve has been divided* it is difficult to repair the injury unless the nerve has been cut before it breaks up into branches. These branches are delicate filaments which it is practically impossible to find or to unite, and the best that can be done under the circumstances is to bring the edges of the wound as accurately together as possible, in the hope that some of the divided filaments may thereby be brought into apposition and may unite. The other important complication, namely, *injury to Stenson's duct*, will be treated of separately in connection with the injuries to the parotid gland.

#### SYPHILITIC AFFECTIONS OF THE FACE.

The face is a favourite seat of syphilitic lesions, which may be met with in all the stages of the disease.

**Primary** sores may occur about the lips or the eye-lids, while **secondary** syphilitic eruptions are common on the forehead in the neighbourhood of the hair. **Tertiary** syphilitic lesions, either in the form of a nodular syphilide or gummatous disease, are frequently met with about the forehead and the nose. The *gummata* are most common in connection with disease of the frontal bone, and there is usually also ulceration of the skin over them.

The nose is a favourite seat both of acquired and congenital syphilis. This may be either a nodular syphilide of the skin or a gumma of the bones : in the latter case necrosis takes place, and as a consequence the bridge of the nose is flattened, the tip is turned upwards, and a most unsightly deformity is produced. Gummata may also occur in the tissues over the cartilage of the tip of the nose, leading to ulcers, which, however, generally yield readily to anti-syphilitic treatment, and leave only scars, or possibly some deformity about the margin of the nostril.

Nodular syphilides are the cause of widespread destruction of the nose. The affection commonly commences about the tip of the organ, which is very rapidly destroyed, and the diagnosis in early cases is difficult. The affection is apt to be confounded with lupus, the chief points in the diagnosis being the greater rapidity of the syphilitic lesion, the absence of the characteristic apple-jelly nodules, the larger size of the tubercles, and the extension of the disease to the bones. In advanced cases the bony structures of the nose may also be destroyed, so that all that is left of the organ may be an oval opening in the face. When this happens, there is extension of the disease along the nasal cavity, with destruction of the vomer or perforation of the hard palate.

**Treatment.**—The treatment of the *primary and secondary lesions* presents no points of difference from that already recommended for the disease in general (see Part I., Chap. XII.). The *gummatous form of the disease affecting the frontal bone* has also been dealt with in connection with diseases of the skull (see p. 34).

The *nodular syphilide of the nose* is usually arrested readily enough by the administration of large doses of iodide of potassium, combined with mercury, which is preferably employed by means of inunction. This form of the disease is more important in that it spreads with great rapidity and the deformity is irreparable ; therefore large doses of these drugs must be administered from the first so as to bring the patient as rapidly as possible under their action.

#### TUBERCULOUS AFFECTIONS OF THE FACE.

These may occur in one of three forms—as tuberculous ulcers of the skin, as lupus, or as an intermediate condition between the two, often described under the name of “scrofuloderma.”

##### **TUBERCULOUS ULCERS OF THE SKIN OF THE FACE.**—

These usually occur either in connection with tuberculous glands in front of the ear or more frequently as a secondary result of tuberculous disease of one of the facial bones, such as the malar or the orbital margin of the superior maxilla. In the latter cases the skin becomes fixed to the bone when the ulcer heals, and the traction may interfere with the movements of the lower eyelid, or may even lead to very unsightly ectropion.

**Treatment.**—Whenever an abscess forms it should be opened, scraped,

injected with iodoform and glycerine emulsion (see Part IV., p. 120), and stitched up. When there is an ulcer situated over diseased bone, the former should be scraped and the latter should be removed. As soon as the surface thus left is healthy, it should be skin-grafted (see Part I., p. 50). Any skin adhering to the bone should be freed, the scar excised, and the edges of the wound sutured. When there is marked eversion of the lower eyelid, the ordinary operation for ectropion should be performed; this is described under the plastic surgery of the face (see Chap. XII.).

**LUPUS.**—*Lupus vulgaris* is the most common tuberculous lesion of the face. It occurs chiefly upon the cheeks or the tip of the nose and presents wide variations in virulence. Thus, it may sometimes occur as *lupus non-exedens*, characterised by scars covered with branny scales without ulceration, or as *lupus exedens*, in which there are nodules that coalesce, ulcerate and become covered with scabs, beneath which is found soft tuberculous material. The ulceration in *lupus exedens* is sometimes slow, but sometimes on the other hand it may be so rapid that the special name of *lupus vorax* has been applied to it; the probability is, however, that this form is a combined condition of epithelioma and lupus, and that has been so in all the cases with which we have had to deal. *Lupus hypertrophicus* is not so common on the face.

The disease may last for years and is very intractable; unless its ravages be checked, it may cause the most distressing deformities. It begins with the deposit of one or two nodules in the skin, around which fresh nodules develop, and these, according to their type, may or may not ulcerate. On the face, the disease spreads to the skin but does not penetrate for any distance into the subcutaneous tissues. On the nose, however, the tubercles penetrate deeper and destroy the cartilages, so that after a time the cartilaginous portion of the nose may be entirely lost. The nasal bones are never affected and the bridge remains intact; this serves to distinguish the condition from syphilitic destruction of the nose. The disease may spread from the nose to the lips and into the nostrils. Apart from the unsightly sores and scars and the destruction of tissue, the lupous ulceration gives rise to other deformities which are both unsightly and serious, such as ectropion, contractions about the lips which distort the mouth, or narrowing of the orifices of the nostrils, so that the patient is unable to breathe properly.

**Treatment.**—The various methods of treatment of lupus are (1) excision, (2) scraping followed by the application of caustics, (3) injections into the nodules, (4) the application of ointments or plasters, (5) exposure to concentrated sunlight or electric light, and (6) the internal administration of drugs. Most of these methods have been already referred to (see Part II., p. 153), and we need therefore only say a few words as to the cases for which each method is most suitable.

**Excision.**—In very early cases, when there is only a small patch consisting of two or three nodules, the ideal treatment is to excise the affected area by including it in an oval incision and subsequently to bring the edges of the

wound together with subcutaneous sutures (see Part I., p. 154). This method may give a perfect result, the disease being entirely removed and the scar in a short time becoming quite unnoticeable. Unfortunately, cases seldom come under the care of the surgeon at such an early date, but the practitioner should always be on the look-out for the chance of cutting short the disease in this satisfactory manner.

Excision is also of value when the disease is more extensive; if it be carried wide enough it cures the disease absolutely and with far less scarring and deformity than is likely to result from any other method. Hence we do not limit excision to those early cases in which the edges of the wound can be brought together. Even in extensive cases of lupus of the cheek it is often possible to excise the patch and to fill the gap left by raising a flap of skin from the neighbourhood. This is done on the lines described for the plastic surgery of the face (see Chap. XII.). The result is that, instead of having extensive scarring and probably a persistent disease, as is so common after the treatment by other methods, all that is left is a few linear scars which in time become inconspicuous.

Even when the patch is so large as to contra-indicate the plastic operation, the results of excision are likely to be much better than those that can be obtained by other methods—with the possible exception of the “light-bath” treatment which is still on its trial—because Thiersch’s skin-grafts can be applied immediately to the surface left by excision, and, if these be cut large enough, the scar resulting is very much superior to that obtained by any method followed by cicatrisation. It is advisable that the grafts be applied immediately to the wound because there is then less contraction than if granulation be allowed to occur before the grafts are used. The best dressing for these cases is the quarter-strength boracic ointment spread very thickly on butter-muslin and fastened in position with gauze and collodion. This is better than fastening on the dressing with a bandage, because the latter is apt to be displaced by the movements of the head, and this will almost certainly entail mechanical detachment of the grafts—an accident that is especially liable to happen in children.

We have treated many cases of facial lupus of all degrees of severity in this manner, and we have been very much pleased with the results obtained. In order to be successful, the excision must be carried freely beyond the edge of the disease and well into the fat beneath. The chief point in the technique is to obtain a level surface upon which to place the grafts. In order to do this the blade of the knife should be kept horizontal as the skin is being raised. We have lately found that the operation is much facilitated by substituting a razor for the ordinary scalpel.

The bleeding generally stops from the mere exposure to the air. Should any trouble be experienced in arresting it, the larger vessels should be twisted and the oozing surface douched with iced water or, if that fails, alternately with that and water at a temperature of 110° Fahr. It is very difficult to stop the bleeding by pressure as recommended for grafting in other situations



(see Part I., p. 51) on account of the anatomical conformation of the parts. The larger the grafts are cut, the fewer are the lines of junction between them, and therefore the less is the subsequent deformity. We have found that the grafts almost invariably unite perfectly well except when the raw surface reaches the margin of the nose or the mouth, in which case the nearest graft may possibly slough.

**Scraping and cauterisation.**—This is an excellent plan when the lupous area consists of scattered patches with small areas of sound skin between them. Excision is then practically out of the question as it would entail the sacrifice of a large amount of healthy skin ; moreover, in ordinary cases, when the affection is of very great extent, excision may be deemed inadvisable, and this method is then valuable. In the first place, all the soft tissue should be scraped away with a largish sharp spoon and then one of the smallest size should be employed to bore into any soft patches where the lupus nodules have extended deeper. The entire affected area must be gone over carefully step by step and every individual nodule must be scraped out. The bleeding is arrested by cold and pressure and the raw surface is then cauterised with pure nitric acid. This is painted on with a glass brush and allowed to soak in thoroughly. The best plan for introducing the acid into the small depressions left after scraping out isolated nodules is to insert into them a fine pointed glass rod dipped in the acid. Special care must be taken to cover the patient's eyes so as to prevent the fumes of the acid affecting them. As a rule the application of the caustic provokes bleeding from the larger vessels, and this necessitates precautions designed to prevent the acid being washed by the blood over the skin and burning it. Any bleeding thus caused should be checked by pressure with a sponge, and when this is done, fresh nitric acid is applied. The cauterisation should last for about ten minutes and then the surface may be thoroughly douched with a solution of carbonate of soda.<sup>1</sup> This is poured over the cauterised area until all effervescence ceases, after which a piece of boracic lint dipped in the same solution is applied for a few hours, when it is replaced by boracic fomentations which are renewed frequently until the surface begins to granulate. Boracic ointment is then employed. When a large area is thus treated, the granulations should be scraped away at the end of about a fortnight and the raw surface skin-grafted in the usual manner.

*Results.*—As a rule this method does not succeed in completely eradicating the disease. In the course of some months further nodules appear in the scars and necessitate further scrapings. Still, if the main part of the affection be destroyed in this manner, the spread of the disease and the deformity consequent on it can be readily enough kept under by treating fresh nodules in a similar manner as soon as they appear.

**Injection.**—The injection of half a minim of undiluted carbolic acid into the substance of a lupus nodule will effectually destroy it, and this method is

<sup>1</sup> The strength of this solution is immaterial ; a handful of carbonate of soda (ordinary washing soda may be used) in a pint of water is most convenient.

most useful when the nodules are quite isolated, as they often are around or over the scars of previous operations, and where it is not worth while to subject the patient to the operation of excision.

**Ointments and plasters.**—Of the various ointments which are employed for this affection, the chief is that known as *Unna's salicylic and creosote plaster*, which has already been fully described (see Part II., p. 154). This method is most useful in lupus non-exedens, where the affection is not amenable to scraping and the deformity is not usually so great. The plasters may also be advantageously employed when a few isolated nodules of lupus are present, and especially when they are scattered over a scar which has been the seat of previous operations. Perhaps the most useful function of the plasters is that they may be used as a test to ascertain whether the disease has been completely eradicated. They are applied over the suspected scar, which if healthy is not affected, but, if the seat of lupus, shows breaking-down areas as a result of their action.

**Light-baths.**—At the present time extensive trials are being made of the continuous application of concentrated light deprived of heat-rays to the lupous area, and the results so far obtained are certainly very remarkable. The question which still awaits an answer is whether the results thus obtained are permanent. There seems to be no question that the disease disappears in a very extraordinary manner, and the scar left is very good. Should the permanent results be as good as the temporary ones, this plan will probably supersede all the others to which we have referred. It must, however, be some time before the method can come into anything like general use, as the apparatus required is costly, and can only be employed under very favourable circumstances.

**Drugs.**—The old plan was to administer cod-liver oil, syrup of the iodide of iron, and so on, which are of no specific value. Improvement has been noted in a number of cases from the use of *thyroid tabloids*, and hence these may be employed in most cases. Their action is, however, extremely variable. *Arsenic* also seems to be useful in some forms of the disease, particularly in the nose.

#### INFLAMMATORY AFFECTIONS.

There are no special points concerning the acute inflammations of the skin and subcutaneous tissues of the face.

**ERYSIPELAS.**—The face is the most common seat of the so-called "medical erysipelas, in which no definite point of entrance of the micro-organisms can be made out. The principal point of importance is that erysipelas of the face has a great tendency to spread to the scalp, and there is always, therefore, the risk of acute inflammatory processes in that region.

**Treatment.**—This does not differ in any way from that already described for the affection in general (see Part I., p. 218).

## TUMOURS OF THE FACE.

**SEBACEOUS CYSTS.**—These are not uncommon, and on the face the wall of the cyst is much thinner than it is in those occurring on the scalp.

**Treatment.**—The method of removing them has been already fully described (see Part II., p. 161). To avoid unnecessary scarring, the incision should always be planned so as to lie as far as possible in the natural folds of the cheek. Injury to the facial nerve is not at all likely to happen if the superficial part of the cyst wall be properly defined, and the soft parts separated from the rest of the wall with a blunt dissector.

**DERMOID CYSTS.**—These occur chiefly about the outer angle of the orbit, the line of the inter-maxillary cleft, the middle line in front, or some times in the thickness of the cheek. The cysts about the external angle of the orbit, which are the commonest, may communicate with the interior of the skull through an aperture in the frontal bone, but they are always external to the dura mater.

**Treatment.**—More care is required to avoid the branches of the facial nerve than is necessary in the case of sebaceous cysts. The incision over the tumour should be parallel to the branches of the nerve, and, as soon as the cyst wall is reached, the rest of the separation should be done with a blunt dissector, and the cyst removed unopened.

**NÆVI.**—These tumours are very common on the face, and naturally call for treatment both from the discoloration they cause when the nævus is superficial and from the swelling when the tumour is of the venous variety.

**Treatment.**—When the nævus is quite small and fairly superficial, *excision* will probably give the best result and leave the smallest scar. The incision should, if possible, be made parallel to the branches of the facial nerve, and, if feasible, along one of the natural folds of the skin. If, however, the tumour be large, excision is not so satisfactory. Under these circumstances it is best to apply *ethylate of sodium* (see Part I., p. 268) to the superficial portion of the tumour and to treat the deeper part by electrolysis.

For the large, deep-seated venous nævi of the cheek *electrolysis* is by far the best method of treatment, as excision or cauterisation cannot be employed, partly because of the possibility of injury to important structures and partly on account of the scarring which would result. The method of employing electrolysis has been already detailed in full (see Part I., p. 266).

“*Port-wine stains.*”—Perhaps the most troublesome nævoid condition on the face is that produced by the so-called “port-wine stains,” and the disfigurement may be so great as to call urgently for treatment. When the growth is of any size, the best plan is to employ a combination of electrolysis, painting the surface with ethylate of sodium and passing a fine silk thread steeped in undiluted carbolic acid through the skin by means of a round needle.

## MOLES.

Moles are very frequently met with upon the face, and are often a considerable source of annoyance to the patient. They may vary in size from a small pea up to a pigmented area larger than the palm of the hand. They are very frequently partially or entirely covered with hair.

**Treatment.**—This has already been fully described (see Part I., p. 163). Should the patient desire to be relieved of the pigmentation, the only method open is to perform *excision*. If the mole be small and the incision suitably planned, the edges of the wound may be brought together by buried sutures (see Part I., p. 154), and the resulting scar may be quite unnoticeable. When the mole is too large to allow of this, Thiersch's skin-grafts should be applied to the raw surface, taking care to cut them as large as possible. The slight scarring resulting from this will, of course, be far less noticeable than the pigmentation due to the mole.

In other cases the patient desires not so much the removal of the pigmentation as to be freed from the presence of hairs upon the mole. Under these circumstances the plan suggested by Mr. Horsley may be adopted with advantage if the mole be large and thickly covered with hair (see Part II., p. 163). It consists in turning down a flap consisting of the skin upon which the mole is, and then shaving away the deep surface of the flap with a razor until the hair follicles are cut away. The flap is then replaced in position, the hairs fall out, and no further growth of them will occur; of course, this method leaves the pigmentation untouched.

When the mole is small and only covered by a few hairs, a method which is also valuable for superfluous hairs upon the upper lip in females may be employed. This consists of the employment of electrolysis; for the following details of the procedure we are indebted to Dr. Arthur Whitfield:

“The battery should consist of dry or Leclanché cells coupled in series. It is seldom that more than ten cells are required for any operation, but if there are eighteen, the battery may also be used for the production of anæsthesia by cataphoresis when necessary. A galvanometer reading in milliamperes is also a necessity. The needle used varies with the taste of the operator; the platino-iridium needle has the obvious advantages that it may be easily sterilised in the flame, it may be bent to any angle that may prove convenient at the time and it is not likely to be broken by the sudden movement of a nervous patient. For all purposes a needle bent at an angle of  $45^\circ$  at a distance of one-third of an inch from the free end is most convenient. The base of the needle may be an octagonal, hollow, metallic cylinder fitting directly on to the terminal of the lead as recommended by Brocq. This arrangement obviates the use of a heavy needle-holder and is far the most convenient for manipulation in awkward situations such as beneath the chin. The indifferent electrode is usually a large metallic cylinder covered with wash-leather

and moistened with salt solution. A lens is usually of advantage and none is more efficient than an ordinary watchmaker's glass.

"The patient should be in a semi-recumbent position on a couch in a good light. The positive electrode may be laid on a piece of mackintosh on the patient's lap, so that she may grasp it when required. Five cells are then put in circuit and, while the indifferent electrode is lying loose on the patient's lap, the needle, attached to the negative pole, is introduced into the neck of the follicle. The direction of the needle should be parallel to that of the hair. In this position, with no current flowing the sense of touch will inform one, after a little experience, whether the needle is entering the follicle or attempting to pierce the skin. The patient is then instructed to firmly grasp the positive electrode and the strength of current as indicated by the galvanometer noted. For the first trial, a strength of about one milliampère is sufficient. After a few seconds, bubbles of hydrogen will be seen issuing from the mouth of the follicle and shortly afterwards a somewhat yellowish transparent zone will appear around the mouth of the follicle. This is the zone of total necrosis; immediately it appears the patient must be instructed to drop the positive electrode. This yellowish zone should never be allowed to gain a diameter larger than that of a small pin's head, otherwise the scar left will be manifest to the naked eye. The needle is now withdrawn and after a moment or two the hair may be pulled very gently with epilation forceps. If the operation has been successful, the hair will slide out of the follicle without offering the slightest resistance and will bring with it the macerated and gelatinous-looking inner root-sheath. If the hair is not loosened, the current must be increased for other hairs, but it must never pass four milliampères for even the stoutest. A medium strength for the chin is about  $2\frac{1}{2}$  milliampères while  $1\frac{1}{2}$  will usually suffice for the upper lip. As regards the time during which the current should be passing, from 5 to 15 seconds will generally suffice. On no account must hairs be taken during one sitting which are so close that their respective zones of necrosis must touch.

"It is better never to introduce the electrode for a second time into a follicle when the first application has failed to loosen the hair. The needle is sure to run down the false passage made on the first introduction and it is practically certain to leave a visible scar. The number of hairs which may be taken on one occasion naturally varies with the coarseness and distribution of the hairs; one may however take 40 as an average number.

"After the operation is finished the patient may be given some lead or calamine lotion to cool the part, but nothing will hasten the healing of the damaged areas. The natural sequence of the after effects is as follows: Immediately on the completion of the operation the part is somewhat red and shiny to the eye and hard to the touch, while there are numerous little yellowish dots indicating the mouths of the follicles. The œdema passes off in one or two hours and the yellow dots dry up into scabs within the first

twenty-four hours, forming dark brown crusts which show rather more than the original marks. These crusts fall off in about three days and the process is practically complete with the exception of possibly a little redness. Patients differ a good deal in the rapidity with which their skins recover the normal appearance, and for those who have a tendency to pustular acne it is a safe plan to prescribe frequent dabbing with a one in four thousand lotion of perchloride of mercury to prevent infection of the destroyed follicles. It is wiser not to exceed this strength, as sublimate lotions have a tendency to stimulate the growth of hair.

“From this it will be seen that the same area may usually be gone over twice in one week but on no account oftener.

“As regards the patient's sensations, if the electrode is not grasped until after the needle is well engaged in the follicle and is dropped before the needle is withdrawn, the pain is not great, and is usually described as irritating rather than severe. The chin is usually far less painful than the upper lip and the centre of the latter is much more sensitive than the outer parts.

“It should be remembered that the patient would prefer to have a hair return and let it be destroyed on another occasion to being marked with a permanent scar. It is therefore wise to err on the side of too weak rather than unnecessarily strong currents. With care and experience, however, even with the use of very moderate currents relapses should not be more than one per cent.

“It is, however, advisable in the case of young women in whom the growth of hair is obviously progressive, to be careful in explaining that the treatment does not prevent the growth of hair in other parts of the skin, and that, until either all the hair is destroyed or the progressive growth stops, the treatment will have to be renewed from time to time.

“For the destruction of small hairy moles the method of procedure is almost identical. Owing to the facts that the hair is almost invariably stronger and that a scar must necessarily result from the destruction of the mole it is usual to work with a stronger current (5 milliamperes). All the hairs in the mole should be first carefully removed, and after a few days, if the mole has not been entirely effaced in the process of destroying the hairs, the needle may be run through it in various directions and the current passed until the whole growth looks white and tensely distended with the gas. The result is a perfectly even, white scar, somewhat smaller than the original growth.

“Where the patient demands an anæsthetic for these small operations the following method of introducing cocaine through the unbroken skin by cataphoresis may prove useful.

“A 10% solution of cocaine (the alkaloid itself, not the hydrochlorate) in pure guaiacol is used. A piece of clean blotting paper is soaked in the solution and placed on the area to be anæsthetised and a suitably shaped incorrodible electrode is placed on the top of it. This electrode is connected with the positive pole, and a current of about four or five milliamperes passed

for five minutes or so. Fifteen cells will probably be required at first, but the resistance soon diminishes and then some may be switched off. A pricking sensation is felt at first, but this soon passes off and is followed by complete anæsthesia to pain. The anæsthesia passes off in about a quarter of an hour. The only objection to this method is the penetrating odour of the solution. In rare cases anæsthesia is not produced at the end of five minutes, and it has been found to be advantageous in such cases to reverse the current after this time."

**MALIGNANT TUMOURS.**—These form the most important group of tumours on the face, and may be either sarcomatous or carcinomatous in nature. The former present no special points of interest, and do not differ in any way from sarcomata elsewhere.

**Carcinomata.**—Various forms presenting points of special interest occur upon the face, which is one of the common seats of the very slow-growing **flat epithelial carcinoma**, which is not infrequent in elderly people. This generally commences in some small pigmented seborrhœa patch or in a pigmented mole, but it may sometimes occur without any antecedent disease of the skin.

**Treatment.**—The treatment of this form is satisfactory, as, if it be removed freely, a perfect recovery may ensue, with an insignificant scar. Glandular infection occurs very late in the disease.

Another form is the **tuberous epithelial carcinoma**, which usually starts at the junction of the mucous membrane with the skin, most frequently in connection with the lower lip. This form will be referred to more in detail in connection with affections of the lips (see Chap. X.).

**Rodent ulcer.**—A third form of epithelial carcinoma frequently met with on the face is the so-called rodent ulcer. The characters of this growth have already been referred to (see Part II., p. 164). When occurring on the face it is usually extremely slow in growth and may lead to widespread destruction of the bones and may ultimately cause the death of the patient by affecting the dura mater and so favouring septic meningitis, or by leading to hæmorrhage or to attacks of inflammation such as erysipelas.

**Treatment.**—The treatment here, as elsewhere, is early excision, which apparently is successful if care only be taken to go sufficiently wide of the growth. In the face this generally entails filling up the gap by means of a plastic operation or by Thiersch's skin-grafting.

When the disease is too far advanced for a complete excision to be feasible, the best plan is perhaps to combine with excision of such portions as are accessible the application of some strong caustic such as *nitric acid* in a similar manner to that for lupus (see p. 101) or better still the employment of *chloride of zinc paste* or *sulphuric acid*.<sup>1</sup> As a rule nitric acid is inferior to sulphuric in that it does not eat far enough into the tissues to destroy the growth. In applying caustics such as these to a growth in the vicinity of the

<sup>1</sup> For details as to the composition of these caustics and their method of application, see Part II., p. 164.

base of the skull, where the bone is thin, great care must be taken not to cause sloughing of the dura mater and septic infection. Whatever caustic be used it should be allowed to act for several hours at least, as its action must extend deeply to be of any use. Boracic fomentations should be applied to facilitate the separation of the sloughs caused by the caustic, and, when granulation is complete, the healing may be hastened by the application of skin-grafts. Careful watch must however be kept to see whether any fresh thickening or ulceration occurs, in which case immediate destruction of the affected area by caustics or the knife must be resorted to. Sometimes the tumour is so large that the defect left requires a very extensive plastic operation (see Chap. XII.); failing that, a suitably coloured celluloid or wax shield must be modelled to hide the deformity.

It is said that the *light-bath treatment* for lupus has also a very beneficial effect upon rodent ulcer. We only mention the matter here, as it is a question that is still *sub judice* and upon which no definite opinion can well be pronounced.



## CHAPTER IX.

### FRACTURES OF THE NASAL BONES.

**CAUSES.**—This injury is practically always caused by direct violence; sometimes however it may be the result of an extensive fracture of the anterior fossa of the base of the skull. Fracture occurs more often in adults than in children, in whom the nose is more yielding. The fracture is usually compound through the mucous membrane and is not uncommonly comminuted. The injuries may be very varied; one bone alone may be broken but usually both are fractured and separated from each other. In other cases the fracture may involve the nasal processes of the superior maxillæ. In badly comminuted cases the fracture usually also runs through the perpendicular plate of the ethmoid or the lachrymal. Lastly, the nasal bones may be dislocated from the cartilages, and it is not uncommon for bending or even dislocation of the cartilaginous septum to occur.

**DISPLACEMENTS.**—The resulting deformity is of course greatest in comminuted fracture, in which the bridge of the nose may be so depressed that it is very difficult to restore it to and retain it in position. In many cases the nose is displaced laterally, while in others there is comparatively little displacement. The swelling is often so great as to mask both the displacement and the crepitus.

**COMPLICATIONS.**—These fractures as a rule are unaccompanied by complications, but when there is severe damage the following conditions may be met with:—

1. *Epistaxis.*—Bleeding from the nose is constant, but is usually only slight. If however one of the larger vessels be ruptured, there may be considerable and persistent hæmorrhage, which sometimes necessitates plugging of the nostrils.

2. *Emphysema.*—Escape of air into the tissues about the orbit or the forehead and bridge of the nose is not uncommon and is due either to injury of the nasal duct or to a free opening through the mucous membrane of the nostril communicating with the cellular tissue. The emphysema is usually developed when the patient attempts to blow his nose. It generally subsides spontaneously and seldom gives rise to any trouble.

3. *Epiphora*.—Epiphora, or the overflowing of tears, usually occurs in connection with fractures of the lachrymal bone accompanied by injury of the lachrymal sac, or, on the other hand, it may arise from fracture and blocking of the nasal duct.

4. *Cellulitis* and suppuration about the nose very rarely follow fracture of the nasal bones.

**Treatment.**—Apart from the question of the complications, a fracture of the nasal bones calls for careful treatment because, if left to itself, considerable deformity may result either from flattening of the bridge of the nose or from lateral displacement of the organ, and these deformities are difficult to remedy at a later stage. The most difficult condition to rectify is displacement of the cartilaginous septum.

**Of the fracture.**—In ordinary cases unaccompanied by displacement there is little or no treatment required. The first point is to be quite sure that there is no displacement—which the swelling is very apt to mask; should none be present, the application of an ice-bag externally or even syringing the nose with ice-cold water to check the bleeding and the effusion will be all that is required. The patient must be specially cautioned against touching his nose or attempting to blow it. The patient often finds it very difficult to resist doing this because of the irritation set up by the fracture and the accumulation of blood.

If there be depression of the bridge or lateral displacement of the nose, it is essential to replace the bones as soon as possible, and for this purpose it is well to administer an anæsthetic. It is not at all advisable to wait for the subsidence of the swelling or even for the hæmorrhage to cease, because repair takes place with extreme rapidity, and the deformity, unless remedied at once, may be very difficult to correct at a later period.

*In the case of lateral displacement of the nose*, the deformity is usually readily remedied by pushing the nose back into position. A little manipulation over the bridge will usually get the nasal bones into their proper relative positions, after which the nose must be examined to see that the septum is in place; if not, it must be put back. When the bones are replaced, there is no great tendency to subsequent displacement. No appliance for keeping the bones in position is required as a rule. The patient should lie on the side opposite to that towards which the displacement has occurred and a small ice-bag should be placed on the nose. This will check the effusion of blood and its weight will tend to keep the bones in position. The patient should be seen daily at first, and the surgeon should see that the displacement does not recur, and should remedy it at once if it does. In five or six days the bones will be fairly firm, but the patient should still be forbidden to handle or blow the nose.

*When the septum has been displaced*, special attempts must be made to get it into position, and this is sometimes very difficult; as a rule this displacement does not occur in connection with the lateral dislocation. In some cases the septum can be pushed into its proper position by intro-

ducing a narrow, thin spatula into the nose. In others this is impossible, and it is then best to use special forceps (see Fig. 28) by which a good hold is obtained of the cartilage and by means of which it can be forcibly twisted into position. In these cases the deformity of the septum is apt to recur, and it is well therefore to introduce a plug (see Fig. 29) into the nostril encroached upon by the displaced septum and to retain it in position for some days until the septum is found to retain its position. The best plugs are made of vulcanite, and are hollowed out so that the patient can breathe through them. At the anterior ends of the plugs are holes for threads which are fastened on the cheek with strapping. These plugs are better than packing, which is not so efficient and may cause great inconvenience from the obstruction of the nostril. The plugs should be taken out twice a day for cleaning, the nose washed out with weak boracic lotion, and the plugs greased with boracic ointment and replaced.

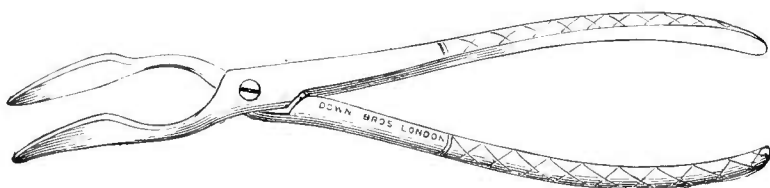


FIG. 28.—FORCEPS FOR STRAIGHTENING THE NASAL SEPTUM.

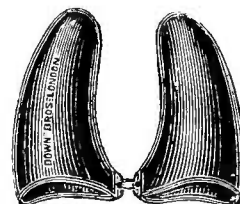


FIG. 29.—NASAL PLUGS.

*In comminuted fractures with depression*, the restoration of the bones is much more difficult, and their retention in position requires a great deal of care. Manipulation externally may first be tried, but it is generally necessary to introduce some instrument into the nostril to push out the bones. It must be remembered that the space between the nasal process of the superior maxillary bone and the septum is very narrow, and, therefore, in order to push out the bones properly a very narrow instrument only can be used; to attempt to do it with ordinary dressing forceps is quite futile. A pair of fine sinus forceps, a curved probe-director, or still better a narrow spatula should be employed. This is introduced into each nostril alternately, and with it the fragments are gradually pushed up into position with the assistance of the fingers applied externally. The retention of the fragments in position is however a very difficult matter. It may be done by packing the nostril with cyanide or iodoform gauze in very narrow strips applied with a fine firm probe. The great objections to this method are that the packing is very difficult to apply owing to the narrowness of the nostril, that in a very short time it becomes foul, and therefore must be frequently renewed, and that this removal is very apt to be followed by recurrence of the displacement: in any case it is a cause of great pain to the patient.

When, therefore, the fragments will not remain in position of themselves, it is better to use some external appliance, such as a metal band round the forehead, from which two arms project furnished with pads, which can be applied one on each side of the bridge of the nose, and braced together

so as to replace the fingers and keep the nasal bones firmly pressed in position. Mason practised a very simple method of keeping up the bridge in bad cases by passing one or more hare-lip pins from side to side through the nose beneath the fragments. These pins project on each side for about half an inch, and a good firm cork is pushed over each projecting end (see Fig. 30). The two pieces of cork on each pin are then pushed together, so as to exercise lateral pressure on the nasal bones, while the pin prevents the bridge from falling back. In many ways this is a more satisfactory arrangement than the apparatus just mentioned, because, while applying lateral pressure, it also prevents the bones falling back. In any case, no apparatus need be continued for more than three or four days, for by that time so much lymph and new material will have been thrown out, that the fragments of bone will remain in position if care be taken not to blow the nose or to disturb it in any way.

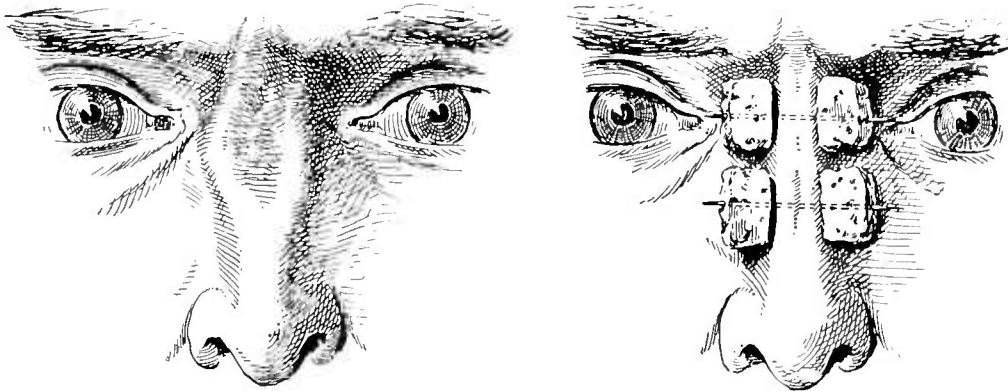


FIG. 30.—MASON'S METHOD OF SUPPORTING THE BRIDGE OF THE NOSE AFTER FRACTURE. The diagram shows how, after the flattened bones have been got into position and the bridge has been restored, the pins support the bones, and the lateral pressure of the pieces of cork keep them inclined at an angle to one another. If the cork becomes loose, a figure-of-eight suture can be applied over all.

**Of complications.**—The treatment of the various complications of this fracture presents few features of importance. The *bleeding*, even though severe, can usually be checked by affusion of cold water over the face, by syringing the nostrils with ice-cold water, or by the application of a small ice-bag to the side of the nose (*vide supra*). If the bleeding really be alarming—sometimes it may be if the nasal artery be divided—it may be necessary to plug the nares. To do this, the plugs must be carefully introduced and packed in place with a firm probe, taking care not to push in too large a mass at once, and by means of them the bridge of the nose will to some extent be supported. The strips of gauze should be impregnated with iodoform and pushed well up into the upper part of the nose.

If *emphysema* be present, it requires no special treatment beyond taking care that the nostril on the affected side is kept clear by repeated syringing with warm boracic lotion, and at the same time the patient should be cautioned not to blow the nose. The emphysema will then readily subside and give no further trouble. The treatment of *epiphora* will be mainly directed, on the one hand, to careful re-position of the fragments, and on the

other to keeping the nasal duct open by means of the regular introduction of suitable probes. If *cerebral injury* be present, the case must be treated on the lines laid down for fracture of the base of the skull (see p. 28), the fracture of the nasal bones being then of secondary importance: care should nevertheless be taken to remedy the deformity.

*Compound fracture* in this situation is not, as a rule, accompanied by serious symptoms. The healing takes place very readily, and it is but seldom that septic infection gains a foothold or that necrosis of the fragments occurs. When the fracture is compound through the skin, the wound should be purified in the ordinary manner, and special care must be taken to prevent the strong lotions from getting into the eyes. The edges of the wound should be brought together as accurately as possible by means of fine horsehair sutures. *Should the wound become septic*, large boracic fomentations should be employed, combined with frequent douching of the nasal cavity with warm boracic lotion.

**Of long-standing deformity.**—The surgeon is sometimes consulted with regard to old cases of fracture of the nose, in which there has been considerable loss of substance or marked depression, or in which coal-dust or other material has been ground into the soft parts leaving an unsightly or pigmented scar. The latter condition has already been referred to (see p. 96). The possibility of remedying the permanent deformities of the nasal bones frequently requires very careful consideration. At an early period it may be possible, by introducing a fine chisel through small incisions in the skin, to chisel through the bones at the line of fracture, and, when they have been properly loosened, they may be brought into position by lateral pressure—either by the hare-lip pins or by the pads on each side of the nose mentioned above. In other cases however the fracture is of such long standing that the deformity cannot be remedied in this way. When the bridge of the nose is much depressed, the tilting forward of the nostrils is of itself so unsightly that a more elaborate operation must be performed, similar to that employed for cases in which the bridge of the nose has been lost from disease. These operations will be more conveniently considered in connection with the plastic surgery of the face (see Chap. XII.).

## CHAPTER X.

### AFFECTIONS OF THE LIPS.

#### WOUNDS OF THE LIPS.

THERE are few points of special interest in connection with wounds of the lips. As in the rest of the face, healing is rapid and satisfactory.

**Treatment.**—When a wound extends through the whole thickness of the lip, the greatest care must be taken in bringing the edges together to see that the red line is on the same horizontal level throughout. The sutures used for the skin should be of fine horsehair, whilst in the red portion of the lip fine catgut may be employed, and it is well to suture the whole of the wound on the mucous surface with the same material. No dressing is really required; at most a thin layer of salicylic wool fastened on by collodion. The discharge rapidly dries up and a scab is formed, under which healing takes place quite readily. When there has been much loss of substance of the lip some form of plastic operation will be necessary (see Chap. XII.).

#### INFLAMMATORY AFFECTIONS OF THE LIPS.

There is little of importance to say concerning these affections. *Gangrene* of the lips which sometimes occurs is usually the result of cancrum oris, a disease already described (see Part I., p. 80).

**CRACKS AND FISSURES OF THE LIPS** are not uncommon in cold weather and are sometimes troublesome as sources of septic infection, whilst they also cause great inconvenience to the patient from their constant liability to be torn open.

**Treatment.**—If the lips be kept well anointed with glycerine, and a little goldbeater's skin be applied over the crack to protect it from cold and from irritants, the affection will usually heal.

**HYPERTROPHY OF THE LIPS.**—In weakly children of the tuberculous type very marked thickening and overgrowth of the lips,

especially the upper, with eversion of the red line is often seen as a result of chronic inflammation in the nature of a lymphangitis following upon the presence of these cracks and fissures. It may also result from excoriation of the skin of the upper lip in children who suffer from chronic coryza. Although it is commonly met with in tuberculous children there is in all probability no actual deposit of tuberculous material.

**Treatment.**—When this condition is noticed very great care must be taken to protect any excoriations or cracks from injury and to heal them as rapidly as possible (*vide supra*). When the fissure is deep, it may be actually advisable to excise it and bring the edges together with fine catgut stitches so as to insure immediate union. At the same time of course, the general condition of the patient must be attended to and the administration of cod-liver oil, iron, etc., with light nourishing food and general attention to hygienic measures is of great help.

In some rare cases the thickening of the lip may reach such an advanced stage that the surgeon is called upon to remedy the deformity. If this be the case, improvement can be readily effected by excising a horizontal strip of the thickness of the lip from its inner aspect. An elliptical incision is made upon the mucous surface of the lip enclosing an amount of the mucous membrane varying in breadth according to the amount of deformity. The upper border of the incision should run parallel to the red line, enough of the mucous membrane being left between the two to represent the normal thickness of the lip. As the incision is deepened, the portion removed is gradually made narrower, so that ultimately the piece excised resembles a segment of an orange, the outer surface of which corresponds to the mucous surface of the lip. The bleeding is usually slight and in any case is readily arrested by torsion. The edges of the incision are brought together by two or three fine catgut stitches and healing is rapid. The general medicinal measures referred to above must be adopted.

#### TUBERCULOUS AFFECTIONS OF THE LIPS.

Tuberculous ulcerations may be met with either in the mucous membrane or in the skin, and they may take the form of lupus or of the ordinary tuberculous ulcers.

**LUPUS** is chiefly met with on the upper lip as an extension from a similar affection upon the nose or cheek.

**Treatment.** This has already been fully discussed (see p. 99), and we need not further refer to it.

**TUBERCULOUS ULCERS** are occasionally met with upon the mucous membrane of the lips, generally the lower, which resemble in all respects those occurring on the tongue. Like that affection they may occur as a primary disease unaccompanied by tuberculous mischief elsewhere; much more commonly they are secondary to advanced tuber-

culous disease, either of the lungs or the larynx. They gradually extend in area and are usually excessively painful.

**Treatment.**—When the ulcers are small and shallow, the most satisfactory treatment is to *excise the ulcer* and bring the edges of the mucous membrane together with fine catgut. This can be done without an anæsthetic by painting the affected surface over with a 20 per cent. solution of cocaine. Should the raw surface thus left be too large to bring together by stitches, it may be touched with undiluted carbolic acid; a mouth-wash of sanitas (three drachms to the pint), or chlorate of potash (10 grs. to the oz.) should be frequently employed during healing, whilst the treatment for the original tuberculous disease is vigorously proceeded with.

When however the ulcer is secondary to tuberculous mischief in the lungs or larynx, the raw surface thus left is very apt to be infected after excision, and under these circumstances it will be better to avoid operation and merely to treat the ulcer locally. In some cases a 20% solution of *lactic acid* painted over the surface of the sore once a week is of great advantage. It relieves the pain and at the same time promotes rapid healing. The value of this treatment is still further increased if the sore be previously scraped with a sharp spoon, which may be done after anæsthetisation with a 20% solution of cocaine.

When the sore is still more extensive and the chief symptom requiring treatment is the pain to which it gives rise, *orthoform* powdered freely over the surface will often relieve it. A similar result may of course be obtained by painting the surface with *cocaine*, but, if the surgeon be obliged to fall back upon the use of this drug, it is important to remember that tolerance to its action is more or less rapidly established, and therefore the solution employed in the first instance should be a weak one (2 per cent.) and should be used as seldom as possible. Care must also be taken that all hard articles of diet, hot and cold substances and more particularly acid or alcoholic liquids are avoided.

#### SYPHILITIC AFFECTIONS OF THE LIPS.

These may be met with in all stages of the disease, but the most common are either a primary sore or, more frequently, secondary mucous patches.

**PRIMARY SORES.**—The chief importance of the primary sore is its recognition, as it is not only of course a great danger to other persons by infection from kissing or even from the use of the same cups, spoons, etc., but it may be mistaken for a malignant growth and removed under that impression.

**Treatment.**—As it is of the greatest importance to obtain rapid healing of a sore in this situation, the patient should be brought under the influence of mercury by one of the more rapid methods such as



inunction (see Part I., p. 233). Healing may also be expedited by dusting the sore with a powder of one part of calomel to three of starch. Should the sore be painful, the best plan is to rub its surface over with solid nitrate of silver.

**MUCOUS PATCHES.**—The chief secondary affections of the lips are mucous patches, which occur most frequently about the angles of the mouth, and on the mucous surface. In the former situation especially, these patches are apt to ulcerate and give rise to irregular ulcers which are extremely painful.

**Treatment.**—This is practically the same as for the primary sore just described; in the more painful cases the use of the solid nitrate of silver is of especial value. Here also the patient must be strongly cautioned as to the infective nature of the condition.

#### TUMOURS OF THE LIPS.

**NÆVUS.**—The lip is sometimes the seat of extensive, subcutaneous, venous nævus causing great swelling and deformity which are difficult to treat. It is more common in the upper than in the lower lip.

**Treatment.**—The best methods are either electrolysis or injection. In either case too much must not be done at one sitting, owing to the

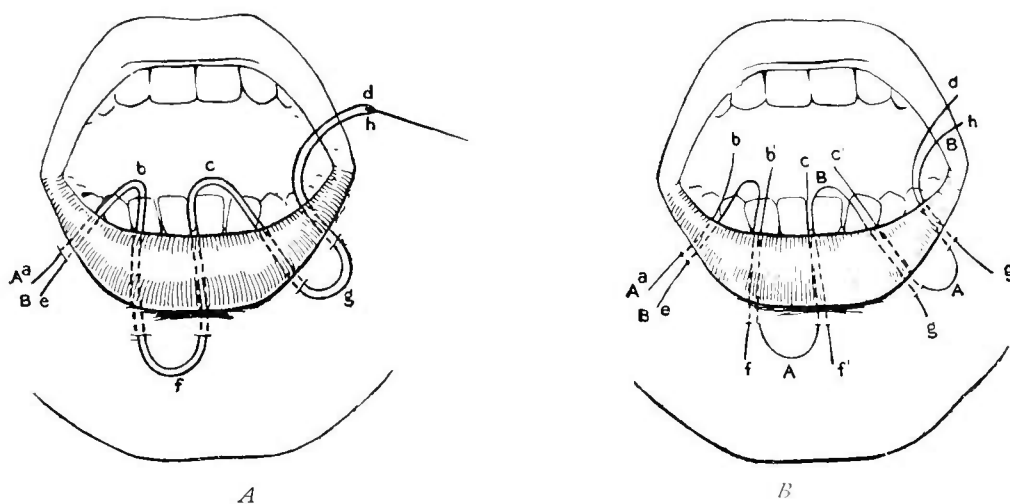


FIG. 31.—TEMPORARY STRANGULATION OF A NÆVUS. *A.* Method of passing the sutures. The dotted lines indicate the threads traversing the thickness of the lip, the continuous ones indicating them as they emerge from the cutaneous and mucous surfaces. *B.* Method of dividing the ligatures. It is easily seen from the diagram how the circulation is completely controlled by tying together the corresponding ends of the ligatures.

risk of producing sloughing either of the skin or, more probably, of the mucous membrane, in which case very serious septic infection might occur throughout the whole venous mass. Attempts at excision are seldom successful and they are accompanied with considerable risk of sepsis.

**Injections.**—The injection of irritants into the tumour is comparatively easy. The circulation through the affected area of the lip may be readily

cut off by a series of ligatures (see Fig. 31), and then undiluted carbolic acid is injected from the cutaneous surface into the substance of the nævus, half a minim at a time, at various points; in about ten minutes the ligatures may be removed. In the course of a few weeks the thickening subsides and it is then possible to see how much of the tumour has been cured and how much nævoid tissue is left behind. It is very important in employing injection to be careful not to inject the carbolic acid too near to the surface, as otherwise sloughing and septic complications are likely to ensue (see also Part I., p. 269).

**Electrolysis.**—Should electrolysis be employed (see Part I., p. 266), two points of importance must be observed. In the first place the needles must not come too near either the cutaneous or the mucous surface, more especially the latter, and the current must not be so strong as to cause actual destruction of tissue; one of 25 milliamperes is quite sufficient. The needles must of course be introduced through the skin, which should be duly purified, and the punctures made afterwards covered with a small collodion dressing.

**LYMPHANGIOMA.**—The condition known as macro-cheilia, or congenital hypertrophy of the lip, is most probably of this nature. One or both lips may be affected, generally the lower, which becomes much everted and pendulous, causing considerable deformity and readily ulcerating. This gives rise to still further thickening, and in some cases the lip may be so large that the surgeon is called upon to remedy the deformity.

**Treatment.**—This is a matter of very great difficulty. The deformity can of course be readily corrected by an operation similar to that recommended for hypertrophy of the lip in tuberculous patients (see p. 115); but in these lymphangiomatous cases there is a grave risk of septic complications, and the operation must therefore not be done without very definite cause. It is however found that, if electrolysis be employed first, the main lymphatic spaces become blocked and the thickened tissues left behind may then be removed by excision comparatively safely. Electrolysis should therefore always be done and repeated until the mass has become solid. Previous to the excision, the mucous membrane should be everted and carefully disinfected, and the mouth should be so packed as to prevent saliva running over the wound during the operation. The teeth should also be carefully examined by a dentist and scaled if necessary. After the excision, the wound should be accurately stitched up with the finest catgut, and it is well to paint it over with Whitehead's varnish.<sup>1</sup> The mouth should be constantly rinsed out with lotions of sanitas or boro-glyceride (a teaspoonful of each to a small tumbler of water). Condy's fluid is not so good because, if it be of sufficient strength to act as an efficient mouth-wash, it stains the skin.

**CYSTS.**—Cysts in connection with the muciparous glands are not at

<sup>1</sup>This is made by adding 1 vol. of turpentine to 9 vols. of a saturated solution of iodoform in ether.

all uncommon. Usually they form small isolated tumours, but sometimes the condition may extend over the whole lip, causing eversion and a very unpleasant deformity.

**Treatment.**—*For simple cysts* it is usually sufficient to clip away the portion of the cyst-wall projecting into the mouth, which is easily done by painting over the mucous membrane with cocaine, seizing the prominent cyst in catch forceps and clipping it away with scissors, making sure that the cyst-wall is removed as well as the mucous membrane covering it. After the glairy fluid has escaped, the remainder of the cyst-wall may be pulled out with forceps or its interior may be touched with undiluted carbolic or nitric acid. In both cases it is important to see that the acid does not reach the surrounding mucous membrane. If nitric acid be used, the mouth should be freely washed out afterwards with a solution of carbonate of soda. The after-treatment consists merely in the use of a simple mouth-wash of chlorate of potash or sanitas (see p. 116).

*When there is a diffuse cystic condition along the lip* this is readily remedied by excising the projecting mass containing the cysts to a sufficient extent to restore the lip to its proper shape. The operation is very similar to that for hypertrophied lip (see p. 115). The edges of the wound are brought together with catgut and a simple mouth-wash employed subsequently.

**EPITHELIOMA.**—The lower lip is a very common seat of epithelioma, which generally occurs towards one side and is often looked on as associated with the irritation caused by smoking clay pipes. The affection was however well known long before the introduction of tobacco into Europe. Both the flat, slow-growing, and the more rapid tuberous forms may be met with, and the cases vary considerably in malignancy. On the whole, the growth, which occurs generally in old people, is not very malignant, and it is not uncommon for patients after excision to remain free from further trouble for the rest of their lives. If left alone, the disease gradually destroys the lip, causing constant dribbling of saliva, difficulty in taking food, etc. It may spread from the lower lip to the upper, often extends to the lower jaw and gives rise to infection of the glands either in the sub-mental or the sub-maxillary regions, usually the latter. Its point of origin is generally at the junction of the cutaneous with the mucous surface. When it arises on the latter, the growth is generally more rapid in its course and glandular infection occurs earlier than when it arises on the cutaneous surface.

**Treatment.**—The treatment is early and free *excision*. As a rule a triangular portion with its apex downwards should be removed from the entire thickness of the lower lip. It is possible in some cases, where the disease is very superficial and has spread for some distance along the lip, to remove half the thickness of the lip only, but, if the incision has to be carried deep, imperfect closure of the mouth is apt to result. When the growth is situated near one angle of the mouth it is well to prolong the V-shaped

incision downwards and outwards in the direction of the sub-maxillary glands, so that the lymphatic vessels running from the lip to the glands may be thereby included. The edges of the wound can usually be readily brought together without the necessity for any plastic operation. Care must of course be taken to see that the red line of the lip is in accurate apposition. When a very considerable portion of the lip is thus removed the angle of the mouth may be pulled towards the middle line on suturing the wound, but in the course of time this deformity rights itself and becomes very slightly noticeable. When still more extensive portions of the lip have to be removed, a plastic operation must be performed (see Chap. XII.).

The excision of the **V**-shaped portion is done as follows: The surgeon grasps the lip well to one side of the growth between his left thumb and

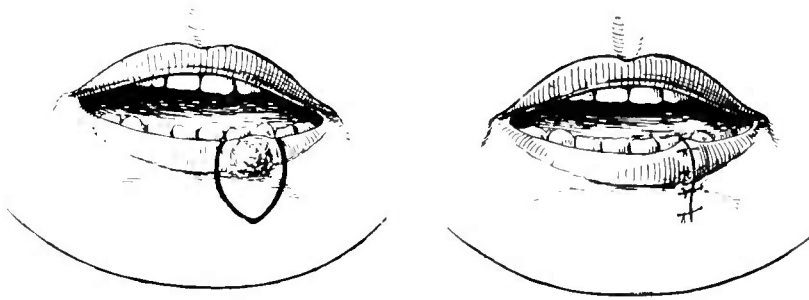


FIG. 32.—INCISIONS FOR THE REMOVAL OF A SMALL EPITHELIOMA OF THE LOWER LIP. The concave limbs of the incisions when brought together give a slight projection on the free margin of the lip, which is obliterated by the contraction of the scar.

forefinger so as to firmly compress the vessels in its thickness. An assistant should do the same on the other side of the growth, and, the circulation in the lip being thus controlled, the **V**-shaped incision is made. It is as a rule advisable not to make the two limbs of the **V** straight; they should be slightly concave so as to allow for the contraction that must inevitably occur in a linear cicatrix. When the two concave sides of the incision are sutured together there will be a slight upward projection at the free edge of the lip (see Fig. 32): in the course of time the contraction of the scar will obliterate this.

The limb of the incision between the growth and the surgeon's fingers should first be cut and should be made by transfixing the thickness of the lip below the growth and cutting upwards through the free margin.<sup>1</sup> When this is done, the surgeon everts the portion of lip grasped between his finger and thumb, relaxes his pressure slightly so as to ascertain the position of the spurting coronary artery, which is then seized and twisted. Any other bleeding vessels may be similarly treated. When the pressure is entirely relaxed, the growth is seized by the fingers or by forceps, and the opposite limb of the incision, that namely between the growth and the assistant's

<sup>1</sup> If there be plenty of room, a still better plan is to have the coronary arteries on each side controlled by the assistant; the surgeon then grasps the growth, and cuts downwards from the free margin of the lip on each side. He can thus make his incisions more accurately and more concave.

fingers, is made by cutting downwards from the free margin of the lip to the apex of the **V**. The bleeding vessels are then similarly treated.

The wound should now be stitched up. The first stitch should be of silkworm gut, and should be put in at the red line which must be carefully adjusted. The ends of this stitch, which should go fairly deeply through the parts, should be left long. A second stitch of silkworm gut should be inserted deeply through the centre of the cutaneous aspect of the incision, and at some distance from the wound in order to relax tension. The remainder of the skin incision is then brought together accurately by stitches of fine silkworm gut or stout horsehair, which pass deeply through the thickness of the lip close down to the mucous membrane. When these have all been inserted, the lip is everted by pulling upon the first stitch in the red line and a few catgut stitches are inserted in the mucous membrane. The latter should not be brought together to anything like the same extent that the skin incision is. It is well to leave gaps in it to permit a certain amount of drainage. These wounds practically invariably heal by first intention.

*Should the glands be infected*, it is generally best to make a separate incision for their removal. Should the sub-maxillary glands be enlarged, the sub-maxillary salivary gland should always be taken away as well, as the lymphatic glands lie close to it and may escape notice unless the salivary gland be removed. As a rule it is unnecessary to remove the lymphatic vessels running between the primary disease and the enlarged glands. When however the growth is large, it is a good plan to carry the apex of the **V** down along the course of the lymphatics so as to terminate in the neighbourhood of the glandular area (see Fig. 33). This has the double advantage that, while it removes the lymphatics, it also, by prolonging the **V**, makes the subsequent approximation of the wound easier.

The sub-maxillary glands are best removed through a curved incision commencing beneath the symphysis, carried downwards and backwards towards the hyoid bone and finally upwards to the angle of the jaw. This flap is dissected up, the deep fascia divided and the glandular area thus exposed. Through this incision also the sub-mental glands can generally be removed should they be enlarged. It is usually sufficient to retract the wound well to get free access to the sub-mental region, but if necessary the incision may be prolonged along the lower border of the chin towards the

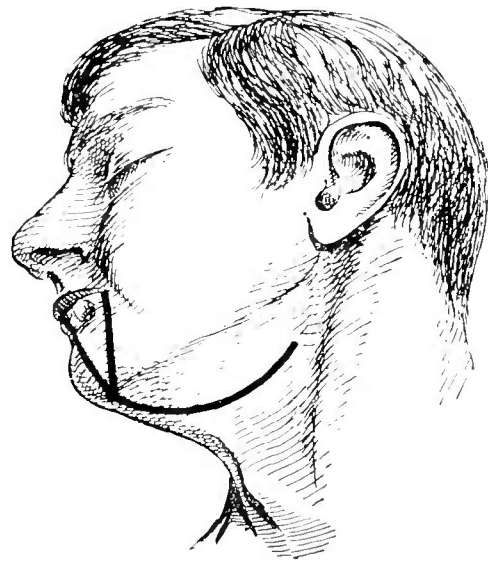

FIG. 33.—INCISIONS FOR THE REMOVAL OF AN EPITHELIOMA OF THE LOWER LIP AND THE SUB-MAXILLARY GLANDS. The ordinary incision for the removal of the tumour is prolonged downwards and backwards, and a sub-maxillary flap is thus raised.

opposite side. Should the sub-mental glands alone be enlarged, the best incision for their removal is a curved one beneath the chin parallel to the jaw and somewhat nearer to the latter than to the hyoid bone (see Fig. 34): the enlarged glands are generally superficial to the genio-hyoid muscle, but they are sometimes found between and even beneath these muscles, so that a very careful search must be made to see that all are removed before the operation is terminated.

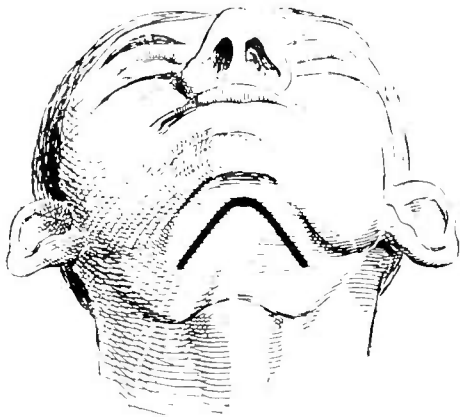

FIG. 34.—INCISION FOR THE REMOVAL OF THE SUB-MENTAL LYMPHATIC GLANDS.

If necessary, any enlarged glands can generally be made more prominent by having the floor of the mouth pushed well downwards by an assistant so as to make the whole sub-mental region project forwards.

When the disease is so extensive that a plastic operation becomes necessary after the removal of the primary growth, it will be unnecessary to make special incisions for the removal of the enlarged glands, as those requisite for the plastic operation will generally be made below the jaw and will permit free access to the glands.

*Should the growth be adherent to the jaw*, a portion of the latter must be removed, as it is never advisable to be content with merely peeling off the periosteum. When the growth has become adherent to the bone, the cells have usually penetrated into the latter and recurrence is certain unless the bone be widely removed. At the same time it must be remembered that the removal of portions of the jaw nearly always leaves a troublesome deformity and should not therefore be done unless it is certain that the disease has penetrated to the bone. When the jaw is affected, it is usually from a growth, which, commencing upon the mucous membrane, has spread to the frenum and so to the mucous membrane of the jaw, and a large portion of the lip will usually require removal, for which it is impossible to give the exact incisions as they must be planned according to the amount requiring removal and according to the requirements of the subsequent plastic operation.

If nearly the whole of the lower lip has to be removed, the incisions should be carried down wide of the growth to the point of the chin, and should be straight and not concave as described above. One of the best forms of plastic operation is to continue the lateral incisions beneath the jaw in a curve which reaches up nearly to the angle of the bone on each side (see Fig. 35. *A*). The flap thus formed must be dissected up well on each side: in front, the skin and mucous membrane must be separated from the jaw, whilst behind, the skin and subcutaneous tissues of the neck are dissected up, and this should be done before steps are taken to remove

the growth which is left attached to the jaw. After the flaps have been dissected up, they are turned aside and the affected part of the jaw is removed.

In some cases the disease affects only the alveolar portion of the bone, so that its lower margin remains intact, and if this be the case it may be possible, by extracting teeth on either side of the growth and by sawing vertically through about two-thirds of the depth of the bone and then joining the lower ends of these incisions by a horizontal saw-cut, to leave a bridge of bone which will maintain the continuity of the jaw and prevent deformity. The periosteum must be removed with the bone *in situ*. This operation is usually very tedious, as the horizontal saw-cut has to be effected with a Hey's saw: if a circular saw driven by a motor be at hand, of course the operation is enormously facilitated. The usual plan is to almost divide the bone with a saw and to complete the division with

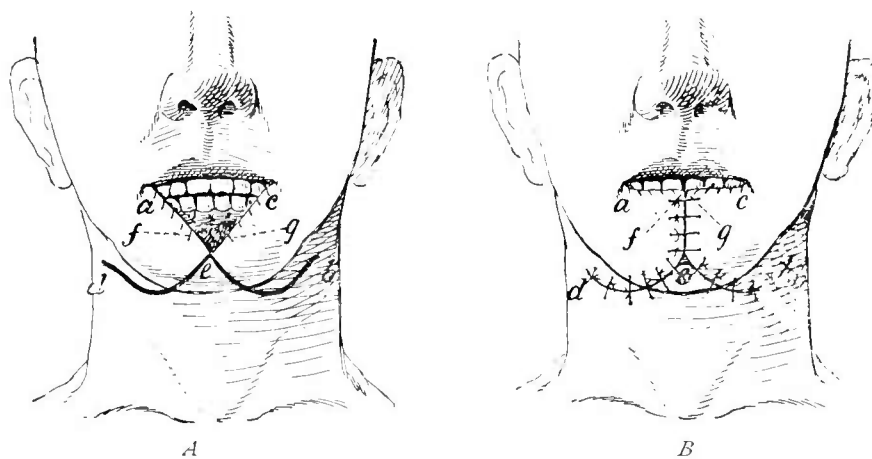


FIG. 35.—INCISIONS FOR THE REMOVAL OF AN EPITHELIOMA OCCUPYING THE BULK OF THE LOWER LIP. The growth is removed by the V-shaped incision *a-c*. To restore the lip, the incision *a-c* is prolonged downwards and backwards to *b*, and the incision *c-e* to *d*. The mucous membrane is stitched to the skin along the edges *a-f*, *c-g*, and the flaps are then raised and sutured as shown in *B*.

a few strokes of the chisel, but the latter must be a very carefully used, as otherwise the narrow bridge of bone may be fractured and the whole object of the operation defeated.

When the bone has been removed, the flaps are brought together so as to restore the lip, and afterwards a dentist will probably be able to supply the patient with artificial teeth to take the place of those that are lost. In bringing up the flaps to form a fresh lip, a raw surface may be left below. It is a good plan to cover this in with a Thiersch's skin-graft, as otherwise the contraction may lead to a certain amount of deformity by pulling upon the new lip.

In many cases, however, the growth involves the whole depth of the jaw, and it is impossible to save any portion of it. If the growth be situated over the symphysis, this portion of the bone will require removal, and this necessitates the separation of the muscles attached to its posterior surface. The result is that the tongue is likely to fall back, and to prevent this a stout silk thread

should be passed through the tip of the tongue, so as to pull it forward and prevent the patient becoming asphyxiated during the operation.

When the symphysis has been removed, the chief trouble afterwards is that the teeth in the upper and lower jaws do not correspond to one another, and the patient will ever afterwards be unable to masticate his food properly. The teeth in the lower jaw, being on a plane posterior to those in the upper, are also very liable to seriously incommode the action of the tongue. Hence, after removal of the symphysis, the divided ends of the jaw should on no account be wired together, as is often suggested, but, on the contrary, an attempt should be made to keep the divided ends apart, so as to preserve the normal contour of the jaw as much as possible. This is a very difficult thing to do, but the importance of it is so great as to render the attempt well worth while. One plan is to interpose between the divided ends a rough model of the symphysis that has been removed, which may be fashioned rapidly out of box-wood, or more carefully from celluloid or some similar substance after a mould of the jaw has been taken. This is interposed between the cut ends of the bone before the lip is brought together, and may be fastened to it by silk around the teeth, wires, etc. The object is to keep the cut ends of the jaw separated until healing is fairly well advanced, when some more suitable apparatus can be fashioned by a dentist to permanently keep the jaws in that position.

Another method of keeping the fragments of the jaw in position is by the use of a Hammond's wire splint (see Chap. XV.), provided that the patient has sufficient sound teeth. If this splint be used, the frame must be made of wire stout enough not to bend during the healing process; this method is not so good as the other.

*After-treatment.*—Little dressing is required; at most a small gauze and collodion dressing may be applied over the incision in the neck, whilst that in the lip is allowed to dry and scab over. The silk loop which has been passed through the tongue should be left in position for a day or two, so that, should there be any tendency for the tongue to fall back, the nurse can pull it forward. For the same reason the patient should be kept lying well over on the side, so that, should the tongue fall back, it will fall to one side, and there will not be the same risk of asphyxia. As a rule, in three or four days the muscles become sufficiently matted together in the granulation tissue to prevent any risk of this sort. The mouth should be frequently washed out with antiseptic mouth-washes, such as sanitas (two drachms to the pint) or chlorate of potash (ten grains to the ounce).



## CHAPTER XI.

### TRIGEMINAL NEURALGIA.

NEURALGIA of one or more of the branches of the fifth nerve is not infrequent. Any branch may be the seat of the disease, and sometimes all three of the main trunks are affected. The pain is generally intermittent and accompanied by spasmodic contractions of the facial muscles—the condition known as “spasmodic tic.” In other cases the pain is practically constant and so severe that the patient’s life is a misery, and the condition may end in insanity.

In the *primary* or *idiopathic* cases the affection is a true neuritis, spreading from the terminal branches to the main trunks and being marked in the more severe cases by degenerative changes in the Gasserian ganglion itself. In the *secondary* cases one of the most common causes is dental caries, and it is worthy of note that the neuralgia may not be referred to the particular tooth that is the seat of the caries. The nerve may also be pressed upon by a cicatrix, a foreign body, callus or a tumour, and sometimes the affection may result from a simple osteitis. Intra-nasal conditions have also been said to originate the affection. More rarely it may depend upon a carious condition of the petrous portion of the temporal bone or the presence of an intra-cranial tumour.

**Treatment.**—The treatment differs according as the case is primary or secondary.

**In the secondary cases** it is generally sufficient, in the earlier stages at any rate, to remove the cause; the affection then subsides and the patient gets well. Should the cause be inaccessible, as it is in disease of the petrous bone, the case will of course be hopeless.

**When no exciting cause can be discovered** and the case is a simple neuritis, the treatment for that condition must first be adopted (see Part II., p. 259). The face should be wrapped up and kept from exposure to cold or draughts, while *quinine* in five-grain doses four times a day or *arsenic* in doses of from three to five minims, cautiously increased up to twelve or more, should be administered. *Antipyrine* in ten to twenty-

grain doses is useful during the severe paroxysms. In some instances *methylene blue* in three-grain pills seems to exercise a specific action. A nourishing diet should be administered and, as a local application, a liniment or similar application containing *menthol* is valuable, as may also be the *linimentum terebinth. aceticum* of the Pharmacopœia.

Should no improvement take place after a prolonged trial of these or similar remedies, and should the patient's condition become unbearable, the propriety of undertaking some surgical measure for the relief of the pain must be considered. Unfortunately in most cases these measures only yield temporary relief as the pain is apt to recur in a few weeks or months and further operations become necessary. The only method of surgical interference that is likely to be of use in these cases is *neurectomy*. Should the disease recur after operation, it may even be necessary to attack the Gasserian ganglion itself.

**Of neuralgia of the first division.**—*Supra-orbital neurectomy.*—This operation is usually performed as follows: The eyebrow is shaved and the parts are purified. During the preliminary purification and the subsequent stages of the operation it is of course of great importance to prevent the access of strong antiseptic lotions to the conjunctiva. The supra-orbital notch, which can usually be readily felt, is first of all defined; it is situated near the junction of the middle and inner thirds of the superior orbital margin. The supra-orbital artery lies close to the outer side of the nerve. An incision is made three-quarters of an inch in length along the upper margin of the orbit, with its centre over the notch, the eyelid being drawn down and the parts steadied as the incision is made. The fibres of the orbicularis palpebrarum are exposed and separated, when the nerve is seen emerging from the notch and lying upon the periosteum. It is carefully separated from the artery, picked up and pulled up into the wound as forcibly as possible, cut off flush with the foramen and as much as possible of it removed. The wound is then sutured and the ordinary dressings are applied.

The small scar left will be almost entirely hidden by the eyebrow, and for this reason the incision recommended above is better than the vertical one sometimes employed, which has the disadvantage of dividing the fibres of the orbicularis palpebrarum and sometimes its nerve supply, besides leaving a very noticeable scar. It no doubt renders the nerve more accessible, but, if the latter be pulled upon in the manner we have recommended, a sufficient length is brought into view to render all possibility of subsequent union out of the question.

**Of neuralgia of the second division.**—When the second division of the fifth nerve is the seat of the disease, the pain may be referred to the teeth of the upper jaw, *i.e.* along the course of the superior maxillary nerve, or to the infra-orbital branch, when it will be referred to the side of the nose, the upper lip and the infra-orbital region. In the latter case, the appropriate treatment is to divide the infra-orbital nerve, whilst in the former the trunk of the second division of the fifth, along with Meckel's ganglion will require ablation.

*Infra-orbital neurectomy.*—The infra-orbital nerve is very easily reached. After the parts have been rendered aseptic it may be exposed through a small incision, nearly an inch in length, along the natural fold of the cheek slightly oblique from above downwards and outwards. Its centre should be over the infra-orbital foramen, which is a quarter of an inch below the orbital margin of the superior maxilla in a line from the supra-orbital notch to the interval between the bicuspid teeth. The skin and fat and a portion of the origin of the zygomaticus major muscle will be divided, the fibres of the orbicularis palpebrarum will come into view above and must be pulled aside, whilst the levator labii superioris must be detached from the upper jaw. After this is done, the nerve is seen emerging from the infra-orbital foramen, and should be seized with forceps and pulled as far out of the infra-orbital canal as possible; as much as can be reached should be taken away. There is generally fairly free oozing from the wound.

The method above described is in any case only useful in the early stages of the affection, and in most it is necessary to divide the nerve further back. It is only in a very few cases that this operation can be successful, because the orbital and the posterior superior dental branches are given off before the nerve enters the infra-orbital canal. When therefore the condition is more severe or when it recurs after the foregoing operation, the trunk of the second division together with Meckel's ganglion must be excised.

*Neurectomy of the superior maxillary nerve and ablation of Meckel's ganglion.*—This may be done through a **V**-shaped incision with the apex downwards, the centre of the **V** being a little below the infra-orbital foramen. The flap thus formed is turned upwards and held or stitched out of the way. The infra-orbital nerve as it emerges from the foramen is then exposed in the manner just described, the soft parts are cleared from the bone for some little distance and a square hole measuring about three-quarters of an inch in each direction is cut out of the front wall of the antrum with a chisel. This should be so planned that the foramen lies slightly above the centre of the hole. A silk ligature is now fastened to the end of the nerve beyond the foramen to serve as a guide in the further procedures. After the bleeding has been arrested, a powerful light is projected into the wound from a forehead lamp or reflector and a slightly smaller hole of similar shape is cut in a similar manner in the posterior wall of the antrum. The oozing here is likely to be very free and must be arrested by pressure or by douching alternately with hot and cold water.

The next step is to remove the floor of the infra-orbital canal which traverses the roof of the antrum, and this is done, using the infra-orbital nerve as a guide, by very cautious strokes of a fine chisel or with a pair of stout scissors. It is very important to avoid damage to the nerve, as otherwise a very essential guide to the later stages of the operation will be lost. The floor of the canal is usually very thin, and it can often be broken away by introducing a fine steel probe or director alongside the nerve and forcibly bending this downwards. The whole floor of the canal is cut away as

far as the posterior wall of the antrum, when the nerve will hang free in the cavity and can be traced up to its point of emergence from the foramen rotundum: at the same time Meckel's ganglion is defined if possible by means of a probe, the aperture in the posterior wall of the antrum being enlarged if necessary. The nerve is now grasped with long-handled forceps and pulled as far out from the base of the skull as possible and cut off flush by curved scissors together with the ganglion attached to it. The portion thus removed should measure at least an inch and three-quarters in length. If preferred, the nerve may be seized by powerful forceps close up to the foramen rotundum and pulled on forcibly until it is torn away from the skull. In any case, before being divided it should be pulled upon so that the cut end will retract inside the foramen, because a very common cause of the neuralgia is a thickening about the periosteum in the foramina at the base of the skull with pressure upon the nerve trunk as it passes through. The oozing at this stage of the operation is usually very profuse and some time may be required for its arrest; it can generally be stopped by sponge pressure. Should it continue, a fine horsehair drain may be inserted through the wound and into the cavity of the antrum for a few days; otherwise no drain need be employed.

**Of neuralgia of the third division.**—When the third division is affected, the pain may be referred to one branch alone, and of these the most commonly attacked is the inferior dental, much less frequently the gustatory, and still more rarely the auriculo-temporal. When this is the case, it is well to see in the first instance what is the result of dividing the particular branch attacked rather than to undertake the very serious operation of exposing and dividing the third division at its exit from the skull.

*Neurectomy of the inferior dental nerve.*—This is done as follows: The patient is anæsthetised and placed in a good light, with the head propped up and the mouth fully opened with a gag. The cheek on the affected side is firmly retracted by a broad copper spatula, and the tongue is held over to the opposite side out of the way either with tongue forceps or better by silk threads passed through its substance. The surgeon first feels for the inferior dental spine with the forefinger of his left hand. This is situated immediately above the commencement of the inferior dental canal, and has inserted into it the internal lateral ligament of the jaw. The mucous membrane is now incised vertically for about an inch just internal to the anterior border of the ascending ramus, and the mucous membrane is detached for a short distance with a small periosteum detacher. The surgeon then introduces the finger through the incision and feels for the inferior dental spine, which must be very carefully defined and the internal ligament attached to it divided with fine blunt-pointed scissors. Immediately behind lies the inferior dental nerve, which can then generally be brought up into the wound with a small blunt hook. The nerve lies in close proximity to the inferior dental vessels as it enters the foramen, but is separated from them by a somewhat larger interval a little higher up. The nerve should not be mistaken for other structures in its vicinity, if proper care has been taken to define and divide

the internal lateral ligament. The lingual gustatory nerve lies behind and internal to the inferior dental, being separated from it by the internal lateral ligament, whilst the mylo-hyoid branch lies posteriorly in its own groove. When the nerve has been brought into the wound, it is grasped with a pair of Spencer Wells' forceps and divided first high up in the wound and then again below, as much being removed as possible.

The operation is tedious and difficult, and the surgeon is much hampered by the continual oozing from the wound. Unless care be taken in isolating the nerve, there may even be considerable hæmorrhage from a wound either of the inferior dental or the internal maxillary artery. It is most important to have a good light during the operation, and if strong daylight be not available a forehead lamp should be employed. No stitches need be inserted after the operation, and all that is necessary is to have the mouth frequently washed out with a weak solution of sanitas (two drachms to the pint). There is often considerable swelling and stiffness about the jaws for some days after the operation, but this usually subsides entirely.

Another and simpler method of reaching the nerve from the cheek by deepening the sigmoid notch finds a place in most of the text-books on operative surgery. It is hardly necessary to say that, since the operation above described is quite feasible in ordinarily skilled hands, the scarring and possible risk of injury to important structures involved in the external operation render it inadmissible.

*Neurectomy of the gustatory nerve.*—The lingual gustatory nerve is very easily divided. The patient is placed in the same position as for the former operation, the mouth is widely opened with a gag and the tongue pulled forcibly over to the opposite side, and at the same time drawn somewhat forwards with tongue forceps. The nerve will then be felt to start up into relief immediately behind and below the last molar tooth. It lies behind the pterygo-maxillary ligament, and is easily felt by the finger in the mouth. An incision should be made along the line of the nerve through the mucous membrane; the former is then drawn out upon a blunt hook and half an inch or more excised.

*Neurectomy of the auriculo-temporal nerve.*—This branch of the fifth nerve very rarely requires division. Should it do so, it can be excised through a vertical incision immediately in front of the ear with its centre across the base of the zygoma. The nerve here lies immediately posterior to the superficial temporal artery.

It is not infrequently found in trigeminal neuralgia that the pain recurs after a short time, notwithstanding the division of all three of its chief branches in turn. It will then be necessary to expose the trunk of the third division as it emerges from the skull through the foramen ovale and to divide it there, so that it shall retract inside the opening. This is perhaps best done by the operation which we quote below in the words of our colleague, Professor William Rose,<sup>1</sup> to whom many of the steps of the operation are due.

<sup>1</sup> *The Surgical Treatment of Neuralgia of the Fifth Nerve*, 1892, p. 52.

It would seem that wherever it is found necessary to perform an operation so severe as this, it would be well to go further and remove the Gasserian ganglion itself, an operation first practised by Professor William Rose in 1890. There are two principal methods of doing this—the extra-cranial method introduced by Professor Rose, and the intra-cranial one devised independently by Hartley and Krause. We quote these operations direct from their authors.

**Division of the inferior maxillary nerve at the foramen ovale.**—“The auditory meatus and external ear are purified thoroughly, and the former plugged with a piece of salicylic wool or cyanide gauze. The skin incision is so planned, as to leave a scar as unobtrusive as possible. Commencing about the middle of the zygoma, the knife is carried backward and downward over the parotid region to the angle of the jaw, and

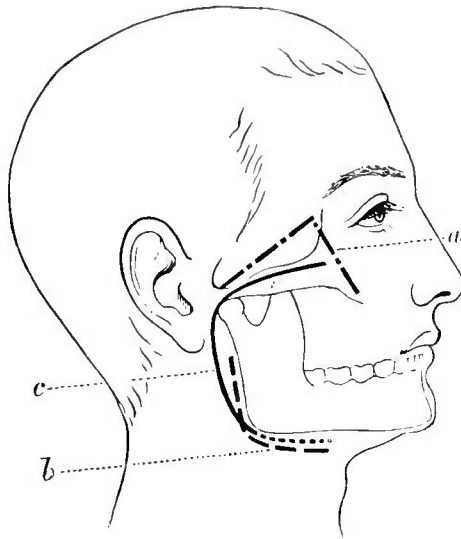


FIG. 36.—INCISIONS FOR EXPOSURE OF THE THIRD DIVISION OF THE FIFTH NERVE, AND FOR REMOVAL OF THE GASSERIAN GANGLION. *c* is the incision referred to in the text for neurectomy of the third division, the dotted continuation being the additional incision needed in the operation upon the Gasserian ganglion. *a* is the Braun-Lossen incision for exposing the foramen rotundum, and *b* the Lücke-Sonnenburg incision to expose the foramen ovale. (Rose.)

then for a short distance along the horizontal ramus (Fig. 36). A semilunar flap consisting of skin and subcutaneous tissue only should be raised and turned forward, and for convenience temporarily stitched across the opposite side and carefully protected. This flap must be so dissected as not to injure any of the branches of the facial nerve. By this means are exposed the masseteric fascia, branches of the facial nerve, Stenson's duct, and a portion of the parotid gland. The deep fascia and masseter muscle are then divided by a transverse incision below and parallel to Stenson's duct, cutting directly down to the bone about a centimetre below the sigmoid notch. Great care must be taken not to wound any of the lobules of the parotid whilst so doing, for even though the main duct be not divided a salivary fistula may ensue, leading to interference with the healing of the wound. The outer surface of the jaw is next denuded of periosteum by means of raspatories, and the soft parts held aside by suitable retractors to allow of the application of a trephine, the diameter of which should not be less than  $\frac{3}{4}$  in. It should be so applied as to leave between it and the sigmoid notch a narrow bridge of bone which can be subsequently clipped away by cutting pliers, and a sufficient amount of bone in

front and behind to preserve the continuity of the jaw with the articular and coronoid processes. At this stage the inferior dental artery may be cut through by the trephine and give rise to troublesome hæmorrhage. The disc of bone having been lifted out and the bridge of bone between the condyle and coronoid process clipped through with bone pliers so as to increase the space in which to work, some loose fatty tissue presents and should be carefully picked away with two pairs of dissecting forceps. The tendon of the temporal muscle is thus more clearly defined, and must be held forward, if necessary. Narrow spatulæ are useful at this stage, not only to keep the wound open, but also by their pressure to arrest hæmorrhage from divided muscular branches. If the bleeding is troublesome the wound should be packed for a few moments with small pieces of sponge wrung out of hot 1-40 carbolic lotion, any obvious bleeding point being secured by ligature. The inferior dental artery, if still intact, is usually first seen and may be secured by passing two ligatures around it with an aneurism needle and dividing it between. The lowest fibres of the external pterygoid muscle are seen running transversely across the wound and require to be held upward or carefully divided, to demonstrate the two nerves passing down from behind. The trunk of the inferior dental nerve can then be raised upon an aneurism needle, and the lingual found a little internal and in front; indeed it occasionally happens that the nerves lie in such close proximity to one another that they are picked up together. A silk or catgut ligature may be advantageously passed around them in order to be able to make traction. It is now easy by a little manipulation with the handle of a scalpel to trace them up to the foramen ovale, which can even be seen, if the external pterygoid muscle be held well out of the way. The nerves can then be divided close to the skull either by scissors or knife, and the meningeal artery should be in no danger if the nerves have been sufficiently isolated. Peripheral traction is also employed so as to draw up as much of the nerve as is possible, and thus a considerable portion—more than an inch—of the trunks can be readily removed.”

**Removal of the Gasserian ganglion—Rose's Method.<sup>1</sup>**

“*Preparation of patient.*—The patient should be in as favourable a condition as possible. The bowels are moved by a mild purgative given the night before. The face is washed as thoroughly as the patient will permit with soap and carbolic solution (1-20) some hours before, and an antiseptic dressing applied. This is important seeing that (as I have previously remarked) the skin is often very dirty on account of the pain caused by any attempts at washing. Chloroform is, perhaps, the most convenient anæsthetic to employ, and when the patient is fully under its influence, the skin and external ear should be again thoroughly cleansed, and a plug of salicylic or some antiseptic wool inserted into the meatus. The conjunctival sac must also be thoroughly washed out with an efficient but unirritating antiseptic, a 1-2000 solution of corrosive sublimate being, perhaps, the most satisfactory; during this proceeding, the lachrymal sac should be squeezed, as collections of mucus are often found therein, and regurgitation of these through the canaliculi may cause septic contamination of the conjunctiva. In order to ensure closure and protection of the eye, both during the operation and for some days after, two fine horsehair or catgut sutures are introduced through the integument of the upper and lower lids about 2 mms. from the palpebral margin of either lid, and exactly opposite each other, taking up small folds of the lax skin, which are approximated by tying the sutures.

“*The skin incision* (Fig. 36) is made by entering the knife over the malar bone about half an inch below the external angular process of the frontal, and carrying it along the zygoma, and down in front of the ear over the parotid region to the angle of the jaw, and then forward along the lower border of the horizontal ramus as far as the facial artery. This done, a flap can now be dissected forward, consisting of skin and subcutaneous fat only, care being taken not to injure Stenson's duct or any of the branches of the facial nerve which lie in close contiguity to the masseteric fascia. Before this is completed,

<sup>1</sup> *The Surgical Treatment of Neuralgia of the Fifth Nerve*, by William Rose.—London, 1892, p. 62.

either a fine catgut thread can be inserted in either side to form a landmark in the subsequent suturing of the wound, or a cross-cut can be made in the skin.

"The skin flap must be carefully protected by a few layers of purified gauze during the operation, and not unnecessarily handled, or exposed to pressure or rough manipulation. It is better to avoid retractors in order to hold it out of the way, and its temporary fixation by a catgut suture to the upper part of the chin will be found beneficial. The anæsthetist should prevent any chloroform dropping on the under surface of the flap, and not allow any part of his apparatus to touch it. Particular stress is laid upon these details, as it is most important not only to maintain asepsis and obtain primary union, but also to leave as little trace of the surgeon's work as possible. After raising the flap probably the transverse facial vessels will need ligation.

"*Section of zygoma and coronoid process, and detachment of masseter and temporal muscles.*—The zygoma is now exposed by means of suitable raspatories and periosteum detachers through an incision along its course. Two holes are drilled at the root of the zygoma, and two also anteriorly through the zygomatic process of the malar bone. This is best accomplished by a fine drill driven by a dynamo. The drill used should be of such a

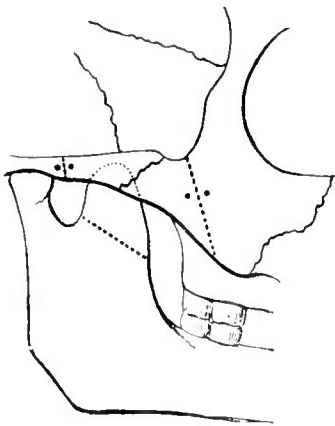


FIG. 37.—SECTION OF THE ZYGOMA AND THE CORONOID PROCESS IN REMOVAL OF THE GANGLION. The dotted lines denote the saw-cuts, the dots on either side of them the position of the drill-holes. (Rose.)

size that the perforation in the bone may carry wire of gauge No. 22, and the holes should be about one-third of an inch apart. The bone is then divided between them with a fine saw, and in such a way that the anterior saw-cut is directed obliquely downward and forward, the posterior part of the zygoma being divided as near its root as possible (see Fig. 37). It is obvious that the bone can be drilled much more efficiently whilst the zygomatic arch is intact, and can be subsequently replaced without difficulty, and maintained in position by means of silver wire.

"The zygoma thus detached is displaced downward and backward together with the masseter; to facilitate this it will be necessary to completely divide the muscular fibres attached anteriorly to the malar bone.

The attachment of the fibres of the masseter muscle to its under surface, from which its nutrition is derived, must not be interfered with. When the masseter

has been sufficiently depressed consistent with the integrity of the important adjacent structures, and a little cellular

tissue picked away, the coronoid process will be exposed together with the tendon of the temporal muscle, which passes further down on the inner aspect of the bone than on the outer. In Cases II., III., and IV. this process was drilled to provide holes for subsequent wiring, and then divided obliquely downward and forward (see Fig. 37). The detached bone was turned up with the temporal muscle, and the deep fibres encroaching upon the ramus of the jaw carefully divided. But latterly I have questioned very much the advisability of attempting to gain osseous union of this process; for the temporal muscle attached to it is paralysed by the operation, and necessarily atrophies, with the result that very considerable impairment of the mobility of the jaw ensues. In my last case, therefore, I simply divided the coronoid without attempting to drill it, and drew it and the muscle upward out of the way, subsequently excising it and a portion of the tendon.

"*Search for the foramen ovale.*—A certain amount of loose cellular tissue and fat will now present, under which will be found the external pterygoid muscle, running transversely backwards, to be inserted into the condyle of the jaw (Fig. 38) and perhaps below it a small portion of the internal pterygoid may be seen. Running superficially across the former muscle, between it and the jaw, the internal maxillary artery is usually found, passing into the sphenomaxillary fossa between the heads of



the muscle. The artery, if it has not been tied at a previous operation, should now be sought for, and divided between a double ligature; by this means hæmorrhage, which might be troublesome during the later steps of the operation, will be avoided. The inferior dental and gustatory nerves under normal circumstances pass downwards from under the lower border of the external pterygoid muscle; but if they have been previously removed, their assistance in guiding the surgeon to the foramen ovale is not available. The external pterygoid muscle is next detached from the great wing of the sphenoid and from the outer surface of the external pterygoid plate by scraping it from the bone with suitable raspatories from above downward. The knife should be used as sparingly as possible, and the strands of muscular tissue are best picked and cut away with dissecting forceps and a fine pair of blunt-pointed scissors. By this means the under surface of the great wing of the sphenoid is exposed, as well as the outer pterygoid plate.

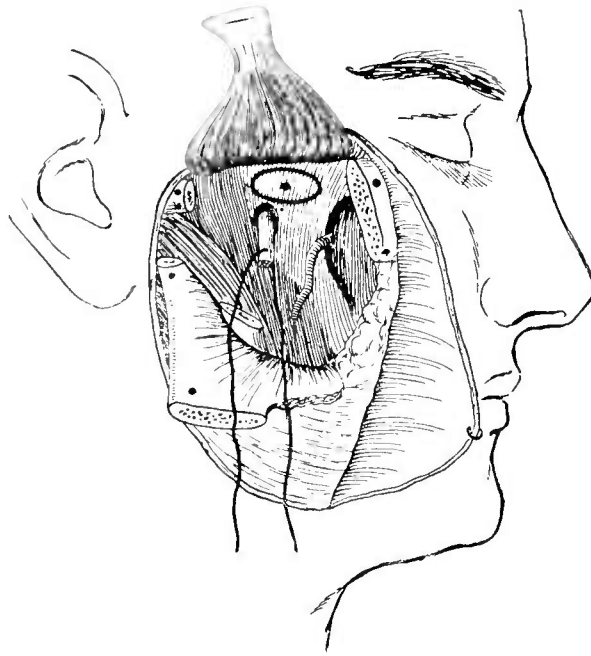


FIG. 38.—EXPOSURE OF THE FORAMEN OVALE. The thick black elliptical line is the trephine groove. A silk thread has been passed through the third division of the fifth nerve. (*Rosc.*)

“The foramen ovale is now to be brought into view, a matter often of some difficulty, and the occasional reference to a dry skull held by an assistant will be a considerable help in indicating its position in relation to the neighbouring landmarks. It is usually on a level with the eminentia articularis, but occasionally lies a little behind it. In fact, the portion of bone which one first reaches in this deep part of the operation is well in front of the foramen, and one is apt to get too far forward, so that the pterygo-maxillary fissure is mistaken for it.

“*Opening the base of the skull.*—Having exposed the foramen ovale and traced to it either the trunk of the undivided lingual and dental nerves, or the stump left from former operations, the base of the skull is now to be opened by means of the trephine. My intention in Cases II., III. and IV., was to remove a disc of bone having the foramen ovale for its centre, and for this purpose I employed a trephine with a handle set on a stem long enough to clear the cheek, and with a reversible centre-pin, one end of which was pointed as usual, the other blunt. The size of the trephine was such that it should remove a  $\frac{1}{2}$ -inch disc of bone; the crown was serrated obliquely on the outer side for a distance of a quarter of an inch in order that the trephine might clear itself of debris, and not get jammed in the bone.

“The smooth-ended centre-pin was projected as far as possible, and passed into the foramen

ovale, so that the blunt point might protect the dura mater or other intra-cranial structures by pushing them before it. To do so, the trephine was, roughly speaking, held in such a position that its axis was parallel to the external pterygoid plate. The handle of the trephine was then depressed and kept as far back as possible; but from the pressure of the soft parts it was always applied at an angle, and not perpendicular to the surface, a proceeding not altogether undesirable, inasmuch as thereby the integrity of the carotid canal could be more readily maintained. The close contiguity of this structure had to be carefully kept in view during this stage of the operation, and, indeed, there is only the inner border of the great wing of the sphenoid, measuring from 2 to 4 mms. in thickness, intervening between it and the foramen ovale. By holding the trephine at this angle, the outer segment of the bony circle was cut through first; the bone could then be broken off on the inner side along the sutural line between the apex of the petrous bone and the great wing of the sphenoid, and thus the carotid canal remained uninjured. The disc of bone being now set free by an elevator, will fit like a collar over the stump of the divided nerve, and can be slipped over it. In one or two of my cases I noticed a definite constriction of the nerve at this point.

"In Case IV., I made an important modification by trephining in addition the great wing of the sphenoid anterior and a little external to the foramen.

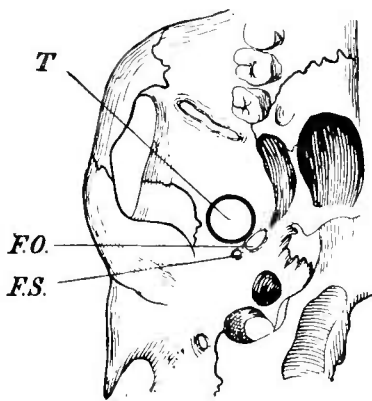


FIG. 39.—POSITION OF THE TREPHINE HOLE IN REMOVAL OF THE GASSERIAN GANGLION. T.=Trephine-hole. F.O.=Foramen ovale. F.S.=Foramen spinosum. (Rose.)

were then united by removing the intervening bridge of bone by a careful use of chisel and mallet. During this process the dura mater, which had been previously loosened around the openings, was protected by a copper spatula, and held up out of the way, for when unsupported it bulged through the opening. As will be seen by reference to the account of my cases which I append, this patient did well, but during the first 48 hours after the operation she had a certain amount of epistaxis and also vomited some grumous material, like coffee grounds, which was evidently altered blood. The source of this was a matter of considerable anxiety to me; it evidently did not come from either the sphenoidal sinus or the antrum, as these were in no way interfered with, but on careful examination of the base of the skull the relationship of the Eustachian tube, which had been previously overlooked, seemed clearly to indicate whence the bleeding was derived.

This structure lies in immediate contiguity to the ridge of bone which forms the inner boundary both of the foramen ovale and spinosum. A groove will be found in this position in most skulls extending backward to the point of attachment of the tube to the petrous portion of the temporal bone and forward to the base of the pterygoid process; and this depression is occupied by the cartilaginous portion of the tube. It is highly probable that in removing a disc of bone, half an inch in diameter, with the foramen ovale as its centre, this structure will be encroached upon, laying the wound open to the risk of septic contamination from the pharynx. This consideration was one of several which induced me to alter my plan of operation in the last case I dealt with; I applied the trephine to the great wing of the sphenoid a little anterior and external to the foramen, and in such a way that the circumference of the disc just impinged on its outer wall (see Figs. 38, 39). The opening thus made can be subsequently enlarged, if necessary, in any direction desirable. It must not be forgotten that the thickness of the skull is very unequal, being thinner on the outer margin of the trephine track than on the inner; and inasmuch as the instrument is necessarily applied at an angle, the outer half will be cut through before the inner. This fact renders damage to the dura possible in spite of the most careful precautions.

"*Removal of the ganglion.*—Having repressed the prominent dura with a spatula, the trunk of the third division, which during all these preliminary proceedings has been care-

fully guarded, and round which a ligature should now be passed (Fig. 38), is to be traced up to the ganglion, which should be loosened from its resting place upon the apex of the petrous portion of the temporal bone. No great difficulty need be experienced as regards the posterior half, but inasmuch as the anterior and upper portion is closely incorporated with the dural sheath, it is perhaps better to sever the connection between the ganglion and the brain at its exit from the dura, and then to draw it forward with a delicate pair of forceps. For this work a pair of fine hooks such as those made for me by Mr. Hawksley will be found most useful: one of them is an ordinary blunt-pointed hook to pass round the nerves and free them from their connections: the other has a sharp edge upon its concave aspect to be used for cutting them through. A pair of long-handled strabismus scissors may also be required. It is quite possible that in dividing the root of the nerve just outside the dura a prolongation of the sub-dural space may be opened, and a small quantity of cerebro-spinal fluid escape through it; this, however, will be of slight extent, and is of no moment, if the wound be kept aseptic. The second division of the nerve must now be dealt with, and this may be facilitated by enlarging the opening in the base of the skull in the direction of the pterygoid processes, and holding up the dural wall out of the way; it may be divided just in front of the ganglion by the sharp hook. Having thus severed all its connections except the ophthalmic division, the ganglionic tissue, which is exceedingly soft, may be pulled away piecemeal by forceps or by a small curette as recommended by Professor Andrews. In this way the danger of wounding the cavernous sinus is reduced to a minimum.

*“Reposition of displaced structures and closure of wound.*—After the steps detailed above have been satisfactorily accomplished, the toilet of the wound must be attended to. The bleeding having been stanchd, the parts should be thoroughly washed with a 1-40 solution of carbolic acid. The coronoid process may be either saturated or removed; in my last case I removed it. Silver wire should be passed through the holes previously drilled in the zygoma, so that it can be accurately adjusted. By this means the contour of the face will not be interfered with, the chances of necrosis or collapse of the zygoma prevented, and firm bony union assured. The integuments may now be brought together with a continuous fine catgut suture, care being taken to adapt the parts accurately to each other. No drain tube is needed, although in my first two cases I used one as a precautionary measure. If the wound has been occasionally irrigated during the operation, and complete asepsis maintained, primary union may certainly be expected. I am glad to say that no suppuration has occurred in any of my cases. To prevent accumulation of blood in the wound, gentle but continuous pressure by means of a purified sponge introduced between the second and third layers of the cyanide gauze will be found very efficacious for the first forty-eight hours. In addition to the face dressing, both eyes should be carefully covered with pads of salicylic wool and lightly bandaged. A certain amount of shock necessarily follows such a protracted operation, and a subsequent elevation of temperature must be expected at the end of the second day. Beyond this no symptoms of importance have been exhibited. The dressing has usually required changing once or twice in the first four days, at the expiration of which time it may be replaced by gauze fixed down with collodion. The stitches can be removed at the end of a week, if they have not already been absorbed. The eye should be kept closed for at least four days when the stitch in the lids may be removed; but it is safer to keep both eyes bandaged for a week, and the eye on the side operated on for three or four weeks.”

**Hartley's method.**<sup>1</sup>—“An omega-shaped incision was made, having its base at the zygoma and measuring a distance marked by a line drawn from the external angular process of the frontal bone to the tragus of the ear.

“The curved and rounded portion of this incision reached as high as the supratemporal ridge, the diameter of said circle being three inches. The skin and deeper tissues were cut in the shape of the Greek capital letter Omega. This incision was carried down to the

<sup>1</sup> *Annals of Surgery*, 1893, Vol. XVII., p. 509.

periosteum of the skull in all portions of the incision, except in the straight part at the base; the tissues were then retracted and the periosteum divided upon the bone in the same direction and as far as the straight part at the base.

“With a chisel a groove was cut in the bone corresponding to the divided periosteum. This groove went to the vitreous plate, except at the upper angle over the rounded portion, where it included the vitreous plate.

“A periosteum elevator was here inserted and used as a lever to snap the bone on a line between the ends of the circular portion of the incision. In this way the breakage occurs along the lower portion of the wound, and a flap, consisting of skin, muscle, periosteum and bone, is thrown down exposing the dura mater over a circular area of three inches in diameter. The middle meningeal artery was tied, the dura mater separated from the bone, and the floor of the middle fossa of the skull was exposed. Broad retractors were used to raise the dura mater with the brain, and to expose the foramen rotundum and the foramen ovale. The hæmorrhage was stopped by sponge pressure. The exposure of the first, second, and third divisions of the fifth nerve, together with the carotid artery and cavernous sinus, was exceedingly good.

“The second and third divisions were isolated at the foramen rotundum and the foramen ovale, and, by slight pressure upon the dura mater, it could be stripped from the nerves to beyond the Gasserian ganglion. These were divided with a tenotome at the foramen rotundum and the foramen ovale, and that part between these and a point beyond the Gasserian ganglion was excised. As this amount of nerve is not very great, the ends of the nerves were pushed through the two foramina so as, if possible, to interfere with any reunion. In the retraction of the dura mater, owing to imperfect instruments, the third, fourth, and sixth nerves were somewhat injured. As no bleeding was present, the brain was allowed to fill the fossa. The flap—consisting of bone, periosteum, muscle, and skin—was replaced. The irregular edge of the vitreous plate which remained attached to the bone, not involved in the flap, acted as a shelf on which the flap rested, and prevented its falling in upon the dura mater. The periosteum was stitched, the muscle sutured in place, and the skin sewn with silk. One drainage tube was inserted at the lower angle; an antiseptic dressing was applied. Time of operation, one hour and forty minutes; the patient was carried to the ward in good condition. The disadvantage was the inability to resect as long a piece as could be done in some of the other methods.”

**Horsley's method.**—This is somewhat similar to that of Hartley, but differs from it in one very important respect, namely, that the dura mater is opened, the temporo-sphenoidal lobe lifted up out of the way, and the sensory root of the fifth nerve isolated behind the ganglion and divided—in Prof. Horsley's original case it was pulled out from its medullary origin. As this operation seems unnecessarily severe as compared with the other two, and therefore much more likely to be fatal from shock, it has been largely supplanted by them.

## CHAPTER XII.

### THE PLASTIC SURGERY OF THE FACE.

IN performing operations about the face the surgeon often has to remove extensive portions of the skin or even of the whole thickness of the cheek and, if the gap thus made be not filled up, very serious deformity will result. He may also be called upon to repair defects caused by the loss of tissue from disease or to remedy deformities of congenital origin, *e.g.* hare-lip, etc. The general principles of plastic surgery have been already referred to (see Part I., p. 177).

The nature of the defect to be remedied varies so much in different cases that it is impossible here to refer in detail to all conditions likely to be met with; we shall therefore limit ourselves to the repair of the deformities in connection with the nose, the eyelids and the mouth. Two classes of cases may have to be dealt with, namely, recent defects made by the surgeon or defects of long standing; the latter may be either congenital or may follow an injury or a disease in which serious contraction occurs during healing.

#### PLASTIC OPERATIONS ON THE FACE IN GENERAL.

The choice of methods is often very large; we shall indicate the principal ones first and shall consider later their applicability to individual cases.

**Thiersch's skin-grafting.**—Immediate skin-grafting (see Part I., p. 50) is of great value where skin alone has been lost—as after the excision of lupus—and we strongly advise that, in all cases where flaps are not available and the loss of substance is not deep, this method should be employed. Some degree of contraction may follow, but probably this will not be enough to cause deformity, and, if it is, it may be remedied subsequently either by division of the cicatrix and skin-grafting or by turning in a flap from the neighbourhood. In large old-standing scars with much contraction, skin-grafting is also of great value. For example, in ectropion following extensive lupus or a burn of the face, it may be impossible to obtain sound skin-flaps in the neighbourhood and under such circumstances division of the cicatrix along the

border of the eyelid, dissecting up the latter, stitching it to the eyebrow, and covering over the raw surface left with skin-grafts will often effect an immediate and striking improvement. A certain amount of shrinking of the grafts will no doubt occur, but a great deal is gained, and, after some months, when the shrinking has ceased, the operation can be repeated, so that ultimately the ectropion may be completely cured. Skin-grafting has however a limited scope in defects on the face, being practically confined to cases in which the loss of tissue is comparatively superficial.

**Flap methods.**—In the majority of cases where plastic surgery is required there is a loss of tissue in depth as well as in superficial area, and very often there are cavities to be bridged over: here the various flap operations are the only ones applicable. When the defects are made by the surgeon, it is generally advisable to cover them in at the time of the operation. Some have advocated that in certain instances the wound should be allowed to heal and the plastic operation performed later, but, by repairing the defect immediately, it is easy to avoid much of the subsequent contraction and deformity which are in reality very difficult to overcome when once established; further, operations through cicatrices, such as these must necessarily be at a later period, are not particularly satisfactory owing to the lower vitality of the cicatricial tissue.

In some cases however it may be desirable to allow the wound to cicatrise. Thus, for example, it may be desirable to leave open the gap made in the cheek after the removal of an extensive tumour from the upper jaw involving the skin, when the surgeon is not at all certain that the disease has been completely removed and wishes to see the interior of the wound thoroughly so as to watch for and treat any recurrence immediately. Again, the amount of tissue removed may be so great that it is impossible to find flaps in the neighbourhood to replace it. Under these circumstances, as much of the space as possible should be covered in immediately by a plastic operation; at a subsequent period the remainder of the defect—which should be left towards the nasal side of the opening—may be covered by a flesh-coloured plate kept in position by spectacles. With care these artificial substitutes may be made even more sightly than the result of a plastic operation and they have the advantage that the area of the operation can quite readily be watched for signs of recurrence.

The most important principle in cutting the flaps is to employ curved incisions wherever this is possible. In many of the text-books straight incisions are shown for the raising and pulling-in of flaps to fill the defects, but these have several disadvantages. In the first place, there is more tension than when curved incisions are used, as the latter allow the flap to slide into position without undue traction; consequently the rectilinear flap either gives way or, if it remain firm, deformity may be caused from the tension, while the angles of the incision at the base of the flap pucker up and cause disagreeable projections. Moreover, with rectilinear flaps it is not, as a rule, possible to get enough covering for most openings. For example,

the method of repairing the lower lip (see Fig. 40) by means of straight incisions, which is so often figured in text-books, is not nearly so satisfactory as that with curved ones. In the former, a quadrilateral portion is excised in removing the lower lip, and to repair this gap incisions are carried vertically downwards into the neck from each extremity; the flap thus marked out is raised and pulled up to the original level of the lower lip and stitched in position. The result is a constant tendency for this flap to retract, and, as a consequence, the lower lip becomes pulled down and proper closure of the mouth is impossible. On the other hand, curved incisions allow the flaps to slide into position without tension, and, as there is not the same liability to subsequent contraction, there is not the same tendency to drooping of the lip afterwards. As the flap slides along, it will be found that there is more skin on one side of the incision than on the other, but, by arranging the

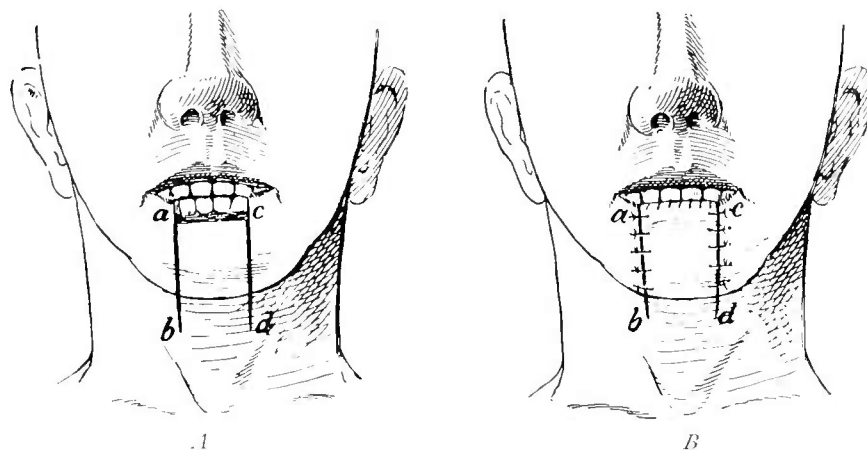


FIG. 40.—RESTORATION OF THE LOWER LIP BY MEANS OF RECTILINEAR INCISIONS—A FAULTY METHOD. The rectangular gap left by the removal of the lower lip is filled by raising a rectangular flap, *abcd*. This is done by carrying the incisions *ab* and *cd* vertically downwards to the hyoid bone. The mucous membrane is stitched to the skin along the line *ac*, and the flap pulled up and sutured, as shown in *B*. It is obvious that there must be a very considerable drag on the new lower lip as the scar contracts.

stitches so that a little more skin is included between each stitch on the former side than on the latter, puckering at the base of the flap is avoided and the cicatrix becomes smooth.

*Sutures.*—Silkworm gut is the best material for the stitches on which there is some tension, and fine horsehair, put in close to the edge of the skin so as to bring it into accurate apposition, for the intermediate ones. Silk is not so good, as it gets soaked with discharge and may act as a carrier of sepsis. As a rule there is so much scarring that the stitch-marks do not matter very much, and buried sutures are unnecessary. However, when the defect is small and the scarring comparatively slight, a great deal of deformity is avoided by using buried stitches (see Part I., p. 154). They are especially useful where small tumours or patches of lupus are excised, and the edges of the skin can either be brought together or a small flap can be turned in to fill the gap. These wounds heal extremely rapidly, and in the great majority of cases union by first intention will be obtained. The stitches can be removed in most cases in four or five days: the earlier they are removed, the less noticeable are the stitch-marks afterwards.

*Dressing.*—We generally apply either a gauze dressing or boracic lint dipped in boracic lotion for a few hours until all bleeding has stopped, and then fix a narrow strip of gauze along the line of incision with collodion; in cases, as in the lips, where the gauze gets readily soiled with saliva, it suffices to allow the line of incision to dry thoroughly and then to paint it with collodion.

#### PLASTIC OPERATIONS ON THE LIPS.

**RESTORATION OF THE LOWER LIP.**—This is most commonly called for when there is an extensive labial cancer and where practically the whole length of the lower lip must be taken away. Here, instead of making a quadrilateral incision (see Fig. 40) which would suffice to remove the growth when it has spread along the margin of the lip, it is better to make a **V**-shaped

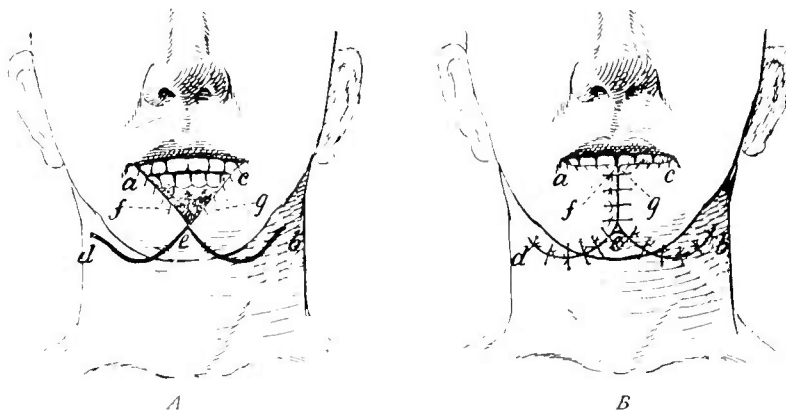


FIG. 41.—RESTORATION OF THE LOWER LIP BY MEANS OF CURVED INCISIONS.—A GOOD METHOD. Here the lip is removed by a large **V**-shaped incision *acc*. The incision *ac* is prolonged to *b*, and *ce* to *d*; these flaps are then dissected up and sutured as shown in *B*. The mucous membrane is sutured to the skin along the lines *af* and *cg*, and these form the margin of the new lip. If any raw surface is left at *e*, it can be closed by undermining the triangular flap of skin *deb*, or by a skin-graft. It is clear that there cannot here be the same direct drag upon the new lip by contraction of the cicatrices.

incision, with the apex of the **V** at the chin (see Fig. 41), even though a considerable portion of the healthy lip be sacrificed in so doing. The result is a large triangular defect, which may be filled in one of the two following ways:

In one method, the soft parts from the angles of the lip down to the reflection of the mucous membrane from the lower lip on to the gums are brought up to form a new lower lip, the mucous membrane being stitched to the skin on each side down to its point of reflection. From the apex of the **V**, curved incisions are carried downwards into the neck on each side (see Fig. 41, *A*) and flaps are raised so that the stitched edges can be brought into line. For example, the incision which was carried down the left side of the lip is continued downwards in a curve into the right side of the neck nearly as low as the hyoid bone, and is then carried upwards again towards the angle of the jaw. The



whole of this flap on the right side is then freed, the base of the flap extending from the angle of the mouth to the margin of the lower jaw; the same is then done on the other side. The facial artery should be left undivided so as to supply the flap with blood. The original lines of incision made for removal of the cancer are now brought up to the horizontal so as to form the margin of the lower lip, the mucous membrane being first stitched to the skin on each side (see Fig. 41, *B*). The edges of the flaps, which have been made to slide forwards, are then stitched together vertically in the middle line for a sufficient distance to leave a somewhat redundant lower lip in order to allow for subsequent contraction, and then the edges of the incision in the neck are stitched together. In order to unite the wound in the neck satisfactorily, it is well to undermine the skin for some distance so that it can be pulled up and united to the lower edge of the flap above without

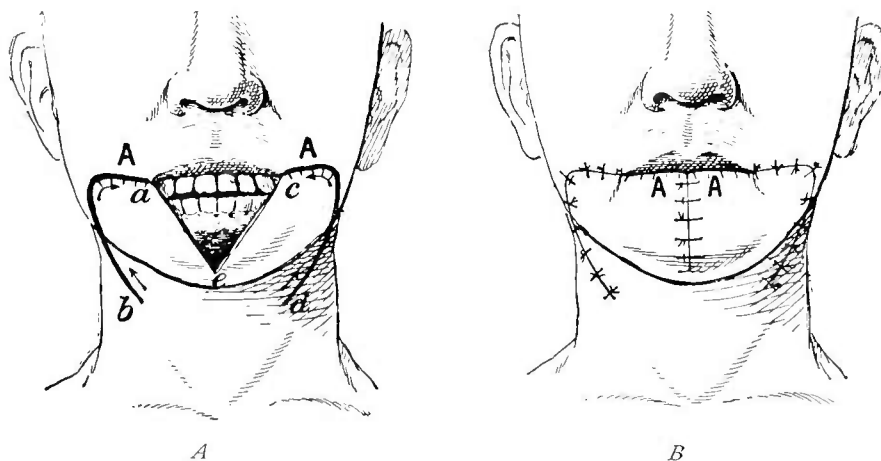


FIG. 42.—RESTORATION OF THE LOWER LIP BY MASSETERIC INCISIONS. The free margin of the new lip is formed by stitching the mucous membrane to the skin along the horizontal part of the incisions *A*; *ac* and *ce* are approximated in the middle line and form a vertical scar, as shown in *B*.

any marked drag; if the sutures be inserted so as to include more of the lower edge between each stitch than of the upper, the incision will usually come together without any marked puckering. In some cases it may be necessary to leave a small triangular raw surface at the outer end of the incision; this can be covered at once by a skin-graft.

The second plan is the following. Instead of continuing the **V**-shaped incision down into the neck, an incision is carried straight outwards from the angle of the mouth on each side, or with a slight bend upwards, as far as the masseter muscles, dividing up to that point the whole thickness of the cheek. When the incision reaches the masseter, it is curved outwards and downwards over the margin of the jaw, and then under the latter nearly to the hyoid bone, ending with a slight upward curve in front (see Fig. 42, *A*). The flaps thus marked out are then raised from the margin of the masseter and from the lower jaw, the mucous membrane being divided vertically downwards along the anterior border of the masseter and then horizontally along the reflection of the mucous membrane on

to the gum. When these flaps have been fully loosened, they can be made to slide in so that the sides of the V-shaped incision meet in the middle line and can be stitched together. The mucous membrane is then stitched to the skin to form the free border of the newly-made lower lip, and then the rest of the wound is closed by sutures (see Fig. 42, B), the skin on the outer side of the incisions being undermined so as to allow it to be brought into position more easily. In some ways this operation is better than the preceding one. The lip has less tendency to drop and there is a better supply of mucous membrane. The chief disadvantages are the division of the branches of the facial nerve going to the flap, the large scar on the cheek and the less perfect blood-supply. If, however, the base of the flap be made sufficiently broad, the blood-supply is usually quite satisfactory. The choice between the two methods will depend very much on the circumstances of the case and on the shape of the patient's face: perhaps the second method will be the one more often chosen.

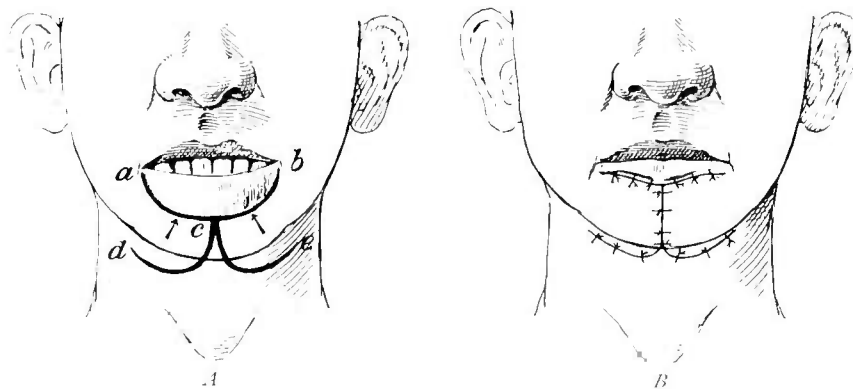

FIG. 43.—OPERATION FOR ECTROPION OF THE LOWER LIP. The lip is liberated by the incision *ab*, and is then kept in place by raising flaps by means of the incisions *cd* and *ce*. These flaps are shown in position in *B*.

**ECTROPION OF THE LIPS.**—Sometimes, as the result of injury or disease, there is ectropion of one of the lips, that is to say, eversion of the red line and the mucous surface.

Where the lower lip is affected, the condition is remedied in the following manner (see Fig. 43). An incision is carried along the lower edge of the everted red line and the parts separated sufficiently to allow the mucous surface to be brought into its proper position. By carrying a vertical incision downwards from the middle of the transverse incision and curving it away to each side when it reaches the chin, flaps of skin and fat on each side can be detached and brought up so as to lengthen the cutaneous surface of the lower lip and thus to keep the mucous membrane in position. In other cases, especially when the condition is on one side of the lip only, the elliptical gap left after freeing the mucous membrane may be filled by a flap turned in from the cheek very much as for ectropion of the lower eyelid (see p. 152).

**RESTORATION OF THE UPPER LIP.**—When only the central portion of the lip has to be removed for disease, the removal is carried out on the same lines as that for cancer of a portion of the lower lip (see p. 120), a V-shaped incision with concave borders being made and afterwards stitched together. Where the whole of the middle of the upper lip has to be removed up to the nostril, each remaining part should

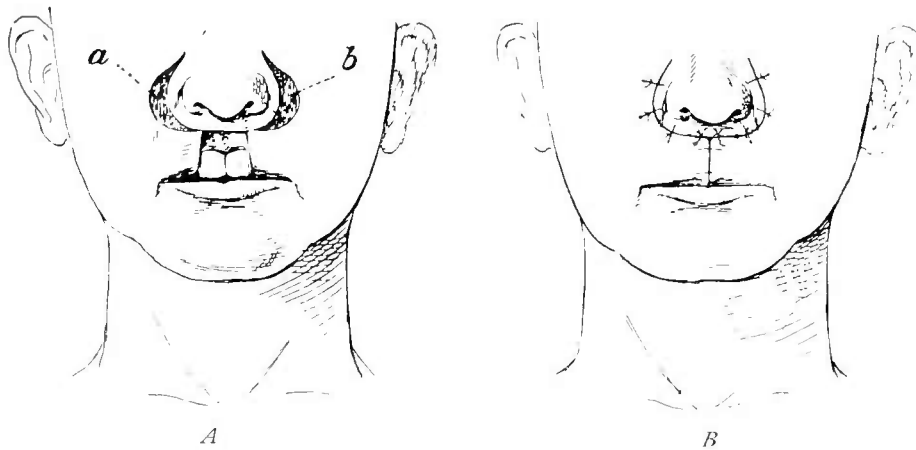


FIG. 44.—OPERATION FOR RESTORATION OF PART OF THE UPPER LIP. In *A* are shown the portions of skin, *a* and *b*, removed from each side of the cheek, in order to allow the remains of the upper lip to slide inwards and meet in the middle line as in *B*.

be freely separated from the jaws and an incision continued upwards round the ala of the nose on each side. An elliptical portion of skin is then removed opposite each ala (see Fig. 44) and the lip can then be brought together and the wound stitched up without compressing the

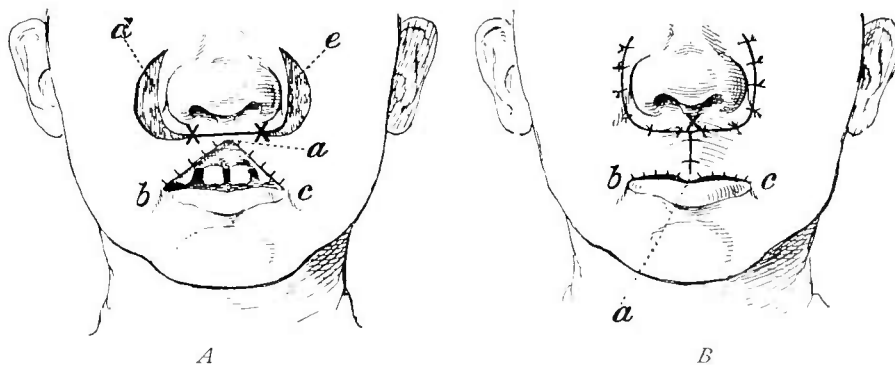


FIG. 45.—OPERATION FOR RESTORATION OF THE ENTIRE UPPER LIP. Two elliptical portions of skin, *d* and *e*, are removed as in the preceding figure. The mucous membrane is stitched to the skin along *ab* and *ac*, and these are then drawn down to form the free margin of the new lip. The points *xx* in *A* come together at the point *x* in *B*, just beneath the columella.

nostrils in any way and with extremely little deformity. The same principle may be employed for more extensive removals of the lip. When the whole of the upper lip has been removed, it is well if possible to make the operation wound as angular as possible, with the apex at the columella: an incision is then carried from the columella round the ala and up along the side of the nose on each side (see Fig. 45). The flaps are raised and an elliptical portion of the cheek is taken away on each side

as in the former operation, sufficient being removed to allow these flaps to come together and form the upper lip. The mucous membrane is stitched to the skin along the raw surfaces of the lip up to the apex of the **V**, the surfaces thus prepared are brought down to the level of upper lip and that part of the two incisions that curved below the ala of the nostrils is stitched together so as to make a vertical median line which will push down the tissues of the cheek and form the substance of the upper lip. The cheek is then brought in to the ala of the nose and stitched there, and in this way the defect will be very thoroughly repaired (see Fig. 45, *B*). This method is however most useful in cases where only the middle portion of the upper lip has been lost and where the lateral portions are still intact. In some cases additional advantage is gained by carrying the incisions outwards into the cheek from the point where they extend upwards around the ala of the nose, the incision being carried downwards and outwards parallel with the line of the lip.

**FOR MICROSTOMA.**—As the result of disease or injury, the mouth may be contracted at one side, and various methods may be employed

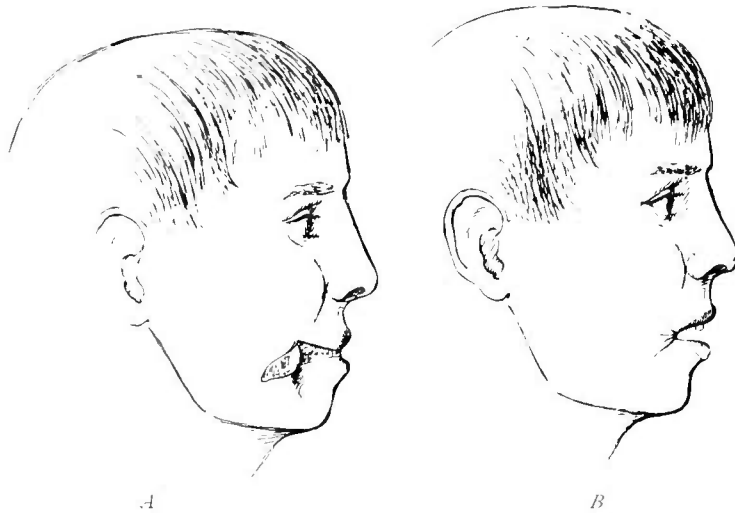


FIG. 46.—DIEFFENBACH'S OPERATION FOR MICROSTOMA. A small triangular flap is first dissected up, and then the angle of the mouth is split along the dotted line shown in *A*. The flap is now turned in around the new angle and sutured as shown in *B*.

to restore it to its proper size. The older plan of introducing metallic rings through the cheek at the desired new angle of the mouth, keeping them in position until the sinus is covered with epithelium, and then splitting the cheek up to the perforation, does not answer very well, as this deformity usually results from disease which destroys the mucous membrane, the skin, or the whole thickness of the cheek, leaving only scar tissue behind. The method of Dieffenbach is the best under these circumstances and is done as follows:

In the first place, the whole thickness of the cheek is split outwards to the point where the new angle of the lip is to be, and then, if the

mucous membrane alone has been mainly destroyed, a small strip is trimmed off the scar tissue on each side and the sound skin is turned in and stitched to the healthy mucous membrane, so that the two are continuous and the normal mucous membrane of the red line is continued outwards by skin. When the skin alone has been destroyed, the mucous membrane is turned outwards and stitched to it so as to form a properly mucous-covered lip. In cases where the skin is superabundant, instead of splitting the cheek in the first instance, a narrow triangular portion of skin with its base at the new angle is raised (see Fig. 46) and the mucous membrane is then split outwards. The flap of skin is

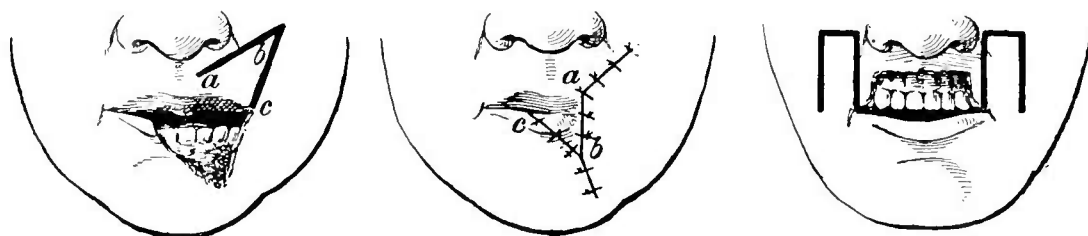


FIG. 47.—PLASTIC OPERATIONS UPON THE MOUTH. The two left-hand figures show the operation devised by Estlander to restore the lower lip and angle of the mouth. A triangular flap *abc*, consisting of the entire thickness of the cheek and containing the coronary artery in its pedicle *a*, is cut from the cheek and rotated into the gap in the lower lip. This gives a flap covered by mucous membrane on its deep surface and bounded above by the red line of the lip.

The right-hand figure is Dieffenbach's method of restoring the upper lip. By marking out the flaps somewhat lower down on the cheek they can be used equally well to restore the lower lip. The flaps comprise the entire thickness of the cheek, and their deep surfaces are therefore lined by mucous membrane.

now turned in and sutured to the mucous membrane so as to cover the new angle; this prevents any fresh contraction spreading from that point. The rest of the raw surface is covered by suturing the mucous membrane to the skin in the manner just described. This plan is very valuable when it can be employed; without it, contraction is very apt to occur at the angle and to diminish the size of the mouth again.

#### PLASTIC OPERATIONS ON THE CHEEK.

The method adopted for repairing defects in the cheek will depend upon the extent of the defect—in particular upon whether the cutaneous or mucous surface alone is wanting—and also upon the presence of complications, such as closed jaw, ectropion of the lips or eyelids, etc.

**A fresh defect of the skin and subcutaneous tissues** of the cheek, such as occurs after the removal of superficial tumours, may be closed in various ways according to its size, etc. The edges of a small oval defect may be brought together by undermining (see Part I., p. 178), or a fairly large circular surface may be covered with skin-grafts. Sometimes the result is better when flaps are turned in from the neighbourhood: these are usually best fashioned from the skin between the defect and the

ear. Failing this, they may be obtained from over the lower jaw or the neck. The flap must be larger than seems requisite at first so as to allow for contraction which might otherwise cause displacement of the lips or eyelids.

**When there is destruction of the whole thickness of the cheek,** the case is much more serious. This may be caused by severe injuries, such as gunshot wounds, by operations for the removal of tumours, or after disease, such as cancrum oris, in which there is extensive destruction of the cheek and the neighbouring parts; the latter is one of the commonest causes of the defect and has already been fully described (see Part I., p. 80). In the great majority of cases the disease leads to difficulty in opening the mouth and often indeed to its complete closure; this may be due to cicatricial contraction of the mucous membrane of the cheek, to fibrous union between the jaws posteriorly, or to infiltration of the masseter with inflammatory material. The last condition is very serious and may complicate either of the others.

Hence the treatment of these cases depends rather upon the closure of the jaws than upon the actual loss of the cheek tissues. The latter is fairly easily repaired, but that is of little advantage unless the fixation of the jaws be also overcome. It is quite exceptional to find merely a defect at the angle of the mouth without any marked limitation of the movements of the jaw.

It must be remembered also that a somewhat similar closure of the jaws may result from operations in which extensive portions of the cheek—particularly the mucous membrane—have been removed, and the remedial procedures here are essentially the same, but the plastic operation should be proceeded with forthwith; it is easier to keep the mouth open and prevent contraction while the flaps are uniting than to force the jaws open afterwards. In cases due to disease, on the other hand, it is well not to be in too great a hurry to operate; patients recovering from cancrum oris usually remain very anæmic for a long time during which failure of union is very apt to occur.

All sorts of defects may be met with in the cheeks, but we may classify them into four chief types: (1) A defect without closure of the jaws; (2) a small defect with plenty of skin left, but closure of the jaws; (3) a large defect with no sound skin, and with complete closure of the jaws; (4) extensive and irremedial closure of the jaws.

**1. A small defect without closure of the jaws.**—Here two flaps may be provided for the closure of the opening, a deep one with its cutaneous surface looking inwards towards the mouth and taking the place of the mucous membrane, and a superficial one with its raw surface applied to that of the deeper flap and its skin surface looking outwards (see Fig. 48). The first thing is to commence by paring the edges of the opening so as to leave a broad surface for the attachment of the flaps, which as a rule can be obtained from over the lower part of the masseter muscle. A flap, with its

base near the defect and somewhat larger than is necessary to cover in the latter, is dissected up with as much fat as can be taken without damaging the branches of the facial nerve. This flap is best shaped by taking a pattern of the opening, laying it on the skin and making an incision a quarter of an inch outside it all round so as to allow for shrinking. The flap is turned forwards without twisting the pedicle, so that the skin surface looks into the mouth; it is stitched in position with interrupted sutures through the buccal mucous membrane.

The superficial flap may be raised at the same time or two or three weeks later. It is better to cut this flap immediately because it gives an extra broad surface for the union of the deep one, for, when the latter has become vascularly connected with the margins of the opening, its pedicle must be cut

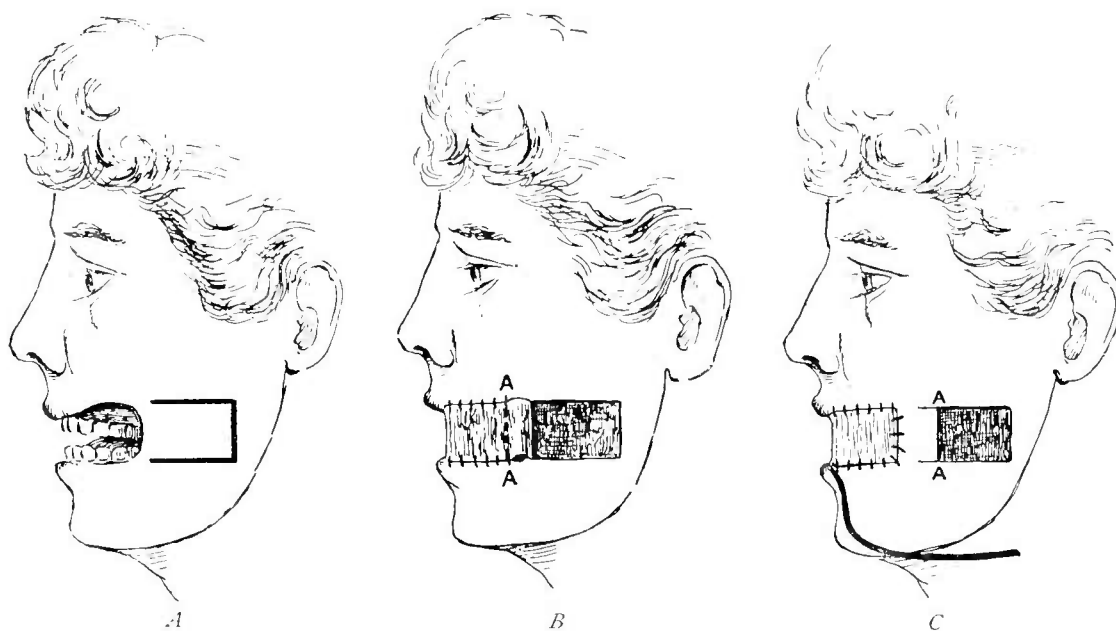


FIG. 48.—PLASTIC OPERATION ON MOUTH WHEN THERE IS NO ANCHYLOSIS OF THE JAWS. In *A* the edges of the defect have been pared, and the flap over the masseter is marked out. In *B* this flap has been reflected and sutured into the gap with its cutaneous surface inwards to the buccal cavity. In *C* the flap, after it has united to the margins of the gap, is divided along the line *AA*, and a small part of its base turned back into place. The remaining raw surface can be covered by skin-grafts, or by undermining the edges. The thick black line passing below the chin is the outline of the skin-flap that is raised and brought over the raw surface of the flap that has been sutured into the gap.

through and stitched in position, so that it is important that the union at the edges of the flap should be reinforced by union of its outer surface with the skin-flap. Where this is the case, the pedicle can be divided sooner than would otherwise be safe and with less risk of sloughing.

The exact method of providing the superficial flap will depend on the situation and shape of the gap, but in many cases it may be made by carrying a curved incision from the front and lower edge of the opening downwards and then backwards under the jaw, raising a flap which can be applied with its raw surface to that of the deeper one. The raw surface left after turning forward the deep flap may be partly closed by stitches after undermining, and partly by skin grafts. A small portion of its anterior end will be subsequently covered when the base of the flap is divided: a portion of the pedicle can

then be turned back and sutured back in position again. The raw surface due to the raising of the superficial flap can be closed by sutures in the manner already described.

When the superficial flap is applied immediately after the deep one and good union occurs, the base of the deeper flap may be divided in about a fortnight; when the operation is done in two stages, it is well to wait for three or four weeks. When the base is divided, the posterior part of the aperture must be again pared and the cut edge of the flap stitched into it.

**2. A small defect with plenty of skin, but closure of the jaws.**— Here the chief trouble is the closure of the jaws. It is best to divide the reparative procedures into two stages, opening the jaws at the first and closing the aperture three or four weeks later. A good example of

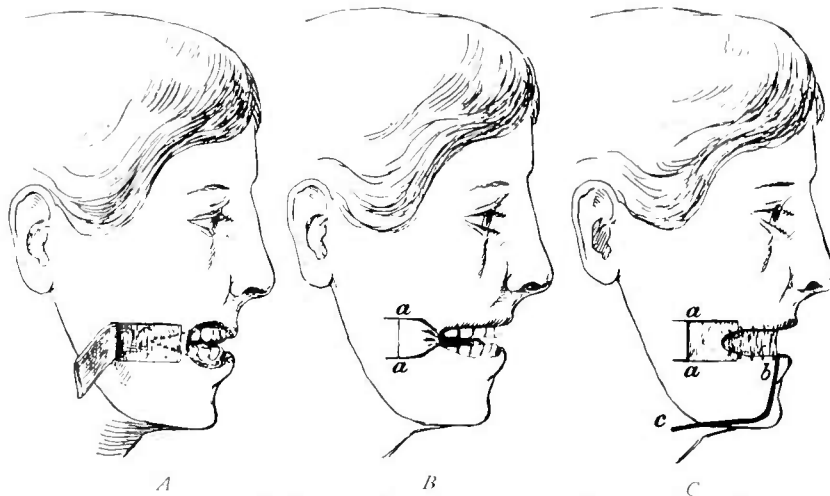


FIG. 49.—GUSSENBAUER'S PLASTIC OPERATION ON THE MOUTH. In *A* the quadrilateral flap is raised, and the dotted lines indicate the incisions for splitting the cheek back to the masseter. When this is done, the flap is turned into the mouth and sutured to the mucous membrane as in *B*. In *C* the flap has been divided along the line *aa*, and turned forwards and sutured to the margins of the gap. The incision *bc* is for the flap which is to be superimposed on the outer raw surface of the one sutured into the defect. The raw surface left where the latter is raised from is skin-grafted.

the method is given by Gussenbauer. In his case, the mucous membrane had been destroyed by a mercurial stomatitis and there was marked contraction of the jaws; the skin however was abundant. A portion of the skin about an inch broad in front and somewhat more behind (see Fig. 49) is marked out by two incisions extending from the margin of the mouth to the masseteric region. The flap of skin and fat is dissected up with the base of the flap posteriorly over the masseter, the cicatricial tissue is divided from the margin of the mouth to the internal pterygoid muscle, and the mouth forced open. Any cicatricial tissue over the internal pterygoid muscle should also be divided and any bands which prevent the opening of the mouth cut across. The skin-flap is turned into the gap thus made and stitched with catgut to the mucous membrane over the inner surface of the pterygoid muscle, and applied closely to the new angle of the mouth. A good way of keeping the flap applied to the raw surface is to pass the suture from the cheek in front of the



jaw through the flap and back again at a different spot, so that when tied it brings the deep surface of the flap in contact with the structures underneath. Two or three of these stitches, in addition to the marginal sutures, will ensure the satisfactory application of the flap. At the end of four weeks, the base of the flap over the masseter is cut across, the free portion turned forward like a door on its hinges and stitched into the front part of the defect, so that the epithelial surface is made to look into the mouth and replace the lost mucous membrane. By means of a flap from the skin over the jaw and neck, as already described, the outer raw surface of the flap can be covered and the defect entirely made good. Even where there is a hole in the cheek this plan can be carried out unless the defect be very far back.

**3. A large defect with no sound skin and complete closure of the jaws.**—These are most difficult cases, as sufficient material for the deep flap cannot be obtained from the cheek. The flap must therefore be provided either from the back part of the neck or from the forehead. The first thing is to divide the cicatricial tissue fixing the jaw, so as to allow the mouth to be freely opened. A boxwood wedge is then inserted between the jaws on the sound side and simultaneously an attempt is made to close the opening by two superposed flaps. The margins of the defect are first pared (except at the upper part) and a flap, marked out as before, is turned down from the forehead. If there be cicatricial tissue inside the internal pterygoid this must be removed and the flap should then have a prolongation posteriorly which will cover this up. The flap is taken from the corresponding side of the forehead, the incision being carried along the line of the junction of the hair and forehead, and curved backwards around the outer edge of the orbit. The flap of skin and subcutaneous fat is turned down and the eyebrow and the skin of the upper eyelid are also displaced downwards, the incisions being continued sufficiently low to allow the flap to be attached to the lower and posterior margins of the gap, and stitched to the mucous membrane with its cutaneous surface inwards. The prolongation destined to cover the raw surface over the internal pterygoid is fixed in position either by catgut stitches or by sutures running through the whole thickness of the cheek, as above described. It is not necessary to pare the upper edge of the gap at this stage, because no union can occur there and paring it would only entail additional subsequent contraction.

The superficial flap is then formed by carrying an incision downwards from the anterior part of the gap into the neck, curving it backwards, and dissecting up a skin-flap. This leaves the mucous membrane and buccinator muscle over it attached to the deep flap, to the raw surface of which the superficial flap can be applied. The latter is stitched to the margin of the opening in front and behind, and also to the deep flap itself.

If these flaps unite well, the pedicle of the deeper one may be cut through in about a fortnight and the portion remaining adherent to the gap made to

fit the opening in the cheek by paring the upper edge of the latter and suturing the united flaps in position. The remainder of the forehead flap is then turned upwards; the eyebrow is usually readily replaced if some of the granulation tissue be torn through, and a certain amount of skin above the eyebrow will be left. The raw surface remaining on the forehead must be skin-grafted.

Should it be thought well not to carry out the whole operation at one time, the base of the deep flap should not be divided for about four weeks, when the flap can be brought up from below to cover it. There is however no advantage in dividing the operation into two stages, though it must be noted that in some cases suppuration does occur between the flaps when they are both cut at the one operation. To obviate this, a drainage tube should be put in at the deeper part so as to carry off any saliva which may get in between the flaps from the posterior margin. If sufficient skin has been obtained, and there is not too much tension, the result should be good, especially if the prolongation of the deep flap over the inner surface of the horizontal ramus of the jaw has united well. No doubt a certain amount of contraction does take place later, but this is usually only enough to limit movement to a certain extent.

**4. Extensive and irremedial closure of the jaws.**—These are the bad cases with extensive union between the alveoli and so much infiltration of the masseter and internal pterygoid muscles with inflammatory material as to convert them practically into dense fibrous bands.

Under these circumstances it is useless to attempt to get movement at the temporo-maxillary articulation, and it is better to try to obtain it by dividing the jaw in front of the contraction. The best plan is to begin by closing the aperture in the cheek by turning in flaps, without division of the cicatricial material, and then subsequently creating a false joint in front of the cicatrix. The typical mode of procedure is that known as Esmarch's, and consists in the removal of a wedge of bone from the horizontal ramus of the jaw, with its base downwards, the size of the wedge varying with the age of the patient; in an adult the base should measure about an inch and a quarter in length, in a child correspondingly less. The wedge must be well in front of the cicatrix. An incision is made along the lower border of the jaw, somewhat longer than the intended base of the wedge, the soft parts are separated from the bone in front and behind, and then the jaw is divided with a keyhole saw. If teeth be present, it is usually impossible to open the mouth so as to extract them, and, if they get in the way of the saw, they must be cut across, and the fangs afterwards picked out. A thin copper spatula should be passed between the inner side of the jaw and the soft tissues to protect them from injury, and the bone should be cut as cleanly as possible. Any sharp edges left must be removed with bone-pliers or a chisel. The wound is closed by one or two horsehair sutures, a small aperture being left for a gauze plug, which may be removed after the first few days.

The *after-treatment* consists in daily passive motion begun about the third day, if necessary under an anæsthetic. The mouth must be washed out several times a day with a non-irritating antiseptic solution such as sanitas, and the movement of the jaw must be persisted in for a long time. We must confess that our experience of this procedure after cancrum oris is very discouraging. In children the loose portion of the jaw becomes drawn back and gets firmly united with the posterior part by strong fibrous adhesions, while the line of the teeth becomes displaced inwards so that the patient cannot bite. At the same time the operation affords the only chance of improving this very distressing deformity.

#### DEFORMITIES OF THE EYELIDS.

**ECTROPION.**—The chief deformity of the eyelids which comes under the notice of the general surgeon is ectropion, especially of the lower lid, due to cicatricial contraction. This may result from burns, lupus, syphilis.

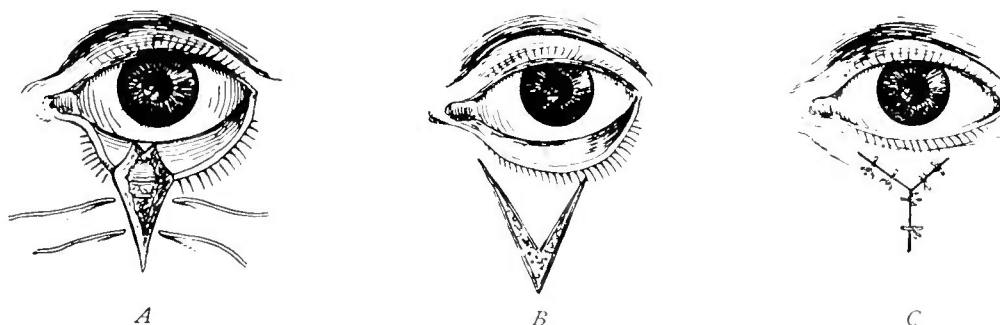


FIG. 50.—OPERATIONS FOR ECTROPION OF THE LOWER EYELID. The operation shown in *A* is suitable for use when the ectropion is due to an injury. The cicatrix is dissected out so as to leave a wedge-shaped gap which, when sutured, restores the lid to its proper position.

Wharton Jones' operation is shown in the two remaining figures. In *B* the V-shaped incision has been made, and the cicatrix partly dissected up. When the lid is brought into position the incision becomes Y-shaped, as shown in *C*.

or necrosis of the orbital margin or the malar bone with adhesion of the skin to it. The forms of ectropion due to thickening of the conjunctiva and paralysis of the lower lid are generally dealt with by the ophthalmic surgeon.

When the deformity is cicatricial, it is of importance not to undertake a plastic operation until the contraction has entirely ceased, as otherwise the deformity will be reproduced; and further, the patient should be in a good state of health. In syphilitic cicatrices, for example, a considerable time must be allowed to elapse after the ulceration has ceased; in fact, unless the patient has recovered from the disease, ulceration is very apt to recur in the scar tissue after operation.

The particular operation performed in these cases depends upon the situation and the extent of the cicatrix. When this is comparatively small and close to the lower eyelid, the operation introduced by Wharton Jones may be employed (see Fig. 50). A V-shaped incision is made with its apex downwards, the skin and fat are dissected up, the lower eyelid

loosened so that it comes into place, and the two sides of the **V** stitched together, possibly after loosening the edge so as to give support to the lower eyelid. This method is also good where the ectropion is due to adhesion of a scar to the orbital margin or even to the malar bone. In the latter case, one side of the **V** will be longer than the other, but, when the eyelid is pulled up and the wound sutured so as to make it into a **Y**-shaped incision, the defect is very satisfactorily overcome.

When the whole cheek is converted into cicatricial tissue and it is not possible to get a sound flap, the treatment must be by skin-grafting. Whenever it is possible to turn in a flap of skin, however, it is best to do so, and when the cicatrix is limited, sound skin to turn in can generally be found over and beyond the malar bone. An incision is made parallel to and just below the margin of the eyelid and deepened until the orbital fat is exposed. With the handle of the knife the lower

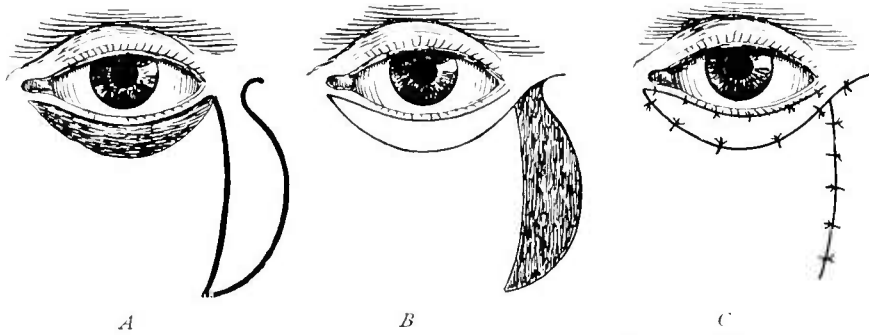


FIG. 51.—FLAP OPERATION FOR ECTROPION OF THE LOWER EYELID. The operation is fully described in the text. The lower lid should be fastened in position by silkworm-gut stitches passing upwards to the eyebrow, but these are not shown in the figure.

eyelid can then be turned up, any necessary extension of the incision at either side being made in order to remove all tension. This leaves an elliptical gap to be covered in (see Fig. 51, *A*). Before doing this it is well to put in two or three interrupted silkworm-gut stitches between the ciliary margin and the eyebrow, so as to retain the lid in position. An incision, somewhat longer than the length of the eyelid, is then carried downwards from the outer end of the incision, and from the lower end of this a curved incision is carried upwards to a point level with but posterior to the upper end of the first, so as to cut a flap the base of which is just outside the outer canthus and which is somewhat broader and longer than is quite necessary to fill up the gap. This flap is then turned on its base and stitched into position with horsehair stitches (see Fig. 51, *B*). A quantity of fat must be raised along with the skin, so that the flap will retain its vitality, but it is well to avoid cutting deep enough to injure the branches of the facial nerve. By undermining the skin, the sides of the gap left in the cheek may be brought together and a vertical scar produced (see Fig. 51, *C*). The ingenuity of the surgeon must however be exercised in these cases to find flaps from any part where there is no cicatrix.

*After-treatment.*—A piece of boracic lint dipped in boracic lotion is applied until the bleeding has stopped, and then the line of the incision is covered with a little salicylic wool fixed on with collodion. The stitches pulling up the lower eyelid should be retained for a few days but, to prevent the accumulation of discharge, it is well to syringe gently beneath the eyelids with equal parts of warm boracic lotion and water three times a day.

In some cases the after-treatment is complicated by a pre-existing ulceration of the cornea from exposure of the eye, and the purulent discharge escaping on to the line of the incision may interfere with the union. It is important to improve this condition as much as possible before doing a plastic operation, but it is not always easy to cure it because it is dependent on the exposure of the cornea.

#### DEFORMITIES OF THE NOSE.

Apart from the lateral deviations of the nose, which have been already described in connection with fractures of the nasal bones, a number of nasal defects may occur from injury or disease. We may classify the chief of these under the following headings:

**1. Sinking-in of the bridge.**—This is a common and very important deformity. It may result from badly treated fractures or from necrosis after fracture, but it is most common as the result of syphilitic necrosis. It also occurs from imperfect development of the bones in congenital syphilis. When the nasal bones have been lost or depressed at an early period of life, a very typical deformity is produced. Instead of the prominent bridge there is a depression into which the cartilaginous portion of the nose sinks. During the contraction in healing a sort of pivot movement occurs, so that the tip of the nose is much higher than normal and the nostrils look forwards instead of downwards, producing a very unsightly deformity.

**2. Loss of the cartilaginous portion.**—The cartilaginous portion of the nose may be lost while the bony structures and the skin over them are healthy. Such deformities are caused by wounds, such as sword-cuts, or diseases, such as lupus or syphilis. More rarely, the deformity may have to be produced by the surgeon in removing malignant disease of the tip of the nose.

**3. Small partial losses.**—Smaller partial deformities from injury or local disease, such as the loss of the tip of the nose, or of a portion of one ala, are frequently seen. The loss of the tip of the nose is not uncommon as the result of gangrene after debilitating diseases, such as typhoid fever or cholera.

**4. Total destruction of the nose.**—This is usually the result of syphilis, most frequently of the congenital variety. In place of the nose there is merely a mass of cicatricial tissue with either one or two oval

openings in the face; when the destruction extends to the septum there is only one large rounded opening, when this remains intact there are two. The extent of the defect varies in different cases and is frequently not quite so complete as above mentioned.

**Treatment.**—(1) *Loss of the bridge of the nose.*—Here there are two deformities to deal with, namely, (a) the sinking-in of the bridge of the nose and (b) the tilting forward of the aperture of the nostrils. The amount of tilting varies in different cases and may be comparatively slight when it follows an injury in adults; in other cases it is very marked. We have used the following method with success for marked tilting forward of the nose with

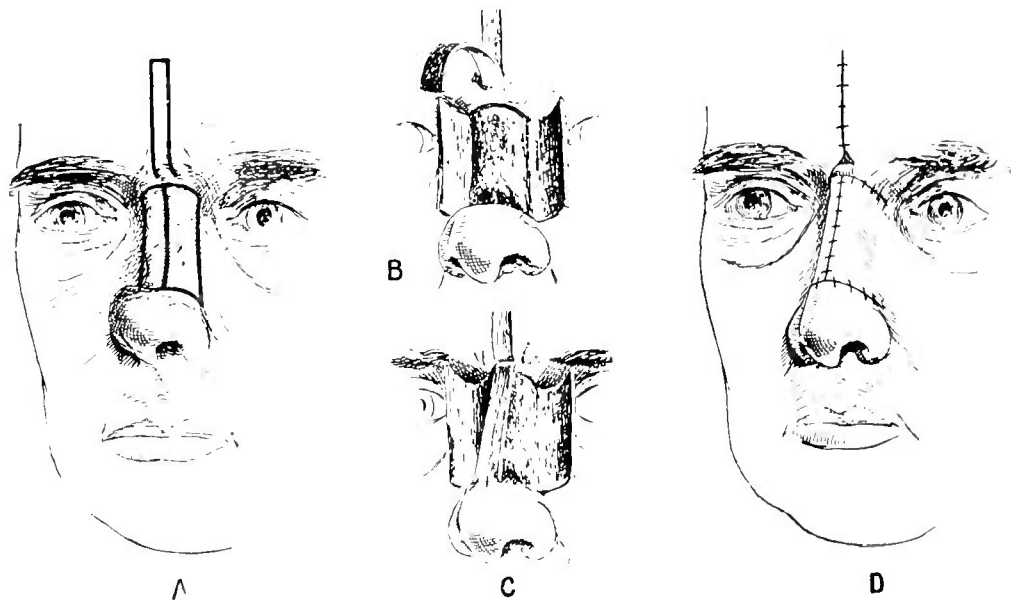


FIG. 52.—RESTORATION OF THE BRIDGE OF THE NOSE. The details of the operation are fully described in the text. *A* shows the lines of incision for the various flaps. In *B* the flaps have been reflected and the tip of the nose freed and brought into position. In *C* the reflected flap from the forehead is sutured in position, while in *D* the lateral flaps have been brought together over the reflected forehead flap. The small triangular gap left at the root of the nose is afterwards filled by the divided pedicle of the forehead flap, which is trimmed into shape and turned up again.

loss of the bridge (see Fig. 52). A vertical incision is made from the root of the nose downwards on to the cartilaginous portion and is carried down to the remains of the nasal bones and the cartilage; it is continued on to the cartilage for about a quarter of an inch. The soft tissues are raised on each side, taking if possible any periosteum or even any fragment of the nasal bones that may be present. Transverse incisions are then carried across the upper and lower ends of this vertical incision, and two lateral flaps are thus formed exposing the remains of the nasal bone and the upper part of the cartilage. The cartilaginous portion of the nose is then separated from its junction with the remains of the bony portion by a transverse incision, which of course passes into the nasal cavity and which must also be carried through the cartilaginous septum sufficiently far to enable the tip of the nose to be readily pulled into its normal position.

A bony bridge to the nose is then manufactured in the following manner: An incision is carried vertically upwards to the margin of the hair, starting about half an inch above the root of the nose and about an eighth of an inch to one side of the middle line. This incision divides all the tissues right down to the bone. An eighth of an inch on the other side of the median line a similar incision is carried up parallel with the first. The upper ends of these incisions are connected by a transverse cut (see Fig. 52, *A*). In this way a flap is marked out about a quarter of an inch in breadth with its base at the root of the nose, and this is turned down along with a thin layer of the frontal bone beneath it. A narrow chisel, about the breadth of the flap, is introduced along each lateral incision and a portion of the external table is chiselled through on each side. The chisel is then introduced into the upper transverse incision, and, being sufficiently sloped, the superficial portion of the external table of the frontal is chipped off along with the flap, which, of course, is raised at the same time (see Fig. 52, *B*). When the lower end of the flap is reached, the bone is broken across and turned down. In this way a long, narrow strip is formed which, when turned downwards, has on its upper surface a thin layer of the frontal bone and on the under surface skin from the frontal region. The flap should be long enough for its free end when turned down to be attached to the cartilaginous portion when pushed into its proper position. To enable this to be done without tension it may be necessary to prolong the lateral incisions a little downwards; but a sufficiently broad pedicle must be left for the proper nutrition of the flap. The flap is then stitched with catgut to the freshened end of the cartilaginous portion of the gap (see Fig. 52, *C*), so that its cutaneous or deep surface covers the aperture into the nasal cavity between the bony and the cartilaginous portions. Above this gap the skin should be carefully shaved off the under surface of the flap, which is thus made raw and can become adherent to the tissues of the bridge. At the root of the nose there is a certain redundance of skin from the folding of the pedicle, which will be divided subsequently and turned upwards.

To keep the tip of the nose in position we have found it a good plan to take a long splinter of a rabbit's femur and to stick one end of it into the tissues at the root of the nose and the other into the cartilaginous portion; this forms a prop sufficiently long to keep the parts in position. The lateral flaps are finally undermined and united over the raw surface of the reflected flap (see Fig. 52, *D*). The upper transverse incisions should be curved downwards and outwards; this allows a certain amount of sliding of the flaps downwards so that they can cover the opening between the tip of the nose and the bridge. The incision in the forehead is readily stitched up and leaves a hardly perceptible linear scar. At the end of three weeks the base of the reflected flap is divided and the little portion remaining is trimmed into a triangular shape and fitted in at the lower part of the vertical incision.

The result is to correct the position of the nostrils and to provide a bony bridge for the nose, but this tends to sink downwards as healing occurs and as a rule will not be high enough. After healing has occurred, we have however been able to heighten the bridge to the required extent by turning aside the skin flaps again and introducing pieces of bone removed from the femur of a newly killed rabbit in sufficient quantity to raise the bridge to its proper level. This cannot be done at the first operation on account of the free communication with the nasal cavity and the consequent risk of decomposition ending in necrosis of the bone; if however care be taken not to re-open the nasal cavity at the second operation, the pieces of bone will unite readily and give a very satisfactory result. In one case where the bridge was not high enough to please the patient we turned aside the flaps and put in some fresh splinters of bone about eighteen months later, with the result that the patient was ultimately completely satisfied.

Other methods such as Langenbeck's have been employed. Here a convex incision is made across the nose from the insertion of one ala to that of the other over the line of junction of the cartilaginous and bony portions, thus liberating the tip practically in the manner above described. When the tip is pulled down, the crescentic defect left is filled by a flap of similar shape turned down from the forehead, taking up the periosteum and having its skin surface downwards. After union has occurred the base is divided and the skin over the nose and the adjacent part of the cheek on each side is brought over it. A similar flap is made by König, but including a thin layer of bone. These operations, however, are more concerned with the repair of the opening left after the liberation of the tip of the nose than with the restoration of the bridge; in bad cases it may be well to commence with this operation and then, when the tip has been satisfactorily fixed in its new position, to form a bridge in the manner above described.

When the tip of the nose is not much deformed, it may not be necessary to make the transverse incision opening the nasal cavity, and then the treatment is easier. For example, flaps of skin may be turned aside from over the defect in the nasal bones and an artificial bridge of aluminium may be fixed in and the flaps turned back; or again the breast bone of a small bird, such as a canary, has been successfully introduced to form a bridge: but even in these cases we believe the best plan is to turn down a narrow flap of bone and superficial tissues in the manner already described, first removing the epithelial surface; the necessary heightening may be given to the bridge by the immediate introduction of portions of rabbit bone.

2. *When the tip of the nose alone has been destroyed*, the operation known as Syme's (see Fig. 53) is useful. The edges of the gap are pared on each side, a flap is cut from each cheek of the appropriate shape and brought inwards so that the adjacent edges meet in the middle line and can be sutured together: the outer and lower edges of the flaps are united to the



pared edges of the defect. This leaves a raw surface on either side of the nose which can be covered with skin grafts.

Where the cartilaginous portion is completely lost, the Indian method (see p. 158) may be employed; it was introduced mainly for these cases.

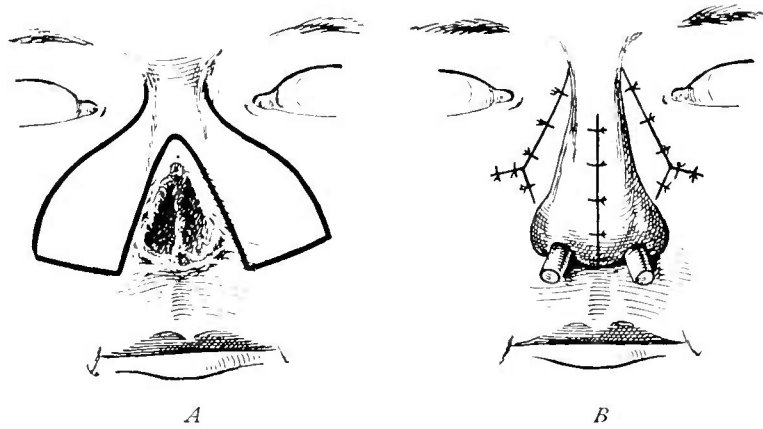


FIG. 53.—SYME'S OPERATION OF RESTORATION OF THE SOFT PARTS OF THE NOSE. *A.* The gap is pared so as to be of a triangular form, and the flap is marked out on the cheek. *B.* The V-shaped edges of the flap are sutured together in the middle line, and the remainder of the flap is fastened to the raw surface. The surface from which the flap is raised is filled up partly by undermining, and partly by skin-grafts.

3. *Partial losses of the ala or tip of the nose* must be repaired by flaps from the cheek; it is seldom necessary to take them from the forehead. It is impossible to give details of these operations because the defects vary so much in character. The principle in most cases must be to employ curved incisions.

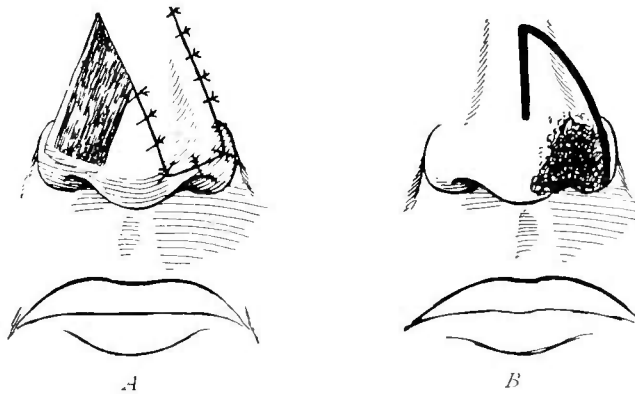


FIG. 54.—PARTIAL RHINOPLASTIC OPERATIONS. *A.* Langenbeck's operation. A skin-flap is raised from the sound ala to fill in the defect in its fellow. The raw surface left may be covered with a large skin-graft. *B.* The operation generally known as Denonvilliers'. The edges of the defect are pared, and the triangular flap, which should contain the cartilage of the ala, is rotated into position on its pedicle.

4. *Loss of the whole nose.*—The methods of forming an entire new nose are very unsatisfactory, as, in whatever way it may be made, the new organ shrinks and ultimately forms as an unsightly mass on the face. Indeed, in most cases the patient will probably be much better off with an artificial nose suitably tinted and held in position by spectacles.

Two operations may be employed: in the one the skin to form the

new nose is obtained from the forehead—the Indian method; in the other it is obtained from the arm—the Italian or Tagliacotian method; neither gives a really satisfactory result. It is possible that a better result might be obtained in the Indian method if the flaps, instead of only containing periosteum, were provided with a thin layer of bone chipped off from the frontal. We ourselves have not tried this, but we should be inclined to adopt it in any future case.

The defect in the nose is prepared for the reception of the forehead flap. Instead of paring the actual edges of the gap, a double flap may be made by carrying the incision round about a quarter of an inch outside its margin and turning in small flaps with their skin surface directed towards the nasal cavity and the raw surface outwards, ready for the forehead flap to be superimposed. An extra long flap may with advantage be taken above, when skin is present over the remains of the nasal bones, and turned down so as to fill up a considerable part of the gap. The upper surface of these flaps adheres to the under surface of the forehead flap and diminishes the amount of subsequent contraction.

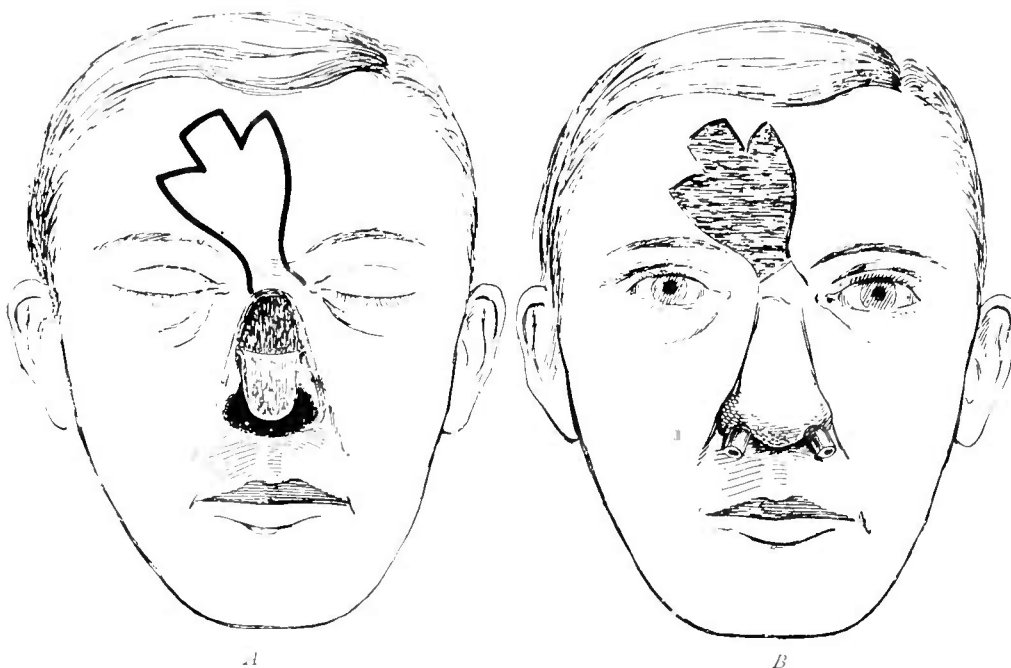


FIG. 55.—THE INDIAN METHOD OF RHINOPLASTY. Full details of the operation are given in the text. The flap is planned obliquely on the forehead for the reasons given. In the figure it is shaped so as to form two nasal apertures when in position (*B*). In practice it is better to cut it with a depression in place of the projection destined to be the columella; this gives a single large nasal aperture, and is much better.

*The Indian method.*—Before the operation, a model of suitable size and shape is cut from a piece of thin gutta-percha; this is now flattened out, laid on the forehead and used as a guide for the formation of the flap; the incision should run about a quarter of an inch outside the pattern all round so as to allow for shrinking. The flap should be made somewhat to one side, the base of the flap being to the left of the root of the nose. By planning the flap somewhat obliquely there is less twisting of the base in adjusting it in position and consequently less risk of sloughing. At the same time, if it be cut too obliquely the eyebrow and upper eyelid may be drawn up by the contraction of the scar. The incision on the side on which the base of the flap lies should be prolonged further down towards the root of the nose than the other. The flap is supplied by one, or if possible

both, of the frontal arteries (see Fig. 55). The incision is carried down to the bone, dividing the periosteum which, in the method ordinarily employed, is then stripped up. As we have remarked above, it may be well to turn up a thin layer of bone along with the periosteum by means of a fine chisel, so as to have a certain amount of new bone to support the flap.

The forehead flap may sometimes be planned so as to provide a new columella, but as a rule it is better not to do so because this is apt to be too broad and, as the new nose shrinks, there will be insufficient breathing space. As a matter of fact, a new columella can be subsequently formed if deemed desirable by turning up the central portion of the upper lip (see Fig. 56).

The nasal flap is now rotated into position and secured to the raw edges of the defect with fine horsehair sutures. The tip of the nose may be supported as follows: hare-lip pins are thrust across the nasal cavity from side to side so as to push up the sides of the nose and make it stand forward; the pin is pushed in up to the head on one side, when, by winding silk around the pin on the other side and pushing this up against the flap, the alæ will be retained in position. Usually two pins suffice; the method is similar to that described for fracture of the nasal bones (see Fig. 30). It is well to plug the opening of the nostrils with strips of iodoform gauze, a drainage tube or a portion of a large catheter being introduced through the centre of the plug to maintain the airway.

As soon as the oozing has stopped, the wound is dressed with salicylic wool fixed on with collodion, and the raw surface on the forehead whence the flap has been raised may be grafted at once by Thiersch's method; any angles of the wound which can be brought together by stitches should be sutured, so as to diminish the area requiring grafting.

The *after-treatment* is very simple. The wound is not touched for four or five days, when some of the stitches may be taken out, the rest being removed later. The plug of gauze should be changed once or twice a day. The pins may be left *in situ* for three or four weeks. At the end of about four weeks, the pedicle of the flap should be divided at the root of the nose and the parts there pared and sutured; the rest of the pedicle is then turned upwards and replaced in the wound in the forehead. Subsequently some small plastic operations may be required to improve the shape of the nose thus formed or to cut away redundant tissue.

The columella, if it has not been fashioned with the forehead flap, can be readily formed afterwards from the upper lip. A narrow strip of the middle line of the upper lip is isolated by vertical incisions beginning just below the aperture of the nares on each side and cutting downwards through the entire thickness of the lip to the free margin. This small portion is turned upwards, the frenum being divided, and its free end is stitched to the tip of the nose, which is refreshed for the purpose. The new columella will have its cutaneous surface looking backwards while the mucous surface is external. Nasal plugs

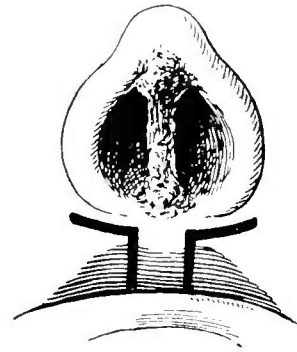


FIG. 56.—METHOD OF FORMING A NEW COLUMELLA. The central part of the lip is isolated by the two vertical incisions running through its entire thickness. This is then turned up and sutured so as to form the new columella. It will of course have its mucous surface looking downwards. The two halves of the divided upper lip are made to meet in the middle line by carrying the small curved incisions depicted above around each ala.

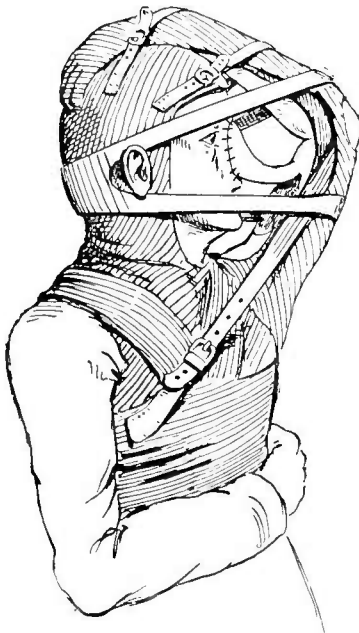


FIG. 57.—THE ITALIAN OR TAGLIACOTIAN METHOD OF RHINOPLASTY.—The drawing shows semi-diagrammatically the kind of apparatus required to keep the arm in position during the union of the flap.

are introduced on each side in order to keep the parts in position, and the divided upper lip is sutured in the middle line after short lateral cuts have been made on each side beneath the nose so as to allow the upper part of the lip to slide in below the new columella (see Fig. 56).

*The Tagliacotian method.*—This plan, although successful in some cases, is on the whole unsatisfactory, and entails great inconvenience and the use of special apparatus. In it the arm is fixed to the forehead so that the elbow comes opposite the nose, and a large flap is then fashioned from the skin over the biceps and made to cover the defect in the nose. The arm must be kept in this position for about four weeks before the pedicle of the flap can be divided. The position is however so very irksome that few patients will submit to it, while the new nose is even more apt to shrink than the one formed by a flap from the forehead; the only advantage of the method is the avoidance of extra scarring about the face or forehead. The accompanying sketch (see Fig. 57) will sufficiently illustrate the position of the arm and the mode of attachment of the flap.

## CHAPTER XIII.

### HARE-LIP AND CLEFT PALATE.

It is well to consider these two deformities together, as they are commonly associated, and the treatment of the one condition is often merely preliminary to the treatment of the other.

#### HARE-LIP.

Hare-lip is a gap or cleft of congenital origin left in the lip as the result of want of proper union between its component parts. It nearly always occurs in the upper lip : it is usually unilateral, and then generally on the left side, although in some rare cases it is present on the right side. It may also be bilateral, and it may or may not be accompanied by cleft palate. The defect in the lip varies in extent from a mere notch in the red line of the lip to a wide cleft extending into the nostril. In the latter case there is generally also a cleft of the alveolar margin, of the palate, or of both, and in addition the nostril on the affected side is unduly widened. When the cleft only affects the red line, the rest of the lip may be normal, but even then the nostril on that side is often broader than on the other. When the gap is wide and there is an extensive cleft in the palate, the edge of the cleft in the lip on one or both sides is bound down to the alveolus by a fairly broad fold of mucous membrane. When the cleft is bilateral, the intervening portion of the lip, which is called the prolabium, lies over the pre-maxillary bone, which is separated from the maxillary bones on each side, and is of variable size. The central portion of the lip may be quite small, and the columella may be more or less absent, so that the pre-maxillary bone is tilted forward and may be merely attached to the columna nasi. In other cases the prolabium is larger, and the pre-maxillary bone is attached to the septum nasi.

**Treatment.**—The first question which arises in the treatment of hare-lip, whether alone or in conjunction with cleft palate, is *the age at which the operation should be performed*. It may be said that the sooner the operation for hare-lip alone is performed the better is the result both from the point of view

of appearance and also of the development of the parts and the general nutrition of the child. Two points, however, must be taken into consideration in determining the question, namely, (1) the strength of the child and its ability to stand the necessary loss of blood, and (2) the presence of any septic condition about the mouth and nose, such as coryza, snuffles, aphthous stomatitis, etc. If the child be feeble, the loss of blood due to the operation may be sufficient to cause a fatal result, and, on the other hand, when the child is weakly there is much greater liability to septic infection. As regards the second point, the presence of any septic condition of the mouth or the nose is particularly prone to lead to septic inflammation of the wound, and thus to endanger union. In the absence of these unfavourable conditions primary union almost invariably occurs, and therefore the age at which uncomplicated hare-lips may be operated upon depends to a large extent on the size of the gap. In slight simple cases the operation may be done within a few weeks or even a few days of birth. If, on the other hand, the cleft is wide, extends up into the nostril and entails a long operation and a free separation of the soft parts from the bone with a considerable loss of blood, the operation should be delayed until the child is at least three months old. This must certainly always be the case in double hare-lip. In all cases, however, unless there be some very strong contra-indication, such as marked marasmus, the operation should be performed before the occurrence of dentition.

*When cleft palate complicates hare-lip*, the question whether the operations for uniting the hare-lip and the cleft palate should be done at the same time or separately has to be considered. It is a generally accepted rule, and one with which we are disposed in the main to agree, that the hare-lip should be closed as soon as possible, whether the operation on the palate be deferred to a later period or not. This is advisable, because the development of the parts improves directly the lip is united, the cleft in the palate, and especially in the alveolus, apparently tends to diminish, and the nutrition of the child becomes better.

*When there is a bilateral cleft of the alveolus and the palate, with a projecting pre-maxillary bone*, it is of the greatest importance to unite the lip as soon as possible in order to remedy the severe deformity and to render the proper feeding of the child possible. It is advised by some that the operation on the palate should precede that on the lip and that the former should be done at quite an early age, from a few months upwards. The principal reason for the first of these recommendations is that the gap in the lip gives the surgeon freer access, and this is a point of considerable importance when the small size of the parts is borne in mind. While we do not think that this is necessary in the majority of cases, it may be called for when the parts are very small, the cleft in the palate very wide, and where it is obviously impossible to obtain closure of the cleft by a single operation. In such cases the extra room obtained by operating on the palate before closing the cleft in the lip is of considerable assistance. But in the majority of cases

we believe it is best to close the lip first and to leave the closure of the palate until a later period.

The chief essential in operating on hare-lip is to repair the cleft so that no notch shall be left after operation, and the red line of the lip shall be united accurately. The two points already referred to must be especially borne in mind, namely, (*a*) the fact that the edges of the cleft are bound down to the gum, and (*b*) that the nostril on the affected side is broader than on the other. We shall consider the following cases: (1) Where the cleft does not extend into the nostril: (2) where it does extend into the nostril: (3) where this extension into the nostril is associated with cleft of the alveolus and perhaps of the palate as well; and (4) double hare-lip.

**1. An incomplete cleft in the lip.**—The closure of the gap here is usually comparatively simple. In the first place, any binding-down of the lip to the alveolus must be freed, and then the gap is pared so as to leave

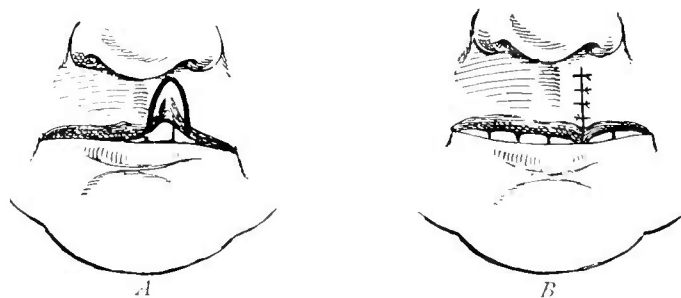

FIG. 58.—OPERATION FOR SIMPLE HARE-LIP WITHOUT WIDENING OF THE NOSTRIL. By paring the edges by means of the concave incision shown in *A*, a small downward projection is left at the free margin of the lip when the edges are sutured (*B*). The subsequent contraction of the scar neutralises this.

a concave surface on each side. The knife is entered just above the apex of the cleft and the curved incision shown in Fig. 58, *A*, is made through the whole thickness of the lip on each side. When the two cut surfaces are brought together in the middle line there will be a projection downwards of the red line (see Fig. 58, *B*), which is afterwards obliterated by the contraction of the vertical scar. The stitches are inserted so as to bring the red line in accurate apposition on the two sides. The sutures in the mucous membrane should be of fine catgut, at the red line and at the centre of the vertical wound, of silkworm gut going through nearly the whole thickness of the lip. One or two intermediate stitches of fine horsehair will complete the union.

Although the cleft does not extend into the nostril, the latter may be unduly broad, and under such circumstances it will be necessary to remedy this also. The concave incision should be carried vertically upwards from the apex of the cleft into the nostril on each side and the ala freely detached from the bone. A narrow vertical strip of the whole thickness of the lip is then removed so that when the sides are stitched together the nostril is brought sufficiently inwards (see Fig. 59).

**2. A complete cleft of the lip.**—A variety of methods are employed

for complete clefts of the lip, some of which are figured in the accompanying diagrams (see Figs. 60-65). We shall only describe the operations that we most commonly employ.

When there is a complete cleft of the lip without any affection of the alveolus, the first step in the operation is to separate the margins of

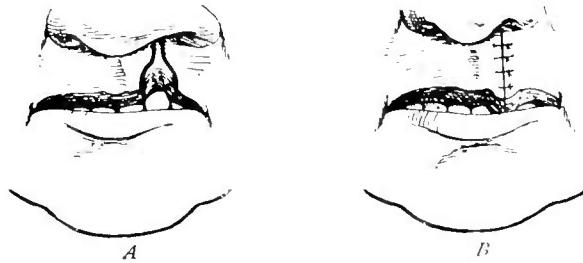


FIG. 5.—OPERATION FOR SIMPLE HARE-LIP WITH WIDENING OF THE NOSTRIL. By carrying the incisions up into the nostril (*A*) the ala is brought well in as the edges of the gap are brought together (*B*).

the cleft from the gum; on the affected side this separation must be continued until the upper border of the lip is separated from the margins of the bony nostril, the ala of the nose is thoroughly detached and the cheek sufficiently freed to allow the margins of the cleft to be approximated without any tension. The edges of the cleft are then pared in the following manner: the surgeon notes on which side the cleft is most vertical, and through the other a narrow sharp-bladed knife is entered just external to the edge of the cleft and carried through the thickness of the

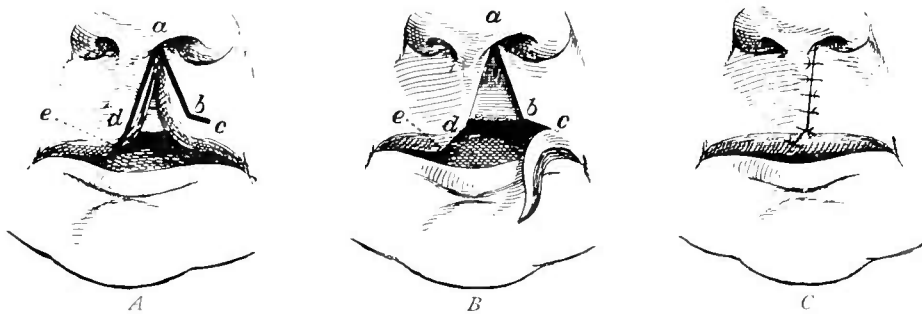


FIG. 60.—MIRAULT'S OPERATION FOR HARE-LIP. The steps of the operation are fully described in the text. Whenever there is any undue widening of the ala, the incision must be carried well up into the nostril, even though the cleft may not extend into it. The angle at *d* should be more marked than it is shown here.

lip directly downwards from the nostril parallel with the edge of the cleft; as it approaches the red line it is diverted obliquely outwards right through the free edge of the lip (see Fig. 60, *A*). This strip of mucous membrane which is angular in shape, the angle *d* being a little above the red line, is completely detached. The outer side of the cleft, which is usually the shorter, is pared similarly above, but just before the red line is reached, the incision is carried outwards parallel with it into the substance of the lip; this pared edge is not completely detached. The pared flap is turned down and leaves an angular raw surface *a b c* (see Fig. 60, *B*). A silkworm-



gut stitch is now put in from the point *d* to the point *a* and tied. A similar stitch is put in above to unite the margin at the nostril and bring the ala of the nose into position. A third deep suture between these two will allow a few horsehair stitches to unite the wound completely. The flap, consisting of the red line of the lip on the outer side of the cleft must now be fitted to the raw surface left on the mesial side of the cleft; it must be fashioned so that the red line fits accurately. Fine horsehair stitches are used for the cutaneous, and catgut stitches for the mucous, surface. If the incision parallel with the red line on the vertical side of the cleft be carried far enough, no angular deformity will be left, and the contraction during healing, although it may slightly draw up the lip, will not produce any marked notch. If the nostril be unduly small after the stitches are put in, it is well to put a small drainage tube in it so as to leave breathing space; fatal cases are recorded from the valve-like action of the upper lip combined with the blocking of the nostrils by clot obstructing the breathing. In time the nostrils will become quite patent.

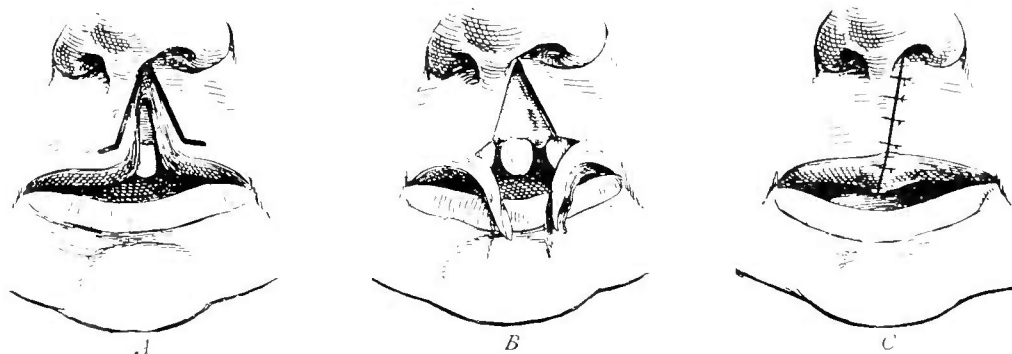


FIG. 61.—MODIFIED MIRAULT'S OPERATION. The flaps are left undetached on both sides of the cleft, and, after the gap has been closed, they are so cut down as to leave a downward projection on the free line of the lip (C) which the contraction of the cicatrix subsequently obliterates. This operation is often spoken of as Malgaigne's.

As soon as the bleeding has stopped, the line of incision is painted with collodion and the following method, introduced by Lord Lister, is of value as a support to the wound. A double thickness of gauze is cut in the shape of a bat's wing, one broad surface lying over each cheek and the narrow intervening portion passing across the lip. One end of this dressing is then fastened to the cheek with collodion, and, when it is dry, the two cheeks are pushed forward and held in this position while the other end is fixed with collodion to the other cheek and held in position until it is quite dry; in this way all tension is avoided.

*After-treatment.*—The stitches can usually be removed at the end of a week; in fact, the horsehair and catgut sutures may be removed in two or three days, the deeper silkworm-gut stitches being left for a week. After the operation the child should be entirely fed by the spoon with very great care to prevent injury to the line of incision: the point of the spoon should be introduced at the side opposite to that operated on. After the wound has healed, the patient may be put on the bottle.

In some cases a certain amount of contraction of the lip opposite the point of incision occurs even after this operation, and with the view of avoiding this, flaps may be cut on the two sides and turned down instead of detaching the flap on the mesial side of the cleft; when the sutures are inserted this leaves the red line of the lip actually projecting downwards (see Fig. 61). Should the subsequent contraction not completely remove this small protuberance, it can afterwards be cut away. When there is only a slight drawing-up, Nélaton's operation will easily remedy it. In this an angular incision parallel to and just outside the edge of the notch on each side is made through the whole thickness of the lip and then the mucous edge of the lip is pulled downwards and the incision transformed into a lozenge-shaped opening which is stitched together so as to leave a vertical cicatrix (see Fig. 62).

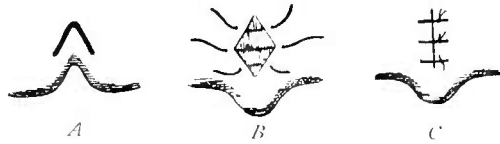


FIG. 62.—NÉLATON'S OPERATION. This is most useful when there is a pucker left in the lip after a previous operation. *A* shows the A-shaped incision converted into a lozenge-shaped opening in *B*, which is sutured as shown in *C*.

**3. Unilateral hare-lip with cleft of the alveolus.**—Here the deformity is usually greater and the additional points requiring attention are the projection forward of the cleft alveolus on the mesial side of the cleft and the undue breadth of the nostril. The projection forwards of the margin of the alveolus, if only slight, is often gradually overcome by the pressure of the repaired lip, but, when it is very marked, the repair of the lip cannot be done satisfactorily until the projection of the alveolus is remedied. In these cases, therefore, after detaching the lip from the bone, as in the preceding operations, the alveolus must be forced into position. This is usually done by seizing the projecting bone above the roots of the teeth with a pair of strong forceps whose blades are covered with tubing and forcibly bending it back; as a matter of practice it is usually necessary to fracture the alveolus to prevent it springing forward again when the forceps are removed. It may sometimes be necessary when suturing the lip in position to pass a wire suture through the alveolus on each side in order to keep the prominent portion back. Before doing this, the opposed surfaces of the alveolar cleft should be pared.

The second point which requires attention is the broadening of the ala. The lip on the shorter side of the cleft is usually very deficient, not merely in breadth but in length, and, if the ala of the nose be simply detached as in the preceding operations, the nostril will be completely closed when the two sides are brought into apposition. Under these circumstances it is well, before detaching the ala, to carry an incision upwards on the cheek around it so as to separate it from the upper lip, as for repair of the upper

lip (see p. 143), and then to remove a small elliptical portion of the cheek in addition so that, when the lip is brought inwards, the ala is not carried inwards to the same extent (see Fig. 44). By operating in this manner the lip can be completely repaired without unduly narrowing the nostril. This is even more important in cases of bilateral cleft where both sides of the lip are shortened. In other respects the operation is carried out as described above.

**4. Double hare-lip.**—Double hare-lip is usually complete, but if it is not, the incisions must be carried up into the nostril. The first point for consideration is what shall be done with the pre-maxilla and the prolabium over it. In any case the prolabium must be detached from the bone and the latter should never be removed if it is possible to avoid it. If it be taken away, a gap is left into which the central unsupported portion of the lip falls and a most unsightly appearance results. In most cases the bone can be easily forced back into position by firm pressure after the prolabium has been detached. In other cases it is connected with the septum and cannot be forced back until the latter has been divided. This may be done through an incision in the mouth along the margin of the septum. The mucous membrane and periosteum are detached on each side, and the septum is then cut across or a V-shaped portion is removed from it (see Fig. 63). If it merely be divided transversely, the anterior part of the septum is pushed a little to one side of the posterior so that, when the pre-maxilla is forced back the anterior part slides along the side of the posterior and allows the bone to come into position. In whatever way the pre-maxilla is brought into position, the mucous surface on each side should be pared, as well as that on the opposite sides of the gap in the alveolus and these raw surfaces should be fastened together by catgut stitches running through the mucous membrane of the gum.

When it is impossible to get the pre-maxilla into position, an incision may be made into its lower edge and the teeth scooped out of it; a shell of bone and periosteum is left which will subsequently ossify and support the central part of the lip.

Attention is next directed to the prolabium. In some cases the columella is so short that the prolabium when pared is simply sufficient to repair this or at most to provide a little triangular tongue extending into the lip. When the columella is long enough, the prolabium must be pared, usually in a rectangular manner (see Fig. 64) to fit in between the sides of the lip when they are brought inwards. The lip on each side is then separated from the alveolus in the usual manner, and it is often advisable to carry an incision up around each ala and to remove an elliptical portion of the skin as already described above (see p. 143) so as to allow the two sides of the lip to come



FIG. 63.—V-SHAPED INCISION IN THE SEPTUM FOR PROJECTING PRE-MAXILLA. The dotted line on the lip is intended to be upon the septum. The lip should be turned back to show it.

together without unduly diminishing the nares. The edges of the cleft are then pared and sutured (see Fig. 64, *B*). As a rule it is well to prolong the

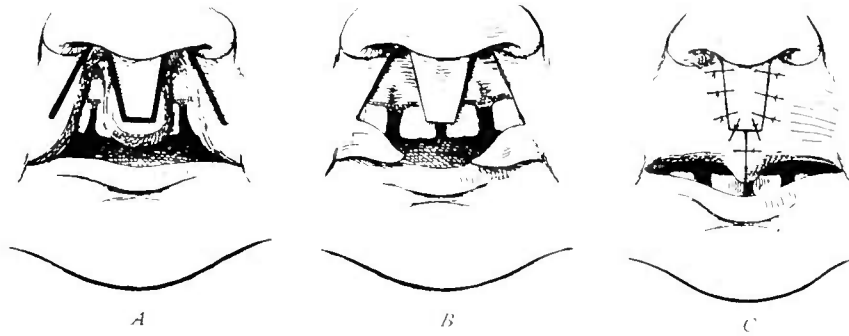


FIG. 64.—OPERATION FOR DOUBLE HARE-LIP. The two flaps of mucous membrane shown in *B* are trimmed down so that they make the slight downward projection in the middle line of the lip (*C*).

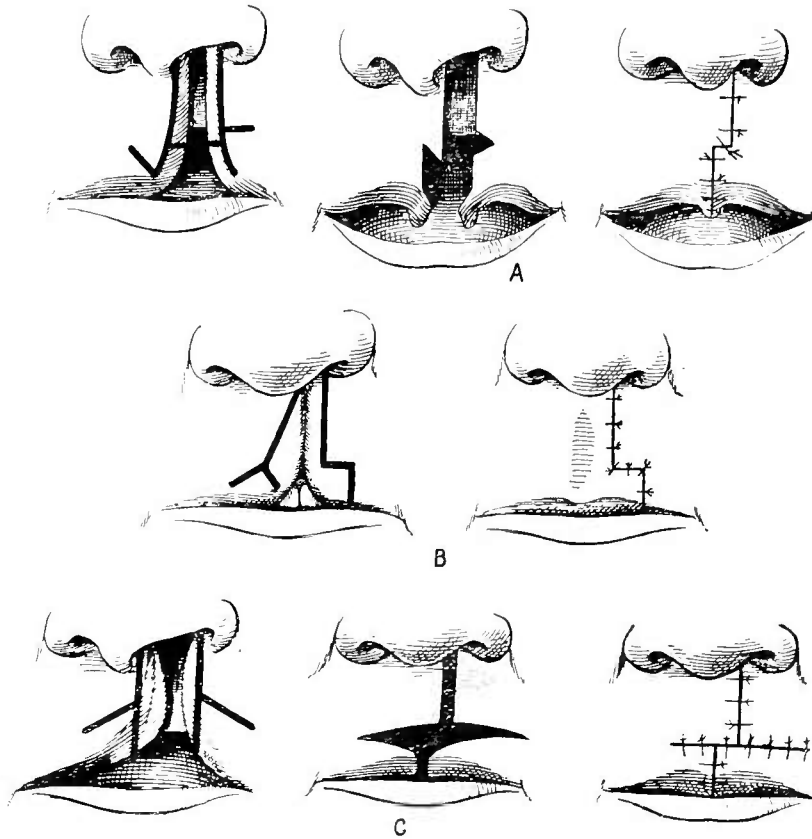


FIG. 65.—VARIOUS HARE-LIP OPERATIONS. These forms of the operation are more complicated than the others, and are best suited for clefts in which the edges are fleshy and fairly symmetrical.

*A* is Hagedorn's operation, *B* is Simon's, and *C* is König's.

incisions downwards and outwards into the lip above the red line, but without detaching the pared portions on either side until the stitches have been put in. The red line when stitched together should show a slight downward

projection in the middle line: this disappears as contraction takes place, or, if it does not, it can be pared down later on.

**COLOBOMA FACIALIS.**—In this condition a congenital cleft runs upwards through the lip and passes externally to the ala of the nose as far as the internal angular process of the frontal bone. It is a rare condition, is sometimes combined with a cleft of the palate and is sometimes bilateral. The operation required for closing the cleft will depend on its extent: as far as the lip is concerned, the operation is practically the same as for hare-lip.

#### CLEFT PALATE.

**Varieties.**—When the palatal processes fail to coalesce, the following conditions may result: 1. Cleft of the soft palate alone. 2. Cleft of both hard and soft palate. 3. Cleft of the alveolar margin without implication of the palate. Besides these common conditions, there is sometimes a cleft of the hard palate and the alveolar margin without implication of the soft palate, and in some extremely rare instances there may be a central aperture either in the soft or the hard palate. The cleft in the hard palate may be unilateral or bilateral. Generally the septum is united to one side of the cleft, which only passes up into one nostril, but in bad cases, especially those associated with double hare-lip, the septum lies free between the two sides of the cleft in the hard palate. In most cases of cleft hard palate the roof of the mouth is unduly arched, and in bad cases it runs almost vertically upwards and is narrower than usual, so that the material available for closing the cleft is very scanty.

**Treatment.**—The operation for uniting a cleft palate demands more time than that for hare-lip, and entails greater loss of blood and more shock, and for these reasons it cannot be done with safety at so early a period of life. It is, however, essential that the cleft should be closed before the child learns to talk, as otherwise the peculiar articulation associated with cleft palate is extremely difficult to correct afterwards. The probable explanation of the persistence of this nasal voice is that the entire absence of nasal breathing due to the presence of the cleft palate, if allowed to persist, prevents proper development of the nasal cavities, and thus, when the cleft is closed, the nasal resonators are ill-developed and do not act properly. Unless there are very strong reasons against it, the operation should not be delayed beyond the third year of life, the most favourable periods being from eighteen months to two and a half years. In some cases, where the cleft is not very bad, the operation may be performed before the eruption of the teeth, from the fifth to the eighth month, but it is well not to perform the operation during the period of active dentition, as, owing to the irritation of the mouth then present, union is apt to fail. The child should be well nourished and able to stand the necessary loss of blood, and at the same time should be sufficiently amenable to its nurse not to endanger union by too much crying.

If both hard and soft palates be cleft, it is well if possible to unite both at

the same operation. When failure occurs it is usually in the soft palate, especially towards the anterior part at its junction with the hard palate. Failure of union of the hard palate is not so common.

**Preliminary measures.**—One of the most important elements of success is the preliminary treatment of the patient. For some time previous to the operation the feeding should be carefully attended to. As much nourishing liquid food as possible should be given, and if necessary iron or other tonics. Young children should be fed with a bottle, the teat of which is fitted with a large palate-shield especially designed for this purpose. Older children should be carefully fed with a spoon. Prior to the operation the teeth must be seen to, any carious stumps removed, and any aphthous or other ulceration about the mouth appropriately treated. It is not at all uncommon to find in these children severe chronic pharyngitis accompanied by dryness of the membrane and the secretion of quantities of tenacious mucus. This condition, which is dependent to a great extent on the presence of the cleft, cannot be entirely got rid of, but it must be improved as much as possible before the operation, the parts being frequently sponged with boracic or carbonate of soda lotion (gr. x. ad ʒj). Nasal breathing should be encouraged and the general health attended to. If there be any coryza, the operation should be delayed. Adenoids are not uncommon in these cases, and should be removed before the operation, partly because the operation can be more easily done, but mainly because they block the naso-pharynx after the operation, interfere with respiration, and lead to the accumulation of discharge above the palate.

**The operation.**—In performing the operation it is very important to have a good light and skilled assistants. The table should be so arranged that the light falls directly into the patient's mouth, and it is well to have the head fully extended, partly because it is thus possible to see and manipulate better and partly because the blood will then collect in the naso-pharynx and is not so likely to enter the air passages. The thorax may be raised by suitable pillows, or the patient may be brought to the end of the table so that the head projects beyond it. The surgeon will most conveniently sit at the head of the table, and it is well to have the seat at such a height that the patient's head rests upon his lap. The child's arms and legs should be secured, as the patient is apt to come partially out of the anæsthetic during the operation.

The question of *anæsthesia* is of great importance in these particular cases, and a skilled anæsthetist is a valuable help to the operator. The anæsthetic should always be chloroform and is best administered by the open method on the corner of a folded towel. This is better than the usual plan of employing Jünker's nasal tube, for, if the latter be pushed up the nose, it is apt to injure the mucous membrane and form a focus of future inflammation, while if introduced into the mouth it gets in the way of the operator. Besides, irritating chloroform vapour blown on the line of incision does not tend to promote union. It is therefore best, after having

got the patient fully under, to saturate the corner of a towel with chloroform and to take advantage of every pause in the operation to maintain the administration. If care be taken to fully anæsthetise the patient before the operation is commenced, it is comparatively easy to keep him under as long as the operation lasts. Accumulation of blood in the pharynx must be carefully watched and sponged away as soon as it becomes excessive.

The assistant's duty is to maintain the gag in position and to sponge for the surgeon; the sponging must be done very carefully so as not to

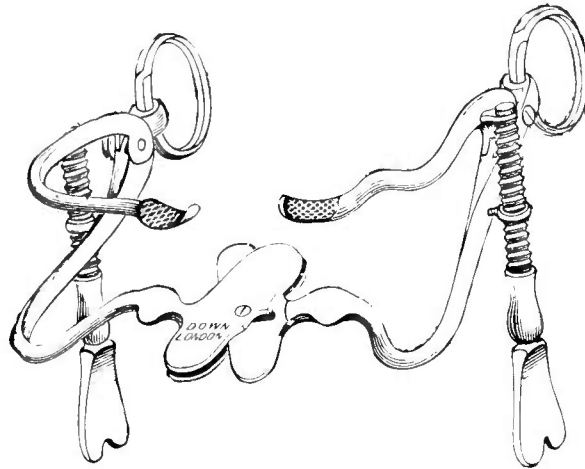


FIG. 66.—SMITH'S GAG.

bruise the delicate flaps, but at the same time the throat must be effectually cleared of blood. The mouth must be held well open with a *gag* and some self-retaining instrument is the most satisfactory. The one most commonly employed is Smith's (see Fig. 66), or some modification of it,

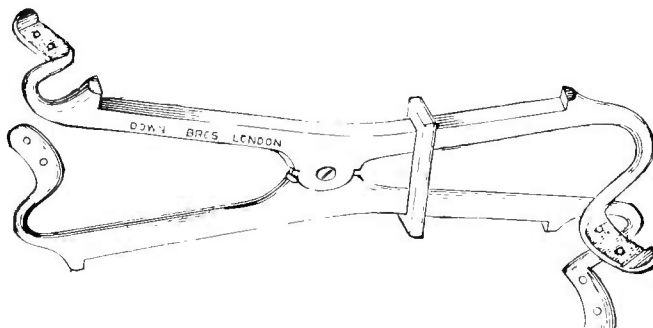


FIG. 67.—ROSE'S GAG.

provided with a tongue-plate to keep that organ out of the way. It is also fitted with rings through which a bandage can be passed behind the head so as to keep it in place. The objections to this form of gag are in the first place that the tongue-plate is apt to force the tongue back and embarrass the respiration; this can generally be avoided by careful insertion of the gag; the other objection is that the upper half of the gag takes its hold behind the alveolus in the middle line and may render it difficult to work quite at the anterior part of the cleft. When these difficulties are met with, Mason's gag, or Rose's modification of it (see Fig. 67), or

a self retaining spring gag, introduced by Mr. Arbuthnot Lane, which is prevented from shifting its position by small spikes thrust into the alveolus (see Fig. 68), may be used instead. When one of these gags is employed, the assistant must keep the tongue out of the way of the operator with a spatula.

The *sponges* should be of medium size and are best used on forceps or in special holders. Care must be taken that neither the forceps nor the holder projects beyond the sponges and that the sponge cannot be displaced laterally so as to uncover the end of the instrument which grasps it; otherwise laceration of the flaps or the back of the throat may occur. When sponges are fixed on handles care must be taken that the sponge does not get detached—an accident that is rather apt to occur.

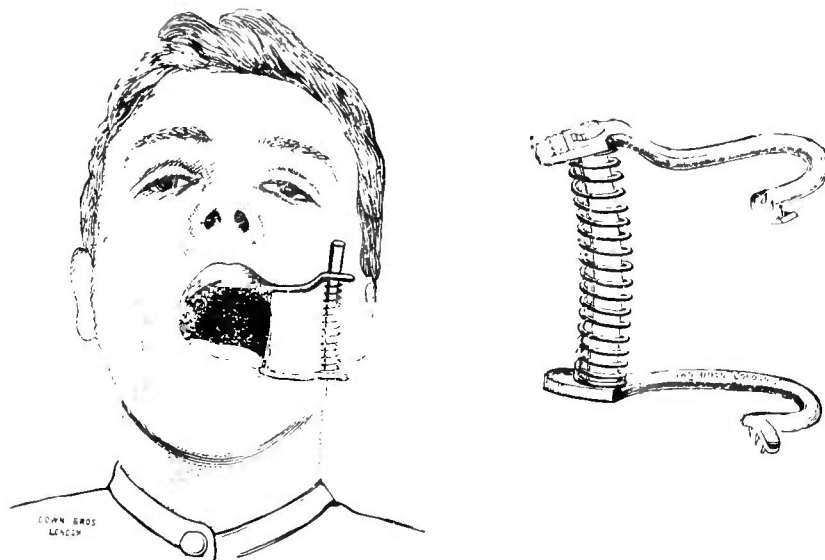


FIG. 68.—LANE'S GAG. The small spikes on the arms of the gag stick firmly into the alveoli and prevent the gag from slipping.

The operation that is generally performed at the present day is called Langenbeck's; in a typical straight-forward, moderate-sized cleft occupying the entire hard and soft palate the following are the steps of the procedure. The operation may be conveniently divided into the following four stages: 1. paring the edges of the cleft; 2. formation of the muco-periosteal flaps; 3. the passage and tightening of the sutures; and 4. the relief of lateral tension. Advantage is generally taken of the intervals between these stages to arrest hæmorrhage, to thoroughly clear the throat of blood and to administer more anæsthetic.

**1. Paring the edges of the cleft.**—This is best done by seizing the extreme tip of the cleft uvula on one side with a pair of special long-handled catch forceps. By pressing these forceps backwards and downwards the palate is put firmly on the stretch and a sharp-pointed, long-handled, narrow-bladed palate knife is inserted through the thickness of the soft palate just external to the edge of the cleft with its back to the forceps. Then, by steadily cutting towards the apex of the cleft, a paring



is detached from the entire edge, which should be of uniform thickness throughout. The strip is left attached at the apex, the knife is turned round and carried back and the paring continued to the tip of the uvula just outside the forceps (see Fig. 69). A similar procedure is carried out on the opposite side and then the strips are completely separated by paring the V-shaped end of the cleft in front. It is important to pare each edge of the cleft in a single piece, so as to ensure it being pared throughout; if done piecemeal, some part may be overlooked and the thickness of the pared surface will be very variable. We consider that it is well to commence with the paring of the edges, although some recommend that this should not be done until the flaps have been detached, for fear of damaging the pared edges by the sponging necessary to clear the throat. This danger is however slight with a skilled assistant, and the process of detaching the flaps and paring the edges is much easier and more satisfactory if it be done as here recommended. The bleeding after paring the edges is very slight and stops quickly.

## 2. Formation of the muco-periosteal flaps.

—An incision on either side of the hard palate running from behind forwards is made with a stout knife. It commences behind opposite and just internal to the last molar tooth and is carried forward parallel with the alveolar margin until it reaches up to the level of the apex of the cleft on each side in front.<sup>1</sup> This incision is often followed by fairly smart hæmorrhage, as the posterior palatine artery is in danger of being wounded. This vessel may sometimes be felt pulsating through the soft parts, and the incision is then planned so as to miss it. It is generally avoided if the incision be kept quite close to the last molar tooth. The knife must be held perpendicular to the plane of the mucous surface so as to avoid bevelling of the edges of the flap. If the hæmorrhage be severe, sponge pressure may be applied for a few moments to check it, but it is best arrested by proceeding immediately to the detachment of the muco-periosteal flaps from the bone. The detachment of the flaps is effected by fine raspatories of

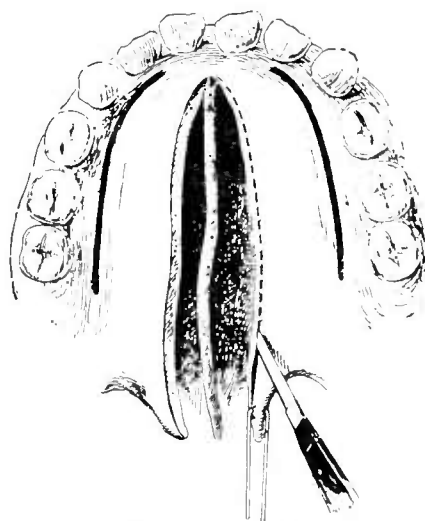


FIG. 69.—PARING THE EDGES OF THE CLEFT IN THE PALATE. On the one side the edge has already been pared and the narrow strip of mucous membrane is seen hanging from the apex of the cleft. On the opposite side the paring is just being begun. The lateral incisions for raising the muco-periosteal flaps from the hard palate are also indicated.

<sup>1</sup>If the cleft be complete, *i.e.* if it extends through the alveolus, the incision does not go as far forward as the end of the cleft as otherwise the blood supply to the front end of the flap from the anterior palatine would be cut off. This leaves a small triangular gap in front when the flaps are approximated, and this is closed after the rest of the palate has united by prolonging the incisions forward through the free margin of the cleft anteriorly and turning in the little flaps thus formed.

varying curves introduced through the lateral incisions. The more curved are used first and, as the detachment proceeds, the straighter ones may be employed. Special curves may be required for the detachment of the anterior portion. In detaching these flaps care must be taken to avoid damaging them as they are often very delicate. The point of the raspatory should be gently inserted between the flap and the bone and the separation made by gentle lateral movements, so that there is no stretching of the parts and no danger of running the point of the instrument through the flap. When the cleft is reached, the point of the raspatory is brought out between the bone and the mucous membrane. Special care must be taken with the detachment at the anterior ends. When both sides have been detached, it is generally easy to ascertain whether the flaps have been freed enough by introducing a detacher beneath each flap and drawing them together. The edges ought to come together without any material tension.

It is next necessary to divide the aponeurosis attaching the soft palate to the hard in order to allow the flaps to come together posteriorly. The mucous membrane extending from the upper surface of the soft palate into the nasal cavities must also be divided so that the whole palate can hang down freely into the mouth. This division of the mucous membrane and fascia is best done with a pair of angular scissors, one blade being inserted between the muco-periosteum and the under surface of the bone, while the other is in the naso-pharynx above the upper surface of the soft palate.

After the flap has been thus detached on each side, a short pause is made while the hæmorrhage is checked by gently pressing the flap against the bone with sponges.

**3. Suturing the flaps.**—After the hæmorrhage has been arrested, the throat sponged, and the patient brought fully under the anæsthetic, the third stage, that of passing the sutures, is reached. For uniting the hard and the greater part of the soft palate we prefer silkworm-gut. Many surgeons employ silver wire, but the gut seems to be less irritating to the dorsum of the tongue, and is also somewhat easier to tie. The last one or two sutures which unite the divided halves of the uvula may be of fine horsehair. The best way of passing the sutures is that known as the "loop method." The stitches are introduced by special long-handled needles (see Fig. 69A) bent at varying angles and curves, carrying an eye for the suture near the point so arranged that the puncture made by its passage is at right angles to the edge of the cleft, so that when the suture is tightened the aperture is somewhat diminished. A needle is threaded with a long piece of fine silk, the two ends being of equal length, and is passed through one side of the cleft about an eighth of an inch from its margin: it should pass through the whole thickness of the flap. It is well to put the first stitch in at the junction of the soft with the hard palate so as to insure the exact apposition of the two halves. When the needle has penetrated the flap, the loop of silk in the eye is caught up in a pair of forceps

or a sharp hook and the needle withdrawn, leaving the loop emerging from the upper surface of the flap (see Fig. 70). With a needle curved in the opposite direction, a silkworm-gut stitch is passed at a corresponding point

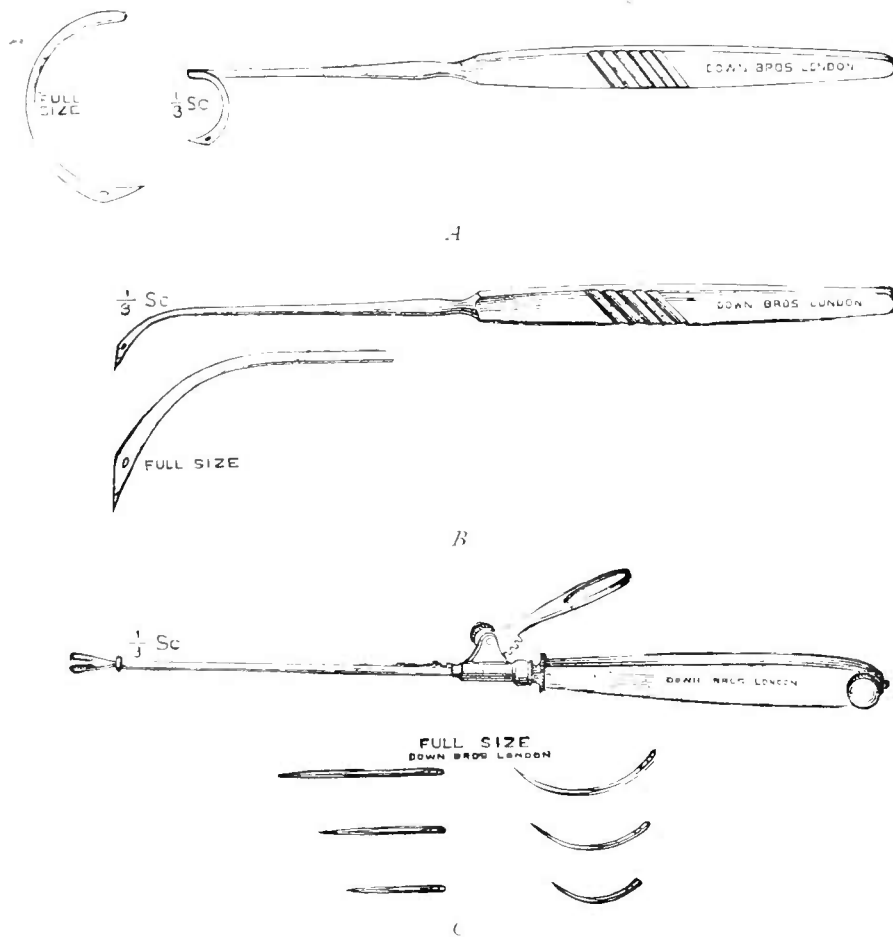


FIG. 69 A.—NEEDLES AND NEEDLE-HOLDER FOR CLEFT PALATE OPERATIONS. *A* is the ordinary form, and is used in pairs, one needle being curved to the right and the other to the left. *B* is a very useful form employed by Prof. Rose. It is easy to stab it through the flaps. *C* is Lane's needle-holder, which is useful for Davies-Colley's operation (see p. 177). The needles for use with it are shown full size.

through the other flap. The end of this is seized with forceps, unthreaded from the eye of the needle and the latter withdrawn. The free end of the gut is brought out into the cleft, and then bent into a loop which is passed through the silk loop already introduced: by traction upon the free ends of the latter the silkworm-gut suture is drawn into place through the opposite flap<sup>1</sup> (see Fig. 70, *c*, *c'*). It is well to clamp both ends of the stitch in forceps, and leave it untied until all the other sutures are in position. It is unnecessary to grasp the edge of the flaps in introducing these stitches: indeed it is desirable not to do so on account of the risk of bruising. If the edge of the flap be put on the stretch by pulling on the uvula, a sharp needle can be stabbed through the palate with ease. The next stitch is best put in about the middle of the hard palate, and then the remaining

<sup>1</sup>To permit of this being done, the eye of the palate needle must be of large size so as to take really thick silkworm-gut. Should such a needle not be available, the second method indicated in Fig. 70 (see 1, 1', 2, 2'), *i.e.* the use of two silk loops must be adopted.

hard palate stitches are inserted in the same manner. The stitch through the tip of the uvula should next be inserted; it can usually be passed

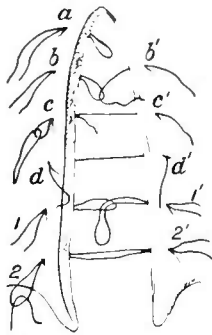


FIG. 70.—METHODS OF INTRODUCING THE SUTURES IN A CLEFT PALATE. Both methods described in the text are illustrated here. In the first method a loop *a* is passed through one side, *bb'* shows the gut suture passed single through the other side and into the loop which is then withdrawn, *cc'* leaving it in position *dd'*.

In *1, 1'* the double loop method is illustrated. In *2, 2'* the second loop, drawn through both sides, has the single gut suture looped into it preparatory to pulling it through both flaps.

directly from one flap to another without the intervention of the loop. For the posterior stitches horsehair should be employed. All the stitches should be drawn through before they are tied, each pair of ends being caught in Spencer Wells' forceps. The back of the throat is now thoroughly sponged out, the line of incision gently cleared from blood-clot and mucus, and the stitches are tied. In tying the latter it is advisable to employ the surgical knot, that is to say two turns should be taken in the first hitch so that it does not slip while the second half of the knot is being tied. The ends should be cut moderately long, so that they may lie against the palate and not project directly on to the dorsum of the tongue. At this stage it is very necessary that the patient should be deeply anæsthetised so as to prevent any retching or vomiting, and care must be taken to sponge away all mucus from the raw surfaces.

#### 4. The relief of lateral tension.

The last stage in the operation is the relief of lateral tension on the soft palate. It is sometimes recommended that this should not be done unless there be marked tension, as ascertained by the pressure of the finger on the united palate. It is however well always to effect it, as its object is rather to prevent tension from the subsequent pull of the palate muscles

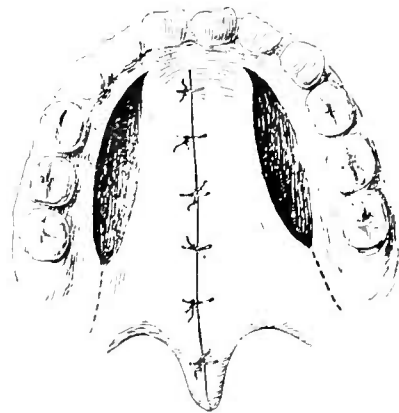


FIG. 71.—THE RELIEF OF LATERAL TENSION IN THE SOFT PALATE. The edges of the cleft have been sutured. The dotted lines indicate the downward prolongations of the incisions on the hard palate, in order to relieve the tension.

than to relieve any actual tension due to the operation. It is best done by introducing a probe-pointed knife into the posterior extremity of each lateral incision and prolonging it vertically backwards into the soft palate,

the incision passing just internal to the hamular process. It should extend through at least half the vertical depth of the palate on each side (see Fig. 71). This procedure sometimes results in smart hæmorrhage from the posterior palatine artery or some of its branches; this may generally be arrested by gentle pressure with a small piece of sponge in the opening, or, failing that, by syringing with iced boracic lotion.

*After-treatment.*—The gag is now removed and the patient put to bed with the head low and turned to one side so that the blood may trickle out through the mouth. There is often a good deal of shock, and the patient should be surrounded with hot bottles or be put upon a large hot-water pillow. Food should not be given until all danger of vomiting has ceased, and for the first four or five days nothing but liquids should be taken; during the first 48 hours these are best given iced. The food should consist of milk, milk and soda or milk and lime-water. It is best given with a spoon and later on from a feeder furnished with an indiarubber tube which is passed as far back as possible at the side of the mouth. After the fourth day bread and milk, custards, arrowroot, etc., may be given, but no solid food should be administered for at least ten days.

The most important part of the treatment consists in keeping the patient absolutely quiet. Talking, laughing, crying, etc., must be guarded against as effectually as possible. The hands should be muffled if necessary and tied to the side to prevent the risk of the child sucking the thumb or fingers,<sup>1</sup> and care must be taken to see that no toys or other things that the child might introduce into his mouth are at hand. It is also a good general rule to insist that no one shall be allowed to inspect the wound for at least ten days; such inspection can do no good and may do harm. At the end of that time the palate should be examined and the stitches removed, at any rate from the hard palate; in order to do this satisfactorily, it is well to administer an anæsthetic. Should the union be good, all the stitches may be taken out then; if at any part the union is doubtful they should be left in for a few days longer.

**Davies Colley's operation.**—Recently another operation has been introduced by the late Mr. Davies Colley (see Fig. 72), which is of advantage in some cases, especially where the cleft is very wide, where several operations have been done and have failed, leaving much cicatricial tissue, or in infants where early operation is desirable. It consists of the following steps. A large triangular flap consisting of all the soft parts is first cut from one side of the hard palate; if the two sides be unequal in size, it should be taken from the larger. This flap is marked out by an incision starting opposite and close to the last molar tooth, running forward parallel with and just internal to the teeth as far as the apex of the cleft. The incision is then carried downwards along the edge of the cleft about a sixth of an inch external to its margin and backwards well on to the beginning of the soft palate. The tongue-like flap thus formed is raised along with the periosteum with a raspator. Along the opposite side of the cleft an incision is made about a quarter of an inch external

<sup>1</sup> A perfectly effectual plan and one that is less irksome to the child is to mould small splints of cardboard or felt along the front of the arm from the middle of the upper arm to the middle of the fore-arm. This prevents the child flexing the elbow; he therefore cannot reach his mouth, but he can use his arms and can play with his toys, etc.

to its margin, commencing in front near the apex and running backwards to the junction of the hard and soft palates. The extremities of this incision should be carried transversely inward as far as the free margin of the cleft. With a raspatory the small flap thus formed is separated from the bone, the base of the flap being formed by the tissues covering the edge of the cleft. There is thus no actual paring of the edges in this operation. The smaller flap is now turned inwards upon its base so that its raw surface looks downwards into the mouth; it is fixed to the mucous membrane on the opposite side of the cleft by two or three catgut sutures.<sup>1</sup> The large triangular flap is then carried across the cleft and its apex is attached by a few silkworm-gut sutures to the mucous membrane at the outer edge of the raw surface made by turning in the small flap (see Fig. 72, *B*). These sutures are introduced by fine fully curved needles. The effect of this is to partially close the cleft in the hard palate with a double thickness of soft parts and thus the vitality of the flaps is less likely to suffer and union is more likely to occur owing to the two vascular surfaces being thus brought into apposition. The opposed surfaces of the flaps may with advantage be

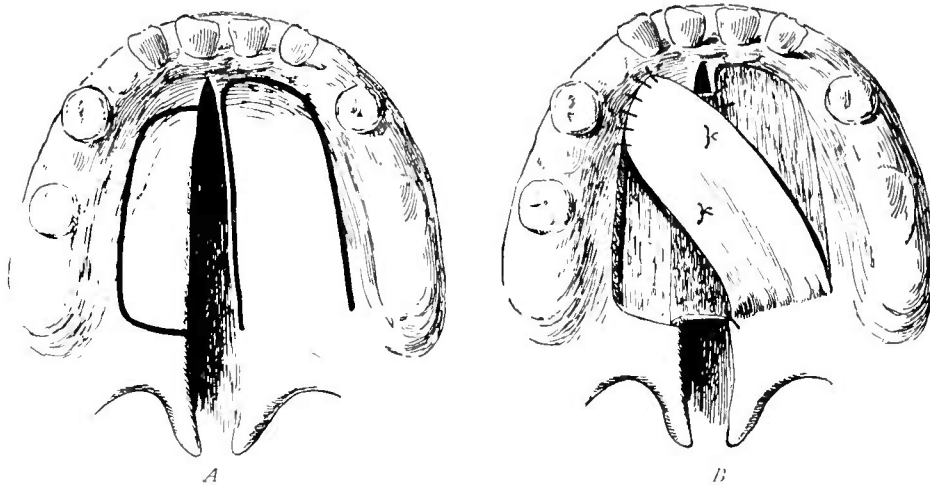


FIG. 72.—DAVIES COLLEY'S OPERATION FOR CLEFT PALATE. *A* shows the incisions for the flaps, the large one on the right-hand side of the gap having its base just beyond the junction of the hard with the soft palate. The base of the smaller or reflected flap on the left-hand side is along the margin of the cleft. In *B* the smaller flap is turned back across the cleft and sutured to its opposite edge, while the large flap is raised and applied to the raw under surface of it, its apex being sutured as shown. Two sutures are also shown penetrating the whole thickness of the two flaps so as to keep them together. These stitches are best introduced through the reflected flap before the larger one is placed over it; the ends are then brought through the latter and tied.

secured together by one or two fine horsehair or silk sutures passed either through the edges or, better, through the whole thickness of the two flaps; if the latter plan be adopted, fine straight needles and a fine needle-holder will be required. This operation generally only succeeds in closing a portion of the cleft, a small triangular gap being almost invariably left anteriorly; this can be closed later. The soft palate may be united at the same time if the surgeon so desires, but it is perhaps preferable to postpone that to a later occasion.

In this operation there is comparatively little hæmorrhage, there is no loss of soft parts, no tension after the operation, and no likelihood of the flap sloughing, as the pressure of the tongue upon the flaps, which in the ordinary operation is so likely to cause separation, is here actually beneficial and serves to press them together. As the bridge of union thus formed consists of a double flap, it is much more likely to unite and therefore the operation may be performed at a much earlier age than the ordinary one.

<sup>1</sup>We have found it a useful plan to turn back the narrow strip of mucous membrane at the edge of the cleft left after cutting the larger triangular flap in a manner similar to that employed for the smaller reflected flap. It can generally be done without any fresh incisions: if necessary two small cuts may be carried outward into the cleft above and below.

**Complications.**—There are two complications common to all operations for cleft palate which require attention.

1. *Bleeding.*—As a rule the hæmorrhage, though free at first, is easily controlled by gentle sponge pressure. If it be obstinate, it generally results from incomplete division of the posterior palatine artery or some of its branches. Secondary hæmorrhage may also occur and is fairly common in weak, anæmic children or in those who are the subject of hæmophilia.

*Treatment.*—This is comparatively simple. If it be troublesome at the time of the operation and sponge pressure will not stop it, the clots should be carefully wiped from the region of the lateral incisions and the source of hæmorrhage exposed. If it comes from a partially divided vessel at the end of the incision, the extension of the incision will probably suffice, especially if combined with firm pressure directly upon the bleeding point either with the finger or a small piece of sponge. The treatment of secondary hæmorrhage is sometimes more difficult. In the first place an attempt should be made to check the bleeding by syringing away the clots with iced boracic lotion, and small pieces of ice enclosed in muslin may be pressed against the lateral incision from which the bleeding is coming. If this fails, an anæsthetic should be given and, after the blood-clot has been cleared away, the bleeding point should be exposed. If firm pressure on it is not effectual, and if the vessel cannot be picked up in forceps and tied, the bleeding will probably be coming from the posterior palatine canal, and an attempt should be made to stop it by temporarily plugging the canal with a fine probe. If this does not succeed, the canal may be plugged with Horsley's wax (see p. 47).

2. *Failure of Union.*—The other important complication is failure of union at some part of the cleft. The failure may be partial or entire. It generally happens that only some portion gives way and it is most common to find a deficiency either at the extreme anterior end or about the junction of the hard with the soft palate. Non-union may be due to one of three principal causes:

(a) *Imperfect operation.*—The cleft may be insufficiently pared, generally because each side has not been pared in a single piece and thus some part has been overlooked or only a very narrow portion removed; the tension upon the flaps may be so great as to interfere with union; the flaps may be brought badly into apposition, one edge being curled up so that the raw surfaces are not together; the stitches may be tied either too loosely or too tightly; or the flap may be so bruised by rough handling that its vitality is seriously diminished.

(b) *Intercurrent inflammatory affections* such as a severe cold, the onset of a specific fever or ordinary septic infection may entirely prevent union. Septic infection of the line of incision is largely predisposed to by rough handling of the flaps.

(c) *Want of proper care in the after-treatment* may bring about failure of union. Among the most important factors leading to failure of union

after an otherwise perfectly satisfactory operation are excessive crying, vomiting, or mechanical violence produced by hard food, fingers or foreign bodies thrust against the flaps.

It is well to remember that, unless union fails throughout the whole palate, the gap left after limited failure of union is diminished very considerably in the course of time by the granulations springing up around the hole. This is especially the case in the soft palate.

*Treatment.*—The treatment in cases where union seems doubtful is of course largely prophylactic, and every precaution must be taken in the way of careful operation and after-treatment to see that nothing interferes with union. Any intercurrent affection, such as a cold, should receive careful attention. If, when the wound is examined, there be any doubt as to the amount of union present, the stitches should not be removed for a fortnight or three weeks. Should failure of union occur at any part, it is well to wait until the edges are freely granulating and then, after administering an anæsthetic, to introduce fresh sutures and draw the flaps together once more, if necessary freeing them sufficiently to allow them to come together without tension. It is not generally necessary to actually pare the edges when introducing stitches for the second time although it may be advisable to scrape the granulating edges slightly. These second stitches should be left in for at least a fortnight. If this secondary union fails, it is well to delay further operative interference for a period of at least six months, so as to allow complete cicatrisation and contraction to take place. The subsequent operation consists in paring the edges of the defect, making lateral incisions for the relief of tension and then bringing the edges together. Unfortunately if the union fails in the soft palate the contraction leads to shortening of the palate so that secondary operations seldom avail to bring about a perfect result. Hence every possible care should be taken to secure union in the first operation.

**Voice Training.**—After any operation for cleft palate it is necessary for the patient to undergo a careful and often prolonged course of vocal training in order to get rid of the nasal twang which has already been acquired, and which if not treated is likely to persist. The movements of the soft palate are also greatly benefited by training of this kind; nose breathing is most important and should be taught regularly.

**Mechanical treatment.**—In some cases the surgeon may conclude that closure of the gap is unlikely to lead to any practical benefit. Such cases are those in which the cleft is very wide and there are not sufficient soft parts to close it, where the soft palate is so rudimentary as to be practically absent, where the failure of former operations has left a shrunken soft palate or where the case does not come under observation until the patient has attained adult life. Under these circumstances there is practically no hope of anything like a good result from operation, the palate being so short that the nasal voice and trouble in feeding continue. Under such circumstances, the patient will be more comfortable with an obturator than with a partially



closed palate, which in itself interferes very materially with the fitting of a suitable obturator. These obturators can be made to supply the place both of the hard and the soft palate. They are certainly difficult to fit and to manage, but, when properly fitting, they are better than a faulty operative result.

**ACQUIRED PERFORATIONS OF THE PALATE.**—These are due to traumatism or to disease, most commonly to syphilitic affections of the palate either acquired or congenital; in the former case they occur in the tertiary period. They are the result of the formation of gummata and are often accompanied by extensive necrosis of the palate or the vomer: the destruction of the palate is very rapid and extensive.

**Treatment.**—The treatment of these cases is at first palliative. *In the traumatic affections*, the frequent use of a mouth-wash of sanitas, chlorate of potash or boracic acid is indicated until granulation has occurred. If possible, stitches may then be introduced and the aperture closed. In some cases, portions of tissue may be lost and an obturator must be employed. *In syphilitic affections*, the important point is whether operative interference should ever be practised; in the early stage, while the gumma is forming, the patient should be put on large doses of iodide of potassium, 20-25 grains thrice daily, and inunction of mercury should be vigorously carried out and, in addition, insufflation of calomel and starch powder (1 in 3) should be employed. The disease extends so rapidly that the patient must be brought as quickly as possible under the influence of anti-syphilitic drugs. When necrosis has occurred, any sequestrum present should be removed and no question of operative interference should be entertained until the patient has been for some years or at any rate many months free from all syphilitic manifestations. An obturator may in the meantime be obtained, or, as a substitute in the hard palate, the patient very often can pack the aperture with gauze or some suitable dressing material very satisfactorily. Success is not likely to attend operation except when the patient is comparatively young, the aperture small and the parts not extensively cicatricial. Usually the operation must be more in the form of Davies Colley's flap method (see p. 177) than simple paring of the edges and bringing them together, although, in some cases, where the opening is small, the ordinary operation may be successful.

## CHAPTER XIV

### THE AFFECTIONS OF THE AURICULAR AND PAROTID REGIONS.

#### DEFORMITIES OF THE AURICLE.

THE chief congenital deformities of the auricle calling for a plastic operation are either excessive size or undue prominence of the organ.

*If the auricle be unduly prominent*, an attempt may be made to fasten back the ear by removing a triangular portion of the skin and cartilage of sufficient size from the posterior surface of the pinna; the amount of skin and cartilage taken will vary according to the degree of the deformity. When the parts are stitched together the ear should lie back in its normal position, and enough of the cartilage must be removed to enable it to do so. The cut edges of the cartilage are united by separate catgut sutures.

*Excessive size of the auricle* may be diminished by taking wedge-shaped pieces out of the whole thickness of the pinna, the vertical measurement being reduced by taking a wedge from the upper part with its apex near the external meatus, and the abnormal breadth being reduced by taking out a strip of cartilage and skin from the middle portion (see Fig. 73).

#### MALIGNANT DISEASE OF THE AURICLE.

As long as the malignant growth is confined to the auricle there is no difficulty in the treatment, which consists in the removal of sufficient of the auricle to leave healthy tissue all around the disease. In some cases, however, the malignant disease begins in the external auditory meatus or in the auricle in its immediate vicinity, and spreads rapidly up the meatus; the operation then becomes much more difficult and more doubtful, as the disease very early affects the glands in the parotid region, and, when these are involved, the chances of eradicating the disease by operation are very slight, unless, indeed, the parotid gland be removed as a whole, or at any rate be opened up without any regard to the facial nerve. Any attempt to combine a removal of

malignant glands in the substance of the parotid with preservation of the branches of the facial nerve will be followed almost inevitably by recurrence.

When the disease is confined to the interior of the meatus, the removal of the external auditory meatus is not a particularly difficult operation, and when the auricle is healthy it may be left and subsequently stitched back into position.

An incision is carried round the posterior margin of the external auditory meatus dividing the cartilage of the ear, and a second is made in front of it including the tragus in the elliptical incision. The soft parts on the posterior surface of the cartilage are left intact, and are pushed backwards along with the auricle. The incision is deepened behind down to the bony meatus, while in front the incision is carried down close to the outer edge of the meatus until the parotid is reached, when, the capsule being divided, the gland can be pushed forwards along with the vessels and nerves which it contains, and the cartilaginous portion of the meatus freely exposed. If the disease extends beyond the region of the cartilaginous portion but not actually on to the tympanic membrane, the former should be cleared all round with a blunt dissector until the bony meatus is fully exposed. It is

usually advisable to extend the incision upwards above the ear to facilitate the pulling forwards of the parotid. The bony meatus is now cut through with a chisel or gouge, and the portion removed along with the cartilaginous meatus. The wound is brought together above and below, leaving a central space at the bottom of which lies the tympanic membrane. Skin-grafts may be placed along the sides of this hole to promote immediate healing, and to ensure a passage leading to the membrana tympani. The auricle is then stitched back into position and the ordinary dressings applied.

When the disease has penetrated through the cartilaginous meatus and extends into the tissues around, more especially into the parotid, the patient is best left alone in the majority of cases. If operation be undertaken—and it is of very doubtful utility—it is advisable to deliberately excise the parotid gland without attempting to remove the diseased portions alone or to pick out the infected glands. Unless the entire parotid be removed, the disease is certain to recur almost immediately.

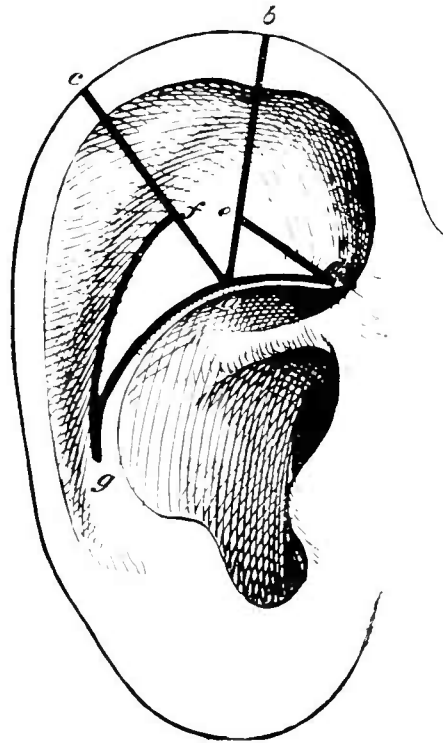


FIG. 73.—PLASTIC OPERATIONS UPON THE AURICLE. The lines *abc* show the incisions for reducing the vertical dimensions of the ear while *de, fg* represent those necessary to reduce its transverse measurement.

## WOUNDS OF THE PAROTID GLAND.

Wounds of the parotid are of importance because they may injure the external carotid artery and its branches, the facial nerve or the salivary ducts.

**Treatment.**—So far as the wound is concerned, the treatment is the same as that for accidental wounds elsewhere. The essential points to be considered in connection with these injuries are the three complications above mentioned.

**Of hæmorrhage.**—In the case of bleeding, the wound should be carefully enlarged, avoiding as far as possible any injury to the facial nerve. Hence the opening should be enlarged in an oblique direction, upwards and forwards rather than vertically. When the parotid gland is exposed, a pair of forceps may be used to separate the parotid tissue itself so as to enable the bleeding point to be exposed and seized without injuring the facial nerve. In most cases, however, it is not advisable to enlarge the wound sufficiently to apply a ligature to a deep-seated vessel, as the chance of injuring the nerve is very great; as a matter of fact, if the bleeding point be caught in a pair of forceps, which are left on for 24 hours, the occlusion of the vessel will be quite satisfactory. Again, if the bleeding be venous, it is not advisable to enlarge the wound more than is necessary to introduce a gauze plug.

When the terminal portion of the external carotid artery itself is divided the condition is very much more serious, because the vessel is deeply seated, difficult to expose and almost impossible to ligature without damage to the facial nerve. Hence, in very severe arterial bleeding from a wound of the parotid, it is best to have the bleeding point compressed with the finger and then to expose the external carotid artery at its origin. A ligature is passed around it but is not tied. By pulling upon the ligature the artery is constricted so that the wound can be sponged free from blood and another effort can be made to catch the divided end of the artery. If the latter be only partially divided it must be cut across completely. If it be completely divided and it is impossible to tie it, the ligature round the external carotid should be tightened and the wound in the parotid plugged for a couple of days so as to prevent bleeding from the upper end. The plug may then be withdrawn and the wound sutured; if, however, it be much contused, the wound had better be left open and allowed to granulate.

**Of division of the facial nerve.**—When the facial nerve is divided after it has broken up into its terminal branches, there is little hope of securing any satisfactory union. If, on the other hand, the injury occurs behind this point it might be possible after a careful search to find and unite the ends with fine catgut; but the chances of success are very slight.

When, however, facial paralysis follows a stab in the parotid region it is well to expose the nerve and try whether the ends can be united; it is then better to expose the main trunk of the nerve by the ordinary method than to try to find it by enlarging the wound. An incision is carried from just

behind the lobule of the ear downwards and forwards to the angle of the jaw, and the auricle and the posterior edge of the parotid are pulled forwards, exposing the sterno-mastoid muscle at the posterior part of the wound. The nerve lies about midway between the angle of the jaw and the zygomatic arch close to the origin of the digastric muscle, and when it has been thus exposed it can be traced forward to the point of injury, and an attempt made to unite the divided portions (see Part II., p. 250).

#### WOUNDS OF THE SALIVARY DUCTS.

These result from stabs or other wounds of the parotid gland, but in that region one of the smaller ducts alone is usually damaged, and although there may be a salivary fistula for a time it generally closes gradually.

When a wound over the parotid gland is accompanied by an escape of saliva, deep stitches should be put in to bring the gland substance together over the divided duct, and a separate row of stitches should be put in the skin. When the injured duct is quite small, the wound may heal without any trouble. In other cases a small opening remains in the line of incision through which saliva escapes. Even here, however, the tendency is for the opening to close of itself as the wound contracts. If this process be very slow it is well to touch the outer end of the sinus with solid nitrate of silver or even with the cauterium from time to time so as to prevent the spread of epithelium along the wall of the fistula and at the same time to stimulate the growth of granulations.

Sometimes, however, there may be a wound of the parotid complicated by considerable loss of skin and subcutaneous tissue, and a plastic operation must then be performed, a flap of skin and subcutaneous tissue being turned in so as to cover the defect. A small fistulous opening usually remains somewhere in the line of union, but in most instances this fistula closes as the parts contract; closure may be hastened by the treatment above mentioned.

*Wound of Stenson's duct.*—This is a much more serious matter, but, owing to the small size and deep position of the duct, it is comparatively rare except in the course of operations or in stabs or gunshot wounds. The accident is of great importance, because it is likely to be followed by a salivary fistula which is extremely difficult to cure. Hence in any wound in the vicinity of the duct this structure should always be looked out for and, if seen, its condition ascertained.

*Treatment.*—If the accident be recognised at the time of its occurrence, as for instance in the course of an operation, and if no portion of the duct has been altogether removed, an attempt should be made to suture the duct with fine catgut and then to close the deeper parts and the skin over the wound accurately by sutures. When the duct is completely divided, a good plan is to introduce along the canal a piece of stout silver wire with its ends filed round, one end emerging into the

mouth through the orifice of the duct and the other being passed along the proximal end: the two ends of the duct are then brought together, stitched with fine catgut and the external wound united. Under these circumstances the saliva will usually find its way into the mouth alongside the wire. The end of the wire in the mouth should be bent up against the cheek and guarded by a small piece of gauze: it will remain in position readily enough because it is pressed against the gums. The wire may be removed in from 24 to 48 hours, but mastication and talking should be rigorously avoided for four or five days.

When, however, the tissues are much bruised and there is danger of sloughing, this plan is not likely to succeed, and a fistula will almost certainly follow. Therefore, when the wound in the duct is in front of the masseter, the incision should be deepened into the mouth either by pushing a trochar and cannula into the buccal cavity and then dilating the canal so formed by forceps, or, better, by deliberately incising the deeper parts, bearing in mind that the branch of the facial nerve which runs along with the duct may have escaped division and should be avoided. All cutting must be done parallel with the duct.

After having made a free incision into the mouth, a few strands of horsehair should be introduced through this opening; one end of this drain should be left lying around the divided portion of the duct while the other is stitched to the mucous membrane of the mouth so as to prevent it slipping out. The external wound is then brought together either by sutures or, if sloughing be anticipated, by gauze and collodion. The object of this plan is to obtain union of the skin over the wound, while leaving a free opening into the mouth for the escape of saliva. When the external wound has healed, the horsehair may be removed, for the pressure of the saliva as it is secreted is sufficient to keep the wound open until a permanent orifice is formed.

#### SALIVARY FISTULA.

This is a permanent communication between one of the salivary ducts and the exterior; in the case of the parotid it occurs directly over the gland when one of the larger ducts of origin has been opened, or in the cheek where Stenson's duct is affected. The condition may arise from a direct wound, from injury during operations, as the result of sloughing or abscess formation or as a sequela of syphilitic or tuberculous mischief. The treatment of a fistula over the gland has already been indicated above; we need therefore only discuss the question of a fistula of Stenson's duct.

The fistulous opening may be either over the masseter or further forward on the cheek. The opening is usually small and the amount of discharge varies with the secretion of the saliva. When thoroughly established, the openings connected with Stenson's duct never close spontaneously.

**Treatment.**—Two points are aimed at in the treatment, namely—1. the diversion of the stream of saliva into the mouth, and 2. the closure of the opening in the skin. In some cases, when the orifice of the duct in the mouth is contracted and there is only a mere puncture of its wall, it may suffice to dilate the buccal orifice, to pare the edges of the opening in the cheek, and to stitch them closely together. The dilatation may be done with probes, but it is much more satisfactorily effected by slitting up the orifice so as to make a larger and more oblique opening. If possible a stitch may be inserted on each side between the duct wall and the mucous membrane.

In most cases, however, the duct is more seriously damaged, and this treatment will not suffice. The exact method of treatment will vary according to the situation of the fistulous opening; in any case it must commence by providing free escape for the saliva into the mouth. If the fistulous opening be over the masseter, the channel thus required for the escape of the saliva is of considerable length, and is best made by thrusting a large-sized trochar from the opening in the cheek forwards into the mouth; if necessary this opening may be increased by tearing the soft tissues open and snipping away the mucous membrane around its buccal end, or even by the actual cautery. A large-sized drainage tube is drawn through the opening, one end projecting into the mouth and the other outwards through the cheek. This is kept in position by silk fastened to each end, the two ends being knotted behind the ear, and should be maintained in position for at least four days, when the communication into the mouth will be fairly well established. It should then be shortened so that its outer end just reaches the duct: the inner end inside the mouth is cut level with the mucous membrane and stitched in position. The external opening of the sinus is now pared and brought together. Union in the skin wound will usually occur readily enough as the saliva passes freely into the mouth through the drainage tube, which should be kept in place until sound union has taken place: if any point fail to unite, it may be touched with caustic, or may be refreshed and again stitched up. When union is complete, the drainage tube may be withdrawn and the flow of saliva will keep open the track.

When the fistulous opening is situated more anteriorly on the cheek, it may be possible to make an incision over the duct, dissect out its posterior uninjured portion, divide it across at the fistulous communication, and then, by making a puncture through the thickness of the cheek into the mouth just anterior to the masseter muscle, to pull the duct along that track and secure it in position in the mouth by sutures, the front end of the duct being slit up for about an eighth of an inch so as to leave a larger orifice. In this way the stream of saliva flows directly into the buccal cavity, and the external wound can be pared and stitched up. This procedure, however, can only be carried out when there is a considerable length of healthy duct between the masseter and the fistulous opening: when this is not the case, the plan recommended when the opening is over the masseter must be adopted, but here the length of the track to be made for the saliva is very much shorter.

## INFLAMMATION OF THE PAROTID GLAND.

Inflammatory conditions of the parotid gland are due to a variety of causes, such as the too free administration of mercury, impaction of a calculus in the duct, the spread of septic inflammations from the mouth or the more general infection occurring in the course of pyæmia. Inflammation of the parotid is also the chief feature in the infective disease known as mumps.

When a calculus has become impacted in Stenson's duct, the parotid gland swells and becomes hard, and this swelling and sclerosis may increase considerably. Suppuration seldom occurs; indeed the blocking of the duct is usually incomplete, giving rise only to a certain amount of hindrance to the flow of saliva, especially when secreted in large quantities as at meals. It is the backward pressure of the saliva that leads to this chronic inflammation of the gland.

**Treatment.**—*When the inflammation is due to the administration of mercury*, the use of the drug should be at once suspended. Hot fomentations should be applied over the swollen gland, chlorate of potash should be given in doses of ten grains four times a day, and the mouth should be washed out frequently with a gargle of chlorate of potash or some antiseptic or astringent mouth-wash, such as sanitas or alum. This condition may or may not end in suppuration.

*When the inflammation is due to a calculus impacted in Stenson's duct*, the obvious treatment is of course to remove the calculus, when the inflammation will at once subside and the thickening of the gland will gradually disappear. The methods of removal of these calculi are described in connection with salivary calculus (*vide infra*).

*An abscess in the parotid gland occurring in the course of infective diseases*, such as pyæmia, typhoid, etc., should be opened as soon as it is evident that pus is present; otherwise it may burrow deeply into the neck. In opening these abscesses the external incision should be made as small as is consistent with the thorough evacuation of the pus, it should be horizontal and situated behind the angle of the jaw, and should not go deeper than the capsule of the gland. As soon as the latter is reached, the knife should be laid aside and a channel gradually burrowed into the abscess cavity with a pair of sinus forceps. When the cavity is reached, the separation of the blades of the forceps in an antero-posterior direction in order to avoid tearing the branches of the nerve will enable a satisfactory opening to be made, through which a good-sized drainage tube can be introduced. The subsequent details of treatment are similar to those for acute abscess elsewhere.

**Mumps** is a disease which only accidentally comes under the notice of the surgeon. Usually both parotid glands become infected within a short time of each other, and in some cases also the other salivary glands. The affection is generally quite devoid of danger and the pain and swelling subside



after a few days. In some cases orchitis or, in the female, mastitis may occur as a complication; suppuration very rarely takes place.

**Treatment.**—Hot fomentations should be applied to the part, the patient put on a fluid or semi-fluid diet, kept in a warm room until the inflammatory symptoms have abated, and kept isolated until the infectious period has passed off. Some simple saline mixture containing nitrate of potash and sulphate of magnesia may be administered.

#### SALIVARY CALCULUS.

Salivary calculus may occur in the parotid although it is more frequent in the sub-maxillary gland. In the parotid it may occur in the substance of the gland or in Stenson's duct.

The exact etiology of these calculi is not clear. They are very probably due to some alteration in the composition of the saliva whereby small hard masses accumulate in the duct and, if retained for any length of time, become infiltrated with calcareous salts, especially phosphate of lime, and in this way the characteristic small ovoid calculi are gradually formed. These calculi usually find their way forward until they are arrested close to the orifice of the duct. Their presence in the duct gives rise to considerable irritation of the lining membrane, and ulceration often occurs. Indeed, if the obstruction persist for a long time, suppuration may even take place around the calculus.

**Treatment.**—In most cases the treatment is quite simple. When the calculus is impacted in Stenson's duct it is usually situated close to the orifice and then all that is necessary is to evert the cheek, pass a fine probe-pointed canaliculus director into the orifice and slit up the duct sufficiently to admit of the calculus being squeezed out with the finger or withdrawn with forceps. The orifice of the duct is usually prominent and somewhat fixed by the inflammation and it is therefore easier to pass a probe into it under these circumstances than it is in the normal state. The most difficult cases are those in which the calculus is impacted at some distance from the opening. Even then it can generally be pressed forward by the fingers until it is within reach, when the duct is slit up and the calculus removed. If not, it may be necessary to cut down on the calculus through the mucous membrane just in front of the masseter and to slit up the wall of the duct. If that be done, no stitches should be put in, as it does not matter whether the slit in the duct closes or not.

#### NEW GROWTHS OF THE PAROTID GLAND.

Several varieties of new growths are found in the parotid, such as fibroma, myxoma, lipoma, angioma, etc., but these present no special points of importance.

**The "parotid tumour."**—Of greater interest are the so-called

parotid tumours, which contain a mixture of tissues with generally a good deal of cartilage, patches of myxomatous tissue interspersed with a certain amount of fibrous tissue, various glandular elements, and in some cases even sarcomatous tissue. These tumours are as a rule firm in consistence, irregular in outline and encapsuled. They are often very slow in growth, the simple forms do not affect the lymphatic glands, and a cure results if the whole growth and its capsule be removed. As the tumours get larger, their weight tends to displace them downwards, so that they are much more easily removed, and indeed in some cases they may pass so far downwards that the mistake is made of considering them to be unconnected with the parotid gland.

**Treatment.**—In removing these growths the skin incision should always be as free as possible because branches of the facial nerve are very apt to be adherent to the capsule of the growth, especially at the deeper part, and it is essential therefore to see exactly what is being done during the removal of the tumour. A curved incision running along the anterior border of the sterno-mastoid from the mastoid process downwards and then forwards and finally curving up across the ascending ramus of the jaw will generally give very complete access. The skin and subcutaneous tissue are dissected up, but care must be taken as the incision is deepened to avoid injuring the branches of the facial nerve. The growth is then exposed where there is least thickness of parotid tissue over it; in many cases it is found uncovered by gland tissue in front; when the tumour has been exposed, its separation from the parotid is effected with a blunt dissector until the growth can be pulled or pushed out of its bed and its deeper connections attacked. It is especially in this situation that the branches of the facial nerve are most likely to be met with, and therefore the tissues retaining the tumour to the deeper parts should be gently detached with a flat blunt instrument.

The hæmorrhage is usually unimportant unless a vein be torn in separating the deeper parts. In that case an attempt should be made to seize and tie the bleeding point; if it be venous or if the attempt to seize it fail, the wound can be stuffed with gauze for 24 hours, stitches being put through the skin edges and tightened after the gauze is removed.

**Malignant disease.**—Malignant disease of the parotid gland may arise primarily either somewhat diffusely in the gland or from the presence of sarcomatous elements in the “parotid tumour” ultimately involving the gland, or secondarily from the development of cancerous glands in the substance of the parotid, or by the spread of malignant disease by direct continuity from carcinoma of the ear.

**Treatment.**—If anything is to be done at all, it must be complete removal of the parotid gland, and, although in the majority of cases this will not seem worth while, still when the disease is fairly limited and any primary deposit has been completely eradicated, it may be done. The operation must of course involve facial paralysis; indeed, any attempt

to preserve the nerve will almost certainly end in recurrence of the growth.

*Excision of the parotid gland.*—As a preliminary step, a temporary ligature should be passed around the common carotid artery, which may be tightened during the operation if necessary. Pulling on this ligature will control the bleeding temporarily, and the thread can be removed at the end of the operation. The shoulders should be raised and the head turned to the opposite side and allowed to fall back. A curved incision is then made from a point midway between the mastoid process and the condyle of the jaw, extending downwards parallel to the ramus of the jaw around the angle and forwards nearly to the anterior border of the masseter. The incision is continued upwards just in front of the ear to the junction of the zygoma with the malar bone, and then curved forwards along the latter. This flap of skin and fat must be turned forwards over the face. If the gland extends downwards into the neck to any extent, it is well to add an incision along the anterior border of the sterno-mastoid from the upper vertical part of the incision. The lower and posterior part of the gland should then be first gradually lifted from its bed. This can usually be done by dividing the deep fascia at the anterior border of the sterno-mastoid muscle, gradually separating the tissues with the handle of the knife and pulling the gland forwards. After a time the external carotid artery is exposed as it passes through the gland, and this vessel should be clamped and divided. The facial nerve enters at the posterior margin and divides into two main branches, the temporo-facial and the cervico-facial, and should be saved as long as possible, but it is usually out of the question to retain any part ultimately. The deeper lobules which pass between the mastoid process and the ramus of the jaw and between the internal and external pterygoid muscles are best enucleated with a dissector, great care being taken to avoid injury to veins which might be a source of very considerable difficulty and even danger. The shelling-out of the deeper part of the gland is helped by pulling the jaw as far forwards as possible. The final removal of the gland is quite easy, as the anterior part is superficial. The divided end of Stenson's duct should be ligatured with catgut, the bleeding points secured, and then the wound stitched up. As a cavity is very likely to be left, it is well to put in a drainage tube.

### SECTION III.—AFFECTIONS OF THE JAWS.

## CHAPTER XV

### FRACTURES OF THE JAWS.

#### FRACTURE OF THE UPPER JAW.

FRACTURES of the superior maxilla are nearly always due to severe direct violence, although in some cases the fracture may extend into the bone from the skull.

**Varieties.**—A not uncommon form is fracture of the alveolar margin, which may be produced by severe blows, such as a kick from a horse, and may involve detachment of the whole of the lower part of the upper jaw—that is to say, the alveolus with the hard palate. In other cases the fracture is limited to a small portion of the alveolar border, as after the extraction of teeth. The nasal process of the superior maxilla may also be fractured in severe injuries to the nose from direct violence. When the nasal process is fractured, there is often injury to the lachrymal sac or nasal duct, and emphysema is not uncommon. Fracture of the anterior wall of the antrum may be due to blows, or, when compound, to stabs or bullet wounds. Fractures of the palate process alone are very rare, and are generally the result of gun-shot wounds or direct thrusts, such as bayonet wounds. Extensive fracture of the whole bone or of both bones together is usually only a part of some very serious injury, being most often associated with fracture of the base of the skull.

When the fracture is compound and opens either into the mouth or upon the cheek, there may be very considerable hæmorrhage from rupture of the infra-orbital artery, and with this there is often anæsthesia of the lip and the adjacent side of the nose from damage to the infra-orbital nerve.

**Complications.**—The complications of this fracture are (1) epiphora and emphysema from damage to the lachrymal sac and nasal duct; (2) anæsthesia of the soft parts from injury to the infra-orbital nerve; (3)

hæmorrhage from wound of the infra-orbital or other artery. The case may also be complicated with fracture of the base of the skull and injury to the brain, and in gun-shot wounds there may be a foreign body lodged in the bone or lying loose in the antrum, which will require removal. At a later stage, if the deformity has not been properly reduced and treated, there may be considerable interference with mastication either from irregularity of the line of the teeth or from the presence of pointed fragments of bone which interfere with the proper movements of the jaws.

**Treatment.**—The most important point is to reduce any deformity present. This is necessary from the point of view of the patient's appearance and more especially from the fact that unless it be done, mastication may be seriously interfered with. Reduction of the deformity may generally be fairly easily effected by manipulation under an anæsthetic.

The most important deformity requiring remedy is *displacement of the alveolar border*, more especially when the whole of the latter is detached and its position relative to the teeth in the lower jaw is altered. The alveolar border must be restored to position and fixed either by binding the two jaws together, which in some cases is sufficient, or by introducing a properly moulded prop between the teeth of the upper and lower jaws on both sides.

*When there is only a partial fracture of the alveolus*, the replaced portion of bone should be fixed in position by securing the teeth in the fractured portion to the adjacent sound ones by means of a suitable wire splint, such as Hammond's splint, which is fully described for fracture of the lower jaw (see p. 196). Union takes place rapidly in all cases of fracture of the upper jaw and in about three weeks the splint may be left off. Where the fracture traverses other portions of the bone it is unnecessary to apply any splint after reduction. *When the nasal process has been fractured* reduction must be effected by instruments introduced into the nose, and as this fracture is usually complicated with fracture of the nasal bones a similar after-treatment must be carried out to that already described (see p. 110).

*When the anterior surface of the bone has been crushed* or the orbital margin has been displaced, it may be necessary to make an incision, introduce a raspatory beneath the fragments and lever them into position. When this is done, the bones will as a rule retain their place; if not, they must be fixed by one of the methods of fixation suitable for fractures. (see Part III., p. 26). With regard to the anterior surface of the bone, it must be remembered that the fragments are usually so extensively comminuted that the chances of restoring them to position are comparatively slight, and that, owing to their comminution, necrosis of portions is very apt to occur. Hence any operation undertaken with the view of restoring them to position must be done through the cheek, and it will become a question whether the deformity caused by the scar will be less than that due to the displacement.

The *prognosis* is very satisfactory when the fracture is simple; when however it is compound, suppuration occasionally occurs at the point of communication with the mouth and actual necrosis may take place, although that is comparatively rare. Should suppuration occur, the region from which the pus is coming should be thoroughly drained, usually by a drainage tube introduced from the mouth, and if the antrum be opened, it should be frequently syringed out with antiseptic solutions, such as sanitas, Condy's fluid or boracic lotion. Any necrosed portions of bone must be removed as soon as they are loose.

*Hæmorrhage from the infra-orbital artery* sometimes gives rise to considerable trouble. If the skin be unbroken, the application of an ice-bag to the cheek will generally control it. If there be a wound connected with the fracture, the bleeding point should be sought for and if possible secured. If this be impossible, the wound should be firmly plugged with strips of cyanide gauze. Sometimes however the vessel retracts within the bony canal, and the canal must either be opened up or the orifice plugged with Horsley's wax (see p. 47). The objection to the latter procedure is the pressure which the wax must also exert on the infra-orbital nerve. Ligature of the external carotid artery has been employed to check the hæmorrhage, but that is hardly likely to be necessary; it would be much better to open up the infra-orbital canal sufficiently to secure the vessel.

**FRACTURE OF THE MALAR BONE.**—This fracture is extremely rare and is practically always associated with fracture of other bones of the face, especially of the adjacent portions of the superior maxilla. It usually results from severe direct injury which drives the bone downwards and backwards and forces in the anterior wall of the antrum. Fracture of the orbital plate of the superior maxilla may also be produced when the blow is applied more horizontally.

**Treatment.**—This must be directed towards remedying the displacement. In some cases by introducing the finger into the mouth and passing it up between the cheek and the upper jaw, the bone may be pressed outwards; if this fails, a small incision may be made anterior to the masseter muscle and a raspatory introduced beneath the bone so as to lever it up into position.

**FRACTURE OF THE ZYGOMATIC ARCH.**—This is a rare injury usually the result of direct violence, and associated with fracture of the malar bone. When the fracture is due to direct violence, the fragments are generally depressed, whilst, when it results from fracture of the malar bone, the fractured ends are protruded somewhat outwards.

**Treatment.**—The fragments must be brought into good position, otherwise the movements of the lower jaw are apt to be considerably interfered with. This may be attempted first by manipulation from the outside or with the finger in the mouth, but, if it cannot be effected satisfactorily, an almost horizontal incision should be made over the arch, the fracture exposed, and the bones drilled and secured by silver wire.

## FRACTURE OF THE LOWER JAW.

**CAUSES.**—Fracture of the lower jaw generally results from direct violence, the bone being fractured opposite the point struck, but it is not uncommon also to have fractures from indirect violence, the bone being struck at one point and fracture occurring on the opposite side of the mandible. For example, where the angles of the jaw are pressed forcibly together, the fracture occurs in the vicinity of the symphysis. This form of fracture is almost entirely confined to adult life.

**VARIETIES.**—The most common seat of *fracture of the ramus* is in the neighbourhood of the canine teeth, and the fracture may be unilateral or bilateral; when bilateral, it is most common to find the fracture on the one side opposite the canine tooth and on the other just in front of the masseter; in some cases the fracture occurs opposite the canine tooth on both sides so that the central portion of the jaw is separated. *Fracture through the symphysis* itself is of great rarity. *Fracture about the angle* of the jaw is fairly common and is generally due to indirect violence; here the fracture is generally behind the last molar tooth. *Fracture of the condyle* is very rare and is only produced either by direct violence, such as gun-shot wounds, etc., or by severe blows upon the chin driving it upwards and backwards so that the condyle is driven against the base of the skull and fracture occurs through its neck; the condyle may even be driven through the base of the skull and fractured. *Fracture of the coronoid process* is still more rare owing to its protected position; it usually only occurs in military surgery.

Fractures of the lower jaw as a rule are compound, as there is practically always laceration of the mucous membrane over the bones; this is practically invariably the case when the bone is broken in its anterior half. Where fracture occurs behind the last molar tooth however it is not necessarily compound.

**DISPLACEMENT.**—The displacement of the fragments varies according to the situation of the fracture. *When the fracture is through the body of the bone on one side only* there is very slight displacement of the larger fragment, but it may be drawn somewhat inwards; the posterior fragment is drawn a little inwards towards the middle line, and may also be tilted upwards in front. *When the fracture is bilateral* in the usual situation, the middle fragment is pulled downwards and backwards by the muscles passing from the lower jaw to the hyoid bone, while the posterior fragments on the two sides are displaced inwards and tilted upwards. *When the fracture occurs through the angle of the jaw* there is generally only slight displacement, the posterior fragment being usually drawn somewhat inwards by the action of the pterygoid muscles.

**COMPLICATIONS.**—The chief complications of fracture of the lower jaw are 1. *Abscess*, which is perhaps the commonest complication met with in these fractures. A very large number of cases are complicated with

suppuration at some period of their progress and in some there may be the formation of a large abscess and more or less extensive necrosis. Sometimes, but very rarely, septicæmia may follow.

2. *Dental neuralgia and loosening of the teeth.*—In nearly all fractures of the jaw where the fracture is situated behind the mental foramen, severe toothache is at first complained of. Sometimes this may be due to partial tearing of the inferior dental nerve as it lies in its canal in the lower jaw; more commonly however it is due to stretching of the nerve by the separation of the fragments; when the fracture is reduced and the tension removed the neuralgia disappears. The teeth adjacent to the fracture are very commonly extremely loose, so that they could be easily removed with the fingers, but it is well to remember that this should on no account be done as the teeth will probably become firmly fixed in their sockets in the course of a few days; if partially displaced, they should be carefully put into position and if necessary secured to the sound teeth by silver wire.

3. *Cerebral injury.*—This complication is rare and generally results from the severe jarring transmitted through the condyles to the base of the brain as the result of the upward blow causing fracture of the jaw. There may be aural hæmorrhage when the condyle is driven back against the external auditory canal. An excessively rare complication is that of salivary fistula where the submaxillary or sublingual ducts are torn across.

4. *Ununited fracture.*—This is also very uncommon and generally only occurs after necrosis about the seat of fracture.

**TREATMENT.**—(a) **Of the fracture.**—The treatment of fracture of the lower jaw varies according as the seat of fracture is anterior to the last molar tooth or behind it.

(1) **When the fracture is anterior to the last molar tooth.**—In all these cases, the best treatment, whenever it is possible to use it, is *Hammond's wire splint* (see Fig 74). It is easy of application, comfortable to the patient, secures perfect apposition of the fragments and perfect immobility during the consolidation of the fracture, and it enables the jaw to be used almost from the first. The following is the method of application.

If the fracture be situated at all far back, it is necessary in the first place to take a mould<sup>1</sup> of the teeth in the lower jaw after the fracture has been temporarily replaced in position: this is done to allow the splint to be properly fashioned before adjusting it. If however the fracture be near the canine tooth, there will be plenty of room for the necessary manipulations and a mould need not be taken. The splint consists essentially of a frame of fairly stout iron wire plated or nickelled, which is applied around the necks of two or more sound teeth on both sides of the

<sup>1</sup>If it be necessary to take a mould, this is best done under an anæsthetic; the mould is taken in the manner usually adopted by dentists, while the fragments are held firmly in position by the surgeon. From the mould a cast is taken in plaster of Paris and upon this cast the wire frame is modelled.



fracture immediately above the mucous membrane of the gum. The furthest teeth should be as far away from the fracture as possible. It is usual to select the third tooth from the fracture on each side. The end of the wire frame is passed between the teeth farthest away from the fracture on each side and the wire is then moulded so as to fit accurately against each tooth; the ends are brought together, twisted, cut short and bent up out of the way so as not to irritate the mucous membrane of the lip.

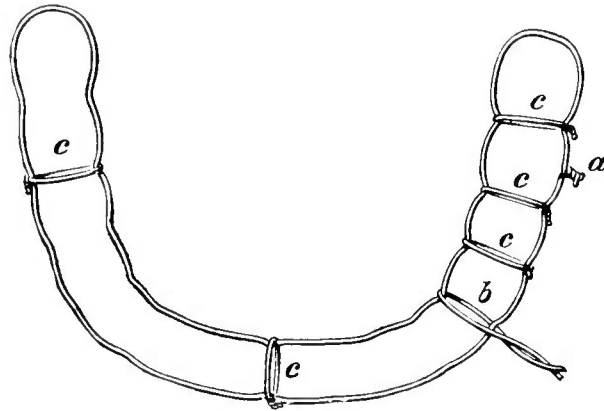


FIG. 74.—HAMMOND'S WIRE SPLINT FOR FRACTURES OF THE JAW.—The stout wire frame is twisted at *a* and the ends cut short and turned down out of the way. Fine binding wires, *b* and *c*, are used to secure the two sides of the frame between each tooth, so that the frame forms a series of compartments, each containing a tooth.

The stout wire framework thus moulded round the necks of the teeth is further secured by binding the two sides of the splint firmly together with silver wire introduced between each tooth. The splint is thus divided into a series of compartments each of which is occupied by a tooth. While the splint is being applied, the jaw is held firmly with the fractured ends accurately in apposition; when the binding wires have been applied, the splint keeps the fracture in position. It is wise in cases where there are only a few sound teeth on either side of the fracture to apply a jaw bandage for the first four or five days; it may be then discontinued and the consolidation of the fracture will proceed satisfactorily.

It is obvious that this splint cannot be used when the jaw is edentulous or when the teeth on one side of the fracture are too few or so loose that its application would pull them out of their sockets. For these cases the splint usually known as Gunning's is one of the best. This consists of two troughs of gutta-percha or some suitable composition moulded on a cast of all the teeth in both jaws; the upper half receives the teeth of the upper jaw, the lower half those of the lower jaw. Between the upper and lower halves of the splint there are props separating the two portions so as to leave an interval through which the tube of a feeder can be introduced. The fracture is reduced, the splint is fitted over the alveolar margins of the upper and lower jaws and the latter is kept in position by a firmly applied jaw bandage (*vide infra*).

Semi-solid food, such as bread and milk, custards, rice pudding, etc., may be administered after the first week, when a Hammond's splint is

employed: when a Gunning's splint is used, liquid food must be maintained until the splint is removed, which will be at the end of about three weeks. In neither case should solid food be allowed until four or five weeks have elapsed from the time of the accident. Hammond's splint need not be removed until about the sixth or seventh week, as it lies comfortably around the necks of the teeth and causes no inconvenience. It is easily removed by cutting the main wire in several places with pliers. In both cases a mouth-wash of sanitas and boracic lotion should be used.

(2) **Fractures situated behind the last molar.**—Here the only thing that can be done is to keep the jaw closed and in proper position while the fracture consolidates. This is usually effected by an ordinary jaw bandage which is made as follows. A piece of fairly stout calico bandage, about three feet long, is taken, and in the centre of it a small oval aperture is cut suitable for the reception of the chin. The strip is converted into a four-tailed bandage by splitting up each end to within a couple of inches of the central aperture. The bandage is then applied so that the point of the chin lies in the central orifice. The upper limb of the bandage is carried horizontally backwards and the ends are knotted together beneath the external occipital protuberance. The lower limbs of the bandage are carried vertically upwards and knotted over the vertex in front of the bregma. The ends of the vertical and horizontal limbs of the bandage are then tied together so as to prevent the anterior strips from slipping forward. In some cases a moulded gutta-percha splint is applied to the chin inside the bandage, but as a rule this is a source of annoyance and is of very little advantage. The saliva often dribbles away in these cases and soils the bandage rapidly, so that it requires frequent changing. Before applying the bandage, attempts should be made by manipulation to entangle the broken surfaces so that the bandage simply keeps the parts at rest after they are put into position. In cases where there are no teeth in the posterior part of the jaw a suitable modification of Gunning's splint may sometimes be modelled upon the alveolar margins so as to keep the jaws in position when fixed by the bandage.

At the end of three weeks the patient may discontinue the use of the bandage and take soft food. As long as the bandage is being worn, it is important that it should not be taken off for the purpose of feeding. The patient should be kept on a liquid diet, strong beef-tea, soups, milk, etc., administered by means of a feeder to which an indiarubber tube is attached. This can be passed through the space which always exists behind the last molar tooth on the sound side and the patient can thus be fed easily without disturbing the bandage. All solid food requiring mastication should be interdicted until the end of the fifth week when the union is fairly firm. The patient need not be confined to bed. If there be a sufficient interval between the teeth or if a tooth be wanting, a mouth-wash of sanitas or chlorate of potash should be used and it is often very comforting.

There are numerous other methods of treating fractures of the lower jaw, but those above described are the ones most universally applicable. We will only refer to two other methods, namely the use of an inter-dental splint with a chin-plate and the wiring of the fragments together. The former are often very complicated and generally consist of a splint embracing the teeth of the lower jaw above and a chin-plate beneath so designed as to press the fragments up into position. These splints are however radically bad, as it is a cardinal point in their use that the chin-plate must press upon the seat of the fracture and this is apt to cause great irritation and even to lead to pressure sores. *Wiring of the fragments* is but rarely called for. It may however sometimes be necessary where it is impossible by other means to secure proper coaptation. This is most likely to be the case when there is a double fracture of the jaw either on one side or bilaterally. The great drawback to wiring is that the fracture is almost always compound and septic, and, if the fragments be wired, suppuration may occur about the fracture followed by necrosis and possibly want of union. The method should therefore not be employed unless it is absolutely called for by the failure of other apparatus. But if the proper alignment of the teeth cannot be maintained by any other means then it is quite necessary to wire the fragments, because, if there be any marked defect in this respect, proper mastication is of course permanently interfered with. Wiring may also be very useful in cases of fracture at the angle where there is marked displacement of the posterior fragment, and where the operation can be carried out without opening into the mouth.

(3) **Fracture of the condyle.**—Fracture of the condyle of the jaw often leads to very unsatisfactory results, stiffness of the jaw or pain on mastication being very common sequelæ. It seems almost hopeless to expect from any mechanical appliance good union and at the same time good movement of the joint, which almost invariably becomes stiff from the adhesions following the fracture. The methods of treatment which suggest themselves are to cut down and wire the fragments, to commence movement at once with the view of obtaining a false joint, or to excise the condyle in the manner to be presently described in speaking of ankylosis of the jaw (see p. 205).

(4) **Fracture of the coronoid process.**—This is a rare injury which is practically always compound, as for example, after gunshot wounds. The fracture may be simple or comminuted, and the fragment to which the temporal muscle is attached is drawn upwards and does not unite with the jaw; hence, the movements of the latter may be seriously interfered with, both from the want of connection between the temporal muscle and the jaw and from the actual destruction of the fragment.

The wound must be thoroughly purified and then enlarged if necessary to expose the fractured region. If the coronoid process be comminuted or if the detached portion be quite small and parts of the temporal muscle still remain attached to the jaw, the simplest plan is to remove the fragment. On the other hand, if it be a single large fragment and the wound be clean, it will be best to wire the fragment to the base of the coronoid process. In

enlarging the wound, the direction of the branches of the facial nerve should be borne in mind and also the position of Stenson's duct.<sup>1</sup> The incision must therefore be transverse or with a slight obliquity downwards and backwards. After the operation, a jaw bandage should be applied and, if stout silver wire has been used, the patient may begin to move his jaw in the course of three or four days. When the fragment has been removed altogether, active and passive motion may be begun at once. The early movement of the jaw is of great importance because the adhesions which would otherwise form are very difficult to overcome subsequently and might lead to a certain amount of closure of the jaws.

**(b) Of complications.**—*The treatment of abscess in connection with the fracture* presents nothing special. The abscess should be opened freely and early and properly drained; it is practically always essential to open the abscess from the outside, as otherwise pus is apt to collect at the most dependent part of the cavity and keep up the inflammation, and possibly lead to necrosis.

*Septicæmia* is sometimes met with, but it is happily very rare. Its treatment has already been mentioned (see Part I., p. 210).

*Persistent dental neuralgia* is of rare occurrence. It usually subsides immediately the fracture is properly reduced, but it may persist and be very severe as the result of pressure upon the nerve by the callus thrown out as the fracture consolidates. Under such circumstances the nerve must either be divided at the dental foramen or an operation for the removal of callus must be undertaken. In the latter case it is by no means easy to find the nerve and divide or free it, whereas at an early period of dental neuralgia the division of the inferior dental nerve (see p. 128) will stop the trouble.

*Non-union* is fortunately extremely rare; if it occurs, the ordinary treatment of ununited fracture must be employed, the edges being refreshed and the bones wired together (see Part III., p. 52). The incision should be made over the lower border of the jaw and the soft parts pulled carefully upwards, taking great care to avoid going through the mucous membrane of the gum in front or above. The fractured surfaces may then be refreshed by a chisel, the lower margin of the bone drilled and a wire passed through it. In doing this the greatest care must be taken to see that the drill-holes on the opposite sides of the fracture correspond, and it is well to be provided with a grooved drill, which may help the passage of the wire. The upper part of the bone may be steadied by a Hammond's splint (see p. 196).

<sup>1</sup>Stenson's duct crosses the masseter parallel to and about a finger's breadth below the zygoma. The infra-orbital branch of the facial nerve lies just above and almost parallel to the duct, the temporal branch runs up almost vertically in front of the ear, while the malar branch occupies a position intermediate between the two.

## CHAPTER XVI.

### AFFECTIONS OF THE TEMPORO-MAXILLARY ARTICULATION.

#### DISLOCATION OF THE LOWER JAW.

**Causes.**—Dislocation of the lower jaw may be either unilateral or bilateral, the latter being much more frequent. It is more common in women than in men, and it usually results from yawning, laughing, and other actions in which the mouth is widely opened. It may also occur from indirect violence, such as a blow on the chin, especially if applied in the downward direction so as to force the mouth open. In the normal movement of opening the mouth the condyles of the lower jaw, accompanied by their inter-articular fibro-cartilages, glide forwards over the eminentia articularis, on the summit of which the condyles lie when the jaw is fully open. If the depression of the lower jaw be carried beyond this point, the inter-articular fibro-cartilage remains stationary owing to its connection with the bone, while the condyle slips forward in front of the eminentia articularis, and becomes fixed there by the contraction of the temporal and masseter muscles. The result is that the mouth cannot be closed, any attempt to shut it being met by contraction of these muscles; the saliva dribbles away and there is severe pain. Mastication is of course absolutely prevented, and speech is almost unintelligible.

**Treatment.**—In order to reduce a *bilateral dislocation*, traction is applied to the vertical ramus of the jaw so as to pull the condyle downwards from the temporal fossa until it reaches the level of the eminentia articularis; it is then pushed back into position. The reduction is usually quite readily effected without an anæsthetic. The patient sits upright in a chair, with the head supported by an assistant or against a wall. The surgeon stands in front, and, having wrapped a thick piece of lint round each thumb, places one along the upper border of the lower jaw as far back as the last molar tooth on each side; the palm of each hand is beneath the symphysis. Steady pressure is then made by the thumbs almost vertically downwards, while the palms beneath the chin press the

latter upwards and still further depress the condyles. As the jaw is felt to yield, the chin is forcibly tilted upwards and the bone pushed bodily backwards. As a rule, directly the condyle reaches the eminentia articularis it slips backwards and the mouth closes with a snap; if the surgeon is not careful his thumbs may be bitten. Hence, the moment it is felt that the condyle is beginning to move back, the thumbs should be slipped off the molar teeth into the recess between the cheek and the jaw.

After the dislocation has been reduced, it is very apt to recur if the patient laughs or opens his mouth too wide, and therefore for the first four or five days a jaw bandage should be applied (see p. 198), in order to support the chin; it is best to use an elastic bandage so that the patient can open his mouth to some extent and can feed himself. The bandage may be left off during the day after about five days, but it should be worn at night for at least another week. There is usually no risk of stiffness because the patient voluntarily uses his jaw and no special massage or passive motion is necessary.

If this procedure fails, the patient should be placed under an anæsthetic and, employing the same procedure, the dislocation can generally be reduced without any difficulty. The pressure may be made downwards and backwards against the anterior border of the coronoid process rather than against the last molar tooth. Should this plan fail, it has been suggested that a piece of wood bound round with lint should be introduced between the last molar tooth on each side and that the chin should then be forcibly elevated with the view of thus levering down the condyles from the temporal fossa; when the teeth almost meet the jaw should be pushed forcibly backwards. One of these methods will succeed in reducing all cases of recent dislocation. The after-treatment is the same in all.

The treatment of *unilateral dislocation* is practically the same as that of the bilateral form. It is well to depress both angles of the jaw, but mostly the one on the dislocated side; the backward pressure should be made on the side on which the dislocation is.

**UNREDUCED DISLOCATION.**—If a dislocation of the jaw remains unreduced, the condition of the patient is very deplorable, although after a time a certain amount of power of approximating the lips is regained and the dribbling of saliva which occurs at first may disappear. Further, a certain amount of lateral mobility may occur, enabling the patient to masticate his food. As a rule however his condition is so bad that an attempt must be made to improve it.

**Treatment.**—Unreduced dislocations of the lower jaw have been successfully reduced as long as four months after the occurrence of the injury and certainly in all cases where no more than six or eight weeks have elapsed an attempt should be made under an anæsthetic by the manipulations above described. Before commencing these manipulations however, it is well to elevate and depress the jaw a number of times with increasing vigour so as to break down adhesions about the condyles.

If the surgeon fails to reduce the dislocation by manipulation, the best procedure is removal of the condyle of the jaw—in other words *excision of the temporo-maxillary joint*. This operation gives better results than the excision of a wedge-shaped portion of the neck of the condyle with the formation of an artificial joint which is sometimes practised. In the latter case, the condyle being out of position, the teeth do not approximate properly, even though movement be restored, and the antero-posterior motion is not regained, whereas after removal of the condyle the ramus of the jaw can be pushed back into proper position and, by carefully keeping up movement, a very satisfactory result is obtained, especially if the dislocation has been bilateral and both condyles have been taken away. The operation is performed as follows:

After disinfecting the parts, a curved incision is made over the articulation with its convexity backwards and upwards, the ends of the incision curving forwards so that the base thus marked out is about opposite the position of the condyle. This incision should divide the skin and fascia and should be deepened first posteriorly. The flap is then raised towards the front, care being taken to avoid division of the upper branches of the facial nerve; if the flap be raised in the manner described these can be pushed forward along with the fascia and there is no great risk of dividing them. The temporal artery will probably be divided but it can be readily tied. The cutaneous nerves may be pulled backwards or divided if necessary; in this way the zygomatic process and the upper part of the masseter muscle are exposed. The latter should then be detached from the zygoma from behind forwards sufficiently to expose the displaced condyle; as a rule, it is only necessary to detach a small portion of the posterior part of the muscle. When the condyle is brought into view, the jaw is depressed by an assistant so as to bring it down beneath the zygoma; this can generally be done fairly easily if ankylosis has not taken place. The neck of the condyle is then snipped across with a pair of cutting pliers and the loose condyle pulled forcibly downwards and dissected out. Care must be taken in removing the condyle not to damage the internal maxillary artery, but the chances of damage to this structure are not so great as when the operation is performed for ankylosis of the joint, because the condyle is carried forwards more or less out of the way of the vessel. After having removed both condyles, the jaw is forcibly depressed and pushed backwards into its proper position; before closing the wound, the surgeon must make sure that the remains of the condyle can go back readily into place. The jaw should be forcibly moved backwards and forwards and up and down so as to tear through any adhesions, and the glenoid cavity should be cleared of any soft material in it. The wound is closed with a continuous suture and a drainage tube is not as a rule required. The jaw should be fixed with an ordinary jaw bandage, and it is well to begin passive motion within two or three days after the operation; in some cases an

anæsthetic may be necessary at first. The passive motions should consist of opening and shutting the mouth, lateral and antero-posterior movements, and should be carried out at first daily and subsequently twice a day for a very considerable time. The chin bandage may be of elastic material and after a few days it need only be worn at night. It should be so arranged that the chin is kept pulled backwards as well as upwards. The result is very satisfactory, especially when both condyles have been excised. In the unilateral condition, the jaw is shorter on one side than on the other and there may be some inequality in the movement of the two sides.

#### INFLAMMATORY AFFECTIONS OF THE TEMPORO-MAXILLARY JOINT.

This articulation may be the seat of various inflammatory conditions which cause considerable trouble from interference with mastication and articulation. Among them may be mentioned acute rheumatism; gonorrhœal rheumatism, which is fairly frequently met with; suppurative arthritis, resulting from a wound of the joint, from some septic focus in the immediate neighbourhood or as a part of a general pyæmic condition; osteo-arthritis, and sometimes, though very rarely, tuberculous disease.

**Treatment.**—The treatment of these conditions differs in no essential respect from the treatment of the affections in other joints, but the important fact must be borne in mind that the stiffness which is prone to result from any inflammatory affection of the articulation may cause very considerable trouble to the patient subsequently from ankylosis of the jaw and consequent inability to separate the teeth. This is especially apt to occur after an arthritis of rheumatic or gonorrhœal origin. In treating these cases, therefore, this point should never be lost sight of, and, as soon as the disease has passed off, movements of the jaw should be begun, and if necessary adhesions should be broken down under an anæsthetic, the administration of which, however, in cases of closed jaw requires the very greatest care. When there is a great tendency to further contraction or much spasm, the best plan is to employ some form of gag to keep the teeth apart. This may be either a conical boxwood gag or some flat gag provided with a screw arrangement so as to gradually increase the separation between the teeth (see Fig. 75).

#### ANCHYLOSIS OF THE JAW.

The conditions just mentioned may give rise to ankylosis of the jaw. After any inflammatory affection of the temporo-maxillary joint adhesions are very prone to form, more especially in connection with the fibro-cartilage, and as a result it becomes impossible to depress the lower jaw. The affection may be unilateral, but is most commonly bilateral. Closure of the jaws may also result from cicatricial contraction of the soft parts in



the neighbourhood of the angles, as has been already mentioned (see Plastic Surgery of the Face). A third condition leading to somewhat similar results is a spasmodic contraction of the elevator muscles of the jaw in connection with some inflammatory condition in the neighbourhood, such as an impacted wisdom tooth, and in these cases, after the spasm has lasted for some time, the muscles are apt to undergo shortening and permanent contraction is produced.

**Treatment.**—The treatment of closure of the jaw therefore depends on the condition present. *In the purely spasmodic cases* the removal of the exciting cause will, if carried out early, generally lead to arrest of the condition within a short time. This will be greatly aided by the application of massage over the masseter muscle, the employment of frequent passive movements of the jaw, the use of a gag which is gradually dilated, and the application of a weak galvanic current to the temporal and masseter regions. The trouble in overcoming the contraction is directly proportional to the length of time that the affection has lasted.

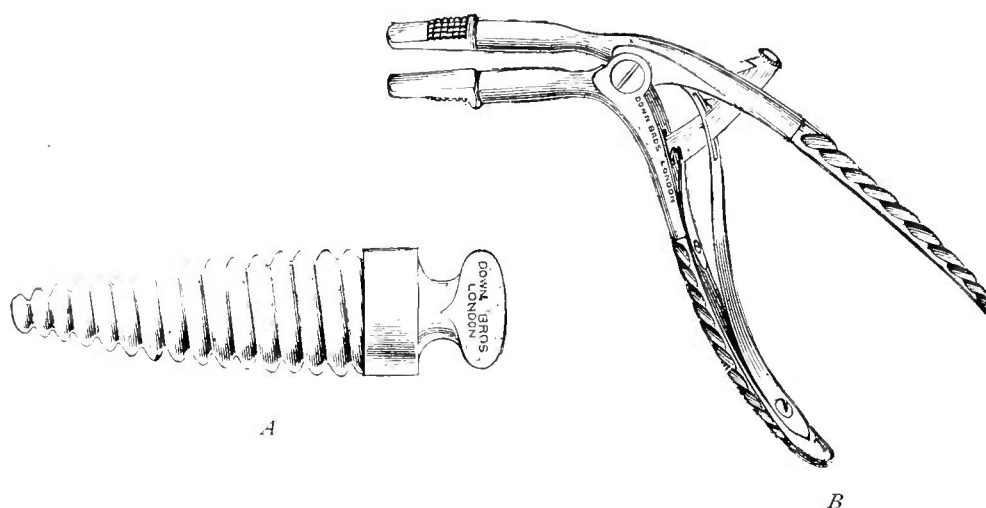


FIG. 75.—GAGS FOR ANCHYLOSIS OF THE JAWS. *B* is a very powerful gag and can be used to lever the jaws open, while the boxwood screw-gag *A* is introduced and left in position.

When the affection is due to ankylosis of the temporo-maxillary joint attempts may first be made to remedy the condition by forcible movements under an anæsthetic, followed by passive movements and the use of a gag worn continuously. If, however, the adhesions have become firm, very little is to be hoped for from this method, and under such circumstances the force employed to rupture the adhesions may very likely fracture the neck of the condyle; moreover, the adhesions if torn are very apt to re-form. Hence, if the adhesions be so extensive and firm that they cannot be overcome by movement under an anæsthetic and subsequent passive motion, the only alternative is to remove the condyle of the jaw and make a false joint. This operation is done as follows:

An incision through the skin and superficial fascia, an inch and a half in length, is made along the lower border of the zygoma; it should

curve downwards immediately in front of the tragus. The flap is dissected up with care, watch being kept for branches of the facial nerve which if seen are pulled out of the way. The posterior portion of the masseter muscle is detached from the zygoma and the capsule of the joint is exposed and opened by a vertical incision; the condyle is sufficiently cleared to enable it to be divided either by cutting pliers or a fine chisel. The separated condyle is then seized with a pair of forceps and twisted out, any firm fibrous connections being divided with the point of the knife. It is most important to keep the point of the knife closely in apposition with the bone so as to avoid injury to the internal maxillary artery. The fibro-cartilage is left behind and the wound sewn up without a drainage tube. Enough bone must be removed to leave a good gap between the neck of the condyle and the eminentia articularis. It is very common to find slight facial paralysis after the operation, but this is usually due to stretching of the nerve and is quite transient. Passive movements should be commenced immediately after the operation, at first under an anæsthetic, such as gas and oxygen: after the lapse of a few days however the movements will be less painful and the use of a gag which is opened by a screw should be commenced. When the gag is not being used, the mouth should be propped open with an ordinary dental prop.

The results are best when the affection is one-sided. Even in bilateral cases however, if the treatment be persevered with for a considerable time, satisfactory results may be obtained; but it is important to caution the patient that the treatment must be perseveringly carried out for a very long period, for several months at any rate, and it must be especially vigorously resorted to if any tendency to re-contraction should be noticed.

## CHAPTER XVII.

### INFLAMMATORY AFFECTIONS OF THE JAWS.

INFLAMMATION of the gums and jaws is most commonly associated with caries of the teeth. It may also occur from the accumulation of tartar around the neck of the teeth, from the action of drugs, such as mercury or phosphorus, from septic infections, aphthous condition of the mouth, etc., or in connection with specific infective diseases, such as syphilis, tubercle or actinomycosis; it may also be associated with digestive troubles. The inflammation may be limited to the alveolar process or may affect the body of the jaw; it may commence in the periosteum and lead to thickening of it or it may begin in the substance of the bone and lead to alveolar abscess, or to necrosis.

#### GINGIVITIS.

In inflammation of the gums from excessive administration of mercury, the treatment is to stop the administration of the drug at once, to employ anti-septic mouth-washes, and to administer chlorate of potash (ten-grain doses three or four times a day). Chlorate of potash (grs. x. ad  $\bar{z}$ i) also forms a very excellent mouth-wash; if some of it be swallowed it will be all the better for the patient.

An aphthous condition of the mouth is also not uncommonly accompanied by a similar affection of the gums and the treatment is very simple; it consists in free purgation, and the employment of antiseptics, such as boro-glyceride, etc.

In secondary syphilis there is also ulceration of the gums following the formation of mucous patches upon them. The treatment is simply the treatment of secondary syphilis (see Part I., p. 231).

#### PYORRHŒA ALVEOLARIS.

The most interesting of these inflammations of the gums is that known as pyorrhœa alveolaris; it often escapes recognition or is mistaken for ulcerated

gums in connection with the administration of drugs or some dyspeptic condition. The ulceration however is, in the first instance, limited to the gum in immediate contact with the teeth; on pressure on the gum, pus may be pressed up from between it and a tooth. It is usually due to an accumulation of tartar and a certain amount of septic infection between the gums and the teeth.

**Treatment.**--This is best carried out by a dentist; it consists in the thorough removal of all tartar, in carefully cleaning out the pus from between the gum and the teeth, and the introduction of tannin and eucalyptus oil once or twice a day.

#### OSTEITIS AND PERIOSTITIS.

The inflammatory affections of the jaws may take the form of limited periostitis, suppurative osteitis, or a more diffuse form leading to necrosis.

**PERIOSTITIS.**--The limited thickenings of the jaw not due to specific infections, such as syphilis or actinomycosis, generally arise in connection with the teeth and are sometimes somewhat difficult to diagnose from tumours. There is usually a little suppuration of the base of the tooth but that is not absolutely essential. In any case the thickening rapidly disappears on removal of the carious tooth.

**ALVEOLAR ABSCESS.**--The most common inflammatory affection of the jaws is limited suppurative osteitis, which goes by the name of an alveolar abscess. Alveolar abscess is a suppuration occurring around the fangs of a tooth which is usually carious; the pus so formed may in some rare cases escape between the neck of the tooth and the jaw, but it more often leads to the formation of an abscess cavity in the bone which gradually approaches the surface. In the majority of cases it reaches the surface beneath the gum and leads to what is popularly known as a "gumboil." In other cases, however, where the fang is long and the abscess consequently more deeply seated in the body of the jaw, the pus reaches the surface of the bone lower down and may lead to adhesion of the cheek to the jaw and to the formation of a subcutaneous abscess.

When an abscess of this kind forms in the lower jaw, it frequently occurs quite at the lower margin and is sometimes mistaken for a suppurating gland; when the abscess is opened, however, a probe will be found to pass upwards into a narrow channel in the bone itself from which the pus is escaping. In an alveolar abscess in the upper jaw the pus may make its way into the antrum and cause suppuration there. In the milder forms there is no necrosis, but in some cases the inflammation may be much more severe and is then followed by limited or even extensive necrosis; this is perhaps most often the case when the suppuration occurs in connection with an impacted wisdom tooth.

**Treatment.**--In the treatment of alveolar abscess the removal of the tooth is in almost all cases essential, and not infrequently, if the pus has

not yet reached the surface of the bone, the removal of the tooth suffices to cure the disease, the pus finding its way outwards through the tooth socket and the abscess cavity gradually closing.

When the abscess has made its way externally either in the gum or through the skin, it must of course be opened, but healing will seldom occur until the tooth is removed; unless this be done, a sinus remains for a long time, leading through a small channel in the bone to the root of the tooth. On the other hand, when the tooth is removed the sinus generally closes very quickly. When the pus is making its way towards the skin it is very important to prevent this if possible, and hence, when the cheek is becoming adherent to the jaw, it is well to incise the indurated tissues from within the mouth, when pus will usually be found; the opening is then plugged, the tooth removed, and in most cases the inflammation will subside without extending further into the cheek.

**ACUTE OSTEO-MYELITIS.**—The more extensive and violent inflammations leading to necrosis of portions or even the whole of the jaw may be due to a carious tooth, but they are more commonly the result of a more diffuse infection, such as a typical osteo-myelitis. These cases usually occur further back than the alveolar abscesses, most commonly somewhere about the angle of the lower jaw, and they are more common in the lower jaw than in the upper. Pus readily forms between the periosteum and the bone and the latter is apt to necrose to a considerable extent.

**Treatment.**—The treatment of this affection must be carried out on the lines already indicated for acute osteo-myelitis generally (see Part III., p. 175). The first point is of course to remove any local cause as quickly as possible; any carious teeth or an impacted wisdom tooth should be extracted without delay. In some cases this is not by any means an easy matter as the jaws are generally more or less closed, in the first instance from spasm and subsequently from inflammatory infiltration of the muscles, so that it is extremely difficult or almost impossible to open the jaws sufficiently widely to extract an impacted wisdom tooth. When however the disease has evidently arisen from such a cause, its removal is absolutely essential, and if the mouth cannot be opened sufficiently widely, the mucous membrane over the posterior part of the jaw should be incised and the bone over the wisdom tooth cut through with a chisel and hammer and the tooth removed from its bed.

It is also absolutely essential to obtain free drainage of the pus surrounding the necrosed bone; as long as it does not escape properly the necrosis extends and the patient is liable to general septic infection. When the disease occurs about the angle of the jaw, it is necessary in the great majority of cases to make an external opening at the most dependent part. An opening into the abscess from the mouth is quite inefficient; the escape of pus is defective, saliva flows back into the cavity, decomposition is excessive and the skin is sure to give way over it. It is much better therefore to anticipate these events by making a suitable counter-

opening. The mucous membrane over the abscess should be incised from the mouth, a pair of sinus forceps passed down the outer surface of the bone to the lowest point of the cavity and a suitable incision made through the skin, taking care to avoid injury to branches of the facial nerve; a drainage tube is then pulled by the forceps into the cavity which is washed out frequently with antiseptic solutions.

This treatment must be continued until the necrosed bone is loose, which usually will be in from six weeks to two months, according to the situation and extent of the necrosis. Here, as elsewhere, the sequestrum becomes enclosed in a bony sheath, so that, even when the greater part of the jaw has necrosed the bone may be more or less completely reproduced by the periosteal new growth. So long as the patient keeps well, it is advisable not to be in too great a hurry to remove the necrosed portion, because it preserves the shape of the jaw and so allows proper reproduction of the bone, whereas, if removed before sufficient periosteal new formation has occurred, the new jaw becomes misshapen. In fact, if the necrosed fragment be removed before enough new bone has been formed to leave a firm jaw, it is well to try by introducing stuffing or a piece of boxwood to keep the jaw in its natural form until enough new bone has been produced.

The removal of the necrosed fragment is usually comparatively simple and can generally be carried out from the mouth. By enlarging the opening in the mucous membrane leading down to the sequestrum and, if necessary, dividing any bridge of bone which interferes with its easy exit, the fragment can generally be seized with forceps and extracted. It is only in rare cases that an external opening is required. As in other cases, care must be taken that all the necrosed bone is removed and that no spicules are left behind. No dressing is necessary except possibly a temporary plug of iodoform gauze if there be oozing, but this should not be kept in for more than a few hours as it becomes extremely fœtid. The mouth should be washed out frequently with the ordinary antiseptic mouth-washes and the drainage tube introduced into the cavity from outside should be retained until the sinus closes, which it usually does very rapidly. The patient should in the first instance be kept on liquids or on semi-solid food.

In these cases the tendency to closure of the jaw, associated with necrosis in the neighbourhood of the ascending ramus, must be borne in mind and steps must be taken to counteract it. As soon therefore as the necrosed fragment is removed, the mouth should be forced open by a wedge placed between the teeth on the sound side provided the new bone be sufficiently firm, and active and passive movements should be encouraged repeatedly during the day. The patient should sleep with the wedge in the mouth; it must of course be secured so that it cannot slip out.

## TUBERCULOUS DISEASE OF THE JAWS.

This affection is not common and chiefly occurs in the upper jaw, more especially about the orbital margin and in the neighbourhood of the malar bone; it may also occur in the lower jaw somewhere in the neighbourhood of the angle. The treatment is similar to that of tuberculous disease of bone elsewhere (see Part III., p. 198); when the disease is superficial, the tuberculous focus should be removed at an early date: should the case not come under observation until the disease has considerably advanced, attempts should be made to eradicate it by an operation planned so as to do as little injury to the parts as possible and to avoid secondary scarring of the face as much as one can.

## PHOSPHORUS NECROSIS.

This condition has already been fully described (see Part III., p. 194) and nothing further need be said about it here.

## ACTINOMYCOSIS OF THE JAW.

This affection like the last has already been fully dealt with in connection with diseases of bone (see Part III., p. 219) and needs no further reference here. It is not a common affection of the jaw.

## CHAPTER XVIII.

### TUMOURS OF THE JAWS.

#### DENTAL CYSTS.

It is not very uncommon to find cysts in the jaws which originate in connection with the teeth. These cysts are of three kinds: 1. Dentigerous cysts, 2. Simple cysts, and 3. Multilocular cysts.

**DENTIGEROUS CYSTS.**—These are cysts containing a clear, somewhat mucoid fluid, unilocular but with either a well-developed tooth or the rudiments of a tooth in their interior. The cysts may occur in either the upper or the lower jaw and usually develop in connection with the permanent teeth; in one or two cases, however, dentigerous cysts have been found in connection with the temporary teeth. They therefore usually appear during the age of the second dentition, between 7 and 30 years of age. The cysts increase slowly and gradually expand and thin the bone around, so that in advanced cases there is the sensation known as “egg-shell crackling” on pressure; indeed the bone may be actually destroyed and fluctuation may be obtained. In the upper jaw the cysts extend upwards and bulge into the antrum and they also dilate the bone outwards so as to form a prominence on the cheek.

**SIMPLE CYSTS.**—Simple cysts not containing a tooth also occur in the jaws and probably develop in connection with the root rather than with the crown of the tooth as is the case with the dentigerous cysts. They are said to be more frequent in the upper jaw than in the lower, and in connection with the incisors or canines more often than with the molars. They may occur not only in young adults but also at a later period of life. The progress of the cyst is the same as that of a dentigerous cyst.

**MULTILOCLULAR CYSTS.**—These are most commonly found in the lower jaw. They may invade the greater part of the ramus and lead to the formation of irregular nodular tumours which sometimes fluctuate in parts. On section there are numerous cysts of varying size which communicate with one another and which in all probability are developed



from the remains of the dental organ. These multilocular cystic tumours may occur at any age, but are most frequent in youth. Their growth is very slow, but it may become more rapid from the development of sarcoma or epithelioma in the wall of the cavities; recurrence is then liable to take place after operation.

A considerable number of the so-called multilocular cystic tumours of the lower jaw are in reality cysts developed in tumours, especially myeloid sarcomata.

**Treatment.**—The treatment of *dentigerous and simple cysts* is the same and consists in more or less complete removal of the cyst wall, which in most cases can be carried out from the mouth. The mucous membrane is reflected from the swelling, the outer wall of the cyst cut away either with scissors or with pliers, the lining membrane of the cavity scraped out and any contained tooth removed, or, in the case of simple cysts, the tooth with which the cyst is apparently connected extracted. In addition to scraping the cavity so as to get rid of the lining membrane of the cyst, it is well to thoroughly gouge its surface and afterwards to sponge it with undiluted carbolic acid: it should then be lightly stuffed with strips of cyanide gauze and allowed to granulate. In no case is it necessary to excise a portion of the jaw.

*After-treatment.*—The packing should be renewed twice daily and should be continued until the cavity has become obliterated. An antiseptic mouth-wash (sanitas, boro-glyceride, etc.), should be frequently used, especially when the packing is changed.

The treatment of *multilocular cystic tumours* of the lower jaw is not so easy. There the removal of the mass is the more necessary on account of the tendency to development of malignant disease subsequently, and in a good many cases the thorough removal of the growth can only be carried out by excision of the portion of the jaw involved. The methods for partial excisions of the jaws will be found on p. 220 and p. 226.

#### NEW GROWTHS OF THE JAWS.

Various simple tumours occur in connection with the jaws, of which we may mention exostoses, fibromata, chondromata, myxomata and lipomata. These tumours may occur either on the surface of the bones or may spring from their interior, and are perhaps more frequent on the lower jaw than on the upper. Their treatment presents no feature of special importance.

**EPULIS.**—The term “epulis” is applied to growths of very different histological characters and is merely a generic term applied to growths springing from the margin of the gum. These tumours are in some cases of inflammatory origin, in others they may be new growths, such as fibromata or sarcomata, either myeloid, round or spindle-celled; more rarely still they may be angiomata. The tumours probably arise in connection with the peri-odontal membrane and usually as a result of dental caries. They

spring from the gum at the side of a tooth and grow either outwards or inwards between the teeth; as they increase, they may cause deviation of the teeth by their pressure. If they reach any considerable size they may ulcerate and bleed freely.

**Treatment.**—The treatment of epulis consists in the first place in the early removal of the tooth in connection with which the growth arises; in addition, the growth with the adjacent mucous and periosteal tissues must also be taken away. When the tumour is not malignant, recurrence seldom takes place.

When the epulis recurs, it will generally be found to be of a sarcomatous nature; under such circumstances, the further operation consists in removing not only the tumour and the soft tissues from which it grows, but also a portion of the bone. The amount of bone removed depends of course on the extent of the tumour. In a small growth the extraction of a tooth on each side and the division of the muco-periosteum over the alveolus in a **V** with its apex well below the tumour allows of the removal of a wedge of bone with the tumour growing from it and will generally suffice.

In most recurrent cases the alveolus is more extensively involved, and a quadrilateral portion of the jaw may have to be taken away after removing the necessary teeth. In the lower jaw, a vertical saw-cut is made through the bone on each side of the growth and then, partly with a saw and partly with a chisel, these are connected transversely so as to remove the bone involved and leave the lower part of the jaw intact. The hæmorrhage is usually easily stopped by pressure; if it be severe, the bleeding point may be touched with the actual cautery.

*Previous to all operations on the jaws and about the mouth great care should be taken to cleanse the mouth and especially the teeth, as otherwise serious infection of the wound is apt to occur. The teeth should be gone over by a dentist before the operation and any foul epithelium on the surface of the tongue should also be scrubbed for two or three days once or twice a day with a nail-brush, and frequent mouth-washes should be used.*

#### MALIGNANT TUMOURS OF THE UPPER JAW.

These may be either carcinomata or sarcomata.

**CARCINOMATA.**—The carcinomata may be *epitheliomata* extending on to the jaw from the mucous membrane of the gum, the palate, or the nose, etc. A considerable number of the antral tumours appear also to belong to the class of carcinomata, and probably originate therefore in connection with the mucous membrane of that cavity.

**SARCOMATA.**—Sarcomata are also common in the upper jaw, and may begin either in the periosteum in various situations, in the substance of the alveolus, in the malar bone, or in neighbouring parts from which they extend to the jaw. In fact, the malignant tumours of the upper jaw may occur in a great variety of situations and may give

rise to very different appearances. They may grow from the periosteum in front, they may arise in the antrum, in the periosteum or the structures behind the jaw, or they may begin in the nose and spread to the jaw secondarily. As a consequence, the symptoms and appearances differ widely in individual cases, as will also the treatment and the extent of the operation.

**Symptoms.**—*When the tumour is on the anterior surface of the jaw*—when it usually begins about the malar process or may indeed be a primary affection of the malar bone extending secondarily on to the jaw—the main feature is a swelling in the cheek, without any blocking of the nose, affection of the hard palate, or elevation of the eyeball. The absence of these last characters distinguishes it from a tumour which has commenced in the antrum and has burst through the anterior wall. In these cases the skin soon becomes involved.

*When the tumour commences in the interior of the antrum* it gradually fills that cavity and proceeds to distend its walls. After a time it leads to blocking of the nostril on the affected side, and very often to epiphora from pressure on the nasal duct. It also presses up the orbital plate of the superior maxilla and leads to elevation of the eyeball; it depresses the hard palate, and may cause a swelling externally in the cheek. When the tumour commences in the wall of the antrum, it may in the early stage remain limited to that part of the cavity, and may chiefly affect the floor—so that the hard palate bulges, while the eyeball is unaffected—or it may chiefly affect the roof; the eyeball will then be displaced, and the disease will extend to the ethmoidal cells, while the palate remains intact. When the disease has spread to the ethmoidal cells, the eyeball, in addition to being elevated, is also pushed outwards; this is an important sign in connection with the advisability of operation.

*When the tumour commences at the back of the jaw or in the sphenoid or pterygo-maxillary fossæ*, and affects the jaw secondarily, the nostril may remain patent, there will be no epiphora and no bulging downwards of the palate, while the swelling in the cheek is not usually particularly marked. Among the early symptoms in these cases is protrusion of the eyeball from the extension of the growth into the orbit; before long a swelling forms in the temporal fossa.

A consideration of the situation and extent of the growth is of great importance in determining the operations that may be required, and still more in connection with the question of the advisability of operating at all. When the tumour is of rapid growth and the eyeball is displaced outwards, it is evident that the ethmoidal cells have become invaded by the disease, and all hope of extirpating it is clearly out of the question. When, on the other hand, the tumour is of slow growth, the fact that the eyeball is thus displaced does not render the case inoperable because, as we have found in more than one case, the growth may fill up the ethmoidal cells without involving the bones and can therefore be got out

along with the mucous membrane, after the jaw has been excised and without any subsequent recurrence in that situation. When the eyeball is pushed forwards or inwards, or both, the chances of success are extremely slight and as a rule it is not advisable to interfere: the tumour is evidently growing in the sphenomaxillary fossa and probably affects the sphenoidal cells and the periosteum of the skull. Hence, not only would the operation be very extensive, but the chances of removing the disease entirely would be extremely slight.

*The cases which are suitable for operation* are those in which the tumour is growing either in the antrum or on one of the surfaces of the bone, and has not yet extended up into the cells at the base of the skull. Mere elevation of the eyeball is no contra-indication to operation, and when the tumour starts in the malar bone or in front of the jaw operation is justifiable, even when the growth is very extensive.

As a rule the operation involves removal of the upper jaw, but, according to the situation and extent of the tumour, its steps may often be modified so as to get rid of some of its drawbacks. The complete excision of the upper jaw has two great disadvantages: in the first place, as a result of the removal of the orbital plate of the superior maxilla, the eyeball loses the greater part of its support and tends to drop, so that, as the scar contracts, the eye looks downwards and becomes not only useless but a source of great discomfort to the patient; the second great disadvantage consists in the removal of the hard palate and the consequent establishment of a free communication between the mouth and the cavity previously occupied by the superior maxilla. Of these troubles, the most unfortunate is the dropping of the eyeball, and in cases where the entire floor of the orbit has to be removed we believe that it is better to enucleate the eye at once.

These troubles may in some cases be avoided in planning the operation; for example, when the disease is clearly limited to the lower part of the upper jaw, the orbital plate may, in the first instance at any rate, be left intact, and the support of the eye thus remains unaffected. On the other hand, when the disease is situated mainly in the upper part of the bone and there is no thinning or bulging downwards of the hard palate, and no reason to suppose that it is infiltrated, it may be possible to peel off the muco-periosteum of the hard palate, and to unite this periosteal flap with the cheek after taking away the bone and thus to shut off the cavity of the nose from that of the mouth. It is only very rarely advisable to leave the actual bony palate with the alveolar border, but if the soft structures of the hard palate can be left it is a great comfort to the patient. In some cases the skin is so thinned or adherent to the tumour that portions of the cheek have to be taken away, and under these circumstances the question of a plastic operation to fill up the gap arises.

It will be most convenient if we now consider the operation for

complete excision of the upper jaw and subsequently refer to the modifications which have just been mentioned.

**Excision of the upper jaw.**—Besides the ordinary preparations for an operation, it is sometimes advisable when the patient is old and feeble and not likely to stand any great loss of blood, and when the growth is extensive, to administer about three hours before the operation an enema containing a drachm of chloride of calcium to the pint of water, with the view of promoting the coagulability of the blood and thus diminishing the hæmorrhage from the wound. Chloroform is the best anæsthetic; the patient may be put under gas and ether, but, during the course of the operation, chloroform is the only available anæsthetic. The head should be placed on a level with the body, or it may be somewhat depressed, the neck and upper part of the shoulders lying on a sandbag, and slightly turned towards the healthy side. In this way the field of operation is well exposed and the blood tends to collect in the naso-pharynx and does not embarrass the breathing. The facial artery on each side should be compressed against the jaw, and the surgeon grasps one side of the upper lip between his thumb and forefinger, and the assistant grasps the other, so as to control the coronary arteries. The upper lip is divided in the middle line right up to the columella, and the incision is carried along the margin of the nostril curving around the ala of the nose up to the inner angle of the orbit just below the lachrymal sac. From this point it is curved outwards along the lower margin of the orbit, stopping short about half an inch before the outer end is reached (see Fig. 76). In some cases where the malar bone is involved, and an extensive operation is necessary, it may be necessary to carry the incision outwards as far as the latter bone. Where, on the other hand, the operation deals chiefly with the lower part of the upper jaw, this incision below the eye can be made shorter, or indeed in some cases may be avoided altogether. The shorter this incision is the less is the orbicularis damaged, and, when the incision does not extend as far out as the malar bone, its nerve supply remains intact.




FIG. 76.—INCISION FOR REMOVAL OF THE UPPER JAW. The incision *bc* is used for partial operations, the limb *ab* along the lower margin of the orbit being used if necessary or if the entire bone has to be removed. The lower incision *de* is for excision of the lower jaw.

The flap thus marked out is rapidly raised, care being taken both to avoid the tumour and to cut the flap thick enough to avoid any risk of sloughing. The flap should be cleared right back to the posterior margin

of the jaw. As soon as it is raised, sponges are firmly applied over the surface, and the chief bleeding points are seized and twisted. The most troublesome bleeding occurs about the inner angle of the orbit; it is chiefly venous and usually stops after a time if the bleeding points be grasped in a pair of forceps. The capillary oozing quickly stops under pressure. The next step in the operation is to detach the periosteum from the orbital margin and push it upwards carrying with it the orbital fat and the eye, and then to introduce a copper spatula beneath it and the eye so as to keep them out of harm's way.

The surgeon then proceeds to divide the various connections of the upper jaw. In the first place, the junction of the malar bone with the

superior maxilla is sawn through and then the junction of the superior maxilla with the frontal at the external angular process (see Fig. 77). Attention is next directed to the palate. The mouth is opened, a central incisor removed and a transverse incision made along the posterior edge of the hard palate, separating the soft palate as far inwards as the middle line. The hard palate is then divided in the middle line from behind forwards by an incision extending down to the bone and then upwards over the alveolus into the nostril. The alveolus and the hard palate are sawn across with a narrow saw introduced into the nose; the division is generally completed with a long pair of cutting pliers. The orbital surface of the superior maxillary bone is now divided with a

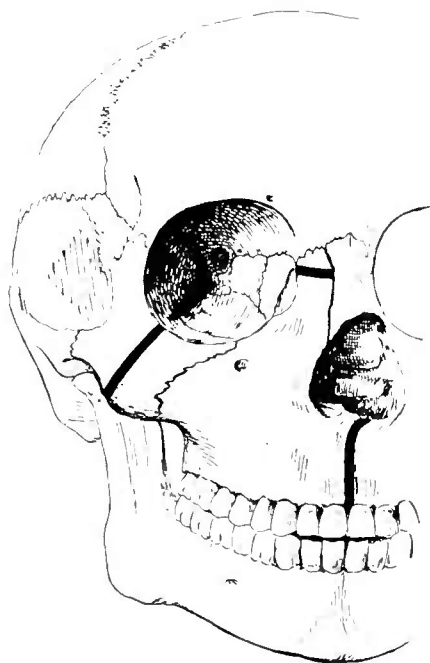


FIG. 77.—LINES OF BONE-SECTION IN REMOVAL OF THE UPPER JAW.—The nasal bone is separated from the nasal process of the superior maxilla with a chisel and turned aside.

small saw and a pair of cutting pliers, one blade of which is introduced into the orbit and one into the nose. The forceps are then pushed well back and, using the bridge of the nose as a fulcrum, the upper jaw is forcibly levered out. As soon as the posterior attachments are felt to give way, the upper jaw is seized with a pair of lion forceps, taking hold of the alveolar and orbital margins, and rapidly twisted out.

In some cases it comes out intact; in others, when it is extensively diseased, it breaks down and only a part comes away. In any case one or two large sponges should be at once packed into the cavity from which the jaw has been torn to arrest the bleeding: after a short time these sponges must be cautiously raised, any bleeding point of consequence

clamped, and the condition of the surface inspected, any remains of the upper jaw or portions of the tumour being clipped away. The bleeding chiefly comes from the pterygo-maxillary fossa, and for the most part stops on pressure; if vessels of any size bleed they can be tied.

After having made quite sure that the whole tumour has been removed and that the bleeding has been arrested, the raw surface should be thoroughly sponged with a solution of chloride of zinc (40 grs. to the oz.), and, for a few hours at any rate, the cavity should be stuffed with iodoform gauze. The ends of the gauze should be brought out at the angle of the mouth and tied together with a piece of silk, which is then fastened around the ear. The flap is brought into position and carefully sutured, the best material to use being silkworm-gut at the angles, with intermediate stitches of horsehair. Care must be taken to see that the red line of the lip is properly united on the two sides; it should be turned outwards and the mucous membrane carefully stitched up as far as the nostril so as to obtain union of the mucous surface. If this be omitted the raw surface may get adherent to the divided margin of the alveolus, and imperfect movement of the upper lip will result. The patient is then put back to bed and well propped up so as to diminish the risk of hæmorrhage and the possibility of blood passing into the larynx.

*Difficulties and dangers.*—The principal danger in this operation is connected with the loss of blood, and every care must be taken to see that the hæmorrhage is checked as quickly as possible. For this purpose sponge pressure associated with cold douching of the face answers best. Some surgeons advise that in cases where the tumour is very vascular a preliminary tracheotomy should be performed and the pharynx plugged. We have not yet met with a case in which we have thought it necessary to do this, but of course it is quite likely that, when the operation is done for a very extensive tumour that spreads far back, such a procedure would be advisable. There is remarkably little shock accompanying the operation and in the majority of cases the wound heals without any complications; in fact, out of a considerable number of these operations we have not lost a single case. Patients, however, who are very feeble or advanced in age may succumb, and a similar result may happen where septic cellulitis or erysipelas attacks the wound or where putrid material has passed down the air passages and given rise to septic pneumonia. As a rule, however, the cavity left is so widely open that the discharge escapes freely, while the application of the chloride of zinc solution after the operation and the subsequent sprinkling of the wound with iodoform protects the tissue for two or three days at least from septic troubles.

*After-treatment.*—The stuffing introduced at the time of the operation should be removed within 24 hours at latest and in the majority of cases should not be re-inserted. The wound should be frequently washed out by spraying the cavity from the mouth or nostril with boro-glyceride or sanitas, and the patient should wash out the mouth repeatedly with these antiseptic

solutions. Some surgeons advocate the continued stuffing of the cavity to prevent the cheek from falling in, but it is very doubtful whether any degree of care will prevent the contraction of the cheek, and the great objection to stuffing is the rapid putrefaction of the discharge in the strips of gauze. Certainly in cases where the palate is left, the stuffing should not be continued: when the palate has been taken away, it may be of advantage to pack the wound lightly with iodoform gauze, which should be renewed on every occasion after food. This is of advantage not only in collecting the discharge, but chiefly in forming a roof to the cavity of the mouth and enabling the patient to swallow without any material passing up into the cavity above.

For the first few days it is well to feed the patient with nutrient enemata and suppositories: after the third day, when the wound is beginning to granulate, the diet should consist of fluids (milk and beef-tea) administered through a feeder provided with a long india-rubber tube which is passed down into the pharynx on the sound side. After about three weeks solid food can be easily managed, especially if the cavity left after removal of the jaw be temporarily plugged with gauze. The patient may generally be allowed to sit up in two or three days and to get out of bed in the course of a week or ten days; the erect position favours the escape of the discharge very much. In the course of two or three months the cavity will have contracted pretty much to its ultimate extent, and the patient may then be sent to a dentist with the view of having some apparatus made to fill up the cavity in the upper jaw and to carry the teeth; in some cases the result is remarkably favourable and the deformity very slight.

**Modified operations.**—The above is the operation for complete removal of the superior maxilla, but wherever possible it is important to modify it so as to avoid one or other of the chief difficulties already alluded to, more especially the dropping of the eye. Hence, in all cases, unless it be quite evident that the orbital plate of the superior maxilla is diseased, it is best, after turning up the periosteum from the orbital margin, to run a fine saw through the orbital plate of the frontal bone just inside the margin, from the internal to the external angular process, so that when the upper jaw is detached the orbital plate shall remain behind. This is best done with a fine saw, but it may be chiselled through, only in that case care must be taken that the bone is not splintered. If the orbital plate be left in this way it is quite easy after removal of the remainder of the upper jaw to see whether it is necessary to remove it or not. Of course, if diseased, it must be completely removed, but in a number of cases it will be found that it can be left behind. When the disease is clearly limited to the lower part of the jaw, the whole of the orbital plate may be left intact and, instead of sawing inside the orbit, the saw-cut may be carried outside the orbital margin throughout.

Attention should also be directed to the possibility of shutting off the communication between the cavity and the mouth. It is very seldom that



it is advisable to saw through the lower part of the jaw from before backwards so as to leave the alveolus intact, but in a considerable number of cases, probably more often than is done, it is possible to leave the muco-periosteum of the hard palate behind and afterwards to attach it to the cheek so as to shut off the cavity from the mouth. When this procedure is decided on, an incision should be carried along the palate on the side affected, just inside the teeth, extending from the hamular process to a little beyond the middle line in front, and the periosteum and mucous membrane should be raised with an elevator as far as the middle line, as in the operation for cleft palate. It is well to divide the soft palate from the hard by a transverse cut as in the previous operation; this can be readily stitched up afterwards. After the operation is completed, the free edge of this muco-periosteal flap is stitched with catgut to the line of division of the mucous membrane on the inner side of the cheek and the incision between it and the soft palate is also similarly united; in this way the cavity of the nose is shut off from the mouth. The only difficulty is in regard to stuffing the cavity should that be required; as has been said, however, it is best not to employ stuffing in any case except for the first few hours, and the strips of gauze put in at the time of operation can be readily pulled out through the nostril.

In some cases the skin flaps must be modified so as to remove portions of the skin over the tumour when the latter is suspiciously near the surface. Under such circumstances a plastic operation will be required, either at the time or at a later period, in order to cover up the defect; whenever possible, the plastic operation should be done at the time of the operation. Sometimes, however, the gap is so large that it is impossible to close it in this way, and under the circumstances it may be best to leave it open and cover it up with a flesh-coloured plate held in position by spectacles. There is the great advantage in doing this that the cavity can be inspected and any sign of recurrence nipped in the bud by the application of caustics such as chloride of zinc paste or sulphuric acid (see Part II., p. 164).

#### INTRA-NASAL MALIGNANT TUMOURS.

Operations in connection with the upper jaw may be required for disease limited to the nasal cavity and not requiring complete excision of the entire jaw for its removal. For example epithelioma or even sarcoma may commence in the mucous membrane or the bony wall of the nasal cavity, such as the upper surface of the hard palate, the turbinals, etc.

It is very seldom that malignant disease of the nose can be dealt with by any of the intra-nasal methods. In order to give the patient a fair chance, some external operation must be performed. When the disease is situated towards the anterior part of the nasal cavity, there are two chief methods in which it can be reached and removed; the one is the operation introduced by Rouge, the other is an operation involving an external incision with detachment of the affected side of the nose from the bone.

**Rouge's operation.**—Before beginning the operation, the posterior nares must be plugged, so as to prevent the blood running back and accumulating in the pharynx. Some surgeons even go the length of performing a preliminary tracheotomy and plugging the pharynx, but, unless the operation be a very extensive one, it is very seldom that this is necessary: in most cases the posterior nares can be quite efficiently plugged in the ordinary manner. The chief objection urged against plugging the nares is that the plug is apt to slip and more especially that the string keeping the plug in position is apt to be divided during the operation. The slipping of the plug depends to a great extent on the manner in which it has been introduced, and to avoid cutting the string which holds it forwards it is well to employ a silver wire instead. The plug is made of boracic lint folded to a size which will fill up the posterior nares and narrow enough to be pulled into it: attached to this is a piece of string with both ends long, and in addition it is well, as has just been said, to attach a piece of silver wire to the part which will come into the nares; but it is better not to employ wire for the portion that passes round the palate into the mouth because in withdrawing it the palate may be cut. Special instruments such as Belocq's sound may be used for the introduction of the plug, but the simplest plan is to take a gum-elastic catheter of small size, pass it through the nose and down into the pharynx and then, holding the mouth open, to seize the tip and pull it out of the mouth. The string and silver wire are then attached to the tip of the catheter which is withdrawn through the nose carrying with it the string attached to the plug. The plug is then drawn into the mouth, and, to avoid injury of the soft palate, it is well to push it back into the pharynx with the finger: when it has disappeared behind the lower edge of the palate the string through the nostril is pulled upon and the plug drawn up into the posterior nares. The finger is introduced behind the palate to see that the plug is properly in position and the end of the string is kept out of the way by an assistant. As a rule it is well to plug both nostrils and of course that is essential when the nasal septum is to be operated on.

The patient is arranged with a sandbag beneath the neck and the head extended so that the nose faces the light; the upper lip is raised, pulled out from the jaw and everted by an assistant, while the surgeon divides the mucous membrane at its reflection from the bicuspid teeth on one side of the jaw to those on the other. The incision is carried upwards keeping close to the bone, and the upper lip is entirely detached from the bone. The septum must then be detached from the nasal crest and the ala of the nose from the upper jaw on each side.

The lip can now be pulled upwards so as to expose the lower part of the opening of the nostrils. The view obtained is quite good in front, but more restricted further back. The exact limits of the disease are then made out, an incision is carried through the mucous membrane at a little distance around it, and the area of bone corresponding to the disease

is chiselled away, so that the growth and the bone beneath are lifted away in one piece along with a fair amount of healthy tissue around.

The bleeding is usually easily stopped by pressure, and when this has been done the surface may be sponged with chloride of zinc and the lip and nose replaced in position; as a rule, no stitches are required. The plugs in the posterior nares are then removed, and the patient put back to bed with the head somewhat raised. Rouge's operation is also employed for the removal of polypi, etc., and it has the great advantage that it prevents any scar; at the same time it has only a limited application, especially in cases of malignant disease, on account of the small area of the nasal cavity which is thoroughly exposed to view.

**The external operation.**—When the disease is extensive, or far back, the most satisfactory plan is by an external operation. The simplest of these is to divide the upper lip in the middle line into the affected nostril, and then, carrying the incision outwards, to detach the ala of the nose from the bone. The incision must be carried upwards on to the nasal bones, and the cheek must be separated so that it can also be pulled well outwards. In some cases it may be necessary to detach the cartilaginous from the bony nose, so as to turn the parts more completely aside. By this operation a complete view of the bony orifice of the nostril may be got, and, by chipping away portions of the superior maxilla, access can gradually be got for a considerable distance backwards; the posterior nares should be plugged. For malignant disease we believe that the external operation is more satisfactory than Rouge's operation, and of course the first object in these cases is to remove the disease thoroughly, the slight scarring along the side of the nose being a matter of secondary importance.

#### MALIGNANT TUMOURS OF THE LOWER JAW.

In the lower jaw, as in the upper, are found both superficial tumours and those affecting the substance of the bone. Epitheliomata of the lower jaw due to the extension of growth from the floor of the mouth or the tongue on to the adjacent portions of the jaw are quite common; primary malignant tumours of the lower jaw, either periosteal or endosteal, are also frequently met with.

**Treatment.**—In cases of epithelioma affecting the alveolus and not spreading into the substance of the bone it is usually possible to remove the affected portion without destroying the continuity of the lower jaw; this is a point of extreme importance, because if a portion of the whole thickness of the jaw be removed, the line of the teeth is apt to be so altered that proper mastication is no longer possible. Hence, in cases of epithelioma spreading on to the alveolus, a bridge of bone should be left below whenever it is possible. The mucous membrane must be incised around the ulcer after extraction of the necessary teeth and the included portion of bone removed by vertical saw-cuts joined transversely below:

the final division of the transverse cut is best effected by a chisel. Access to the part may be gained in various ways according to circumstances. In most cases it is best to carry a curved incision along the lower margin of the jaw and to turn a flap upwards: in some however it may be more convenient, both for the operation on the bone and also for the operation on the tongue, or whatever other part the disease is spreading from, to split the cheek outwards towards the masseter. The various incisions required for these cases will be described either presently in speaking of excision of the lower jaw or later on in speaking of diseases of the tongue and floor of the mouth. The point which we wish to emphasise here is that whenever possible a bridge of bone should be left intact connecting the anterior and posterior parts of the jaw, and this is usually most conveniently done by an incision below the jaw and turning up the tissues over it.

Tumours growing elsewhere than in the alveolus usually require removal of the affected portion of the jaw, and, according to the extent and seat of the tumour, the following operations may be required:

1. Excision of one-half of the jaw.
2. Excision of the horizontal ramus or portions of it on one side of the angle.
3. Excision of the symphysis.
4. Excision of the entire jaw.

**Removal of one-half of the lower jaw.**—The patient is propped up by pillows beneath the shoulders, the head allowed to hang back over a sandbag and turned towards the sound side. Chloroform should be administered: tracheotomy is unnecessary unless the growth extends beyond the limits of the lower jaw and involves a very extensive operation. The incision is commenced in front of the chin about an inch above the symphysis (see Fig. 78). It is then carried downwards to about half an inch below the lower margin of the jaw and along the bone at this distance below it till the angle is reached, when it is curved upwards over the posterior border of the jaw, as far up as will safely avoid the facial nerve. This incision is deepened until the bone is fully exposed; the facial vessels will be seen and should be clamped and divided. The flap is rapidly raised from the jaw, the masseter muscle being taken up with it, unless it be involved in the disease, when of course it must be left behind. The raising of the flap is continued until the mucous membrane is reached, but at this stage the cavity of the mouth should not be opened.

The soft parts are next separated from the inner surface of the jaw, the mylo-hyoid and the internal pterygoid muscles being divided and the latter peeled up, unless it be infiltrated too. Here also the incision should be carried up to the mucous membrane, but not through it, and up to this point there will be no trouble from blood running into the pharynx; any vessel bleeding externally can be clamped and twisted if necessary. An incisor tooth on the affected side is now extracted and the bone is

divided with the saw, if possible a little to one side of the middle line, so as to leave the attachment of the tongue muscles. The flap being held up, the mucous membrane is divided all along the outer side of the jaw, after which, by pulling the jaw outwards, the mucous membrane on the inner side is also divided. The jaw is now forcibly depressed while the flap is held up; this brings the coronoid process into view and, by cutting on it, the tendon of the temporal muscle is gradually divided; the jaw will then depress much more freely.

In some cases, either because the size of the tumour prevents proper depression of the jaw, or because of the extra length of the coronoid process, it is very difficult to divide the muscle satisfactorily, and under such circumstances it is best to snip across the coronoid process with bone pliers and dissect it out after the lower jaw has been removed. Finally the jaw is firmly




FIG. 78.—INCISION FOR REMOVAL OF THE LOWER JAW. The thick black line *de* is the one referred to.

depressed and pulled outwards while the ligaments around the articulation are divided. In some cases indeed the jaw can be forcibly pulled out, but it is generally well to divide the external ligaments at any rate. Care must be taken to cut close to the bone and especial care must be taken in turning the jaw outwards not to twist the soft parts out with it; otherwise the internal maxillary artery may be divided. As a rule, when the ligaments on the outer side are divided the jaw may be pulled out.

After the jaw has been removed, the soft parts must be carefully examined to see that no growth is left behind; the sub-maxillary and the anterior triangles, should also be investigated and if necessary opened up to make sure that there is no glandular disease. The bleeding is arrested, the raw surface sponged over with chloride of zinc solution (grs. 40 to the oz.), and the incision is sutured with silkworm-gut or horsehair. It is well to introduce a drainage tube projecting into the mouth opposite the angle of the jaw; the ordinary cyanide dressings are applied. The patient is put back to bed, propped up with pillows and the head turned towards the side operated on, so that the discharge may readily escape.

*After-treatment.*—To check the capillary bleeding, the patient should suck small pieces of ice wrapped in fine muslin. The dressing will require changing two or three times a day for the first few days. After the fifth day the drainage tube can be taken out, washed, and a suitable portion of it cut off; the remainder is then put in the external part of the tract: as the tube no longer projects into the mouth, the communication with the

mouth is allowed gradually to close. The tube can usually be left out altogether about the tenth day, by which time the whole line of incision will be healed with the exception of the place where the tube is.

For the first two or three days the patient should be fed by nutrient enemata and suppositories. Subsequently he may be allowed to take liquid nourishment by the mouth, the fluid being put in a feeder to which a piece of india-rubber tubing is attached, and this is carried well back towards the pharynx on the sound side. It is well to turn the head to the sound side and rather depress it when taking food so that the fluid runs down along the healthy mucous membrane and does not come in contact with the raw surface. At the end of a week semi-solid food may be given and usually the patient may be allowed to get up. The bowels should be kept freely open and the mouth frequently syringed with antiseptic lotions, especially after taking food. After about a week the patient can generally rinse out the mouth for himself.

After recovery there is usually considerable deformity because the portion of the jaw remaining becomes pulled over towards the affected side, partly from the want of support and partly from the contraction of the scar. With any sort of apparatus this is to some extent unavoidable, but inter-dental splints fixed on the sound side between the upper and lower jaw may be employed from an early period with the view of keeping the line of the teeth as normal as possible.

The operation often requires to be modified according to the size and situation of the tumour. In some cases portions of the skin over the tumour must be taken away; a plastic operation is then necessary. As a rule it is unnecessary to cut through the free margin of the lip at the anterior part of the incision, but when the tumour is of great size, it may be impossible to avoid this; care must of course be taken in suturing the incision to see that the red line is in proper apposition.

Where the jaw is much destroyed by the growth, it may be found that in depressing it in order to disarticulate, fracture may take place; under these circumstances the fractured portion should be detached as rapidly as possible and the ascending ramus of the bone is then seized with lion forceps, pulled downwards and twisted or dissected out as before.

**Removal of the horizontal ramus alone.**—When the tumour is endosteal and is limited, the ascending ramus may be sometimes left behind. The method is of course the same as already described, except that, instead of detaching the coronoid process and disarticulating, the jaw is sawn across at the angle. In some cases again it may be necessary only to remove smaller portions of the jaw.

When the ascending ramus is left, it is well to try to keep the teeth on the sound side in proper position in some more effectual manner than by the use of inter-dental splints. One plan is to put a piece of boxwood between the divided bones or to fill up the interval with stent, these plugs being kept in while the healing is taking place so as to

prevent the fibrous contraction. Subsequently some form of vulcanite or other denture can be made by the dentist to fill the vacant space. These boxwood splints answer very well for the first week or two but after that time, as the part becomes filled up with fibrous tissue, they are forced out of place and contraction proceeds rapidly. Nevertheless, even if only kept in for a week or two, they are of considerable advantage. Another method by which the gap can be kept open and which in some cases is more convenient is by bridging it over with a band of nicked steel or an ivory peg fixed into the bone on each side. Holes can be drilled on each side to receive the metal peg which is cut so that, when the ends are fixed into these holes, the gap shall be of proper width. The only trouble is that in the course of time the holes enlarge by inflammatory action and the pegs get loose and may even fall out. As a rule however the contraction of the scar prevents them falling out if they have been buried sufficiently deeply in the jaw.

**Removal of the symphysis.**—Excision of the central portion of the jaw alone is chiefly required when epithelioma has spread from the floor of the mouth and the periosteum has become infiltrated in the neighbourhood of the symphysis. The removal of this portion of the jaw of course involves the complete detachment of the muscles which hold forward the tongue and this is the chief trouble in the after-treatment. The removal itself is simple enough and hardly requires description. The skin must be divided along the lower margin of the jaw for the requisite distance; the necessary teeth are extracted, the bone is sawn through on each side and the wedge is then removed with the necessary portions of the soft tissues. Before the bone is actually removed, the tip of the tongue should be seized with forceps so as to prevent it falling back and choking the patient. In all cases of removal of the symphysis it is most necessary to try to prevent the two divided surfaces coming together, as otherwise the lower jaw is hopelessly contracted and the teeth in it lie on a plane greatly posterior to those in the upper. Two nicked steel rods, one fixed in the lower border of the jaw and the other in the upper, may be used with great advantage; if these be not handy, the insertion of a wedge of boxwood may be tried. Whichever be employed, a stitch should be put through the muscles of the tongue and fastened over the wedge or the steel pins so as to keep the tongue forwards; in the course of three or four days, when the wound is granulating and the parts are becoming consolidated, the tongue will retain its position. The best material for this stitch is silkworm-gut which does not get septic in the same way that a silk suture does.

**Removal of the entire jaw.**—In some cases the whole of the jaw may require removal; this is done practically in the same way as above described, each half of the jaw being removed separately.

## CHAPTER XIX.

### TUMOURS OF THE NASO-PHARYNX.

TUMOURS in the naso-pharynx are not uncommon and may be either polypoid or sessile, simple or malignant. The ordinary naso-pharyngeal polypi may be simple fibromata, but perhaps most frequently they are fibro-sarcomata, and unless carefully removed are very apt to recur. They generally have a broad attachment to the under surface of the sphenoid, and often run forwards on to the posterior part of the roof of the nose. They are usually very firm and contain large blood-vessels, more especially large venous sinuses, and, the vessels do not lie in a sheath and therefore do not retract when divided; hence, incision into one of these naso-pharyngeal polypi is usually followed by furious bleeding which does not cease spontaneously. The naso-pharyngeal polypi grow with varying rapidity according to their nature. They fill up the naso-pharynx, bulge down the soft palate and may even escape behind the latter and project into the pharynx itself; they also grow forwards into the posterior part of the nose. The surface frequently becomes abraded and bleeding is very common and usually very severe. Hence these tumours cannot be left alone; it is necessary to attempt their removal.

**Treatment.**—Attempts have been frequently made to remove these tumours by means of a wire loop, an *écraseur*, or the galvanic wire, but these attempts are not as a rule followed by success. In the first place, an ordinary wire loop is out of the question; apart from the difficulty of getting it round the base of the growth, it is not strong enough to cut it through. With the *écraseur* the great difficulty is to get the loop round the base of the tumour and, without some operative interference, this is usually impossible. The great objection to all these methods is that only the neck of the tumour is cut across and the base is left behind and tends to grow again, sometimes pretty quickly; besides this, the base is very vascular and the bleeding may be very severe or even actually fatal. Hence, in most cases of naso-pharyngeal polypi it is well to expose the



base of the tumour more thoroughly and if possible to remove it and the periosteum from which it grows.

The polypi can be got at in various ways, and we shall here indicate the chief routes by which they are approached. The actual details of these operations need hardly be given because as a rule there is no urgency in the operation and the various plans can be considered at leisure.

In one set of operations the tumour is got at *through the mouth*. Of these probably the best plan is that introduced by Nélaton, which consists in splitting the uvula and soft palate, carrying the incision forwards in the middle line on to about the posterior half of the hard palate. At the anterior end of this, transverse incisions are made halfway across the hard palate on each side, and muco-periosteal flaps are raised towards each side. In this way the posterior part of the bony palate is exposed. Then by means of a chisel and hammer the portion of bone so exposed is chipped away. When this bone is removed, the mucous membrane of the floor of the nose and the septum are exposed and the former is divided close to the septum and turned aside; such portions of the septum are chipped away as may be necessary to expose the base of the tumour. The result of this procedure is to give a very fair view of the growth although it does not give very good access to its base. It certainly is sufficient to allow one to pass an écraseur loop around the tumour through the nose; when the main mass of the tumour has been removed in this way, providing the bleeding can be checked, the periosteum from which it is growing can be peeled off readily enough. At the same time, as has been already said, cutting through the pedicle is apt to be followed by very severe bleeding, which is very difficult to check, and the operator may be unable to go on to the complete removal of the pedicle. Annandale performs the operation by simply splitting the soft and hard palates, dividing the bone, and then pulling asunder the two halves of the jaw. Other operations by the mouth have been described, but with regard to all it must be admitted that, especially where the tumour is malignant, sufficient access is not obtained to the growth. The best of them however seems to be that introduced by Nélaton.

In other cases, attempts have been made to reach the tumour *through the nose*. Rouge's operation has been employed by some but the access given to the back part of the nose by this operation is so imperfect that it cannot be recommended. Ollier has employed an operation in which, instead of turning up the nose, as in Rouge's operation, the nose is turned down. An incision is made across the upper part of the nasal bones and downwards on each side towards the alæ of the nose. The bones are then sawn through, the septum divided as far as is necessary, the soft parts detached and the nose turned down. But here again the access given is quite insufficient, for it must be remembered that there is a distance of something like two to three inches between the level of the

nose and that of the naso-pharynx and the work has to be done through quite a narrow channel on one side of the septum in order to reach the tumour.

A third set of operations consist in *the osteoplastic resection of the upper jaw*, of which the type is Langenbeck's. In this case incisions are carried through the skin commencing below the outer extremity of the orbital margin, running forwards to the nasal bones, curving downwards to about opposite the ala of the nose and then running outwards again in the cheek. The underlying portion of the bone which consists of the entire upper jaw with the exception of the orbital margin above and the alveolar margin below, is divided with the saw and then an attempt is made to lever this portion outwards along with the skin covering it. This is really a very difficult matter, and, when it is done, the space left is after all not large, while on the other hand the skin incision is a great deformity.

In cases of malignant polypi about the back of the nose it is best in our opinion to *remove portions of the upper jaw* rather than to attempt to work through a small opening. The line of incision is that for a partial excision of the upper jaw (see p. 220). It is certainly not necessary to remove the orbital plate and it is also unnecessary to remove the periosteum of the hard palate, but it is well to remove the rest of the bone and if the muco-periosteal hard palate be turned aside, in the way already described (see p. 221), and an incision carried through the bone below the orbital margin, the lower part of the maxilla can be removed by dividing the palate process to one side of the middle line, the frontal process of the bone below the orbital margin and the malar process externally. The posterior part of the antrum, which generally breaks off, can be chipped away; in this way free access is obtained to the naso-pharynx. The base of the tumour can then be properly dealt with. After all, the deformity resulting from an operation of this kind is extremely slight. The line of incision need not be carried very far out along the orbital margin and, when carefully united, hardly shows, while the cavity left is shut off from the mouth by the hard palate and the sinking-in of the cheek is comparatively slight, more especially as no portion of the malar bone need be taken away.

When the tumour is malignant and sessile, no operation short of a partial excision of the upper jaw such as the above will give satisfactory access to the part; with such an operation there is a perfect view into the naso-pharynx if the pterygoid process be also cut through. Such a procedure is described by one of us in the Lettsomian Lectures for 1897.<sup>1</sup> In the case detailed in these lectures the access to the disease, after removal of the lower part of the upper jaw and the pterygoid processes, was perfect and, although a portion of the Eustachian tube was involved, it was removed

<sup>1</sup>See also *Objects and Limits of Operations for Cancer*, by W. Watson Cheyne. Baillière, Tyndall & Cox. 1897.

thoroughly and with practically no bleeding. In that case a preliminary tracheotomy was performed, but it must be admitted that the bleeding was so slight that it proved to have been unnecessary. At the same time it is probably best in all these operations in the naso-pharynx to start with a preliminary tracheotomy. Even if it be not necessary, it adds to the comfort of the surgeon and enables him to devote his full attention to the thorough removal of the disease, while at the same time it does not materially add to the dangers of the procedure.

## SECTION IV—THE LARYNX AND TRACHEA.

### CHAPTER XX.

#### CONGENITAL AFFECTIONS: INJURIES.

##### PERSISTENT THYRO-GLOSSAL TRACT.

THIS embryonic structure commences at the foramen cæcum on the dorsum of the tongue and runs downwards in the middle line of that organ, passing between the posterior surface of the body of the hyoid bone and the front of the thyroid cartilage to the isthmus of the thyroid gland; the thyroid isthmus is developed from it. As a rule the entire tract is obliterated, but the whole or a portion of it may remain and give rise to a central fistula which is situated just above the thyroid isthmus. In other cases again the tract may be obliterated at both ends and an unobliterated portion in the centre may become dilated, leading to the formation of a cyst, either in the neighbourhood of the base of the tongue or very commonly just in front of the thyro-hyoid membrane and extending upwards behind the hyoid bone.

**TREATMENT.**—(a) **Of a fistula.**—Sometimes a thyro-glossal fistula may cause very little trouble and it may not be necessary to adopt any treatment for it. Operation should never be lightly undertaken, as the satisfactory treatment of this condition is a matter of very considerable difficulty. In many cases, however, the fistula discharges fairly freely and is a source of so much irritation and discomfort to the patient that he insists on something being done. The only treatment likely to do any good is an attempt to dissect out the fistula completely. It will not close until its epithelial lining has been entirely removed, and any attempt short of excision, such as destruction by caustics or the cautery, invariably fails.

The removal of the fistula, if complete, is not easy. An incision is carried downwards from the upper border of the hyoid bone, diverging below so as to enclose the orifice of the fistula. The fistulous tract is defined by passing a stout probe along it, and its wall is then dissected out.

Difficulty is met with when the posterior surface of the hyoid bone is reached, in cases where the sinus runs higher, because it is not at all easy to remove the upper part of the tract. In these cases, after having cleared the fistula well up to the hyoid, the skin incision should be prolonged upwards towards the chin and the tongue muscles separated until the fistulous canal is exposed above the bone; the separation is then continued and the entire tract removed. It is well to put in a drainage tube above the hyoid for a few days.

(b) **Of a cyst.**—A cyst is likewise very troublesome to treat. If not removed, it tends to increase in size and may cause not only deformity but interference with the patient's comfort. Tapping is of no use whatever, while the operation of complete extirpation is even more difficult than the removal of the upper part of the fistulous tract described above, on account of the wide lateral extent of the cyst. Nevertheless, if the cyst be a cause of serious annoyance to the patient, it must be removed in a manner similar to that recommended for removal of the duct.

#### ENLARGEMENT OF THE THYRO-HYOID BURSA.

Enlargement of the thyro-hyoid bursa is not at all uncommon, and the diagnosis between this condition and a cyst in connection with the thyro-glossal duct is sometimes a matter of considerable difficulty. The distinct limitation of a bursal sac, its central situation and the fact that it bulges below the hyoid bone rather than above it, are points in favour of a bursal swelling.

**Treatment.**—The simplest plan is to dissect out the bursa, and, if that be done, it is a matter of indifference whether the diagnosis has been right or wrong. A vertical incision commencing a little above the upper border of the hyoid bone and carried downwards to the lower end of the cyst will expose its anterior wall, which is then defined laterally by pushing the tissues aside, and the bursa is readily shelled out.

#### INJURIES OF THE LARYNX.

**FRACTURES OF THE HYOID BONE.**—These are extremely rare and generally result from direct violence, such as suicide by hanging or attempts at throttling. In death from hanging, the body of the bone is often broken, whereas in attempts at throttling the fracture usually occurs at the junction of the body with one of the cornua. The injury is generally accompanied by serious symptoms. The pain is great and, if the fracture be compound into the throat, as it frequently is, there may be severe hæmorrhage from the mouth; the difficulty in swallowing and speaking may be also very marked. Later on, severe dyspnœa with constant cough and expectoration are very likely to occur from the inflammatory disturbance about the fracture.

**Treatment.**—The displacement is best reduced by manipulation. The throat is painted with a 10% solution of cocaine, and the forefinger of one hand is introduced into the pharynx whilst the other hand outside manipulates the fragments into position. Should cocaine be insufficient to enable the patient to tolerate this, a general anæsthetic must be given. Although reduction of the deformity is easy, there is great difficulty in keeping the fragments in position. An attempt may be made to prevent all lateral movements as well as flexion and extension of the neck by a properly moulded pasteboard or poroplastic collar, and the patient should be restricted from swallowing as far as possible for the first three or four days, food being given entirely per rectum. In addition to this he should be kept as much as possible in the upright position.

The results thus obtained are very disappointing, and a better method would seem to be to expose the fragments immediately through an external incision and to wire the ends together. In simple fractures this method gives the patient immediate relief from pain and avoids the possibility of the deformity subsequently interfering with the proper action of the larynx. The bone can readily be exposed by a transverse incision over the seat of the fracture, care being taken in deepening the incision not to go too far back or too low down, which would endanger the superior laryngeal nerve. The bone is then wired in the ordinary manner (see Part III., p. 52).

In a compound fracture, an external opening, such as would be necessary in the above operation, will be actually beneficial by providing suitable drainage and preventing the œdematous inflammatory swelling which is apt to give rise to considerable trouble.

#### **FRACTURES OF THE CARTILAGES OF THE LARYNX.—**

These fractures are of considerable rarity, and are produced by causes similar to those giving rise to fracture of the hyoid bone. The injury is very serious, a large proportion of the cases terminating fatally from the obstruction to respiration consequent on the displacement of the cartilaginous walls of the larynx. If the case be left untreated, this obstruction rapidly increases owing to the inflammatory reaction around the part,

whilst in any case it may come on after an interval, even when there has been no difficulty in breathing immediately after the accident.

**Treatment.**—*If there be obstruction to the breathing,* it is advisable to perform *laryngotomy* at once. A small vertical median incision is made over the crico-thyroid space, its edges are well retracted, the muscles are separated, the crico-thyroid membrane is opened by a transverse incision, and a suitable laryngotomy tube (see Fig. 79) is inserted. The surgeon should at the same time enlarge the incision upwards and expose the *alæ* of the thyroid cartilage. He can then bring the fractured portions

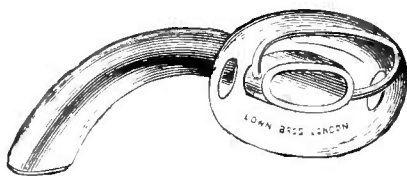


FIG. 79.—LARYNGOTOMY TUBE. The cross section of the tube is oval, the short diameter being vertical.

into apposition and secure them by a few catgut sutures. As a rule the laryngotomy tube can be left out after five or six days.

*When there is no impediment to respiration,* it is unnecessary to have recourse to any active treatment if the patient can be kept under close observation. The parts should be kept at rest by the aid of a suitably moulded poroplastic collar, and union takes place readily. Should œdema of the glottis supervene, intubation of the larynx (see p. 422) may be called for. Should the patient be so situated that the surgeon is not readily available in case urgent symptoms arise, it will be safer to introduce a tube by intubation or to perform tracheotomy (see p. 248) in the first instance, or at any rate immediately on the appearance of the slightest swelling.

## CHAPTER XXI.

### CUT THROAT.

THIS may be either suicidal or homicidal ; in the latter case the structures are generally more extensively damaged than in the former, and it is in them especially that wounds of the important vessels and nerves of the neck most frequently occur. In suicidal wounds of the neck the chief damage as a rule is inflicted on the left side, but the sterno-mastoid by contracting usually protects the large vessels from injury. The extent and situation of the wound varies considerably in different cases. Usually the incision runs across the thyro-hyoid membrane or just above the hyoid bone. It is rare for the trachea itself to be opened in suicidal cases ; in some however the thyroid cartilage may be cut through. It is rare in any case for the larger vessels, the carotid artery and the internal jugular vein, to be injured ; the bleeding usually comes from the larger veins joining the jugular, especially the superior thyroid and lingual. It is most convenient to divide the cases up into those in which the air-passages are not implicated and those in which they are involved.

**1. Wounds not implicating the air-passages.**—Wounds through the thyro-hyoid membrane or above the hyoid bone do not necessarily implicate the air-passages although, when carried deeply, they may do so. For example, when the incision is in the former situation the base of the epiglottis may be cut across ; when above the hyoid bone, part of the epiglottis may be severed and the pharynx opened ; but there is no communication with the larynx or trachea.

**2. Wounds involving the air-passages.**—Wounds of this kind are much more serious on account of the complications, both immediate and remote, which may follow them. Thus, the large vessels or nerves in the neck may be divided, but this is rare in suicidal cases. If there be a deep wound above the hyoid bone there may be very free bleeding from the lingual or facial arteries or veins, and the tongue muscles may be cut through to such an extent that the organ may fall back over the aperture of the larynx and death from asphyxia may occur.



When the incision is through the thyro-hyoid space, the base of the epiglottis may be severed, and a similar obstruction to respiration is then produced. In this case also there may be free bleeding from the lingual or superior thyroid vessels. The superior laryngeal nerve may also be divided, and in this, as well as in the next group of cases, the blood may pass down into the trachea and may actually choke the patient.

When the wound of the air-passages is through or below the thyroid cartilage the oozing is generally very free indeed, and there is great risk of rapid asphyxia from the entrance of blood into the air-passages. Should the trachea be completely divided, the risk of asphyxia will be still greater, as the interference with respiration is then due not merely to entrance of blood but to actual displacement of the two halves of the tube. The recurrent laryngeal nerve is also frequently injured in these cases, and the carotid artery may be also divided, especially if the œsophagus be wounded.

Amongst the later complications may be mentioned septic infection of the wound, leading to diffuse cellulitis extending down into the mediastinum, and bronchitis and broncho-pneumonia, the latter being especially apt to occur, as the patient is often in a low state of health at the time of the self-inflicted wound. Among the less frequent sequelæ are emphysema of the neck, an aërial fistula, subsequent laryngeal stenosis or paralysis of one vocal cord following division of the recurrent laryngeal nerve. Apart from these complications, the fact must never be lost sight of that the patient is very likely to repeat the attempt upon his life.

**Treatment.**—1. **When the air-passages are not implicated.**—There is nothing of special importance in these cases, the treatment following the lines for ordinary wounds. The main essentials are the arrest of bleeding, and the disinfection and proper suture of the wound. The bleeding is usually very slight when the air-passages are not opened, because the incision does not extend deeply. Sometimes however, when the attempt has been made with a sharp-pointed knife thrust deeply into the neck to begin with, there may be serious hæmorrhage; under such circumstances, if the patient be still alive when the surgeon sees the case, the first thing to be done is naturally to apply firm digital pressure to the bleeding point. The best way to do this is to thrust the thumb firmly into the wound and, placing the fingers and palm of the hand over the back of the neck, to press strongly backwards. The wound is then enlarged or its edges retracted and all blood-clot is removed. Should the bleeding be satisfactorily arrested by the temporary digital pressure, the next step is to wash the wound out thoroughly with 1-20 carbolic lotion and disinfect it in the ordinary manner. Then, if the bleeding comes from some of the smaller vessels, these can be seized and tied; if one of the larger trunks be injured, it will be necessary to extend the incision upwards and downwards over its course, to divide the deep fascia, separate the parts freely and have the wound well retracted. The surgeon then transfers the duty of compressing the bleeding vessel to his assistant, who

applies pressure above and below the opening, and the injury to the vessels can be examined and dealt with in the ordinary way. This will usually take the form of ligature above and below the seat of injury.

It is quite likely that it will be necessary to make use of an infusion of saline solution, as the amount of blood lost may be very great. Should this be the case, the infusion should be carried out immediately after the surgeon is satisfied that the compression of the bleeding spot is effectual and before he proceeds any further. The salt solution should be introduced through one of the veins of the arm in the usual manner (see Part I., p. 136), and as soon as the cannula has been tied into the vein and the infusion started, its administration should be taken over by an assistant or a nurse, whilst the surgeon busies himself with disinfecting the wound and arranging for the permanent arrest of the bleeding. When the vessels are tied, the condition of the nerves must be investigated and, if any be found divided, they should be sutured if possible. If the base of the epiglottis has been cut across it should be fastened in position by two or three catgut stitches. The soft tissues connecting the hyoid bone and thyroid cartilages should then be sutured as accurately as possible, or, when the incision is higher up, the muscles of the base of the tongue must be united; in most cases a drainage tube will be unnecessary, as the wound is clean-cut.

**2. When the air-passages are involved.**—The following four points have to be considered:—(1) The arrest of hæmorrhage; (2) the prevention of asphyxia; (3) the treatment of the opening into the air-passages; and (4) the measures to be taken for avoiding subsequent complications, particularly cellulitis and broncho-pneumonia.

When the patient is first seen the two most urgent points to be attended to are the *arrest of hæmorrhage and the prevention of asphyxia*. If there

be embarrassment of respiration, either from the passage of blood down the air-passages or obstruction to the laryngeal aperture by the tongue, the first thing is to apply firm sponge pressure to the wound so as to arrest the bleeding temporarily, and then rapidly to open the trachea. As soon as this is done, the patient's head should be lowered, and the opening in the trachea held wide apart so as to facilitate the escape of blood: this may be further aided by

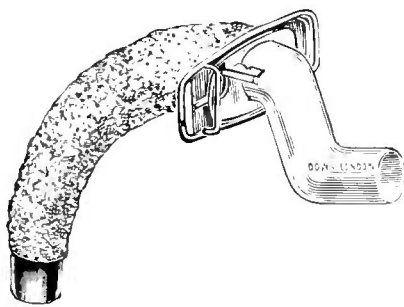


FIG. 80.—HAHN'S CANNULA. The method of preparing this for use is described on p. 260. The chloroform apparatus shown in Fig. 81 can be attached to this tube also.

tickling the trachea with a feather. When the clots have been coughed up, the tracheotomy tube should be introduced, and this should be a Hahn's (see Fig. 80) or a Trendelenburg's tube (see Fig. 81), if one be at hand, so as to shut off the air passages and prevent the further escape of blood into them, whilst the surgeon is attending to the wound higher

up. Should neither of these tubes be at hand, the same result may be obtained by packing the trachea firmly above the tube either with a small sponge attached to a silk thread or with a strip of gauze. Should the latter material be used, care must be taken to see that it cannot be sucked into the trachea, and a long strip should therefore be used, one end of which is left hanging well out of the wound. As an additional precaution it is well to tie a long silk thread to this so that, should it slip in, it can easily be pulled up, as it is not at all uncommon for it to be gradually sucked past the tube in the violent attempts at respiration.

The surgeon's attention is next directed to the arrest of the hæmorrhage. This should be done in the usual manner, and what has already been said with reference to wounds not implicating the air passages applies equally here (see p. 239). In disinfecting the wound, particular care must be taken to see that none of the strong disinfectants run into the trachea.

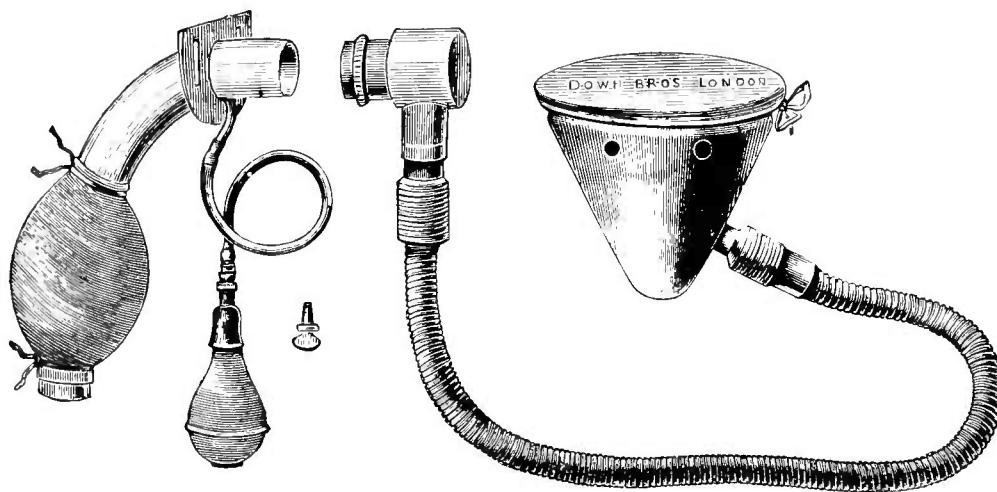


FIG. 81.—TRENDELENBURG'S TAMPON CANNULA. The cannula with its inflating end is seen at the left side of the figure, on the right is the chloroform apparatus referred to on p. 260.

The next point is *the treatment of the wound in the air-passages*. When tracheotomy has been performed there need be no hesitation at all about closing this entirely.

When the incision runs through the larynx itself, the cartilages are united by catgut sutures, and a careful examination must always be made to see whether the vocal cords have been injured: if so, the divided structures must be carefully sutured. When the trachea is divided, one or two stitches usually suffice to maintain the edges in apposition; should the tube be completely divided, three stout stitches, one central, and one on either side, should be employed to fix the two halves together, and a few finer stitches in between will complete the apposition.

After the opening into the air-passages or the pharynx has been completely shut off, the divided structures in the neck are sutured together layer by layer and the skin wound is closed, a drainage tube being inserted at one angle of the wound, as its asepticity cannot be guaranteed.

When a tracheotomy has not been done, the question of the feasibility of completely closing the opening into the air-passages is not so simple, and will depend largely upon the nature of the injury. Should this be extensive and should the wound be closed in the manner just described, considerable emphysema is likely to occur and in addition there may be œdema of the glottis or even hæmorrhage into the larynx causing considerable embarrassment to respiration; septic pneumonia is also likely to follow. Hence, with very few exceptions, we strongly recommend that tracheotomy should be done in all cases of cut throat, a tube introduced and, for the first few hours at any rate, the communication between the larynx and the trachea cut off, either by the employment of one of the special tubes mentioned (see p. 238) or by packing with gauze. When this is done, the wound in the air-passages may be closed without hesitation. The use of the tracheotomy tube is still more important when the superior laryngeal nerve has been wounded, because the resulting anæsthesia of the glottis hinders the patient from coughing, and food or septic discharges may pass into the air-passages and give rise to a very fatal form of pneumonia. In these cases a Hahn's or Trendelenburg's tube should be used until healing has occurred, and should be changed twice daily.

The wound is dressed in the usual manner and it is advisable at the end of the operation to employ an infusion of saline solution, followed if necessary by subcutaneous injections of strychnine and digitaline (see Part I., p. 140) to combat the shock, which is often profound and is due partly to the injury, partly to the loss of blood, and partly to the patient's general enfeebled condition before the attempt at suicide.

*After-treatment.*—The patient should be put to bed with the head bent well forward on to the sternum, so as to take off all tension from the wound. The head may be flexed by a large firm pillow beneath it and prevented from rotating by sandbags on each side. In addition, if the patient be restless, a firm bandage may be applied around the head, from the front of which long strips pass down to be fastened to the foot or sides of the bed. For the first few hours at any rate it is advisable to tie the patient's hands to the sides of the bed, and the case must be watched night and day to restrain the restlessness and particularly to see that the patient does not tear off the bandages. The bed should be surrounded with a tent containing a steam-kettle, to the vapour of which terebene or eucalyptus is added. The use of a steam-kettle however is open to much discussion, a good many surgeons considering that these cases do better without it. In any case, a thin layer of gauze wrung out of warm water and sprinkled with terebene should be placed over the orifice of the tracheotomy tube and fresh terebene or eucalyptus oil should be dropped on it from time to time so as to keep up a constant antiseptic inhalation.

The administration of some sedative, such as bromide of potassium and chloral, or if this fail, the hypodermic injection of hyoscine hydrobromide (gr.  $\frac{1}{50}$ ) is generally necessary on account of the patient's

restlessness; morphine as a rule is objectionable as it increases rather than diminishes this. As much nourishing food as possible should be given and, unless the patient be extremely weakly, it is well for the first few days to confine its administration to the rectum, enemata containing half an ounce of brandy and two ounces of peptonised meat juice being given alternately with zymised suppositories at two-hourly intervals. As the patient begins to recover, food may be administered by the mouth, but the question whether this may be given in the ordinary way or whether a stomach tube should be used will depend very largely upon the conditions present. When the superior laryngeal nerve has been injured, or when there is extensive damage about the base of the tongue, feeding should always be carried out through a stomach tube and great care must be taken to see that the tube does not pass into the larynx. Should there be any doubt on the point, as there may be when no tracheotomy tube has been used, it is well to run a few drops of boracic lotion through the tube after its introduction and before food is given; should the tube be in the air passages, cough will be at once excited, and no harm will be done by the introduction of the boracic lotion.

**3. Of complications.**—*Septic pneumonia*.—Once this affection has set in, the chances of doing any good are very slight indeed, but the treatment should be conducted on medical lines, and will consist mainly in the administration of concentrated and nutritious food and free stimulation by alcohol, ether, strychnine, etc. The patient should be propped up into the sitting position and large jacket-poultices applied to the affected side of the chest.

*Cellulitis of the neck*.—Free incisions must be made wherever necessary, but care should be taken in planning them and in arranging the dressing to prevent as far as possible any entrance of septic material into the air passages.

The treatment of the other sequelæ, such as aërial fistula, stenosis of the larynx, etc., will be subsequently referred to.

## CHAPTER XXII.

### FOREIGN BODIES IN THE AIR PASSAGES.

FOREIGN bodies may cause either dyspnœa or actual asphyxia, whether they lodge in the pharynx about the upper aperture of the larynx, or whether they enter the air passages proper.

#### FOREIGN BODIES IN THE PHARYNX.

Foreign bodies lodging in the pharynx must of course be of large size, and usually consist of masses of food either swallowed or vomited, tooth-plates, etc. These interfere with respiration mechanically and a sudden and fatal asphyxia may result unless prompt and effectual treatment be adopted.

**Treatment.**—In all cases in which the patient is suddenly attacked by asphyxia, either during eating or after vomiting, the first thing is to force open the jaws; this may be done, if no gag be at hand, by introducing the handle of a knife, a spoon, or any other convenient article, between the teeth and levering the jaws apart. The finger is then pushed well back into the pharynx and swept round the orifice of the larynx in search of the foreign body causing the obstruction. If the foreign body be outside the air passages proper, it can generally either be pulled up with the finger or pushed down into the œsophagus. When the source of obstruction is a tooth-plate, however, it may not be easy to dislodge it, and in that case recourse must be had to immediate laryngotomy (see p. 234) to save the patient's life. After that has been done and a tube introduced, further efforts should be made at once to remove the foreign body. As a rule the patient will begin to breathe directly the laryngotomy is done, but when this is not the case, artificial respiration should be commenced and the surgeon should then proceed to extract the foreign body. This should be done with forceps bent at a right angle and guided by a frontal

mirror if the circumstances permit. When the foreign body is a tooth-plate, the chief obstacles to removal are the sharp hooks projecting from it which catch in the tissues: these may be so firmly impacted that it is necessary to break up the plate with cutting forceps before it can be extracted. As soon as this has been done and the natural breathing has been restored, the laryngotomy tube may be taken out and the wound allowed to heal. No stitches should be inserted as otherwise emphysema is likely to occur.

#### FOREIGN BODIES IN THE LARYNX AND TRACHEA.

Foreign bodies may enter the larynx from some sudden inspiration during swallowing, such as is caused by laughing or talking whilst eating. Sometimes the accident may occur during sleep. Artificial teeth are the most common foreign bodies in adults: buttons, sweets, fruit stones, and small toys in children. Sometimes the material entering the larynx may come from the stomach, as for example when vomiting occurs when a patient is drunk or under an anæsthetic.

**Symptoms.**—A large foreign body may completely obstruct respiration and give rise to most urgent dyspnœa calling for immediate tracheotomy, the removal of the foreign body being carried out subsequently. In any case its impact in the larynx excites sudden pain, violent cough and a fit of choking accompanied by intense terror. A fatal result may ensue, not only when the body is large enough to block the larynx completely, but also when it is not, as a result of the acute spasm it gives rise to. Should the spasm not be immediately fatal, it subsides after a time and the body may then be retained in the larynx, the trachea or the bronchi and produce very few symptoms, of which the chief are a slight cough and a sense of discomfort. This may continue for a very long period, but as long as the foreign body remains in the air passages the patient is in constant danger of spasm of the glottis should it alter its position.

A smooth, rounded body lodged in the ventricle of the larynx may give rise to no symptoms after the initial convulsive attack has passed off, but a sudden suffocative attack should always excite the suspicion of a foreign body, especially in children, even when no definite history can be obtained. If the body be sharp, it may cause hæmorrhage, and the blood in the air passages may cause severe dyspnœa. In other cases inflammatory swelling occurs in the course of a few days, with increasing dyspnœa.

In other cases again, a small body, such as a button or a fruit-stone, may pass into the trachea, in which it may remain freely movable, or it may be drawn onwards and impacted in one of the bronchi, usually the right, the opening of which is larger and in a more direct line with the trachea. When the body is movable in the trachea, the patient, after the

first spasm has passed off, can breathe fairly freely as long as he remains quiet, although respiration is usually somewhat noisy and rattling. As soon, however, as he exerts himself or coughs, the foreign body is driven up against the glottis and sets up fresh spasm. This condition is not common however as, if the body be small enough to pass into the trachea, it generally becomes impacted in a bronchus which it blocks either partially or completely according to its shape and size. If, however, the body be sharp, it may become impacted in the trachea; in one case in which we operated a piece of bone had remained there for years, giving rise to stenosis which had been looked upon as syphilitic.

A foreign body impacted in a bronchus generally causes partial or entire collapse of the corresponding lung. It acts as a ball-valve, preventing air entering on inspiration, but allowing a certain amount to escape on expiration until the collapse becomes complete. A foreign body thus impacted gives rise to inflammation in the bronchus around it, whilst the collapsed portion of the lung is very likely to become the seat of pneumonia. The inflammation around the foreign body may gradually loosen it, and after some days a recurrence of the laryngeal spasm may indicate that it is again loose and has been projected up against the glottis. In other cases again an abscess may form and may burst into the trachea, so that the patient coughs up large quantities of pus, or it may burst into the pleura, when it is followed by empyema, or into the mediastinum, in which case it may give rise to fatal cellulitis.

**Treatment.**—Any foreign body, whether it gives rise to immediate serious symptoms or whether it has become impacted and is accompanied by less serious symptoms, should invariably be removed if possible. The methods of removing it vary of course with the nature of the foreign body, with its situation and with the symptoms it produces.

**(a) Of foreign bodies in the larynx.**—Whenever there is urgent dyspnoea, and particularly in children, tracheotomy should be performed as soon as the case is seen. In adults, if there be no marked dyspnoea and if the patient be tolerant of intra-laryngeal manipulations, an attempt may be made to remove the foreign body with forceps, if it can be seen on laryngoscopic examination. The pharynx and larynx are thoroughly anaesthetised by spraying with cocaine and brushing the aperture of the glottis over with the drug, and then the situation and character of the body are ascertained by a laryngoscope. Suitable laryngeal forceps, guided by a laryngoscopic mirror, may then be introduced and the body extracted as gently as possible. In children an attempt may be made to extract the body with forceps guided to the larynx by the finger, but in them it will usually be safer to perform a preliminary high tracheotomy (see p. 248).

In all cases where the above methods fail, or where they cannot be employed owing to the situation or the nature of the foreign body, thyrotomy should be performed; indeed, in the majority of cases calling for tracheotomy,



it is better to continue the operation and perform a partial thyrotomy so as to remove the foreign body immediately. For this purpose, when the trachea has been opened, a Hahn's cannula should be introduced, or the packing above described (see p. 239) should be inserted above an ordinary tracheotomy tube. The incision is then extended vertically upwards, the cricoid cartilage is split in the middle line together with as much of the thyroid cartilage as may be necessary for free inspection of the interior of the larynx. It is of course highly desirable to avoid splitting the thyroid cartilage completely, so as not to risk any disturbance of the vocal cords. When the thyrotomy has been done, a smooth foreign body can usually be pushed up from below into the pharynx; failing this, it may be grasped with forceps which are then pushed up into the pharynx and the foreign body is seized from the mouth. Unless the body be very small, there is a risk of lacerating the vocal cords if attempts be made to pull it downwards through the glottis. When the foreign body is angular and its removal therefore is likely to lead to laceration of the parts above the cords, as for example an artificial tooth fixed with a hook, it is essential to split the thyroid cartilage completely.

After the body has been extracted, the edges of the cartilages should be accurately united and the wound closed above the tracheotomy tube. Should the thyroid cartilage be only partially divided, its accurate closure is quite simple. Should it be necessary to split it entirely, it is well before doing so to make a superficial transverse incision across the front of the cartilage, so as to provide a guide for its accurate adaptation when its two halves are afterwards brought together. The tracheotomy tube should be left in for two or three days until all danger of œdema of the glottis has passed off.

**(b) Of foreign bodies in the trachea.**—When the foreign body is in the trachea, immediate tracheotomy should be performed; when the body is loose a high tracheotomy will suffice. The opening should however be free enough to permit the body to escape easily. The best procedure is to insert a sharp hook on each side of the middle line through the trachea before it is opened (see p. 249). The incision is then made and the hooks are pulled upwards and outwards on each side; the trachea is thus fixed and the incision into it widely dilated. When this is done, the surgeon should be on the alert to catch the foreign body should it be projected upwards opposite the incision. It has more than once happened that the foreign body has thus shown itself, but, the opening not being sufficiently free to enable it to escape, it has been sucked back and become impacted in the bronchus. As a rule, if the body be small and the trachea be sufficiently freely opened, it is at once shot out; should this not happen, the patient should be inverted and shaken, or coughing may be induced by tickling the interior of the trachea with a feather. Should this not be immediately successful, Golding Bird's trachea dilator (see Fig. 82) should be introduced and kept in position for

some little time so as to keep the lips of the incision widely apart, in the hope that the body may be coughed up.

**(c) Of foreign bodies in the bronchus.**—Should the foreign body be evidently impacted in the bronchus, immediate steps should be taken to remove it. This should if possible be done at the time the tracheotomy is performed. The situation of the body may often be detected by means of a long probe, and attempts may be made to gently insinuate the blades of a long, fine pair of forceps between it and the wall of the bronchus. Sometimes a probe bent into a hook insinuated past it may succeed in dislodging the body, which is then expelled through the tracheotomy opening. In some cases removal may be facilitated by extending the incision into the trachea downwards through the isthmus of the thyroid as low as possible; it is always well to do this before abandoning the operation, in cases seen immediately after impaction.

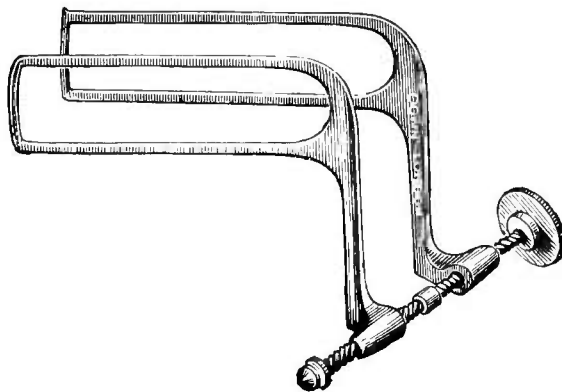


FIG. 82.—GOLDING-BIRD'S TRACHEAL DILATOR.

When it is found quite impossible to displace the foreign body, the case may be left alone for some time in the hope that the inflammatory process going on around it may cause it to become loosened, a large tracheotomy tube being meanwhile introduced into the wound.

The foreign body may be situated so low down that it evidently cannot be removed through a tracheotomy opening (as may be shown by a radiograph) and attempts have been made to remove it by incisions through the thoracic wall. When it is impacted fairly high up, a portion of the sternum has been removed or this bone has been split and the two halves pulled asunder so that the bronchus can be opened from the front. Attempts have also been made to get at the body from behind after resecting portions of the ribs, but these have usually failed.

In some cases empyema has resulted, the pus in the pleural cavity communicating with the foreign body in the bronchus; should this be the case, attempts may be made, after resection of one or more ribs, to reach the foreign body from the outside of the chest. We have had a very satisfactory case of this kind in which a boot-button was extracted

from the left bronchus through the chest wall. The great drawback however here is the difficulty in getting the sinus in the chest wall to heal, as the aperture in the skin communicates directly with one of the larger bronchial tubes ; all attempts may fail even after a most extensive resection of ribs. These cases will be dealt with again in connection with the surgery of the chest.

## CHAPTER XXIII.

### THE OPERATIONS UPON THE LARYNX AND TRACHEA.

#### TRACHEOTOMY.

THE trachea may be opened either above or below the isthmus of the thyroid, which usually lies over the third and fourth rings of the trachea; the operation is consequently spoken of as the high or the low form according to the situation of the opening relative to this structure. In practice, however, there is no strict line of demarcation between the two forms of operation, because it is often necessary to divide the thyroid isthmus partially or even completely. The operation in most frequent use is the high tracheotomy, because the trachea is here more accessible, the operation is less likely to damage important structures and can be more rapidly done; there is also less likelihood of septic cellulitis spreading from the wound into the anterior mediastinum. When however the operation is done in order to reach a foreign body lodged in the bronchus, the low operation is to be preferred as it enables the body to be reached more easily.

When it is necessary to perform a preliminary tracheotomy for the insertion of a Hahn's cannula, as in various mouth operations, it is usually best to divide the thyroid isthmus partially or entirely, and this should always be done in a preliminary tracheotomy for complete or partial excision of the larynx.

**HIGH TRACHEOTOMY.**—The patient should be in a good light with a firm sandbag beneath the neck so as to project the trachea well forward. If an anæsthetic be given, it should be administered very slowly so as to avoid the risk of increasing the dyspnœa. Standing on the right of the patient, the surgeon grasps the thyroid cartilage between the thumb and middle finger of the left hand, while the index is placed upon the thyroid notch so as to steady the trachea and to indicate the middle line. Then, taking care that the chin, the thyroid notch and the sternum are in the same straight line, a vertical incision in the middle line is commenced over the crico-thyroid membrane and carried down well below

the level of the thyroid isthmus. The crico-thyroid membrane can easily be identified in all cases and the incision will generally be about two inches long. It is carried through skin and fascia until the interval between the muscles running from the larynx to the sternum is exposed. The handle of the knife, aided by a few touches of its point, will suffice to separate these muscles, which are then carefully retracted to an equal extent on the two sides. In separating the muscles, care should be taken to avoid puncturing the anterior jugular veins in the upper part of the incision. These are often much dilated if there be much dyspnoea, and the transverse jugular branch joining them generally has to be divided. The best plan is to seize it in two pairs of forceps before it is divided and to tie it as soon as possible. When the muscles are well retracted, the isthmus of the thyroid and the trachea covered by the deep layer of cervical fascia come into view. A transverse incision should now be made along the lower border of the cricoid cartilage, curving somewhat downwards at each extremity so as to detach the fascia running from that structure to the isthmus of the thyroid, and the latter is then pushed well out of the way by stripping down the fascia with the handle of the knife. This is a better plan than making a median incision through the fascia, and should always be done when time allows, as it saves oozing that is very frequently extremely troublesome. A double hook-retractor is now used to pull the isthmus of the thyroid firmly downwards and to steady the trachea, whilst a sharp hook is introduced through the trachea on each side of the middle line, its point passing through the membrane below one of the rings and emerging through the membrane above the same ring; these hooks are given to an assistant to hold and the trachea is thereby steadied. The knife is now inserted with its cutting edge upwards just below the second ring of the trachea and made to divide this structure vertically in the middle line as far upwards as the cricoid; immediately the opening is made, its edges are pulled apart by means of the sharp hooks.

When there is no urgency about the operation, as will be the case when a preliminary tracheotomy is required before certain mouth and throat operations, etc., it is well to arrest all bleeding before the trachea is opened. When however it is done for urgent dyspnoea, no attention need be paid to the bleeding until the trachea is opened and a tube has been introduced. In these cases the venous oozing is often extremely free and practically uncontrollable from the great congestion of the parts, but it will stop almost immediately the trachea is opened and free respiration is established.

*Tracheotomy tubes.*—Various forms of tracheotomy tubes are employed, of which the best are Parker's (see Fig. 83) or Durham's lobster-tailed tube (see Fig. 84). Parker's is more suitable for children, while Durham's is best for adults, especially when the low operation is employed, as here Parker's may not be long enough to reach comfortably into the trachea. The older tubes made in the form of a segment of a circle are bad,

because the lower end of the tube is apt to press upon the anterior wall of the trachea and cause severe ulceration, while at the same time its

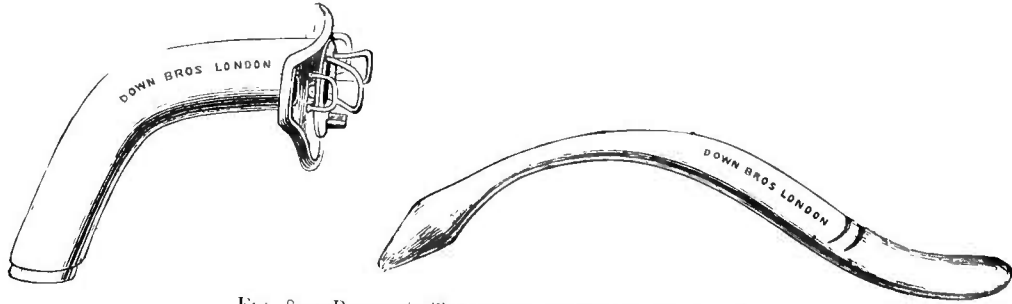


FIG. 83.—PARKER'S TRACHEOTOMY TUBE AND PILOT.

long axis does not coincide with that of the trachea. The bivalve tube (see Fig. 85) is bad for permanent use as its sharp edges may cause

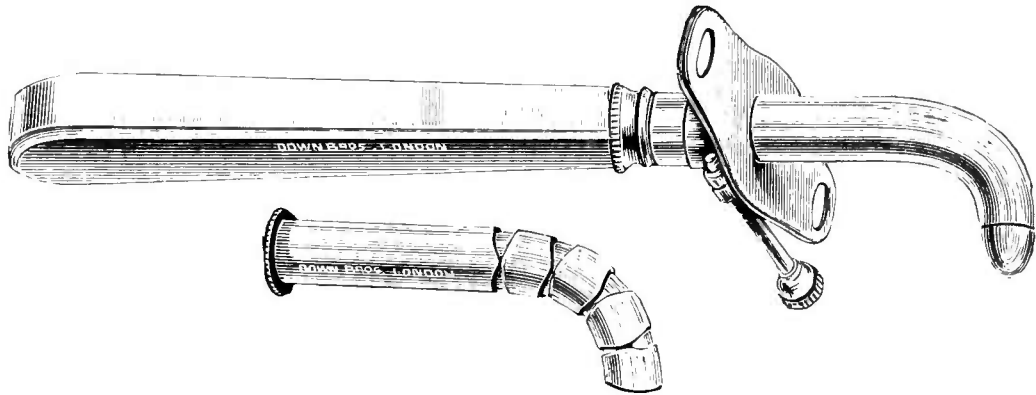


FIG. 84.—DURHAM'S LOBSTER-TAIL TRACHEOTOMY TUBE, with Pilot and inner tube.

ulceration of the posterior wall of the trachea, but it is a very valuable emergency tube as it occupies a very small compass and can be readily introduced.

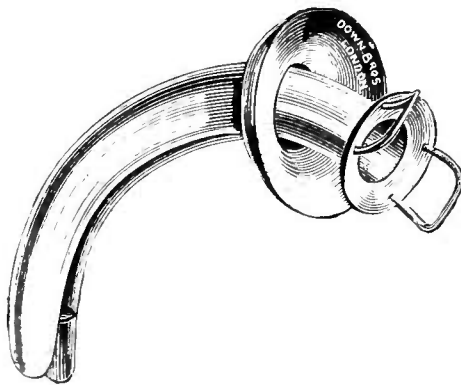


FIG. 85.—FULLER'S BIVALVE CANNULA AND INNER TUBE.

The introduction of the tube in the high operation is perfectly easy if the sharp hooks have been employed as described above to steady the

trachea. When they are not at hand, the trachea should be fixed as firmly as possible with the fingers whilst it is being opened, and, immediately this is done, the nail of the forefinger of the left hand is slipped in between the edges of the incision and made to depress one side over which the tube can be slipped into the trachea.

When the tube has been introduced, care must be taken to see that air passes freely through it, as in fat patients in whom the trachea is deeply seated, it is easy to force the tube down in front of or to one side of the trachea. It is in these cases that a Durham's tube is particularly valuable as the thickness of the soft parts over the trachea may be easily allowed for by altering the position of the shield. The tube before introduction should be threaded with tapes which are passed round the neck and tied together at some little distance from the edge of the wound so that the knot does not interfere with the wound or press upon the vessels. Care must be taken to see that it is not tied sufficiently tightly to embarrass the venous circulation. After the tube has been inserted, one or two silk-worm-gut stitches are introduced into the wound above and below the opening so as to close the greater part of the incision.

The best dressing is a large piece of boracic lint spread thickly with boracic ointment and slit vertically through half its depth so that it can be drawn up on each side of the tube. A few layers of gauze wrung out of hot water, and sprinkled with a little terebene, should be applied over the orifice of the tube; this should be changed every half-hour or so and kept moistened with hot water and terebene. The inner tube should be removed two or three times a day and thoroughly washed; should obstruction arise, it must be removed immediately and thoroughly cleaned out. A special nurse must be employed night and day to see that the tube works satisfactorily and it is important that all material coughed up through the tube should be wiped away immediately with a fresh piece of gauze, so that it does not get sucked back into the trachea. Should the trachea not be thoroughly emptied, it is well to excite coughing occasionally by tickling the interior of the trachea with a fine feather introduced through the tube. These feathers should be boiled first so as to disinfect them, as otherwise they may introduce septic material; they should be kept in boracic lotion, which is squeezed out before the feather is introduced into the trachea. Unless an obstruction occurs which cannot be remedied by the mere removal of the inner tube, the outer tube should be left in position for the first 24 or 36 hours, after which it should be removed once or even twice a day if there be much discharge. A fresh tube should always be at hand to be immediately introduced on the removal of the old one, which should be thoroughly cleaned in cold water, boiled, and kept in boracic lotion until required.

The subsequent management of the tube varies according to the condition for which the operation is done. The point of chief importance is the time at which the tube can be left out. It is obvious that this should

be done as soon as it is safe, as the irritation caused by a foreign body in the trachea is harmful. When the tracheotomy is done for laryngeal stenosis, or for cancer in which no radical operation can be performed, the tube of course must be retained permanently, but in other cases it is merely a temporary expedient. When the tracheotomy has been done for the removal of a foreign body which has been successfully extracted, the tube should only be kept in for a few hours. It should not be removed at once as otherwise emphysema from the imperfect escape of air through the external wound is likely to occur; after a few hours the tissues become sufficiently glazed to render that improbable. In cases of diphtheria, especially in children, the tube should not be kept in longer than is absolutely necessary, as otherwise there may be great difficulty in leaving it out, for children rapidly lose the habit of breathing through the larynx;



FIG. 85.—MARRANT BAKER'S INDIA-RUBBER TUBE.

moreover, granulation may occur in the upper part of the trachea and cause more or less complete blockage. The factor that will mainly influence the question of the removal of the tube in these cases is the amount of discharge coughed up; as long as membrane and thick mucus are being expelled, the silver instrument must be retained and the inner tube frequently changed; as soon, however, as it becomes thin and watery, but is present in sufficient quantity to render it impossible to dispense with the tube

entirely, the soft rubber form known as Marrant Baker's (see Fig. 86) should be substituted. This is soft and flexible, and is therefore not nearly so irritating or so likely to produce ulceration of the trachea. The prolonged retention of a silver tube, especially if it does not fit perfectly, is a frequent cause of severe ulceration of the wall of the trachea and necrosis of the cartilages; in some cases either a peri-oesophageal abscess or a direct communication with the oesophagus itself may form. The india-rubber tube should never be used from the first, as, owing to its softness, it may become occluded by the lateral pressure of the muscles of the neck, and it should therefore only be employed after the opening has become fairly rigid. In employing the rubber tube care must also be taken to see that it is properly made, as it has happened that the shield has become detached and the tube has slipped into the trachea. Should this happen, it is usually fairly easy to introduce forceps into the trachea, grasp the tube, and gradually withdraw it. When the india rubber tube is used, a large hole should be cut in its upper convex surface, so that a certain amount of air passes through the larynx as well as through the



tracheotomy opening, and frequent attempts should be made by closing the latter to accustom the child to breathe normally through the larynx. When it is found that the child can breathe freely after the external aperture has been plugged, cautious attempts should be made to leave out the tube. In the first instance this must only be done when the surgeon or his assistant is present, as spasm is very likely to occur in nervous children from the mere thought that they are without the tube; this may necessitate its immediate re-introduction. In any case the tube should not be left out for more than half an hour or so on the first occasion. Each succeeding period may be gradually lengthened until in the course of about a week it may often be given up altogether. Should the child persistently get spasm after the tube is removed, although it is obvious that there is a free passage through the larynx, it may be quite sufficient to restore confidence by shortening the tube so much that the child wears little more than a shield, behind which cicatrisation of the wound can take place. Another method of encouraging the use of laryngeal breathing is to incite the child to blow out a light, blow a whistle, play a musical instrument, etc.

The question of the general treatment of the patient need not be considered here; that will of course depend upon the condition for which the tracheotomy is done.

**THE LOW OPERATION.**—This is usually performed when there is no great hurry in opening the trachea, and where therefore the bleeding can be properly controlled as it is met with; as a rule, however, the hæmorrhage is not so free as in the high operation. The preparation of the patient, etc., is the same as before, and the incision should commence at the lower border of the cricoid cartilage and be carried down through the skin as far as the sternal notch. As the wound is deepened, however, care must be taken not to go too deep at the lower part because the left innominate vein, if distended, may bulge up close behind the sternal notch and may be wounded; the anterior jugular vein may require ligature. In this operation the deep cervical fascia is divided vertically from the lower border of the isthmus of the thyroid, and it is well to notch it slightly by a transverse incision above; the isthmus of the thyroid can be then pulled well up by a double hook. The trachea is fixed and opened in the same manner as in the high operation.

**Difficulties in tracheotomy.**—There are several difficulties requiring mention in the operation of tracheotomy. In the first place *the trachea may be missed entirely*, especially in a small, fat child, and the operator in seeking for it has been known to do serious damage to important structures in the neck. This is best avoided by taking care before the operation that the chin and sternum are in the same straight line, and that the incisions are kept strictly to the middle line throughout. The finding of the trachea is further facilitated by steadying the larynx between the thumb and finger, in the manner recommended above, until the trachea is opened, and the surgeon,

however much time may be of importance, should not be flurried in the performance of the operation.

A cause of great embarrassment to inexperienced operators is the *hæmorrhage* which may occur in urgent cases, and it is well to remember that, however free it may appear to be, it is almost entirely venous and is due to the great congestion of the veins from the obstruction to respiration. The operator should therefore not stop to attempt to arrest it, for, as soon as the opening into the trachea is made and respiration is freely established, the veins collapse and serious bleeding ceases. If, after the trachea is opened, the bleeding should continue, the operator will then have plenty of time to retract the edges of the wound and clamp the bleeding points. A very good plan in urgent cases is to turn the child over upon the face immediately the trachea has been opened, so that the blood finds its way externally and not into the lungs. After the child has been in this position for some time and respiration has become normal, the hæmorrhage is reduced to a minimum, and can be easily stopped by sponge pressure or by clamping one or two small bleeding points.

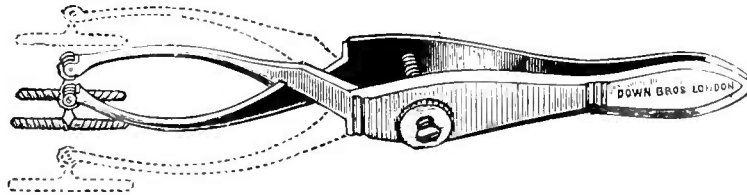


FIG. 87.—PARKER'S AUTOMATIC TRACHEAL DILATOR.

Another thing that sometimes alarms the young operator is that *the child ceases breathing immediately the trachea is opened*. In most cases this is due to the fact that the patient takes an abnormally deep breath and fills the lungs directly the opening is made, so that there is no immediate need for breathing. If the child be left alone, natural respiration will commence in a few moments, and there is hardly ever need for artificial respiration.

Another point of the greatest practical importance is that *the introduction of a tube may not establish free respiration*. This may be either because the tube is not in the trachea or, if it be in proper position, because it is blocked by membrane which has been pushed down in front of it. Another possible cause is that the tube is of wrong shape, so that its end impinges against one of the walls of the trachea and thus becomes occluded. The best means of avoiding blocking of the tube by membrane is to hold the lips of the incision widely open for some little time, either by the sharp hooks mentioned above or by introducing some form of dilator, such as Golding Bird's (see Fig. 82) or Parker's (see Fig. 87), and clearing the trachea with a feather, which both mechanically removes membrane and excites coughing, by which it can be expelled.

More serious cases are sometimes met with in which *the membrane has spread down to the bifurcation of the trachea*, and is very difficult to remove.

Under these circumstances it may be necessary to have recourse to a tracheal aspirator, of which that introduced by Mr. Parker (see Fig. 88) is the best. This consists of a catheter connected by an india-rubber tube with a small glass vessel into which some cotton-wool is introduced so as to prevent the possibility of membrane or mucus from the trachea entering the surgeon's mouth as it is sucked out.

There may sometimes be considerable *difficulty in the introduction of the cannula*. This is generally due to the opening in the trachea being made too small, and it is further increased if the patient happens to have a short, fat neck, so that the trachea is situated very deeply. Clumsy attempts at introducing a cannula through an insufficient opening may cause serious damage to the structures of the neck as the tube may be forced down either in front of or to one side of the trachea, and this may be followed by the most serious septic complications. Therefore,

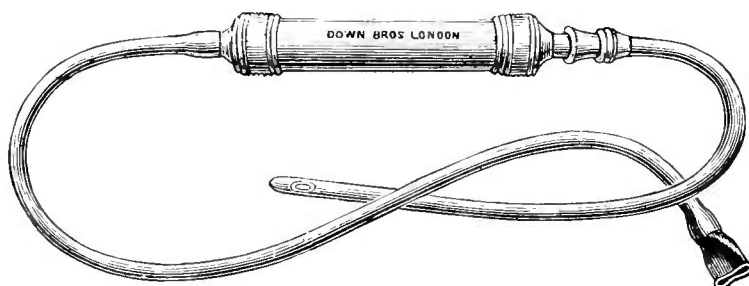


FIG. 88.—PARKER'S TRACHEAL ASPIRATOR. The glass cylinder is filled loosely with cotton-wool.

before opening the trachea, the surgeon should bear clearly in mind the size of the tube he is about to employ, and should always make the incision free enough to enable it to be introduced without any difficulty. The use of the sharp hooks above recommended (see p. 249) enormously facilitates this procedure, and with them it is almost impossible to go wrong. Should they not be at hand, the manœuvre of depressing one edge of the incision into the trachea with the finger-nail and slipping the tube over it (see p. 251) will suffice. In inserting the tube it should first be held with its long axis at right angles to the long axis of the neck until the point is well within the trachea; it is then rotated round through a quarter of a circle until its long axis coincides with the long axis of the body and its introduction is completed.

**Complications.**—There are very few complications following this operation, most of the difficulties arising during the progress of the operation itself.

*Hæmorrhage* does not occur as a rule if care has been taken to ligature all bleeding vessels before the child is put back to bed, but it may sometimes occur in the later stages from ulceration of the trachea due to a badly-fitting tube, or from free oozing from the granulations about the orifice. The best method of meeting this is either to dispense with the tube entirely or to substitute the india-rubber one (see p. 252) as soon as possible.

*Cellulitis of the neck* may sometimes occur from infection of the wound from the tracheotomy opening. This condition is of course most serious and must be treated on the ordinary principles, namely, free incisions followed by large boracic fomentations frequently repeated. The great risk is that the affection may spread into the anterior mediastinum and end fatally.

*Emphysema* is rare when a tube is employed.

Tracheotomy may be called for to relieve urgent dyspnoea in diphtheria, acute laryngitis, œdema or stenosis of the glottis, etc. We may add here some remarks with regard to certain points in the operation when it is done for diphtheria.

**Tracheotomy for diphtheria.**—Chloroform is the best anæsthetic to use. Some surgeons hold that an anæsthetic had better not be employed, but we are of opinion that it is of great advantage so long as there is entry of air through the larynx. It is mainly needed for the skin incision and it prevents struggling and therefore further embarrassment of the respiration and consequently less troublesome hæmorrhage. Should it be deemed advisable to operate without an anæsthetic, the child should be rolled up in a large towel or sheet so as to confine the arms to the sides, the legs should be fastened to the foot of the table, and an assistant, whose duty it is to retract the wound, etc., should sit at the head of the table and fix the patient's head immovably between his elbows and fore-arms as he holds the retractors. As soon as the trachea is opened, the patient generally gives a violent cough, and large quantities of mucus and membrane may be expelled. The operator and his assistants must remember the risk of infection under these circumstances, and must not therefore be bending over the patient when the trachea is opened. A piece of moist gauze should always be ready to throw over the wound as soon as the opening is made.

It is important not to introduce the tube directly the opening is made into the trachea, but to hold the edges of the latter aside with sharp hooks or a tracheal dilator, so as to allow free respiration and expulsion of as much diphtheritic membrane and mucus as possible. Indeed, if the child is quiet, it may be advisable to employ a tracheal dilator, such as Golding Bird's (see Fig. 82) in preference to a tracheotomy tube for as long as 24 hours.

When the membrane has extended below the tube, it is a good plan to spray alkaline solutions, such as bicarbonate of soda (10-15 grains to the oz.), or a saturated solution of biborate of soda, through it every hour or two in order to soften the tenacious mucus and allow the trachea to be more easily cleared. At the present day however, since the introduction of antitoxin, not only is tracheotomy much less frequently called for in this affection but there is not the same trouble in getting rid of the membrane.

## LARYNGOTOMY

When the air passages must be opened with the least possible delay for impending asphyxia not due to diphtheria, the most rapid plan is to perform a laryngotomy. The steps of this operation have already been fully described (see p. 234). If circumstances demand it, the operation can be done in a few seconds by plunging a knife transversely through the skin over the crico-thyroid membrane and passing along it the blades of a pair of dressing forceps, or, where these are not at hand, a hairpin, before it is removed.

The *after-treatment* of the case will of course depend on the cause of the obstruction. When it is necessary to employ a tube permanently it is better to perform a high tracheotomy and allow the laryngotomy wound to close.

## CHAPTER XXIV

### CANCER OF THE LARYNX.

EPITHELIOMA may arise primarily in the larynx or may spread to it from the surrounding parts, such as the pharynx or the base of the tongue. When it is primary in the larynx, it usually starts about the base of the epiglottis or in the neighbourhood of the cords. In the latter situation it is generally unilateral at first, but later on affects both sides. It infiltrates the sub-mucous tissue, attacks the cartilages and, if situated near the posterior part, it invades the arytenoids and affects the pharynx over which it spreads rapidly. As soon as it reaches the latter region or penetrates the cartilages, glandular infection is very rapid, but, as long as the disease remains limited to the larynx, the glands may be unaffected.

**Symptoms.**—These are often most distressing. There is first much hoarseness and cough, and, later on, dysphagia and excessive pain when the growth reaches the pharyngeal mucous membrane. Spasm and dyspnoea are common when one or both cords are implicated, and free hæmorrhage is not infrequent. The death of the patient is generally due to septic pneumonia, but may occur from weakness or from asphyxia due to blocking of the air passages by the growth or by hæmorrhage.

**Treatment.**—This must be either operative or palliative. The latter is fully dealt with elsewhere (see p. 440), and the cases suited for it indicated. Extirpation should be performed whenever it is possible; the exact operation will vary with the situation and extent of the tumour. Excluding the cases in which the disease has spread to the pharynx or only affects the larynx secondarily (which will be dealt with in connection with cancer of the pharynx), there is the choice of three procedures: (1) Thyrotomy and removal of the growth from the interior of the larynx; (2) partial laryngectomy, or removal of one half of the larynx; and (3) complete laryngectomy or removal of the entire structure. The dangers of these operations are essentially those of sepsis, viz. cellulitis, septic pneumonia or acute septicæmia, with the additional risk of blood getting into the trachea and either causing asphyxia or setting up pneumonia

subsequently. The danger of local sepsis, although it cannot be entirely avoided, may be minimised by adopting the preliminary precautions already recommended for all operations of this kind (see p. 214), and is still further guarded against by dividing the operation into two stages (*vide infra*). The dangers arising from the passage of blood into the trachea are avoided by the means described on p. 260.

*Preliminary tracheotomy.*—It is well in all cases to commence with a preliminary tracheotomy so as to block the communication between the larynx and the trachea. Some surgeons advocate that this should be done some days before the operation proper is proceeded with so that the patient may become accustomed to breathe through a tracheotomy tube and that he may be relieved of his laryngeal obstruction and may thus be in a better condition to stand the operation. It is further urged that the trachea becomes accustomed to the tube and there is thus less coughing and less risk of bronchitis, whilst the length of time occupied by the operation proper is diminished and the shock is consequently less. We have adopted both plans, and on the whole we are in favour of performing the tracheotomy immediately before proceeding to do the thyrotomy. In cases of extensive disease, however, when there are enlarged glands in the neck, there is a distinct advantage in performing the operation in two stages, quite apart from any diminution in the irritation of the trachea; namely, there is much less risk of suppuration in the neck than if the various layers of the cervical fascia were opened up for the removal of the glands at the same time that the larynx is removed: the cellular planes are fairly well closed up before the larynx is removed, and therefore the risk of septic infection is reduced to a minimum. It is also easier to prevent pus getting into the trachea if the operation be done in two stages. In these cases, therefore, we would advocate that the operation be divided into two stages, the first being the performance of the tracheotomy and the removal of the glands in the neck, and the second being the operation on the larynx itself. We are accustomed to allow about a week to intervene between the two operations; some surgeons advocate as long a period as a fortnight, but much will depend upon the extent of the primary disease and the rapidity with which it is spreading.

We are generally accustomed to perform a median tracheotomy, intermediate between the high and low forms, dividing the isthmus of the thyroid freely and introducing a tube between its two halves. This leaves quite sufficient room above for the necessary operation upon the larynx, whilst the trachea is not so deep as in the low operation and the tube is more easily managed. When the operation is divided into two stages, an ordinary tracheotomy tube is first introduced, but the opening in the trachea should be made large enough to admit of the admission of a Hahn's or Trendelenburg's cannula (see p. 238) at the second operation, as it is not advisable to have to perform any further cutting operation on

the trachea. At the second operation the Hahn's cannula<sup>1</sup> (see Fig. 80) is inserted into the tracheal opening with a tube attached to it through which the chloroform may be administered without the anaesthetist getting in the way of the operator (see Fig. 81, p. 239).

**Thyrotomy.**—This operation is only suited for very early cases, but it may be followed by extremely good results, both with regard to the question of non-recurrence and also with regard to that of articulation, the patient retaining a perfectly satisfactory though somewhat hoarse voice. In most cases of intrinsic cancer of the larynx, the operation should commence with a thyrotomy whenever it is considered that the disease is quite local. This allows adequate inspection of the interior and the surgeon is able to determine the best course to pursue. Before it is undertaken, however, the position of affairs must be explained to the patient and the surgeon should have leave to do whatever is necessary. We have in several cases been agreeably disappointed in finding after thyrotomy that the disease was more local than indications had seemed to point to. This was notably the case on one occasion in which the larynx seemed to be entirely filled with growth, but in which, on performing thyrotomy merely as a matter of routine and not in the hope of finding the disease localised, it turned out to be a pedunculated mass in the neighbourhood of the arytenoids which could be completely removed by clipping through its pedicle. A median vertical incision is made in the middle line, commencing at the upper border of the hyoid bone and continued down to the lower border of the cricoid cartilage; this incision is carried right down to the cartilages. The tissues are dissected off the thyroid cartilage for about half an inch on either side of the middle line and the flaps held aside. A small superficial transverse incision is then made in the thyroid cartilage about its centre so as to indicate the proper position for re-uniting the two halves at the end of the operation, and the cartilage is split in the middle line. Should this structure be partially ossified, the crico-thyroid membrane is opened, and the cartilage is split vertically by introducing one blade of a strong pair of straight scissors beneath it in the middle line. The two halves are then retracted firmly with sharp hooks, and the interior of the larynx is exposed; should the exposure be insufficient, short transverse incisions may be made in the crico-thyroid and thyro-hyoid membranes. A small piece of sponge firmly fastened to a stout thread may now be introduced into the upper end of the trachea above the Hahn's tube to make still more certain that blood does not get into the trachea, and the further steps of the operation

<sup>1</sup>This may be prepared as follows: The tube is first boiled, and then a piece of firm flat sponge, which has lain for some days in a 1-20 carbolic lotion, is squeezed dry, dipped in a 10% ethereal solution of iodoform, and wrapped firmly around the tubing. The opposed surfaces are then stitched together and a piece of sterilised tape is finally wound tightly round the sponge so as to compress it. The whole is then dried. The tape is removed before the tube is introduced dry into the trachea.



are then determined upon. These will depend upon the size and situation of the growth, but if this be limited to one side of the larynx and not firmly adherent to the cartilages, an internal operation will often suffice. Under these circumstances an incision should be made through the mucous membrane at some little distance around the growth and carried down to the cartilage. The perichondrium is then raised with an elevator and the diseased area removed.

When the disease is limited to the vocal cords and has not penetrated to the cartilages, it is not absolutely necessary to strip off the perichondrium, but this does no particular harm and makes the result more certain. The bleeding is usually comparatively slight and stops on pressure. After it has been arrested, the sponge is removed from above the Hahn's cannula, which by this time will have swelled sufficiently to block the trachea, and it is well to leave the cannula in position for a few hours until the oozing has entirely stopped.

The two halves of the thyroid cartilage must be united accurately by catgut stitches. This is generally easy and there is little or no tendency to displacement afterwards. The skin incision is then completely closed and the patient put back to bed. The Hahn's cannula is retained for six or eight hours, when it is replaced by an ordinary tracheotomy tube, which may as a rule be left out after 24 hours and the wound then allowed to close. Unless the incision goes through the arytenoids or the aryteno-epiglottidean folds, the patient can swallow quite well and may be fed by the mouth without difficulty. There is often considerable coughing during healing, but this passes off, and the result is usually very satisfactory. The patient may sit up at the end of a week.

**UNILATERAL LARYNGECTOMY.**—Should the disease infiltrate extensively and attack the cartilage but be still limited to one side, one half of the larynx should be removed. This operation involves much greater risk to the patient than does complete laryngectomy, done as recommended on p. 263, on account of the free communication between the pharynx and trachea; therefore, should there be the least doubt as to the limitation of the disease, the complete operation should be chosen.

Transverse incisions are added to the vertical one, one over the lower border of the cricoid and the other over the thyro-hyoid membrane, and the flap marked out is raised, the perichondrium being lifted with it except when the cartilage is obviously diseased. This displays the outer surface of the thyroid and cricoid cartilages. The latter is then divided in the middle line in front with scissors, and the separation is carried backwards so that the œsophagus below and pharynx above are detached from the posterior surface. The cricoid is then split behind and the separation is effected above in the neighbourhood of the aryteno-epiglottidean folds. The surgeon must be careful not to leave disease behind, but at the same time he must avoid encroaching too far on the mucous membrane of the pharynx. The detachment is best effected with blunt-

pointed scissors. Any bleeding vessels must be secured as they are cut; the superior laryngeal artery and nerve will of course be divided.

When all bleeding has been stopped, careful search should be made for enlarged glands, and if any are present, the entire lymphatic area involved is dissected out. The larynx is filled with strips of cyanide gauze which should not be packed tightly enough to cause irritation; the object is to arrest hæmorrhage and prevent blood trickling into the lungs. The transverse incisions are then brought together and one or two silk worm-gut stitches are inserted into the vertical one, room being left for the ends of the gauze to emerge. If the neck has been opened for the removal of glands, a drainage tube should be inserted at the most dependent spot.

In this operation it is well to insert a fresh Hahn's tube immediately after the operation and to retain it for 24 or 48 hours, after which the ordinary silver tube may be substituted for it. The packing should be changed daily for three or four days, when it may be left out entirely and the skin wound allowed to granulate. The tracheotomy tube may be discontinued at the end of a week if the case progresses favourably and if there be no marked swelling or œdema about the wound.

The feeding after the operation will probably have to be by the rectum for the first three or four days, but if necessary an œsophageal tube may be passed once or twice daily as well and the patient fed by it. In doing this, great care must be taken to pass the tube along the uninjured side of the pharynx so as to avoid irritating the wound. Swallowing is usually possible within less than a week, and when first attempted it is well for the patient to lie with the head hanging over the bed with the sound side downwards, so that the food runs along the healthy side of the pharynx. A good plan is to make the patient swallow a small quantity of boracic lotion before he is allowed to swallow food for the first time, so as to see if it passes in the proper direction. Should it run into the larynx no harm will be done, as it will simply act as an irrigation to the wound. Speech is generally recovered soon after the power of swallowing is restored, and the patient talks in a low, hoarse, monotonous voice, though usually perfectly clearly and distinctly.

**COMPLETE LARYNGECTOMY.**—As a rule, when thyrotomy and internal removal of the growth are not feasible, complete laryngectomy is required if any operation is to be performed at all. This may be done in two ways. On the one hand it may be so planned that, when the patient recovers, an artificial larynx may be introduced between the trachea and the opening into the pharynx: on the other hand, the operation may be made to cut off permanently all connection between the pharynx and the trachea. The mortality after the latter operation is very much less than after the former because, when an artificial larynx is to be subsequently fitted, the operation must be carried out in such a way that the discharges from the wound and the pharynx very readily run down into

the trachea,<sup>1</sup> whereas, on the other hand, where the pharynx is completely shut off, the tracheotomy wound is protected from discharges and the risks of the operation are comparatively slight. This is such an important matter that in most cases we prefer the operation which completely shuts off the trachea from the pharynx. In cases requiring the complete operation there are almost always numerous enlarged glands in the neck and it is well to divide the operation into two stages (see p. 259). It must be remembered that enlarged glands are very likely to be present on both sides of the neck and both anterior triangles may therefore require to be cleared out.<sup>2</sup> The removal of the larynx is done as follows:

A vertical incision is made from the upper border of the hyoid bone down to a little below the lower border of the cricoid cartilage. Transverse incisions are made at the upper and lower end of this and the two flaps thus formed are dissected up freely. Usually it is well not to take the perichondrium of the larynx. After the sides of the larynx and the attachment of the pharynx to it have been defined, the trachea should be divided completely across below the cricoid cartilage and this should be done somewhat obliquely from before upwards and backwards. The œsophagus and pharynx can now be peeled from the back of the cricoid cartilage with a blunt dissector, which can generally be inserted between the perichondrium and the cartilage, and thus there is less risk of injuring the pharynx. When the upper part of the cartilage is reached, the pharynx is peeled off as far as possible right up to the aryteno-epiglottidean folds, provided that these be not affected. When the point is reached above which it is not safe to leave any more of the mucous membrane, this must be clipped across, the epiglottis being also divided or removed altogether; a few snips of the scissors will now detach the larynx completely. This leaves a large gap communicating with the pharynx, whilst the obliquely divided end of the trachea lies in the lower part of the wound.

The next step is to shut off the pharynx, and this is done by first of all sewing up the mucous membrane with a separate row of stitches, the mucous surface being turned inwards as far as possible. It is best, if possible, to bring up and suture the anterior wall of the pharynx to the base of the tongue transversely. Next, the muscles and soft tissues over

<sup>1</sup> The passage of blood and discharges down the trachea, during and after the operation, may be avoided to a large extent by attention to the position of the patient. We usually raise the shoulders on a large sand-bag so that the head is low and the blood runs into the naso-pharynx. Keen has recently suggested the adoption of the Trendelenburg position, and proposes in his next case to dispense with a preliminary tracheotomy, and to begin by dividing the trachea across below the larynx, attaching it to the skin, and inserting an ordinary tracheotomy tube through which the anæsthetic may be given by means of the apparatus shown in Fig. 81, p. 239.

Keen further suggests that after the operation the patient should be kept in the Trendelenburg position for 24 hours. The next day he is to be kept lying flat, on the third the shoulders may be raised, while on the fourth he may be allowed to sit up.

<sup>2</sup> The method of removing glands from the neck will be fully described in Part VI.

this are brought together by a vertical layer of stitches and the skin is then sutured closely over the wound, except below where the œsophagus is pushed back from the trachea by a blunt dissector and the trachea is drawn sufficiently forward for the cut orifice to lie on a level with the skin. It is usually well to continue the skin incision downwards for a little, so as to stitch it to the margin of the trachea all round with strong catgut. The rest of the skin incision should be closed with silk worm-gut stitches.

The Hahn's tube should now be removed and an ordinary tube inserted into the open end of the trachea. Gauze dressings are then applied so as to exercise a certain amount of pressure on the skin flaps above the opening into the trachea and thus to keep them in contact with the deeper parts, and it is well to insert a small drainage tube on each side running up towards but not touching the line of suture in the pharynx, so that, should the opening in the pharynx give way, the discharge can escape. Rectal feeding must be employed at first, but, if the union holds, feeding by the mouth may be begun in about a week.

This operation is extremely successful when it is not necessary to remove portions of the pharyngeal wall. The mortality is very slight and the functional result is good. The patient can swallow well and breathes freely through the trachea. Of course the great objection to it is the complete loss of voice, but it is found that the patient can learn after a time to whisper a few words at a time sufficiently to make himself understood. The great safety of the operation compared with the other compensates for this loss of voice.

In the other operation the trachea is not brought forwards to the skin and the opening in the pharynx is left open and the entire wound is packed with gauze, the case being treated in much the same way as we have already described for unilateral laryngectomy (see p. 261). In these cases an œsophageal tube may be passed from a very early period.

When the pharyngeal wall is extensively affected, the results are not nearly so good. Attempts have been made to rid the patient of the disease by excision of the pharynx and the larynx, but that involves feeding through an œsophagostomy opening as well as breathing through a tracheotomy opening, and in most cases recurrence has also taken place. Under these circumstances the condition of the patient for the remainder of his life is by no means a happy one; indeed very few will submit to it if the case be thoroughly put before them, as it always should be. This question will be referred to again in Part VI.

DIVISION II.  
THE INTRINSIC DISEASES OF THE  
NOSE, EAR AND LARYNX.

BY H. LAMBERT LACK, M.D. (LOND.), F.R.C.S.

*SECTION I.—AFFECTIONS OF THE NOSE.*

CHAPTER XXV

THE ANATOMY OF THE NOSE.

BEFORE proceeding to the subject proper of this section it seems well to draw attention briefly to some of the chief points in the anatomy of the nose from a surgical point of view, this subject being new and much too briefly dealt with in anatomical text-books.

**THE VESTIBULE.**—The entrance to the nose, or vestibule, is lined by squamous epithelium continuous with that of the skin, and is separated by a sharp line from the nasal fossa proper. The opening is protected by several large stiff hairs or vibrissæ.

**THE NASAL FOSSÆ.**—The nasal fossæ are two extremely irregular cavities which are divided into four more or less horizontal channels by the three turbinate bodies (see Fig. 89). The inferior turbinate is largest in front and tapers posteriorly; the **inferior meatus** is narrowed anteriorly and posteriorly and much more roomy in the centre, the outer wall of the nose bending strongly outwards at its centre (see Fig. 93). The shape of the inferior meatus, which has been well compared to that of a boat with a small piece of either end removed, is of considerable surgical importance, for in cases of undue narrowness of the nasal passages direct access to the larger middle part of the meatus is obtained by removing the anterior extremity of the inferior turbinate, and thus free nasal respira-

tion may sometimes be restored. High up under the concavity of the inferior turbinate is the lower opening of the lachrymal duct (see Fig. 98). The **middle meatus**, lying between the inferior and middle turbinates, receives at its upper part the openings of the anterior set of accessory

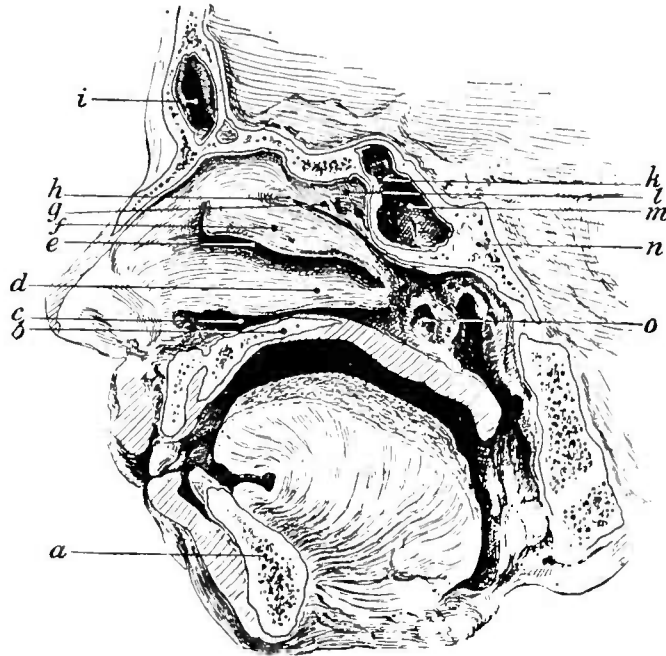


FIG. 89.—VERTICAL ANTERO-POSTERIOR SECTION OF THE HEAD PASSING THROUGH THE RIGHT NASAL FOSSA IMMEDIATELY TO THE OUTER SIDE OF THE SEPTUM. *a.* Lower jaw; *b.* hard palate; *c.* inferior meatus; *d.* inferior turbinate; *e.* middle meatus; *f.* middle turbinate; *g.* superior turbinate; *h.* superior meatus; *i.* frontal sinus; *k.* posterior ethmoidal cell; *l.* fourth or highest meatus; *m.* sphenoidal sinus; *n.* body of the sphenoid; *o.* Eustachian tube.

sinuses, namely, the antrum, the frontal sinus, and the anterior and middle ethmoidal cells (see Figs. 90 and 91). On the outer wall of the nose, arising in front from the anterior portion of the lateral mass of the ethmoid in close proximity to the upper part of the anterior border of the middle turbinate, is a long shelf-like process—the *uncinate process*—which passes downwards and backwards parallel to the *bulla ethmoidalis*, and ends just below the *ostium maxillare* (see Fig. 90). It is broadest in front and gradually tapers posteriorly. The external surface looks outwards, upwards, and backwards, and forms the lower boundary of the *hiatus semilunaris*; the upper boundary of this hiatus is formed by a rounded prominence caused by a projection of one or more of the larger middle ethmoidal cells, and is known as the *bulla ethmoidalis*. Into this long narrow cleft open the *infundibulum*, the duct leading from the frontal sinus, in front, the *ostium maxillare* at the posterior end, and the ostia of some of the middle ethmoidal cells, usually near the anterior end. Thus, pus coming down from the frontal sinus or ethmoidal cells is guided by the shelf-like uncinat process towards the opening of the maxillary antrum, into which it is extremely liable to find its way. It will also be seen that these structures.

and especially the uncinæ process, form a most serious obstacle to the passage of a probe, etc., into the frontal sinus. The **superior meatus** is comparatively small and lies between the middle and superior turbinates: it receives the openings of the posterior ethmoidal cells. The **fourth** or

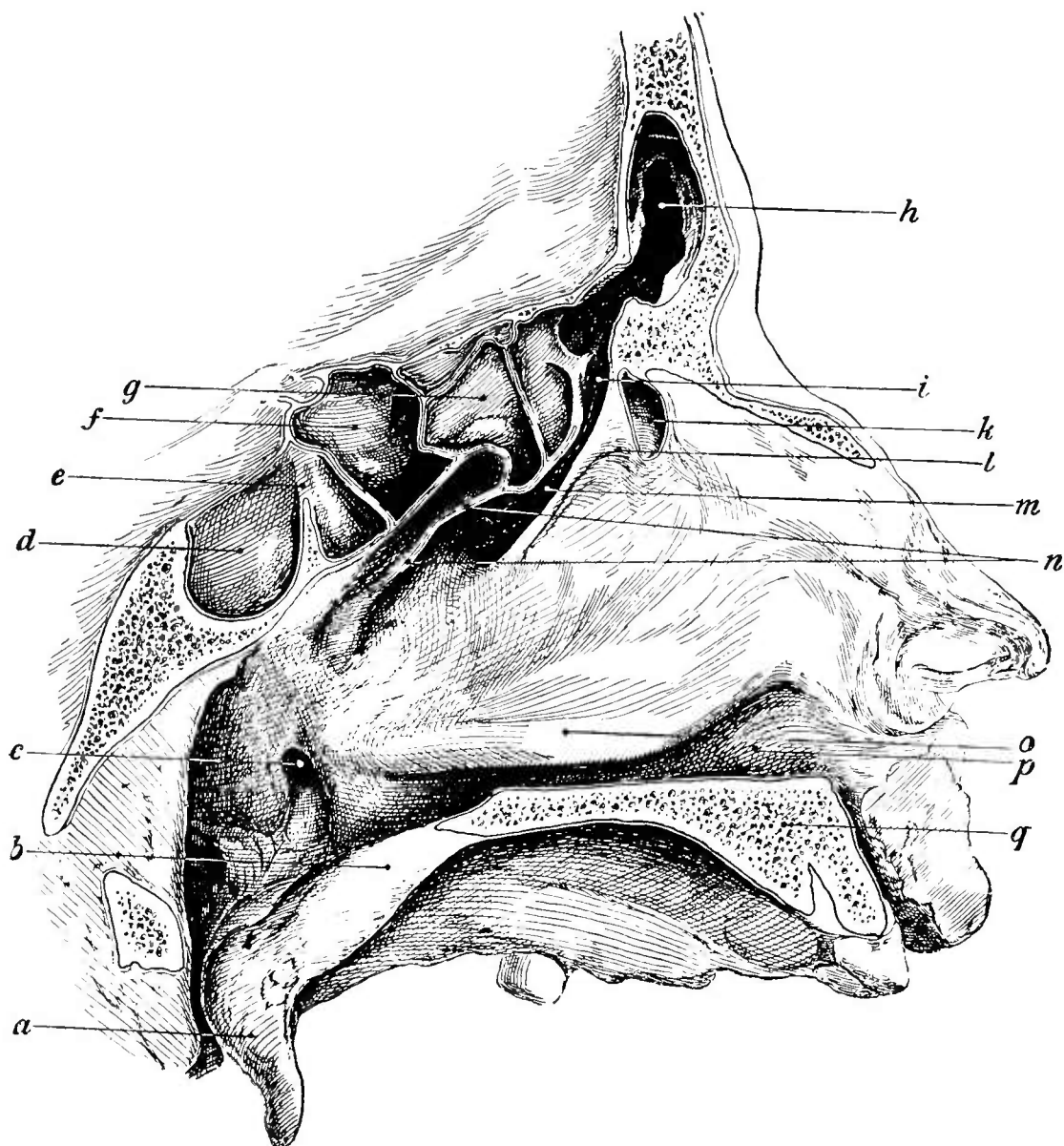


FIG. 90.—VERTICAL ANTERO-POSTERIOR SECTION THROUGH THE NASAL FOSSÆ SOMEWHAT TO THE LEFT OF THE MIDDLE LINE. The middle turbinate has been removed and a dissection made to expose the structures on the outer wall of the nose. *a.* Uvula; *b.* soft palate; *c.* Eustachian tube; *d.* sphenoidal sinus; *e.* position of the ostium of the sphenoidal sinus; *f.* posterior ethmoidal cell; *g.* middle ethmoidal cell; *h.* frontal sinus; *i.* infundibulum; *k.* a window cut in the uncinæ process to show the fossa on its outer side; *l.* uncinæ process; *m.* hiatus semilunaris; *n.* attachment of the middle turbinate; *o.* inferior turbinate; *p.* inferior meatus; *q.* hard palate.

**highest meatus** lies above and posterior to the superior turbinate and is bounded above by the roof of the nose. The sphenoidal sinus opens into it near its upper part (see Fig. 90).

**THE SEPTUM.**—The septum of the nose is formed in front by the triangular cartilage, and posteriorly by the vomer and the perpendicular plate of the ethmoid. It is very often asymmetrical; the bony part is more

or less deflected from the middle line in nearly 70% of skulls; and the triangular cartilage is almost invariably deflected (see Fig. 93). On the

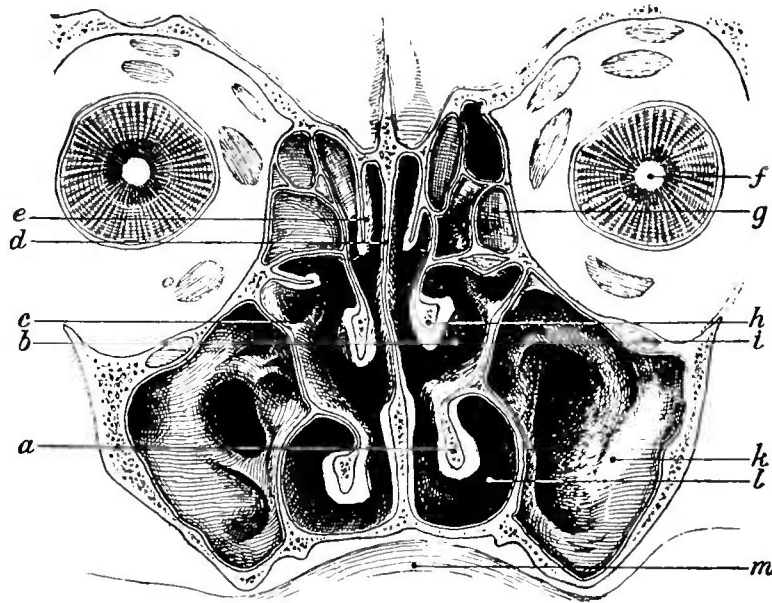


FIG. 91.—VERTICAL TRANSVERSE SECTION OF THE NOSE, IN THE PLANE OF THE EYEBALLS AND SECOND MOLARS, VIEWED FROM BEHIND. Showing the extent and relationship of the turbinates and the four meati, and of the antral and ethmoidal cells. *a.* inferior turbinate; *b.* middle fossa; *c.* uncinat process; *d.* nasal septum; *e.* superior turbinate; *f.* pupil; *g.* middle ethmoidal cell; *h.* middle turbinate; *i.* infra-orbital vessels and nerve; *k.* cavity of the antrum; *l.* inferior meatus; *m.* hard palate.

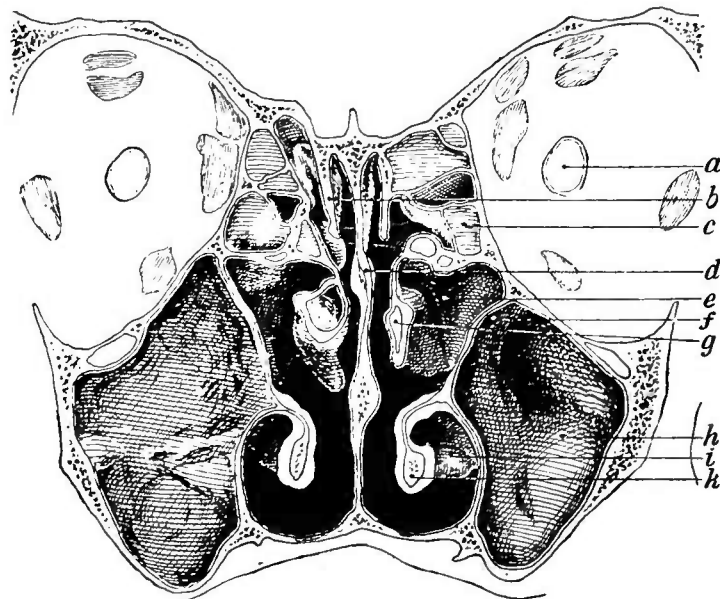


FIG. 92.—VERTICAL TRANSVERSE SECTION THROUGH THE NASAL FOSSÆ IN THE PLANE OF THE OPTIC NERVES AND THE THIRD MOLARS, VIEWED FROM THE FRONT. *a.* Optic nerve; *b.* superior turbinate; *c.* middle ethmoidal cell; *d.* septum; *e.* middle meatus; *f.* ostium of the maxillary antrum; *g.* middle turbinate showing a cell; *h.* maxillary antrum; *i.* inferior meatus; *k.* inferior turbinate.

other hand, the posterior third of the septum is almost always in the middle line.



**THE MUCOUS MEMBRANE.**—The mucous membrane covering the inferior turbinate bone is extremely thick and contains numerous large venous sinuses with muscular fibres in their walls forming a plexus; it also contains numerous racemose mucous glands, and the surface is covered by columnar ciliated epithelium. These vascular sinuses give to the mucous membrane somewhat the character of erectile tissue. The lower part of the septum and the floor of the nose are covered by a similar thick mucous membrane containing venous plexuses. In the upper part of the nose the mucous membrane is thin and intimately blended with the periosteum.

**The functions of the nose.**—The respiratory functions of the nose are extremely important. The air in passing through it is warmed, being raised almost if not quite to the body temperature, is saturated with moisture and is entirely freed from dust and organisms. The proper performance of these functions depends chiefly upon the integrity of the venous sinuses and the action of the ciliated epithelial cells. The former vary in size according to the demands made upon them by the state of the atmosphere, and the cilia, aided by a free secretion from the numerous mucous glands, remove all the dust and organisms that have gained access to the nose. Therefore, in operating it is extremely important not to cause any unnecessary damage to the parts carrying on these functions, and particularly the tissues of the inferior meatus. It is especially important to avoid extensive injuries to the epithelium, as under certain conditions these cells may lose their cilia and be replaced by a simpler form of squamous epithelium.

**THE ACCESSORY SINUSES.**—Of these the **maxillary antrum** is the largest and is situated in the body of the superior maxilla (see Figs. 91-93, 95). It is irregularly pyramidal in shape, *the apex* being formed by the malar process and the base by the outer wall of the nose. *The base or inner wall* separates the antrum from the inferior meatus of the nose below, and the middle meatus above. It is very markedly convex towards the antrum from before backwards in its lower part. This bony wall is everywhere very thin, especially in its posterior half and in the upper part near the ostium, where it is often defective in places. Its junction with the nasal floor and with the anterior wall form very thick angles of bone. At the extreme upper part of the inner wall and somewhat posteriorly is a small opening or occasionally two openings through which the antrum communicates with the posterior end of the hiatus semilunaris (see Figs. 92, 98).

*The floor of the antrum* is formed by the alveolar margin and the outer part of the hard palate. The roots of the first molar, and more rarely of the adjacent teeth, may protrude into the antrum as small conical projections on its floor and be separated from the cavity merely by an extremely thin bony plate, or by membrane only (see Fig. 98). As a rule the antral floor is on a somewhat lower level than the floor of the nose (see Figs. 91 and 92). *The anterior or outer wall* of the antrum corresponds

to the canine fossa externally. The bone forming it is thin, but not nearly so thin as that forming the inner wall, and it requires considerable force to puncture it. *The roof* of the antrum separates that cavity from the orbit and is a thin plate of bone: it is not uncommonly perforated in disease, with the consequent formation of an orbital abscess.

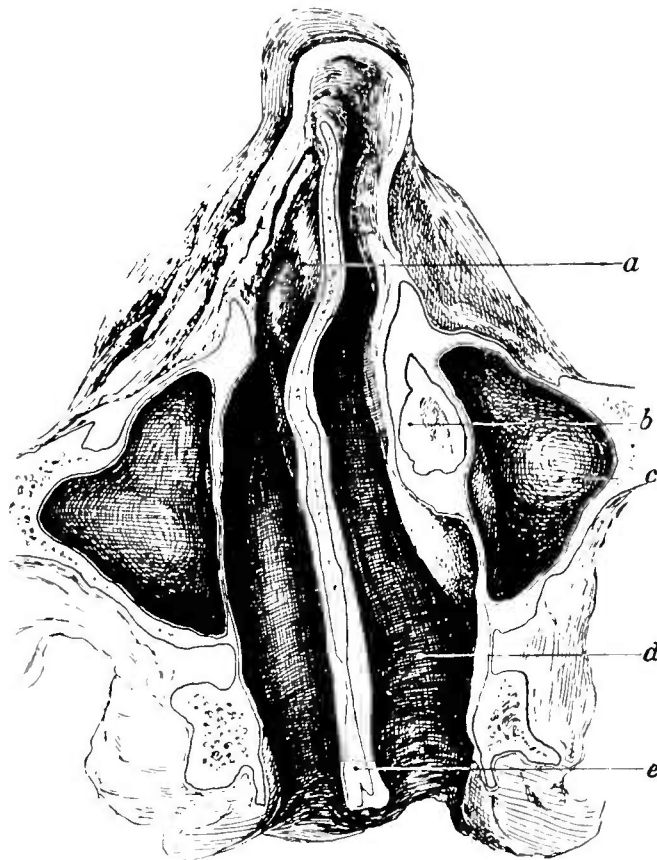


FIG. 93.—HORIZONTAL SECTION OF THE NOSE ABOUT HALF AN INCH ABOVE ITS FLOOR, VIEWED FROM ABOVE. On the left side the inferior turbinate has been entirely removed to show the antro-meatal septum. *a.* Large spur on the septum; *b.* inferior turbinate; *c.* cavity of the antrum; *d.* inferior meatus; *e.* septum.

*The cavity of the antrum* varies much in size, but is usually from 25 to 30 millimeters in diameter, both antero-posteriorly and vertically. In a few very rare cases the antrum may be extremely ill-developed: it may even be limited to a mere cleft in the bone or to a small cavity on a level with the middle meatus of the nose (see Fig. 94). In these cases it may be impossible to perforate it either from the alveolar margin or from the inferior meatus of the nose. The shape of the superior maxilla, with a high-arched palate, a narrow prominent alveolar border and with a hollow in the canine fossa, may give some clue to the smallness of the cavity. The antrum is commonly traversed by irregular bony septa, or by membranous folds, and very rarely may be divided by such partitions into two separate cavities (see Figs. 91, 92). The antrum is present at birth as an extremely small cavity (half to one millimeter in diameter), but after the

first year it gradually increases in size, attaining its full development at about the twelfth year.

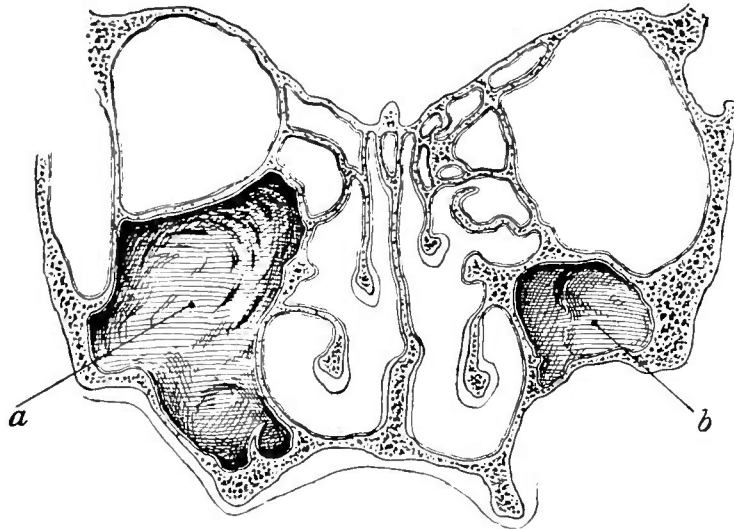


FIG. 94.—A SEMI-DIAGRAMMATIC FIGURE SHOWING ASYMMETRY OF THE ANTRAL CAVITIES. *a*. Normal antrum; *b*. extremely small antrum which it would be impossible to puncture from the alveolar process and extremely difficult to do so from the inferior meatus.

**The frontal sinus** is formed chiefly in the frontal bone and consists of a vertical portion extending upwards on to the forehead, and a horizontal portion passing backwards over the roof of the orbit (see Figs. 89, 90, 95). The sinus varies very much in size. It may extend outwards as far as

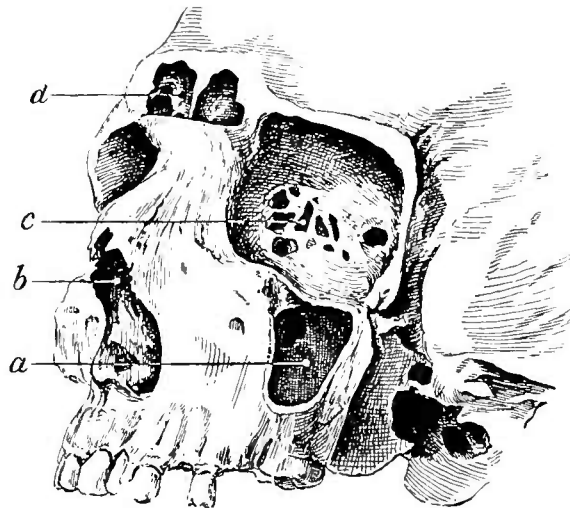


FIG. 95.—THE RELATIONS OF THE ETHMOIDAL CELLS AND THE MAXILLARY ANTRUM TO THE SURFACE. A skull from which the anterior walls of the frontal sinuses, part of the roof and outer wall of the orbit, and the outer walls of some of the ethmoidal cells and the maxillary antrum have been removed. *a*. The maxillary antrum; *b*. nasal fossæ; *c*. middle ethmoidal cells; *d*. frontal sinus.

the external angle of the orbit, while the orbital portion may extend backwards to the sphenoid bone, and the vertical portion upwards for an inch to an inch and a half or even more. In other cases both sinuses may be absent, or one sinus alone may be present. It is however very rare for the orbital portion of the sinus to be entirely missing, but the vertical part of it is absent in about 12% of cases. There are no reliable external

signs to indicate the size of the cavity. *The anterior wall* of the sinus is usually from two to three millimeters thick, but varies considerably in different skulls: this wall contains a slight but definite amount of diploë. *The posterior wall* is usually very thin, composed of dense, brittle bone with no cancelli; it is indented on its posterior surface with the convolutions of the frontal lobe of the brain. *The inferior wall* of the sinus is the most important, and consists of two portions,—the outer, or orbital, forming part of the roof of the orbit, and the inner, or nasal, formed by the roofs of some of the anterior ethmoidal cells. The orbital portion is thin, contains no diploë, is perforated near its inner end by a small vein, and is the most usual seat of tenderness and bulging in cases of suppuration in the sinus. The nasal portion of the floor forms a very irregular surface. The bone is extremely thin and commonly gives way in disease: consequently frontal sinus suppuration is almost invariably, if not constantly, associated with suppuration in some of the anterior ethmoidal cells. In the posterior part of this portion of the floor is a rounded or oval opening leading into the infundibulum. *The septum* between the two sinuses is often considerably deflected from the median line, and one sinus may actually overlap the other, and thus, in an attempt to reach a sinus near the middle line above the supra-orbital margin, the sinus on the opposite side may actually be exposed.

**The infundibulum** is a curved canal running downwards and backwards from the ostium of the frontal sinus, and generally terminating in the anterior end of the hiatus semilunaris, but sometimes opening into the upper part of the middle meatus (see Fig. 90). In the former case the canal is convex forwards and downwards and is generally tortuous; in the latter case it is much shorter and often nearly straight.

**The ethmoidal cells** are situated in the lateral masses of the ethmoid bone, above and external to the middle turbinate, and are bounded above by the cribriform plate, and externally by the lamina papyracea (see Figs. 91, 92, 95-98). The cells vary in size and number, and are never symmetrical. Generally speaking they are larger below and posteriorly, and smaller and more numerous above and anteriorly. It must be remembered that all their walls are extremely thin and easily broken down, and that they are separated from the orbit and from the cranial cavity by extremely thin plates of bone. They may be divided into three groups of cells—posterior, middle, and anterior. *The posterior group* consists of from one to four large cells with comparatively large ostia opening into the superior meatus; *the middle ethmoidal cells* form a group of from four to six opening into the middle meatus of the nose, usually high up under the middle turbinate, or more rarely into the posterior part of the hiatus semilunaris; *the anterior set* comprises a group of small cells opposite the lachrymal bone, and surrounding the infundibulum, into which they generally open. As already said, these anterior cells form the nasal portion of the inferior wall of the frontal sinus, and, surgically, they are best

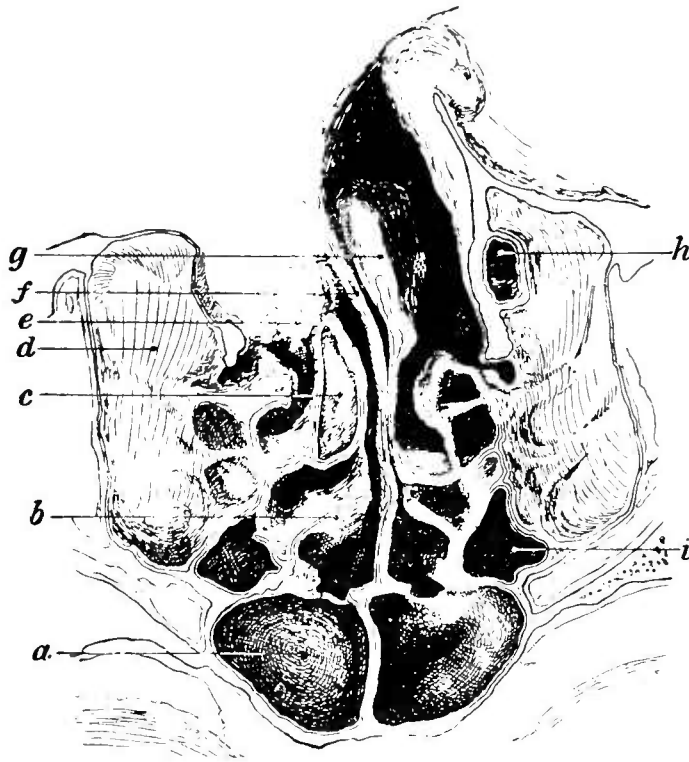


FIG. 96.—HORIZONTAL SECTION THROUGH THE UPPER PART OF THE NOSE, VIEWED FROM BELOW. *a*. Sphenoidal sinus showing the ostium (the cavities in this specimen are unusually symmetrical); *b*. superior turbinate; *c*. bony cyst in anterior end of middle turbinate; *d*. roof of the antrum; *e*. a nasal polypus; *f*. septum; *g*. anterior end of middle turbinate; *h*. lachrymal duct; *i*. posterior ethmoidal cell.

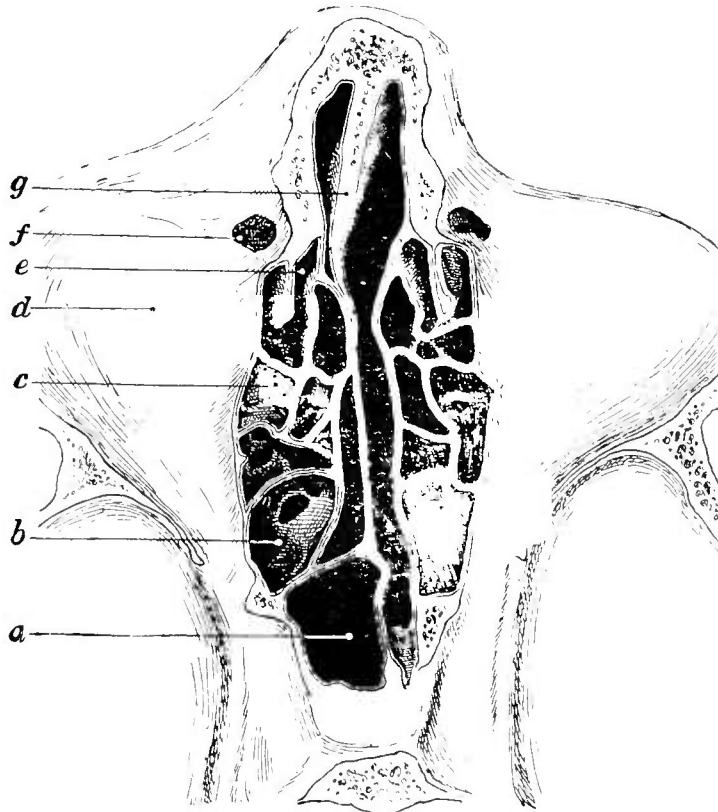


FIG. 97.—HORIZONTAL SECTION THROUGH THE UPPER PART OF THE NOSE, VIEWED FROM ABOVE. *a*. Sphenoidal sinus (the extreme asymmetry of these cavities is well seen, the one on the right side being a mere slit); *b*. posterior ethmoidal cells; *c*. middle ethmoidal cells; *d*. floor of the orbit; *e*. upper part of the middle meatus; *f*. upper aperture of the lachrymal duct; *g*. septum.

considered as forming a part of that sinus. The ostia of the ethmoidal cells are most usually in the lateral walls of the cavities. They may be near the apex, and are almost always too highly placed to allow of efficient drainage. The cells are practically absent at birth, and are developed during infancy and childhood.

**The sphenoidal sinuses** are situated in the body of the sphenoid bone, and are usually somewhat quadrilateral in shape (see Figs. 96, 97, 98).

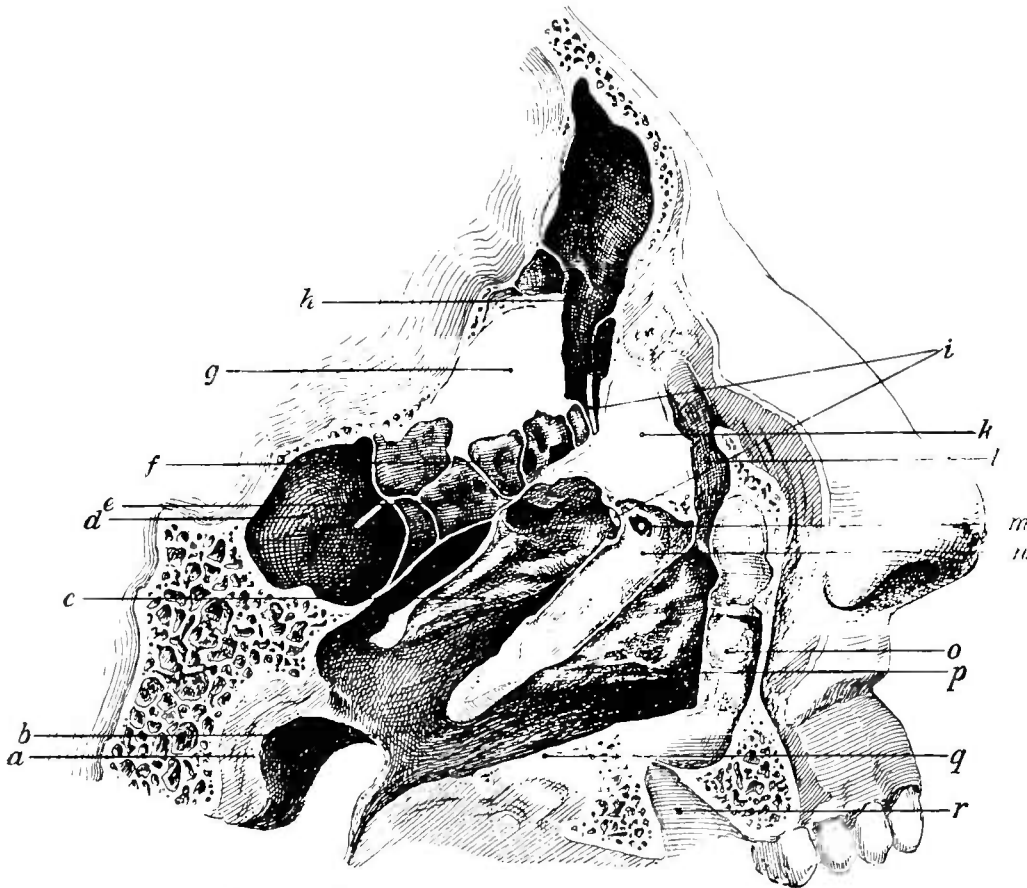


FIG. 98.—VERTICAL SECTION OF THE NOSE THROUGH THE BODY OF THE SPHENOID, NEAR THE MIDDLE LINE POSTERIORLY, AND PASSING OBLIQUELY FORWARDS THROUGH THE OUTER WALL OF THE NOSE, THE ORBIT AND THE ALVEOLAR BORDER ANTERIORLY. Viewed from the outer side. Part of the inner wall of the orbit and of the inner wall of the antrum have been subsequently cut away to show the infundibulum, the ethmoidal cells, and the large concavities under the middle and inferior turbinates. *a*. Post-pharyngeal wall; *b*. posterior margin of the nasal septum; *c*. outer surface of the middle turbinate; *d*. sphenoidal sinus showing a probe inserted into its ostium; *e*. posterior ethmoidal cells; *f*. middle ethmoidal cells; *g*. inner wall of the orbit; *h*. position of ostium of frontal sinus surrounded by anterior ethmoidal cells; *i*. probe passed down the infundibulum into the middle meatus; *k*. inner wall of the orbit; *l*. lachrymal duct; *m*. ostium of maxillary antrum; *n*. and *o*. parts of inner wall of antrum; *p*. large external surface of inferior turbinate; *q*. hard palate; *r*. socket of first molar tooth showing its proximity to floor of antrum.

The anterior wall looking downwards and forwards is usually thin, and forms part of the roof of the nasal cavity. The upper wall, dividing the sinus from the cranial cavity, is usually composed of somewhat dense bone, but it may be thin. The other walls are thick, and are of no surgical importance. The septum is very commonly deflected from the median line, and the sinuses themselves are extremely variable in size,

and are very rarely symmetrical. One may be as large as a walnut, and the other form a mere slit (see Fig. 97). The ostium opens into the fourth or highest meatus, is round or oval, from two to five millimeters in diameter, and is situated close to the nasal septum.

**The mucous membrane.**—The mucous membrane lining the accessory sinuses is extremely thin and pale, and is covered throughout with ciliated columnar epithelium. It will be seen that all these cavities, with the exception of the frontal sinus, depend for their drainage upon small openings situated at or near the apices of the various cavities, and thus we see the immense importance of the ciliary action of the lining mucous membrane, for upon this action the removal of the secretion entirely depends.

## CHAPTER XXVI.

### METHODS OF EXAMINATION OF THE NOSE AND THE ACCESSORY CAVITIES.

IN examining the nose the attention should in the first place be directed to its general shape and to the presence or absence of folds or creases on the alæ nasi indicative of nasal obstruction. Any prominence or bulging in the regions of the accessory cavities should be observed. The shape of the teeth and jaws should also be noted, and whether the patient habitually breathes through the mouth: the neck should be examined for enlarged glands, especially behind the sterno-mastoids.

**Illumination.**—For the examination of the interior of the nose artificial light must be used. Sunlight or strong daylight may be utilised when available, but is not always to be relied upon, and the latter is not sufficiently strong for the examination of the post-nasal space. Of artificial lights, the electric light, gas (either in the form of an Argand or an incandescent burner), the oxy-hydrogen lime-light or an ordinary paraffine lamp are those most generally employed. The brilliant illuminant acetylene gas is not yet sufficiently reliable.

**The electric light.**—The electric light is the most generally convenient whenever it can be obtained. The best form of lamp is shown in Fig 99, which may be arranged to stand upon a table, be fixed upon a movable bracket to the wall, or be used as a hand-lamp. It should be fitted with several plugs, so that it can be used in any house in which the electric light has been installed. It has the great advantages that it is always ready for use, that it does not give rise to much heat, that there is no danger of fire if it be dropped, and that it can be held and turned in any position. The lamp should be about 32 candle power, and should be of frosted glass. A stronger light (50 candle power) is sometimes required, but it is usually better to use a 32 candle power and to darken the examining room. If this light be used, it is necessary to provide a means of warming the mirrors—either a small spirit lamp or hot water.



**Gas.**—An Argand burner or one of the incandescent lamps may be used; the latter give a powerful white light, but are somewhat trying to the eye. The best form of stand is that shown in Fig. 100. Where the electric light is not available, gas is the most generally useful illuminant.

**The oxy-hydrogen lime-light.**— This is perhaps the best light of all, but it is by far the most troublesome to manage. The apparatus may be fixed on a tripod stand and can be carried about and erected anywhere. Such a lamp gives a diffuse bright light with a very strong fine central beam. The illumination shows objects almost in their natural colours and is very powerful and pleasant to use. It is suitable when in constant use, but the apparatus is cumbersome and for ordinary purposes it is not nearly so convenient as the electric light.

Should none of these lights be obtainable, an ordinary paraffine lamp may be used. This may be fitted with a reflector and a bull's-eye as for gas. Such a lamp may be easily made suitable to carry about in an instrument bag; in this case it should have a broad flat bottom, and the

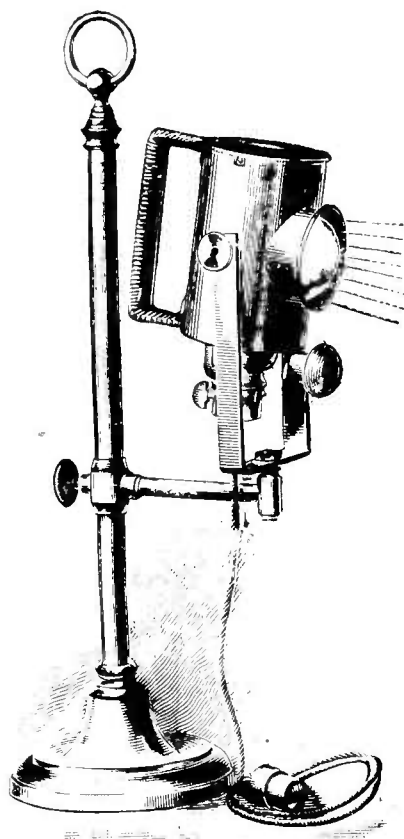


FIG. 99.—GREVILLE MACDONALD'S LAMP FOR LARYNGOSCOPY.

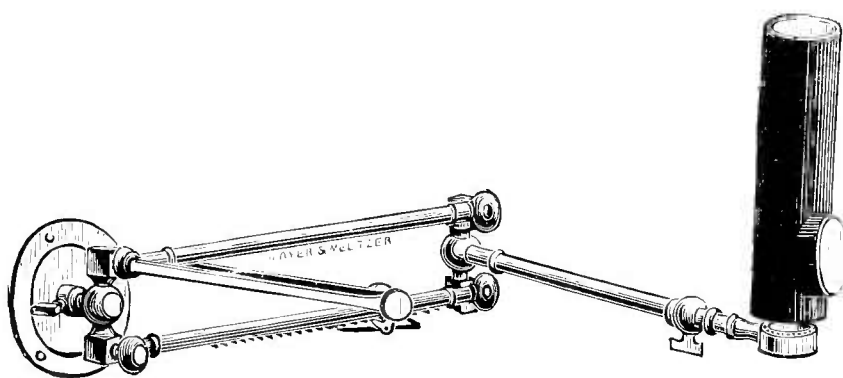


FIG. 100.—MACKENZIE'S LAMP FOR LARYNGOSCOPY. This lamp has an Argand burner and may easily be adapted to stand upon the table.

top of the oil should be covered by two or three layers of finely chopped cork, to prevent its being spilt when shaken.

**The Head Mirror.**—The interior of the nose must always be examined by reflected light, and for this purpose a frontal mirror is required. This may be fixed on the surgeon's head by either a band or a spectacle frame.

The band should be firm, not elastic, and tightened by means of a buckle. If a spectacle frame be used it must be carefully fitted to the surgeon's head and kept entirely for his own use. The chief essentials of a good mirror are that it should be light, have a large opening opposite the eye, and that its focal length should be about twelve inches. The mirror should always be worn over the eye on the same side as the source of the light; it then shades both eyes from the glare.

**The position of the patient.**—The patient should be seated on a firm chair with a narrow seat and a vertical back, so that he is compelled to sit upright. The chair should be strong and well balanced, so that it will not tip backwards. It is well to use an arm-chair, but the arms must be so adapted that the patient can easily turn to one or other side (see Fig. 140). The surgeon may conveniently be seated on an ordinary music-stool, which can be regulated in height, and it will be found most convenient that he should sit, as a rule, a little lower than the patient, so that his eye is about on a level with the patient's mouth. In this country the lamp is usually placed just behind and to the left side of the patient's head, and consequently the frontal mirror must be worn over the right eye of the surgeon. There are many advantages however to be obtained by reversing these positions, as most surgeons use the right hand in operating, and consequently the movement of the hand is apt to interfere with the source of the light if it is on the operator's right hand side.

#### ANTERIOR RHINOSCOPY.

**Specula.**—For anterior rhinoscopy, a nasal speculum is necessary, and of these Thudichum's or Lennox Browne's are the best (see Fig. 101). Thudichum's speculum should be held between the thumb and fore-finger, and then the third and fourth fingers should compress the spring (see Fig. 102). It is thus introduced, when the spring is released and the third and fourth fingers are allowed to rest upon the bridge of the patient's nose. By slightly raising the tip of the nose, a view of the inferior and middle meati can be obtained. In the lower part of the nose the most prominent object is the globular anterior end of the inferior turbinate, and it is normally possible to see some distance down the inferior meatus between this body and the septum. If however the turbinate be unduly large, it is impossible to see into the inferior meatus at all; and in cases in which it is unduly small, or in which the vascular tissue is temporarily collapsed, it may be possible to obtain a view of the posterior choana or posterior wall of the naso-pharynx. By raising the patient's chin and bending the head backwards, the middle meatus and the middle turbinate come into view. The superior turbinate can only be seen from the front in exceptional cases.

A better view of the interior of the nose can often be obtained by the aid of cocaine (see p. 284), which causes shrinking of the mucous

membrane and collapse of the erectile tissue. This is especially important and useful in cases in which the nasal passages are unduly narrow or distorted. By its means the posterior parts of the nose can be readily examined, and growths situated far back and other forms of obstruction

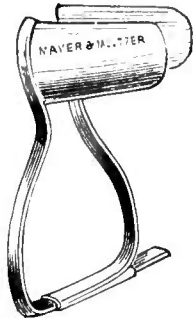


FIG. 101.—BROWNE'S NASAL SPECULUM.

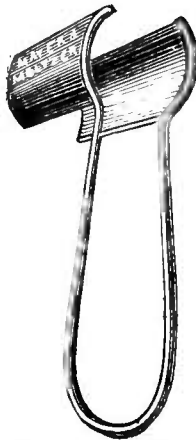



FIG. 102.—THUDICHUM'S NASAL SPECULUM. The left-hand figure shows the speculum, the right-hand one the method of introducing it.

hitherto concealed come readily into sight. It also enables the probe to be used more readily and without causing pain.

**The use of the probe.**—The nasal probe should be made of fine flexible metal, mounted upon a handle to which it is inclined at an angle of about  $60^{\circ}$ . It is especially useful for determining the attachments of growths, their mobility, and their consistence—whether cystic, mucous, fibrous, or partly bony. By its means masses of hypertrophied tissue previously concealed from view can often be rolled out from under the concavity of the inferior turbinate. The probe may also be used for the detection of foreign bodies or of pieces of necrosed bone, and in cases of suppuration in the nose, it is useful for exploring the ostia of the sinuses, determining the existence of obstructions and adhesions, etc.

#### POSTERIOR RHINOSCOPY.

**Instruments.**—For posterior rhinoscopy a mirror such as the smallest size of laryngeal mirror, a tongue-depressor, and in some cases a palate-

retractor are necessary. *The mirror* should be about a quarter of an inch in diameter and inclined at an angle of  $60^{\circ}$  to  $80^{\circ}$  to its handle. Fraenkel's adjustable mirror is also frequently used. The most generally useful *tongue depressor* is that shown in Fig. 103; it is simple, easily cleansed, and very comfortable to the patient.

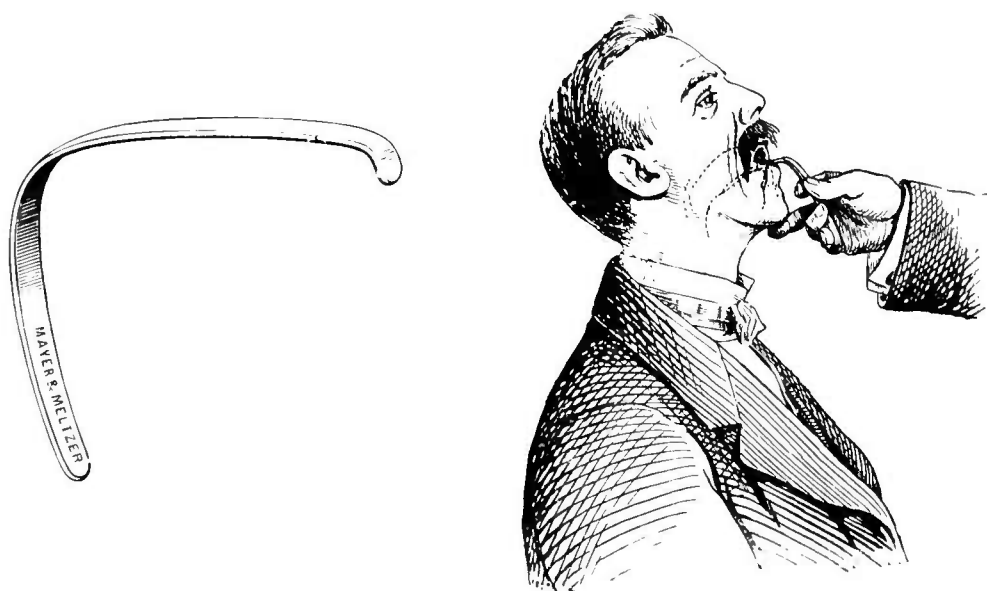


FIG. 103.—LACK'S TONGUE DEPRESSOR. The curved end is for laryngoscopy in children: the plain one is used as an ordinary spatula. The right-hand figure shows how the instrument is used.

The method is as follows: The tongue depressor, held by the thumb and two or three fingers of the left hand, is passed well back on to the centre of the tongue, whilst the mouth is opened to about half its full extent. The second or third finger of the surgeon's left hand is placed under the patient's chin, which is pulled well forward, and the tongue is pressed downwards and forwards well out of the way of the uvula without causing distress to the patient (see Fig. 103). A strong light being thrown on to the posterior wall of the pharynx, the small mirror is introduced with its flat metal surface towards the tongue, and carefully passed backwards into the post-nasal space, great care being taken to avoid touching the

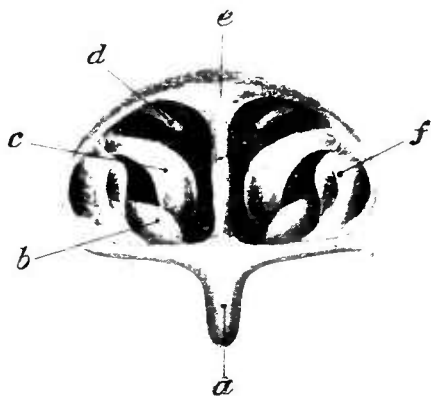


FIG. 104.—THE POST-NASAL SPACE AS SEEN BY POSTERIOR RHINOSCOPY. *a*, uvula; *b*, inferior turbinate; *c*, middle turbinate; *d*, superior turbinate; *e*, septum; *f*, Eustachian tube.

uvula or the soft palate. By turning the mirror in various directions, the whole of the post-nasal space can be examined *seriatim*. The objects to be inspected are the posterior end of the septum, the posterior ends of

the three turbinates, the Eustachian cushions, and the orifices of the Eustachian tubes (see Fig. 104). The presence or absence of adenoids or other post-nasal growth can also be determined. During the examination the patient should be directed to breathe freely through the nose, so that the soft palate may hang loosely. The greatest care must be taken to avoid touching the posterior part of the tongue or the uvula, but the mirror may be rested on the posterior wall of the pharynx and may even be allowed to press in this position, firm pressure being much more easily tolerated

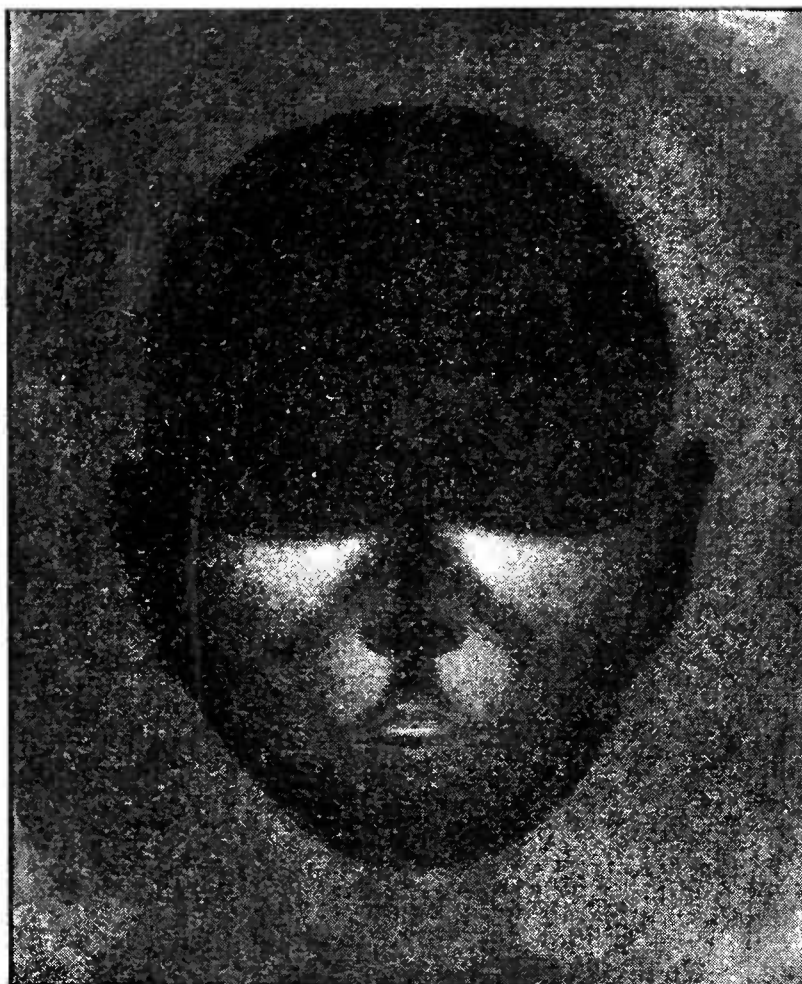


FIG. 105.—TRANS-ILLUMINATION OF THE MAXILLARY ANTRUM. The bright bands of light under the eyes are well shown.

than a light tickling. In some cases this examination is extremely easy to carry out; in others it is almost impossible. The mirror should never be retained long in position, but should always be removed on the first sign of irritability on the part of the patient. In a few cases the use of *the palate hook* greatly facilitates this method of examination. The best is one that is retained in position automatically, and thus does not occupy one of the surgeon's hands. As a rule it is necessary to cocaine the palate before using it.

As seen in the post-nasal mirror, the posterior part of the nose is usually

of a greyish or pale blue colour; the inferior tubinate is small, the middle comparatively large; the septum, usually in the middle line, is often symmetrically thickened near its centre; the Eustachian cushions are often prominent, and may even encroach to a large extent on the post-nasal space. Should adenoids be present, they can usually be recognised and their quantity gauged by the amount of the upper part of the septum which is concealed from view.

#### TRANS-ILLUMINATION.

This method is used in examining the accessory sinuses of the nose, but is only of practical value in the case of the antrum. The patient is taken into a completely darkened room; a small electric lamp on a tongue depressor is introduced into the mouth, any artificial teeth that may be present having been removed, and the patient's lips firmly closed. Under normal conditions, when the lamp is lighted, the whole cheek is clearly illuminated quite up to the infra-orbital margin (see Fig. 105), and in most cases a bright light can be seen in the patient's pupils, who also himself experiences a subjective sensation of light. This illumination will be interfered with if the antrum contains pus or a tumour, and also in certain cases in which the walls of the cavity or its mucous lining are extremely thick. The method is chiefly of use as a means of diagnosis. If clear illumination is obtained, it is certain that the cavity contains no pus, although the reverse is by no means true unless it has been previously ascertained that the antrum is normally translucent. The method is too fallacious to be of value in the frontal or other sinuses.

#### NASAL THERAPEUTICS.

**Methods of cleansing the nose.**—The interior of the nasal chambers may be cleansed by lotions, which may be used as simple hand washes or applied by means of the nasal douche, syringe, or spray. All fluids used for this purpose should be of about the density of blood serum. One of the best of these is Dobell's solution or some modification of it. A useful formula is:

R	Sod. bicarb.,	gr. xv.
	Sod. biborat.,	„ xv.
	Acid carbol.,	„ iv.
	Glycerini,	℥ xlv.
	Aq.,	ad. ℥ j.

One tablespoonful in two of warm water to be sniffed up the nose or used as directed.

This lotion is capable of various modifications. Thus chloride of sodium (five grains to the ounce) may be added in special cases as a mild astringent; or chloride of ammonium (five grains to the ounce) in cases in which a

stimulant is required: chlorate of potassium or iodide of potassium, in similar doses, in cases of unusual dryness of the mucous membrane, etc.: the carbolic acid, if too irritating, may be omitted. All nasal lotions are improved by the addition of either a little glycerine or sugar.

**Hand washes.**—The method most generally to be recommended is to sniff the lotion from the hand or from a shallow bowl up the nose, letting it pass well through into the throat, and returning it through the mouth. About one ounce to an ounce and a half of solution should be used at each washing. This method is the most pleasant of all and can easily be learned. It should be carried out before rather than after meals, as otherwise in some cases it causes retching and even vomiting.

**Syringing.**—When force is required to be used, as when large crusts have to be detached, the above method is ineffectual and must be replaced by syringing. This should, as a rule, be carried out by the surgeon himself in the first instance, and continued until the nose is absolutely clean, when the patient may be taught to do it. A rubber ball syringe is the most convenient. The stream of fluid should be directed along the inferior meatus, the patient's head should be bent well forward over a bowl, and he should be directed to open and breathe through his mouth. In this way the fluid, entering one nostril, will pass around the post-nasal space and come out down the other. Care must be taken not to inject the fluid with too much force, or it may be driven through the Eustachian tubes and set up acute otitis; this is especially liable to happen if the fluid be injected down a wide nostril when the other nostril is obstructed. The nasal douche, on account of the continuous pressure with which the fluid is injected, is extremely liable to give rise to this complication, and as its use has no advantage over that of the syringe, it should be entirely abandoned.

**Sprays.**—Nasal lotions may also be used by means of a spray. This instrument should give as coarse a spray as possible, but it is not nearly such an effectual method of cleansing the nose as those above mentioned and gives rise to more discomfort.

**Nasal irrigators.**—For simple cases in which the inferior meatus alone requires to be cleansed, if the above-described method of using a hand wash fail or is found very inconvenient, the fluid may be introduced by means of a nasal irrigator (see Fig. 106). This is filled with lotion, the thumb tightly applied to the opening at the side and the nozzle end inserted into the nostril; when the thumb is removed the fluid will flow down. In children fluid may be introduced into the nose in a similar way, or a teaspoon may be used, but as a rule it is better to employ a syringe, using it with the greatest gentleness.

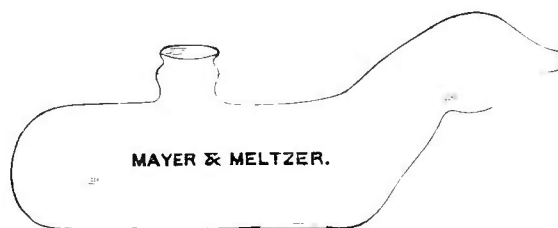

FIG. 106.—GLASS TUBE FOR IRRIGATING THE NOSE

**The use of oils.**—Oily solutions are often prescribed and may be applied by means of a good atomiser or by means of a small camel's hair brush; the latter is generally used if it be desired to make the application to the anterior part of the nasal septum only: in other cases it is better to use the atomiser. A good basis for these preparations is almond oil or paroline, to which may be added various medicaments, such as eucalyptus oil (one part to twenty), unguentum hydrarg. nitrat. (one part to six), morphinæ sulphatis (two to four grains to the ounce), menthol (grains xv. to the ounce), etc., as circumstances require. When it is desired to apply any ointment to the nose, it is better to soften it with almond oil or paroline so that it may be applied in a similar way.

Inhalations and insufflations are very rarely used in nasal diseases, and therefore the methods of prescribing and using them will be described later in connection with diseases of the larynx (*q.v.*).

#### NASAL ANÆSTHESIA.

**Cocaine and eucaine.**—A large number of minor intra-nasal operations can be performed under *local* anæsthesia. The best drug for this purpose is the hydrochlorate of cocaine, which is used in 5% or 10% solution, or occasionally 20% may be required. It is best and most convenient to prepare the solution freshly each time, using cocaine tabloids. The drug in solution is apt to undergo decomposition, but it can be kept for a considerable time in a 20% solution with the addition of some preservative such as salicylic acid (gr. x. ad ʒj.), or by dissolving it in camphor water.

It is best applied by first spraying the interior of the nose with one gentle fine spray, and then the part to be operated upon should be packed all round with small pledgets of wool soaked in the solution. Great care should be taken to prevent any of the cocaine running down into the throat and being swallowed, and therefore immediately after placing the pledgets in position the patient's head should be bent strongly forward. After about ten minutes the anæsthesia is usually sufficient, and will last for from five to ten minutes. Besides its anæsthetic effect, cocaine produces vascular collapse of the erectile tissue and marked shrinking up of the mucous membrane, and thus greatly facilitates operations by diminishing hæmorrhage and increasing the roominess of the nasal fossæ. For these reasons however, in certain cases, such as hypertrophy of the inferior turbinate, in which it is desired to remove pieces with the snare, the use of cocaine sometimes increases the difficulty of the operation by diminishing the size of the part to be removed. In children cocaine must be employed with great care, a solution of 2, 4 or 5% being as much as it is safe to use.

Latterly *eucaine* has been used in place of cocaine. It apparently takes a little longer than cocaine to produce anæsthesia, but its effect is a little more lasting. It does not produce such marked shrinking of the nasal mucous membrane, and it is said not to produce the toxic effects of cocaine,



but if cocaine be used in the careful manner above described there is very slight danger of it producing any ill effects. In some cases however there is a remarkable idiosyncrasy with regard to this drug, a minute dose producing dangerous symptoms. Thus, when first using it in a case, great caution is necessary, and diffusible stimulants such as sal volatile or whiskey should always be at hand and at once administered in case of faintness. It is a good plan always to give a small dose of stimulant as a prophylactic in nervous or weakly people. The after-effects of cocaine are frequently manifested by excitability, loquacity, and some loss of self-control, followed by tremblings and more or less severe depression. In neurotic individuals especially, a severe attack of hysteria is very common. These symptoms are best combated by the recumbent position and the administration of hot stimulating drinks, such as beef-tea or alcohol. In such cases the following method should always be employed in preference to cocaine alone.

**The suprarenal extract.**—This is best used in a 4% or 5% solution in combination with cocaine, a convenient method being to dissolve a 5-grain solid together with 5 grains of cocaine in about 100 minims of distilled water. The drug produces the most marked constriction of the nasal mucous membrane, rendering it practically white and anæmic: it requires from twenty to thirty minutes to produce its full effect. Used as an addition to cocaine, it produces more complete and lasting anæsthesia, and almost completely prevents hæmorrhage during small operations in the nose. Thus, during the whole of the operation it is possible to see accurately what is being done. The combination with cocaine is especially valuable in patients who are intolerant of the latter drug, as very complete anæsthesia can be obtained with the use of a very minute quantity of cocaine, and, moreover, it is less liable to be absorbed owing to the constriction of the blood vessels. The extract alone is inefficient and somewhat painful.

The one objection to the use of suprarenal extract is that it increases the tendency to secondary hæmorrhage, and consequently in operations on nasal spurs or on the inferior turbinate, in which this drug has been used, it is advisable not to let the patient go beyond reach of the surgeon for at least 24 hours, or, if this be impracticable, to pack the nose immediately after the operation.

Another nasal astringent sometimes employed, but of far less value, is *antipyrine*, which may be used in a 5% or 10% solution. A little cocaine should always be applied before using it.

#### NASAL ANTISEPSIS.

As already stated, the nasal mucosa covering the nasal fossæ proper is in health usually free from organisms, and if organisms be artificially introduced they are rapidly removed. Thus, before operations on the healthy nose, it is worse than useless to apply irritating antiseptics. Of course, in cases in which pus or other discharges are present, the nose

must be cleansed, and this is best done by means of a non-irritating solution, such as that of common salt, one drachm to the pint of warm water, to which a little sanitas or permanganate of potash should be added. In cases in which a purulent discharge is present, especially if in the form of adherent crusts, a most efficacious means of removing it is by the application of a 20% solution of hydrogen peroxide. This drug must be procured absolutely fresh and applied by means of cotton wool pledgets. It rapidly loosens crusts, even the large masses found in ozæna, and is an excellent non-irritating antiseptic. Further, the drug is very useful as a hæmostatic. Septic troubles after operations on the nose are almost unknown, probably on account of the free drainage which is obtained. Of course all the usual precautions must be taken to avoid introducing infection from without by means of the instruments, hands, etc., as in operations elsewhere.

#### ARREST OF HÆMORRHAGE.

Bleeding in the nose is always somewhat profuse, but in most cases it is sufficient to let the patient lie down quietly, bidding him avoid all efforts at sneezing, coughing and straining, and to apply cold to the face by means of iced water, or by pieces of lint wrung out of iced water in order to arrest it. The patient must also be given cold food, and in the intervals may be encouraged to suck ice; in more serious cases a small piece of ice may also occasionally be introduced into the nose.

In the more severe cases it is necessary to pack the nose. If the bleeding spot be known, it is best to apply direct pressure by packing the cavity tightly with a strip of gauze. If the bleeding spot be on the anterior part of the septum it is quite sufficient to introduce a plug of gauze or cotton wool into the affected nostril and then to tightly compress the nose with the finger and thumb, or, when the necessary apparatus is at hand, the blood may be sponged away and the hæmorrhage arrested by sealing the bleeding vessel with the electric cautery. If the upper part of the nose, the ethmoidal region, be the source of the hæmorrhage, it is better always to apply packing. This is most effectually done by passing the finger through the mouth up into the post-nasal space, and then introducing a long strip of gauze by means of forceps and tightly packing the nose from behind forwards, the finger in the post-nasal space preventing any gauze escaping through the posterior choana. The disadvantage of this method is that the removal of the gauze is liable to set up fresh hæmorrhage. For this reason it should be very gently and slowly removed, the nose being frequently douched so as to wash rather than pull it away.

Should the hæmorrhage be very profuse and not readily controllable by these means, a Cooper Rose's bag should be used. This is simply a soft rubber bag which is introduced into the nose and then inflated, and it will be found a most effective means of arresting hæmorrhage.

## CHAPTER XXVII.

### DEFORMITIES OF THE NOSE; FOREIGN BODIES IN THE NOSE.

#### DEFORMITIES OF THE SEPTUM.

THE nasal septum presents more or less deviation from the middle line in about 75% of cases, but in the large majority this gives rise to no inconvenience. It is only when the patient is conscious of obstruction in one nostril, or suffers from symptoms which can be reasonably traced to this affection, that it requires to be treated.

**Pathological conditions.**—The septum may be simply deflected without being thickened—a condition usually associated with external deformity of the nose, and due to some defect in the growth of the bones. In the large majority of cases, however, deflection of the septum is associated with a large amount of bony or cartilaginous thickening at the site of the bend, forming a ridge or spur, which is often termed enchondrosis or exostosis of the septum. These latter almost invariably result from trauma, and are consequently far more frequently seen in the anterior third of the nose. The ridge or spur may run either in an antero-posterior or in a vertical direction. These cases may or may not be associated with external deformity.

**Treatment.**—Septal deformities require treatment only when they actually give rise to symptoms such as nasal obstruction, when they are associated with chronic rhinitis, or when they interfere with the carrying out of other treatment: thus, they may hinder access to the accessory sinuses, or may prevent the passage of a Eustachian catheter. The main object of treatment is to free the nasal passages rather than to correct the deformity. Thus many cases require no treatment, and in others it is simply necessary to treat the chronic rhinitis by lotions, etc. (see p. 300), and thus, by reducing the swelling of the mucous membrane, free nasal respiration may be restored. In other cases, even when the spur is not very large, it may be in contact with the inferior turbinate, and may thus produce irritation; operation will consequently be required.

**Methods of operating.** (1) **In cases of simple deflection without thickening of the septum.**—These cases are the most difficult to remedy by operation. It is obviously useless to attempt to force a curved septum

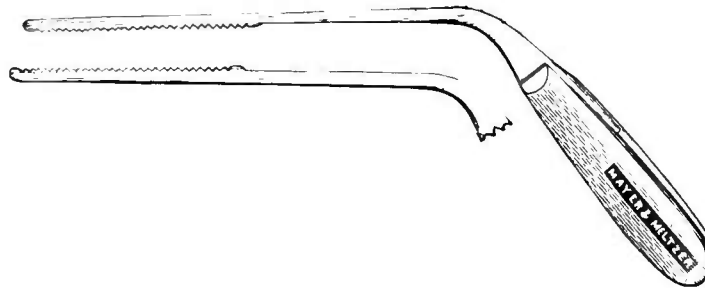


FIG. 107.—BOSWORTH'S SAW.

back into the middle line unless a portion of it be first removed. The most successful operation, if it can be practised in these cases, is the

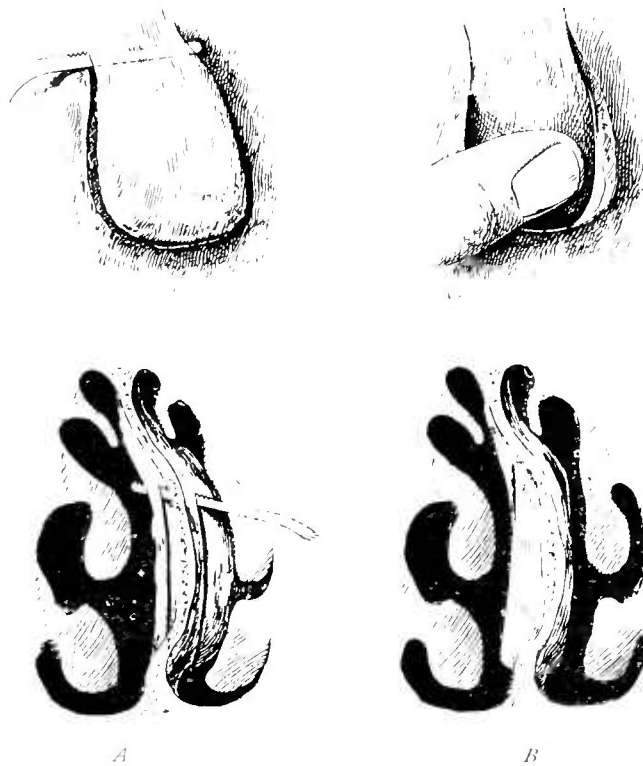


FIG. 108.—THE OPERATION FOR DEFLECTED SEPTUM. *A* shows the saw in action cutting the flap, and *B* the flap pushed through the aperture to the opposite side. In each case the upper of the two figures is the view (diagrammatic) from the side, the lower the view from the front.

following: Under gas, ether, or, if the patient prefer it, local anæsthesia, a Bosworth's saw (see Fig. 107), cutting in an upward direction, is inserted into the inferior meatus, under the most prominent part of the deflection, which is then sawn through from below upwards. The saw soon enters

the opposite nostril, and by continuing to cut upwards a large piece of the septum is partly detached (see Fig. 108, *A*). This piece, still attached along its upper edge, is left hanging as a large valve over the perforation. Now, by passing the finger down the obstructed nostril, this hanging piece of the septum is forced through the perforation, and its edges, catching on the margins of the opening, will prevent its return (see Fig. 108, *B*). In such cases not only will the obstructed nostril be freed, but the septum will be brought almost into the middle line, and healing will take place without the production of a permanent perforation. The *after-treatment* consists simply in packing the nostrils for a few days, and in subsequent irrigation until healing is complete.

In a very narrow nose this operation is impracticable. The best method then is to saw off the most prominent part of the apex of the deflected portion and then, having produced a perforation, to forcibly straighten the septum. This may require considerable force and the septum

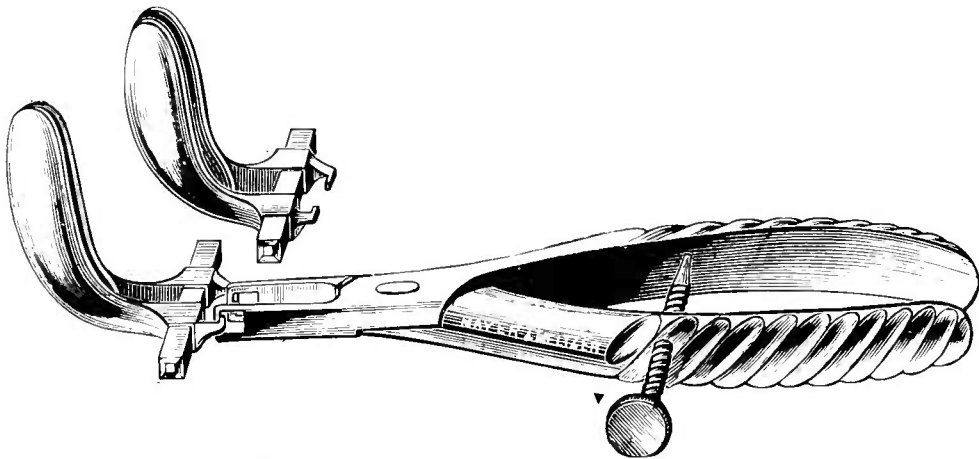


FIG. 109.—DELSTANCHE'S NASAL CLAMP FOR DEFLECTED SEPTUM.

may in part be fractured. To straighten the septum Delstanche's nasal clamp (see Fig. 109) is the most useful instrument, or if it should not be sufficiently strong, the septum may be first broken up by Smith's or Ashe's cutting forceps and then Delstanche's instrument may be introduced and left *in situ* for 1-2 days. With care this operation usually gives a satisfactory result, but it not uncommonly produces a permanent perforation of the septum. After the clamp has been removed, the nostril should be packed for from ten to fourteen days with strips of gauze which act as a splint to the septum. Rubber plugs and other nasal splints usually give rise to a great deal of discomfort and have no special advantages.

(2) **The removal of horizontal spurs or ridges.**—These, if small and not too close to the floor of the nose, may be most easily removed by a spoke-shave. This operation is extremely easy and quick, may be performed under gas or local anæsthesia, and is suitable for all cases in which only a small piece not containing bone requires to be removed. When the anterior cartilaginous part of the septum alone is affected all that is required is to remove the projecting part with a sharp probe-pointed knife, and this can

be accomplished quite easily under cocaine. If desired, the mucous membrane may be first incised and raised from the underlying cartilage with a small raspatory, but it is much quicker to remove the mucous membrane with the projecting part of the cartilage, and apparently this does no harm.

When there is a *large bony* projection of the septum, it is best to remove the projecting part with a saw. For this purpose any fine, stiff saw may be used; Bosworth's (see Fig. 107) is one of the best. If the saw can be introduced along the inferior meatus under the spur it is better to use the one with the blade cutting upwards, but if this cannot be done one with the cutting edge downwards must be selected. The blade of the saw having been inserted under the part to be removed, the direction in which the cut is to be made must be ascertained, and then, the saw being worked rapidly and lightly, the bone is cut through. The piece often remains adherent to the mucous membrane of the nose, in which case it may be clipped off with scissors. If the detached piece be grasped with polypus forceps it is usually easy to pass the scissors down to and to cut through its attachment, and it is better to do this than to wrench it away.

*After-treatment.*—The subsequent treatment consists in packing the nose with a strip of oiled gauze for a few days, followed by daily irrigations of the nose. It is never advisable to operate on the septum and on the inferior turbinate at the same time, and, if by chance the turbinate should be injured, the further progress of the case must be carefully watched and the packing continued until healing is quite complete, otherwise an adhesion between the opposed raw surfaces is certain to occur and will make matters worse. These adhesions are extremely difficult to overcome.

(3) **Vertical spurs and ridges** are much more rarely seen and may be dealt with on the lines above mentioned. The knife or saw is always required, the former being used in cases of small ridges when there is little hard bone to be encountered, and the latter in all cases in which the growth is mainly bony.

**Complicated cases.**—In many cases the above conditions are associated, a deflected septum being accompanied by a markedly thickened ridge. If removal of the ridge allows free nasal respiration, this alone should be performed. If however the ridge be small and the deflection great, the removal of the former may be insufficient, and then a subsequent operation may be undertaken to remedy the deflection, or the two methods may be combined in one operation as in the second method described on p. 289.

*Turbinectomy.*—Some surgeons have strongly urged the removal of a piece of the inferior turbinate in severe cases of deflected septum so as to make a passage round the obstruction. This has the single merit of being easy to perform. It is bad surgery to deprive the patient of such an eminently useful structure as a healthy inferior turbinate, if by any other means even more difficult to carry out it can be preserved to him.

## ADHESIONS BETWEEN THE SEPTUM AND THE INFERIOR TURBINATE.

**Causes.**—These adhesions commonly follow operations in which the septum and the turbinate have been simultaneously denuded of epithelium, but they may also be the result of other forms of trauma or of ulceration of the nose, such as occurs in syphilis or in acute inflammatory affections like fibrinous rhinitis. A very common cause is the unskilful application of the electric cautery.

**Treatment.** (a) *In recent cases.*—When an adhesion has just occurred or is in the process of formation, the mucous membrane is usually much inflamed, and any apparatus to keep the parts separate causes considerable pain to the patient, sets up an acute swelling of the mucous membrane and is consequently often intolerable. In a few of these cases however if a small piece of gauze be introduced between the raw surfaces and changed repeatedly, a good result may be obtained; but frequently, even after weeks of treatment, the raw surface absolutely refuses to heal until all packing or splints have been removed. If therefore, after a careful trial for a reasonable time, failure seems certain, it is well to give the nose some two or three months' rest and to allow the adhesion to form.

(b) *When established.*—When all the inflammation and swelling has subsided, the adhesion may be divided. If it be small, this is best accomplished by the galvano-cautery. The charred surfaces left have little tendency to adhere for several days, and consequently no apparatus need be used. In most cases it is sufficient to see the patient every second or third day for a fortnight, and, applying cocaine, to introduce a probe between the raw surfaces to see that no adhesion forms.

If the adhesion be extensive, it is better to divide it with the scissors or a saw, and then to remove a large piece either from the septum or from the turbinate with a spokeshave and thus to make a large gap between the opposing surfaces. Into this gap a small piece of gauze may be introduced, and the packing renewed every second or third day until healing is complete. If only a small interval be left between two broad surfaces and an attempt be made to keep the opposing surfaces apart by means of celluloid plates, indiarubber strips or metal or ivory plugs, there will often be so much irritation and swelling that the raw surfaces pressing tightly against the plugs will not heal, and consequently adhesion will recur directly the plugs are removed.

## ABSCESS OF THE NASAL SEPTUM.

**Causes.**—The majority of these rare cases occur in children, and are due to trauma, but a few are on record in which the disease has followed erysipelas, typhoid, etc. In the more common cases a hæmatoma of the septum follows the injury, and pyogenic organisms subsequently gain admission, probably through an abrasion in the mucous membrane, and

in most cases, on evacuating the pus, degenerated blood-clot is found in the abscess cavity.

**Symptoms.**—The usual history is that the child receives a severe blow on the nose, followed by bleeding and nasal obstruction. The acute symptoms soon subside, but in a few days the nose becomes hot, swollen, painful, and completely obstructed. On looking into the nasal fossæ they are seen to be completely filled by a symmetrical, bright red, tender, fluctuating swelling over the cartilaginous part of the septum. The whole end of the nose is frequently reddened, swollen, and tender.

**Treatment.**—This consists in evacuating the pus, and it is advisable to make a free incision on each side of the septum. This is commonly all that is required, but if the pus re-accumulates, the best plan is to snip out a small piece of the abscess wall on one side. This is quite easy and effectual, and does no harm. On the other hand, it is difficult to secure drainage by packing the cavity or to fix in a drainage tube except by passing it quite through the septum, which is liable to lead to a permanent perforation. As a rule, these cases do well, and recovery is complete within a week; but in a few, and especially in those in which the abscess has been present for some days unopened, necrosis of the cartilage occurs and leaves a permanent perforation. Also in the majority of traumatic cases there is some subsequent deformity of the septum or nose, which is probably due rather to the original trauma than to the abscess. As soon as the abscess has healed, an attempt may be made to remedy this by packing the nose on either side with a pad of gauze, or with an india-rubber splint.

#### CONGENITAL MALFORMATIONS OF THE NOSE.

Congenital malformations of the nose leading to partial or complete occlusion of one or other of the nasal fossæ are very uncommon. One or both of the posterior nares may be completely obstructed usually by means of a web, and more rarely by bone; anteriorly a more or less complete web is occasionally found at the junction of the vestibule with the mucous membrane proper.

**Treatment.**—The best method is to destroy the web-like obstruction thoroughly by means of the galvano-cautery and subsequently to keep the opening packed until healing is established. Should the occlusion be bony nothing can be done.

#### COLLAPSE OF THE ALÆ NASI.

This condition in a slight form is not at all infrequently met with in connection with post-nasal growths or other causes of nasal obstruction in the young, and sometimes with polypi or hypertrophied turbinates, etc., in adults. When these essential causes of the nasal obstruction have been



removed, the patient may still find considerable difficulty in breathing through the nose, which is relieved at once by the introduction of a nasal speculum. There is in these cases a large furrow externally just behind the cartilage of the alæ.

**Treatment.**—The cause of the nasal obstruction having been removed, the best way of overcoming this deformity is to insert into the vestibule a small circle of rubber tubing, sufficiently large to distend the ala comfortably. This must be regularly worn, and the patient instructed to remove it for cleaning and to re-insert it. When in position it should not be visible externally.

#### FOREIGN BODIES IN THE NOSE.

Foreign bodies in the nose are found almost exclusively in children, and consist of such articles as boot buttons, beads, pieces of paper, string, india-rubber, pencils, berries, etc., and more rarely the larvæ of various flies. The last are more common in adults in association with sinus suppuration. Attention is generally drawn to these cases by a purulent discharge from one nostril, which excoriates the upper lip and is extremely fœtid. When these symptoms are present a foreign body should always be sought for both by inspection and by means of a probe, an anæsthetic being given if necessary.

**Treatment.**—By far the most efficient instrument for the removal of these bodies is an ordinary strabismus hook. This should be passed well up into the middle meatus of the nose over and beyond the foreign body without touching the mucous membrane, so as not to arouse any resistance on the part of the child. Having got it into position behind the foreign body, it is gently drawn forward, and should the child now pull backwards no harm is done. In this way the large majority of foreign bodies may be easily removed. In a very few cases it is necessary to give chloroform; it is not necessary to produce complete anæsthesia, but simply to give the child enough to keep him quiet. In adults a little cocaine may be sprayed into the nostril.

In other cases foreign bodies may be grasped and removed with a pair of nasal forceps, but if this be attempted, it is advisable to introduce the finger into the post-nasal space to prevent the foreign body slipping from the forceps and passing back into the throat.

No attempt should be made by syringing down the opposite nostril to force a foreign body out by a stream of water coming from behind. This is dangerous, as considerable force may be required, and the infected fluid may enter the Eustachian tubes. Syringing should only be employed when larvæ, etc., are present in the nose, and in these cases it is generally better to destroy the larvæ by spraying with alcohol (10 per cent.), or formalin ( $\frac{1}{2}$  per cent.), and subsequently to employ the syringe.

## RHINOLITHS.

These are concretions, sometimes apparently originating spontaneously or forming around a small plug of mucus, but most commonly having a nucleus consisting of a small foreign body. The stone is almost invariably single, and the surface roughened and black, probably from blood pigment. In some cases the rhinoliths grow to a considerable size and are firmly embedded in the nasal mucous membrane. They can generally be removed in the same way as foreign bodies, but sometimes it is necessary to break them before doing so. This may be done with a strong pair of forceps or with bone pliers.

## CHAPTER XXVIII.

### INFLAMMATORY AFFECTIONS OF THE NASAL FOSSÆ AND THEIR SEQUELÆ.

#### ACUTE INFLAMMATIONS.

**SIMPLE ACUTE RHINITIS.**—Simple acute rhinitis or ordinary coryza is too well known to require much description. The affection is most common in children, and is comparatively rare in the aged. Besides the well-recognised predisposing and exciting causes of cold, it must be borne in mind that an acute coryza may also be due to the internal administration of certain drugs, such as iodine and arsenic.

**Treatment.**—There are numerous specifics, for all of which it is claimed that they will cut short the cold if taken during the first 24 hours. Of these, *opium* is undoubtedly the most reliable, and it is best administered as Mackenzie recommended, in five-minim doses of the tincture two or three times during the day, before meals. A more usual, but a less efficacious plan, is to give a full dose of Dover's powder (grs. x.) at bedtime. A large dose of *quinine* (5-8 grains in solution) or spirits of camphor (℥ x.) given at the commencement of a cold may also serve to arrest it. As a local remedy, strong inhalations of *ammonia*, or of ammonia and *carbolic acid*, which form the active ingredients of many quack catarrh cures, are occasionally effectual.

Even when a cold has become well established, a great deal can be done to cut short its course, and to alleviate the symptoms, if only the patient will consent to be treated. If the patient be a singer or a public speaker, or one in delicate health, or if there be any other reason which renders a speedy recovery particularly desirable, he should be confined to one room, which must be kept at an even temperature. A mild purge is frequently beneficial, and diaphoresis should be promoted by drugs such as Dover's powder (gr. x.) at bedtime, or liq. ammon. acet.<sup>1</sup>, as

<sup>1</sup> The following prescription may be used :

℞	Liq. morph.,	℥x.
	Liq. ammon. acet.,	ʒij.
	Aq. chloroformi,	ad. ʒss.

Sig. One tablespoonful every hour until sleep or perspiration is induced.

well as by the ordinary household remedies, such as a hot bath, plenty of hot drinks, sleeping in flannels, etc. For this purpose a Turkish bath is often most useful. A hot steam inhalation, containing compound tincture of benzoin (one drachm to the pint of hot water) will often alleviate the distressing pain and dryness of the nose in the early stages. The water should be at a temperature of from 130° to 140°. Each inhalation should be practised in a warm room, and should not last for more than five or six minutes, but it may be repeated three or four times during the 24 hours.

When the discharge lessens and becomes more purulent, a simple alkaline nose lotion should be given (see p. 282), and if the nose be at all sore, an ointment, such as vaseline or lanoline made fluid by the addition of almond oil or paroline, should be frequently applied to anterior part of the nose with a small camel's hair brush. Change of air, with a suitable tonic, such as perchloride of iron in large doses, etc., will probably complete the cure.<sup>1</sup> This treatment should always be enforced in weakly patients or in those in whom it is highly desirable that a cold should be speedily got rid of; but the majority of patients will prefer to let the affection run its course rather than submit to the restrictions necessary for successful treatment.

In treating an exceptionally severe cold, the possibility must be borne in mind that secondary infection of one of the accessory cavities of the nose may ensue, and also that in children acute rhinitis may usher in one of the specific fevers, such as measles, etc.

**After-treatment.**—Persons who are particularly subject to colds should be examined with a view to detect and remedy any chronic nasal affection, such as hypertrophy of the inferior turbinates, polypi, etc., and in children adenoid growths in the post-nasal space should especially be sought for. Certain general precautions should also be adopted. The clothing should be warm and light, adjusted carefully to the changes of the weather, and woollen garments should always be worn next the skin. Care must be taken to avoid draughts when overheated or perspiring. The healthy action of the skin should be promoted by a cold sponge-bath daily, followed by thorough drying and rubbing. In cold weather the water may be tepid or the room warmed, and, if rapidly carried out under these conditions, even weakly persons and children will be all the better for it. In otherwise healthy people, an occasional Turkish bath is probably of value. Ill-ventilated, hot rooms must always be avoided, and

<sup>1</sup> The following prescription may be used:

R	Tinct. ferri perchlor.,	℥xx.
	Tinct. nucis vom.,	℥viiij.
	Tinct. limonis,	℥xx.
	Glycerini,	℥xx.
	Aq. chloroformi,	ʒij.
	Inf. calumbæ,	ad. ʒj.

Misce. Ft. mist. Signe. To be taken three times daily after meals.

the patient should sleep with the window open all the year round, though a small fire in the very cold weather is desirable. Generally speaking, every means must be taken to keep in good general health; tonics should be prescribed if necessary, and the well-known causes of cold should be avoided.

**RHINITIS IN THE SPECIFIC FEVERS.**—Some of the most severe forms of acute rhinitis are met with as symptoms or complications of the acute infectious fevers. Thus, rhinitis occurs constantly in measles, whooping cough, and influenza, very commonly in scarlet fever, typhoid, typhus, smallpox, chicken-pox, etc., and is often seen in the secondary stage of syphilis. In diphtheria and erysipelas an acute inflammation of the nose may also be found, but in such cases the nose is really attacked by the specific process. The eruption of smallpox, chicken-pox, etc., may also appear in the nose. Nothing further need be said about these cases of rhinitis, except that they are of a very severe type, are often associated with or followed by inflammation of the accessory sinuses, and that they are very apt to become chronic and to lead to important changes in the nasal mucous membrane.

**GONORRHOËAL RHINITIS.**—Gonorrhœa of the nose is very rarely seen in adults, but it is occasionally produced by direct inoculation of the nose with infected hands, and in some cases the affection is very severe. A few cases of purulent rhinitis are seen in infancy in which the gonococcus can be demonstrated in the discharge, and mild rhinitis associated with and probably due to the gonococcus is not at all rare in infants suffering from gonorrhœai ophthalmia. In most of the latter cases the nasal discharge is slight and unimportant, but in a few it is purulent and associated with complete nasal obstruction and excoriation of the upper lip.

**Treatment.**—The treatment consists in thoroughly cleansing the nose by frequent irrigation with mild antiseptic solutions. Boracic acid (gr. xv. to ̄j), or a solution of common salt with sanitas or permanganate of potash<sup>1</sup> may be used, and, in the first instance, the syringing should always be done by a surgeon or trained nurse (see p. 283). Many of these infants have considerable difficulty in suckling and must be fed with a spoon. As a rule recovery is rapid if the treatment be thoroughly carried out. All the instruments used must be carefully disinfected, and not employed for other purposes.

**TRAUMATIC RHINITIS.**—This is a rhinitis due to the inhalation of irritating particles of dust of various kinds, and is seen amongst millers, sawyers, brush-makers, metal workers, etc., and also, in its most severe forms, amongst workers in certain chemicals, such as arsenic, mercurial sublimate, and bichromate of potassium.

**Symptoms.**—*In its milder forms* the patient complains of a dry nose

<sup>1</sup>The salt solution should be of the strength of about 5 grs. to the ounce, and to this xx. -xxx. minims of sanitas or gr. j.-ij. of potassium permanganate may be added.

associated with a feeling of irritation or stiffness ; occasionally he complains of obstruction, and frequently there are repeated slight attacks of epistaxis. On looking into the nose, the dust or other irritant is seen on the anterior part of the cartilaginous septum, on the anterior end of the middle turbinate and occasionally on other parts. Enlarged venules and occasionally small hæmorrhages may be found on the septum. The mucous membrane seems to be eroded in spots, and in the older cases the cartilage is exposed, or there may be a small circular perforation of the septum.

*In the more severe forms*, such as are found amongst workers using bichromate of potash, the disease commences as an ordinary acute rhinitis, but the discharge rapidly becomes purulent and blood-stained. The mucous membrane covering the anterior part of the septum ulcerates or sloughs, and the cartilages become necrosed ; severe epistaxis is frequent, and pieces of sloughing mucous membrane or necrosed cartilages may be found in the discharge. The bony septum is very rarely attacked, but small ulcers may appear on the inferior turbinates.

Arsenic may cause a similar affection, which is met with amongst the makers of wallpapers and artificial flowers, and, it is said, may even occur in people who inhabit rooms furnished with arsenical papers. Mercury, and especially the perchloride of mercury, may apparently act in the same way. In all these instances the poison simply acts as a local irritant and does not produce its effects constitutionally. The stream of air as it enters the nose impinges upon the anterior part of the septum and thus the dust or other irritants accumulate here and produce their effects:

**Treatment.**—*In the milder cases* of this affection the treatment consists in washing the nose regularly with a simple alkaline lotion, such as Dobell's solution (see p. 282), and spraying into it an oily solution, or the latter may be applied to the anterior part of the cartilaginous septum by means of a small camel's hair brush. For this purpose olive or almond oil containing one part in twenty of eucalyptus oil may be used.

*In the severer forms* the patient must be at once removed from the noxious influence, and treated on lines similar to those for the milder cases, when he will quickly recover, but more or less extensive permanent damage may have resulted.

**FIBRINOUS OR CROUPOUS RHINITIS.**—Until quite recently this affection was looked upon as simply a severe form of ordinary rhinitis, but it is now known to be a mild variety of nasal diphtheria. The disease is not uncommon, is found almost entirely amongst children, and is most prevalent in the autumn months. The nasal discharge and the membrane contain numerous Klebs-Löffler bacilli ; sometimes the latter are apparently in pure culture but in most cases staphylococci and streptococci are also present. Further, the bacilli are of full virulence. The disease differs from true nasal diphtheria in that the local necrosis is much less deep, and as a result it is possible that the toxins which are produced by the bacilli are not absorbed, or that absorption takes place so slowly that

anti-toxin is formed in the blood in sufficient quantity to counteract their effects.

**Symptoms.**—The child seems to have an ordinary head-cold, but the nasal obstruction on one or both sides is usually complete. The discharge in the early stages is profuse, clear and watery, but later it consists of thick, yellow matter, and is very often blood-stained; occasionally epistaxis is severe. The discharge is never fœtid, and in a few cases it may be very slight. There is more or less excoriation of the anterior nares and sometimes impetiginous crusts on the upper lip or the face. On examination, the nasal mucous membrane is usually found to be covered with a thin, whitish adherent exudation, which is strictly limited anteriorly to the nasal fossa proper, and never extends into the vestibule. Sometimes pieces of thick membrane can be removed as complete casts of the interior of the nose. In a few cases there is a film of exudation in the post-nasal space, and occasionally slight sore throat is complained of. The general symptoms are quite unimportant, and the disease runs a sub-acute or almost chronic course, varying in duration from three to twelve weeks. The prognosis is good; all the cases make a good recovery, and in none have paralytic sequelæ been noted.

**Treatment.**—It is most important to recognise the disease as early as possible and to isolate the patient. It is certain that these patients may be a centre of infection for similar diseases, and may also give rise to sore throats in others. Whether they ever give rise to an outbreak of true diphtheria is at present uncertain, but in any case there is no doubt that the patients should be isolated. The child as a rule need not be confined to bed, but requires a general tonic treatment: plenty of good food, rest, and drugs such as tinct. ferri perchlor., quinine or Easton's syrup should be prescribed. Locally, the nose should be frequently irrigated with a mild antiseptic lotion such as a solution of boracic acid (gr. xv. ad ℥j), permanganate of potash or sanitas with salt (see footnote, p. 297). Removal of the membrane and insufflations of iodoform, etc., are quite useless. If the vestibule or nostrils be at all excoriated, it is well to apply eucalyptus oil (one part in twenty of almond oil), or dilute nitrate of mercury ointment, made soft with almond oil and painted on all round with a small camel's hair brush. The children should not be allowed to return to the society of others until all bacilli have disappeared from the nose—as shown by bacteriological examination.<sup>1</sup> On theoretical grounds the diphtheritic anti-toxin should be of service in this affection, but I cannot speak of its value from personal experience: in the single case in which I had an opportunity of trying it, two doses produced no apparent effect.

<sup>1</sup> It is often sufficient to smear a little of the secretion on cover-glasses and then to fix and stain it with Löffler's methylene blue solution. The bacilli are commonly numerous and easily recognised. In doubtful cases the nose should be swabbed out with a sterilised mop, and a tube of Löffler's serum inoculated. This must be cultivated at a temperature of 37° C. and examined by cover-glass preparations in 12-24 hours.

## CHRONIC INFLAMMATIONS.

**CHRONIC CATARRHAL RHINITIS. Causes.**—This most commonly results from repeated or neglected colds, especially in those who suffer from impairment of the general health or who are repeatedly exposed to sources of local irritation. Amongst predisposing causes a very important one seems to be a tendency to narrowness of the nasal fossæ. Thus, chronic rhinitis is common in individuals with thin prominent narrow noses, such as the Jewish race. In children the affection is very frequently associated with adenoids and enlargement of the tonsils. Enlargement of the inferior or middle turbinates and hypertrophies or irregularities of the septum, cartilaginous or osseous, should also be sought for. The former are in most instances the result of catarrh, but when present they serve as prominent factors in maintaining it.

**Pathology.**—The mucous membrane covering the inferior turbinate bone, the floor of the nose and corresponding part of the septum is swollen, so that the inferior meatus is almost completely obstructed. The membrane is usually of a greyish pink colour and sodden-looking; occasionally, but rarely, it is deeply congested. The inferior turbinate appears as a smooth, uniform and globular swelling. It pits very readily with the probe, as if it were a bag filled with fluid, and the application of cocaine causes complete disappearance of the swelling, showing the absence of true hypertrophy.

**Symptoms.**—The patient complains of a muco-purulent discharge from the nose and more or less nasal obstruction. Associated with this there is usually some catarrh of the pharynx and larynx, with expectoration of muco-pus especially in the morning, and interference with the speaking and singing voice. There may also be chronic inflammation of the Eustachian tubes and middle ear.

**Results.**—If the disease persists, the nasal obstruction usually becomes more complete and permanent, true hypertrophy of the inferior turbinate supervening. This may lead to considerable trouble with the throat from mouth-breathing. Frequently the mental capacity of the patient is interfered with; he suffers from headache and inability to fix the attention, and in time the general health may become seriously affected.

**Treatment. Local.**—*In the more recent cases* it is often sufficient to prescribe a simple alkaline lotion for the nose, such as the following:

R Sodii bicarb.,	grs. 5
Sodii bibor.,	grs. 5
Sodii chloridi,	grs. 5
Glycerini,	℥xx.
Aquam,	ad ʒi.

One tablespoonful to be added to two of warm water, and to be sniffed up the nose every morning and evening, or used in any of the ways previously recommended (see p. 282). It is essential that the fluid should pass entirely through the nose into the throat and should return by the mouth.



For convenience the above lotion may be prescribed in powder or in tabloid form, sugar being substituted for glycerine. As tolerance is established it may be used stronger, until equal parts of the lotion and water are being used.

*In more chronic cases*, and in those in which the above treatment fails, the nasal lotion should be varied. A good effect will often be obtained by adding carbolic acid (2 grs. to the oz.) to the above prescription. In other cases chloride of ammonium (5 grs. to the oz.) or chlorate of potash (5 to 10 grs. to the oz.) may also be tried. Another lotion which is especially useful when the discharge is somewhat profuse is the following :

R    Spirit. vini. rect. } āā ʒj.  
           Glycerini boracis, }

One teaspoonful to two ounces of warm water to be used as a nasal lotion : or in very chronic cases it may be diluted with two parts of water and used as a spray.

Astringents, even very weak ones, are generally to be avoided, as the nasal mucous membrane is extremely intolerant of such applications. In a few obstinate cases with profuse discharge however the effect of *hazeline* as a lotion (10 to 15 minims of the tincture to the ounce of water) may be cautiously tried. If the mucous membrane becomes dry, the most useful treatment is to spray the nose twice daily with an oily solution, such as eucalyptus oil (20-40 minims to the ounce of almond oil); or a few drops of this may be allowed to fall into each nostril twice a day. This treatment is used in addition to the daily washing with simple alkaline lotion.

Should these means, aided by general treatment, fail, the best plan is to reduce the swelling of the mucous membrane by the aid of the galvanocautery or chemical caustics. The nose should be thoroughly anæsthetised and the congestion reduced by the application of cocaine or cocaine and suprarenal extract (see p. 285). Then any moisture should be removed by mopping with pledgets of absorbent wool. The electric cautery is to be preferred when obtainable. It is best to use a somewhat broad cautery-end and to make long linear cauterisations the entire length of the inferior turbinate. Care must be taken to avoid touching the septum, otherwise adhesions may take place between the opposed raw surfaces as healing occurs. To avoid this risk when the nostril is very narrow, it is preferable to use a sharp-pointed cautery and to plunge the point deeply into the swollen tissue of the anterior end of the inferior turbinate and to hold it there for a second : in this way shrinking of the swollen tissue is produced without much destruction of the mucous membrane, and consequently without risk of producing adhesions. The beneficial effect however is slower to appear in this deep method of cauterisation, and for the first few days there is frequently pain and increased disturbance.

Of chemical caustics, chromic acid, trichlor-acetic acid and nitric acid have the greatest reputation ; personally, I prefer the last-named. It should

be applied to the inferior turbinate by means of a small pledget of wool on the end of a probe. The nose should be previously cocainised, and, after applying the acid, the inferior meatus should be thoroughly wiped out and all excess of acid removed by pledgets of wool on a probe. By either of these means rapid improvement is commonly obtained, but they may require to be repeated at an interval of not less than a fortnight.

In a few cases, in which the nostrils are extremely narrow, it may be necessary to remove the anterior end or more of the inferior turbinate. This operation, which is known as anterior turbinectomy, will be fully described later (see p. 304). In all cases where hypertrophies or deflections of the septum are causing any marked obstruction these must be removed, for it is impossible to obtain a cure until the nasal fossæ are sufficiently patent.

**General.**—In addition to this treatment, suitable tonics, and especially the perchloride of iron (see footnote, p. 296) should always be prescribed, together with change of air, preferably to the seaside if it can be obtained.

**HYPERTROPHY OF THE INFERIOR TURBINATE.**—This is most commonly the result of chronic catarrhal rhinitis, especially when in association with other causes of nasal obstruction, such as adenoids, deflected septum, etc. It also frequently follows a succession of severe colds. It is found chiefly in those between twenty and thirty years of age, but it is not very uncommon in young adults or even in children, in association with post-nasal growths.

**Pathological changes.**—The inferior turbinate instead of being globular and smooth, as in simple chronic rhinitis, is sometimes finely, sometimes coarsely lobulated, giving it a papillary or cauliflower-like appearance. These hypertrophic portions are firm, do not indent easily with the probe, and do not shrink much under cocaine. In some cases large masses attached to the under surface or free border of the inferior turbinate are tucked away within its concavity, and thus are concealed from view until they are turned out with a probe. Similar hypertrophies may also be found growing from the floor of the nose, and from the lower part of the septum; they very frequently form a more or less symmetrical swelling on the posterior end of the septum. Either end or the whole length of the inferior turbinate may be involved. Histologically, these hypertrophied outgrowths are found to contain all the elements of the normal mucous membrane of this region, combined with an excessive amount of fibrous tissue.

**Symptoms.**—The symptoms are those of aggravated chronic rhinitis. The nasal obstruction is often complete and does not vary much with atmospheric conditions. The affection is generally associated with some pharyngitis, laryngitis, or Eustachian obstruction, etc.

**Treatment.**—It is obvious that surgical measures to reduce the hypertrophy will generally be required. When there is only slight hypertrophy associated with a large amount of vascular engorgement, treatment

in the first instance should be carried out exactly on the lines already prescribed for chronic rhinitis (see p. 300). The *cautery*, electric or chemical, is especially to be recommended, and may be applied as already described (see p. 301). If this fails, or if the nose be very obstructed, either because it is congenitally narrow or because the hypertrophy is excessive, some more radical means must be adopted to clear the nasal fossa. In doing this it must be borne in mind that in some cases hypertrophy of the inferior turbinate may be compensatory: that is, that the size of the inferior turbinate should bear a certain relation to the size of the nasal fossa. By the aid of a speculum it should be possible to see into the inferior meatus and alongside the septum for a third or more of the inferior meatus; but in the normal nose the post-nasal space should not be clearly seen. Thus, in a wide nose, a very large or even an hypertrophied inferior turbinate may be present, and it would, nevertheless, be unwise to attempt to remove or to reduce it. On the other hand, in

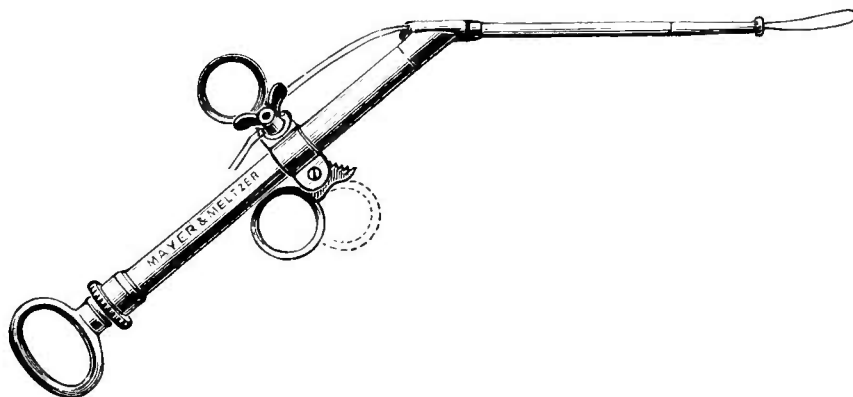


FIG. 110.—LACK'S SNARE.

a narrow nose a very slight hypertrophy may require to be freely removed in order to establish free nasal respiration.

**Operation.**—In the majority of these cases removal with a *cold wire snare* is to be preferred. The part to be removed having been thoroughly cocaineised (see p. 284), the loop of the snare is passed around it, and the wire tightened quickly so as to obtain a firm hold on it. Subsequently it is better to tighten the wire as slowly as possible in order that the vessels may be obliterated as they are divided and the risk of hæmorrhage lessened. The best snare for this purpose is shown in Fig. 110. It has the great advantage that it can be tightened up very quickly with one hand, whilst a view can be obtained of the parts to be enclosed; at the same time the snare will carry a thick wire and is strong enough to stand a great strain, for it must be remembered that these growths are frequently very tough. It may be necessary to snare off several pieces, and the operation should be repeated until all redundant growth has been removed and the inferior meatus allows of the free passage of air.

*After-treatment.*—The nose should be cleansed after the first 24 hours with a cold solution of boracic acid or an alkaline lotion (see p. 282), which

should be very gently syringed, or poured into the nose with the nasal irrigator (see p. 283). No attempts should be made to sniff it up, and if it cause irritation its use should not be persisted in. All violent attempts at sneezing or blowing the nose should be prohibited for fear of causing secondary hæmorrhage. For the same reason all food for the first 24 hours should be given quite cold, and no hot drinks should be allowed for at least a week. If the operation be performed in the way mentioned, secondary hæmorrhage is extremely rare. It is more liable to occur if suprarenal extract has been used, and consequently in such cases, if the patient be not under immediate observation, the nose should be packed for a few days (see p. 286). Should hæmorrhage occur, it is best to apply iced lotion to the nose and the patient should lie down quite quietly and suck ice; a few drops of iced lotion may also be allowed to trickle into the nose. Should this not be effectual, the nose should be plugged with strips of dry gauze, and if the posterior end of the inferior turbinate be affected, the post-nasal space must also be plugged either by means of gauze or a Cooper Rose bag.

**Treatment of cases associated with undue narrowness of the nasal fossa.**—In many cases, especially in patients with narrow noses, there is so little room between the bony part of the anterior end of the inferior turbinate and the septum that it is necessary to do more than this, and to remove at least a portion of the bone of the inferior turbinate. As already seen, the nasal fossa is boat-shaped (see p. 265), both the anterior and posterior parts of it being narrower than the centre; it therefore follows that in many cases the larger middle part of the nose may be opened up and free nasal respiration established by removing the anterior end of the inferior turbinate, and that therefore it is generally unnecessary to remove the whole of that structure.

*Anterior turbinectomy.*—Anterior turbinectomy is thus performed. Either cocaine anæsthesia, gas, or gas and oxygen may be employed, the last being preferable in nervous patients. In any case it is well to apply a solution of suprarenal extract with cocaine (see p. 285) to the nose 15 to 20 minutes before the operation. This not only diminishes the hæmorrhage from the operation, but, by producing contraction of the tissues, enables a better view of the part to be obtained. The patient should be seated in a dental chair, and a good light must be thrown into the nose. The operation may be performed with a pair of stout nasal scissors, such as Panza's (see Fig. 111), or with a nasal saw, and completed with the snare or spokeshave. If the scissors be used one blade is passed down the inferior meatus under the inferior turbinate and then about half an inch of the anterior part of the bone is cut through longitudinally (see Fig. 112). In some cases this piece may be entirely detached, but in the majority of cases the attachment of the inferior turbinate to the outer wall of the nose is alone divided. The wire of a strong snare is passed along the slit thus made and the isthmus of the turbinate snared off (see Fig. 112); instead

of using a snare the semi-detached anterior end of the turbinate may be removed with the spokeshave. Even if this latter instrument be used, it

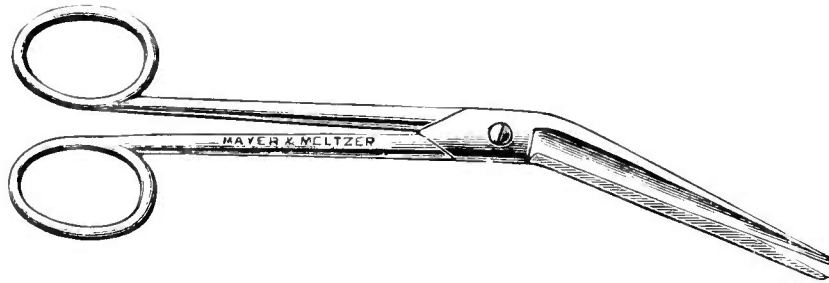


FIG. 111.—PANZA'S SCISSORS FOR ANTERIOR TURBINECTOMY.

is still advisable to make the cut with the scissors as above recommended, as otherwise the piece may remain hanging by a shred of mucous mem-

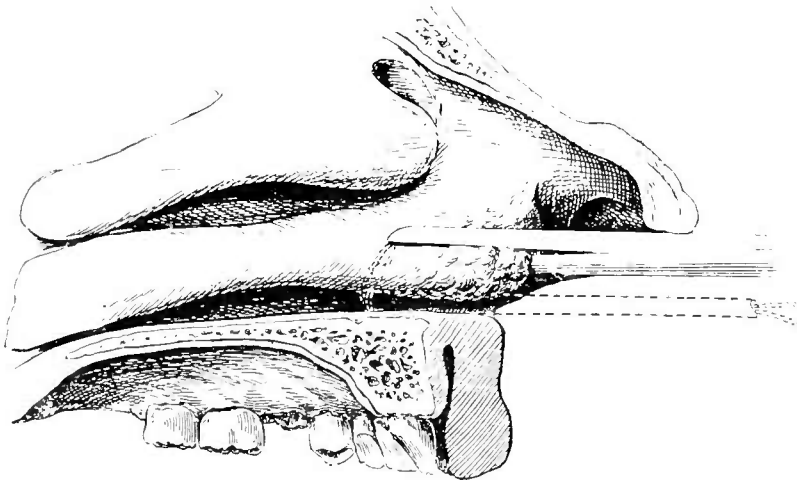


FIG. 112.—REMOVAL OF THE ANTERIOR END OF THE INFERIOR TURBINATE. The sketch shows the position of the scissors and the usual amount of tissue that it is necessary to remove. The dotted lines indicate the position of the snare that is applied after the scissors have been used.

brane. The after-treatment is similar to that already described (see p. 303). On looking into the nose after healing has taken place it is possible to

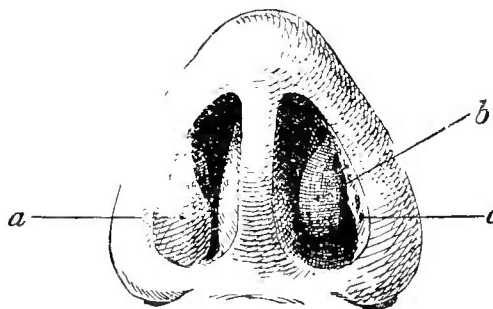


FIG. 113.—RESULT OF REMOVAL OF THE ANTERIOR END OF THE INFERIOR TURBINATE. In the right fossa the normal inferior turbinate is seen. In the left, the outer part of the inferior meatus as opened up by removal of the anterior extremity of the turbinate is shown. *a*. Right inferior turbinate; *b*. left inferior turbinate; *c*. outer part of inferior meatus.

see quite into the middle of the inferior meatus, which now appears to be divided into two portions by a narrow inferior turbinate (see Fig. 113). Thus the large concavity under this bone is opened up to respiration.

*Removal of the posterior end of the inferior turbinate.*—For this operation it is usually advisable to give a general anæsthetic; gas may be used if only one turbinate be affected, but if both sides require to be operated upon, an anæsthesia of three or four minutes' duration is required. The bone at the posterior extremity of the inferior turbinate is usually very small, and consequently soft parts alone require to be removed. This can be best accomplished with a snare.

The patient being anæsthetised, is turned on to his left side, and, the surgeon standing always on the left side of the patient, passes his left

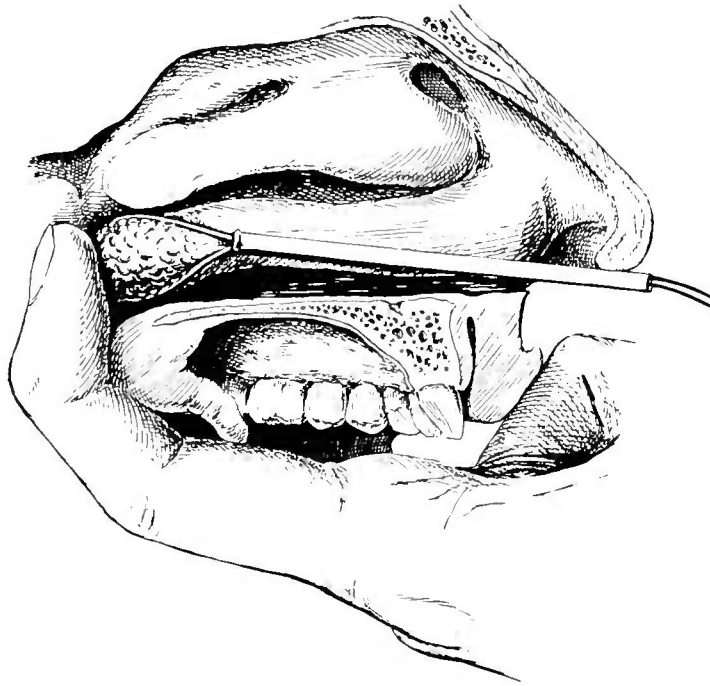


FIG. 114.—REMOVAL OF THE POSTERIOR END OF THE INFERIOR TURBINATE. Showing the loop of the snare in position, and the method of holding it with the finger.

forefinger up into the post-nasal space. The wire loop of the snare is then passed down the inferior meatus of the side to be operated upon until it comes in contact with the finger in the post-nasal space. If the nostril be considerably obstructed it is advisable to use a stiff wire and a small loop which can afterwards be opened out by the finger. This loop is hooked round the posterior extremity of the turbinate and held in position by firm pressure with the finger (see Fig. 114). The handle of the snare is bent over to the opposite side so as to press the point of the snare well into the mucous membrane of the turbinate. The wire is then rapidly drawn tight until a firm hold is obtained, after which it should be tightened as slowly as possible until the parts are cut off. It is a good plan when both sides are being operated upon to tighten up the wire on one side and then to leave it in position while the other side is being similarly treated. In this way, if three, four or more minutes be taken to tighten the snare, even very large masses can be removed with the loss of a very few drops

of blood. This is important, not so much because the loss of blood might prove serious, as because it adds greatly to the danger of the anæsthetic. For after-treatment see p. 303.

*Removal of the whole of the inferior turbinate.*—This operation is very rarely required. In the large majority of cases it is far better to proceed on the lines already indicated, removing the anterior extremity of the turbinate by anterior turbinectomy, and the posterior with the cold wire snare. In this way as much of the inferior turbinate body as possible is preserved intact—a point of no little importance (see p. 303). But in a few cases the whole length of the inferior turbinate is covered by papillomatous growths which completely fill the inferior meatus, and then nothing short of removal of a portion of its entire length will suffice. This is best

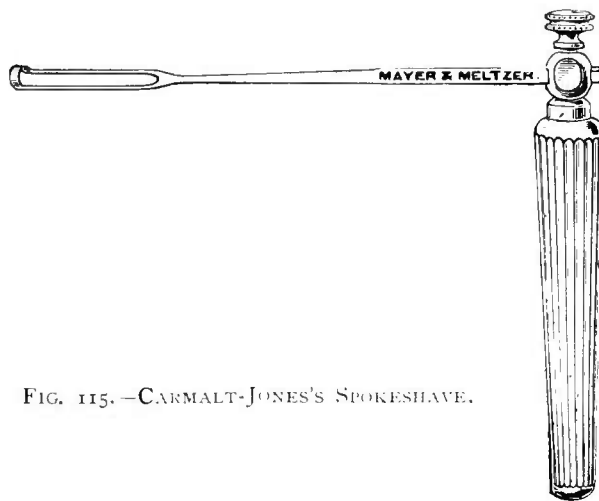


FIG. 115.—CARMALT-JONES'S SPOKESHAVE.

accomplished by means of the spokeshave (see Fig. 115). The operation is extremely easy and can be rapidly performed. The great objection to it is that there is no means of accurately regulating the amount of the inferior turbinate that is removed. It is best to give a general anæsthetic, but gas alone, or gas followed by a little ether is usually sufficient. It is best to operate with the patient sitting, but if lying down he must be turned over well on to his side. The surgeon stands on the left side of the patient and passes the spokeshave through the inferior meatus into the post-nasal space, and then, guided by the finger, hooks it on to the posterior end of the inferior turbinate with the convex side of the knife towards the part to be removed. The instrument is now dragged forcibly forwards and a large piece of the inferior turbinate is easily detached and brought away. Both sides of the nose may be operated upon at the same time. Hæmorrhage is usually profuse, and means for rapidly plugging the post-nasal space should always be at hand. A good plan is to retain the finger in the post-nasal space and pass a long strip of gauze back through the inferior meatus so as to tightly plug the whole nose. For other details of after-treatment see p. 303.

The *results* of this operation are on the whole good. Of course it

always leads to patency of the nostrils,—often to undue patency,—and for some months afterwards the patient may suffer from dryness of the mucous membrane, which is not limited to the nose, but extends to the post-nasal space, the pharynx and the larynx. This however generally yields in time, and should be treated on the lines laid down for the treatment of rhinitis sicca (see below). In a few cases however a condition not unlike atrophic rhinitis has been produced, and therefore the operation is not one to be lightly decided upon, especially if the patient be a professional voice-user.

**RHINITIS SICCA.**—Rhinitis sicca consists essentially in a dryness of the mucous membrane of the nose, and is met with in two entirely distinct conditions.

**Varieties and Causes.**—In the one form, the mucous membrane of the nose is congested, swollen and red, and small blackish crusts are seen on the septum, on the middle, and occasionally on the inferior turbinate. This form is most common in men about middle life, and especially amongst those addicted to alcohol: in some cases it is associated with gout. Women may be affected under similar conditions.

In the other form, the dryness of the mucous membrane is associated with considerable anæmia, both local and general. It is most common in weakly women and especially in those who suffer from dyspepsia, constipation and similar troubles. In both forms, the affection is aggravated if the patient be exposed to unfavourable local conditions, such as the inhalation of dust, flour, etc., or by dwelling in unventilated, hot, overcrowded rooms.

**Pathological results.**—There is a special tendency for the crusts to be deposited on the anterior part of the septum, and these the patient is very apt to remove with the finger or by violently blowing the nose. As the crusts adhere firmly, their detachment causes excoriation of the mucous membrane, and in this way the epithelium becomes injured, the crusts adhere still more firmly and actual ulceration may occur. The epithelium, as it is reproduced, tends in time to lose its cilia, and to become more squamous in form. If the source of irritation still continue, the picking at the nose will produce a deeper ulceration which will soon affect the perichondrium; even the cartilage may be gradually eaten away, and perforation of the cartilaginous septum may occur. This perforation is at first quite small, but the crusts continue to adhere to its edges and it consequently enlarges until it may become the size of a sixpence or even larger, but the bony septum is never attacked.

Another result of rhinitis sicca is *epistaxis*, which is due to detachment of crusts from the excoriated surface of the septum. Enlarged venules are often seen crossing the affected area and a tiny blood-clot may be found, the removal of which will at once produce bleeding. Epistaxis is exceedingly frequent, being repeated daily or even oftener but usually only to a small amount.



**Symptoms.**—The patient usually complains of a considerable amount of nasal irritation, stiffness of the nose, pricking pains and nasal obstruction. These are commonly associated with laryngeal and pharyngeal affections, such as a constant tickling cough, hoarseness, and a feeling of constriction or of a lump in the throat. The crusts in the nose are always small and are never the large thick masses seen in ozæna.

**Treatment.**—The treatment must be both constitutional and local.

(a) **General.**—If the rhinitis be associated with a plethoric condition, the patient's diet and general habits must be carefully regulated. The amount of alcohol consumed must be strictly limited, beer and heavy wines being entirely interdicted. Smoking also should be indulged in but moderately, cigarettes being especially harmful. The diet should consist of light easily digestible meats and fruits.

In most cases the medicinal treatment should be commenced with a daily morning glass of one of the aperient waters, such as Hunyadi Janos, Carlsbad, or Apenta; or if constipation be present, the *Mist. Alba*<sup>1</sup> in doses of ʒj-ʒij taken in a tumbler of warm water may be substituted. Subsequently a rhubarb and soda mixture may be prescribed. In gouty subjects appropriate diet and medicines must be ordered.<sup>2</sup>

In the anæmic subject constitutional treatment is also of the greatest importance. In the first place the diet should be plentiful, light, and nutritious. Plenty of fresh air, a change to the sea-side if possible, with suitable outdoor exercise should always be ordered. Any digestive disturbance must be carefully enquired into and appropriate remedies prescribed. In most cases constipation is present, and a pill should be given daily after dinner or on retiring at night. *Pil. Aloes et Ferri*, or *Pil. Aloes et Myrrh* in ʒ gr. doses may be tried, or the following prescription is often especially useful:

R	Ferri redacti,	gr. ii.
	Aloini,	gr. ʒ.
	Ext. nucis. vom.,	gr. ʒ.
	Ext. belladonnæ,	gr. ʒ.

After the digestive functions have been attended to, iron should be prescribed in full doses: *Blaud's pill* in xv.-xx. grain doses three to four times a day after meals, *Easton's syrup*, or the mixture of perchloride of iron recommended on p. 296 may be used.

<sup>1</sup>The *Mist. Alba* contains: *Magnes. sulphatis* ʒj, *magnes. carbonatis*. gr. xx., to the ounce of peppermint water.

<sup>2</sup>The following prescription may be used:

	<i>Sodii salicyl.</i> ,	gr. x.
	<i>Salicini</i> ,	gr. v.
	<i>Potass. bicarb.</i> ,	gr. x.
	<i>Spirit. chloroformi</i> ,	m. xx.
	<i>Inf. calumbæ</i> ,	ad ʒ ss

One tablespoonful three times a day before meals.

(b) **Local.**—The local treatment must be conducted on similar lines in both forms of the affection. In the first instance it is best to cleanse the nose with a non-stimulating alkaline solution, such as a solution of borax, soda and salt (see p. 300); this can be used two or three times a day. In all severe cases it should be followed up by the application of an oily solution; eucalyptus oil (one part to twenty of almond oil), may be applied by means of an atomiser (see p. 284), or painted on the anterior parts of the nose with a camel's hair brush. The thorough application of the oil to the anterior part of the septum is one of the most essential points in the treatment of cases of commencing ulceration. It prevents the adherence of crusts and consequently arrests the ulceration, avoids perforation, and cures the epistaxis. Should this simple lotion not cure the dryness, various additions may be made to it. Carbolic acid (1-2 grains to the ounce), may be added; or ammonium chloride (5 grains to the ounce), the latter especially being very useful. Also an inhalation of cubebs (see p. 428) may be tried, especially when the dryness in the nose is associated with marked laryngeal and pharyngeal symptoms. It is also often necessary to wash out the naso-pharynx; this may be performed either with a post-nasal syringe or a spray.

In obstinate cases when there is a constant tendency to clear the throat and to hawk up phlegm from the back of the nose, associated with a marked formation of tenacious crusts in the post-nasal space, the throat should be well swabbed out once every day with a brush or a pledget of wool dipped in Mandl's solution. This solution contains Iodine, gr. vj., Potass. Iodid. gr. xx., Ol. Menth. Pip. m. vj. to the ounce of glycerine. For the cough and dryness of the throat carbolic acid or borax lozenges may also be prescribed and will often give great relief.

Should this treatment fail, means to give rest to the mucous membrane should be adopted. This is easily obtained by plugging the nostrils with cotton wool and insisting upon mouth breathing. In this way, the air not being able to enter the nose, the secretion remains fluid and the crusts rapidly disappear. It may however be necessary to persist with the treatment for many months. In some cases the patient will always require to wash out the nose occasionally, and in such circumstances sodium chloride (one drachm to the pint of warm water) is the simplest and best lotion.

*When one nostril is obstructed.*—When one nostril is obstructed, the opposite side of the nose, if at all wide, does double work, and is consequently very likely to become dry. In these cases the question of operation occurs, and is somewhat difficult to decide, as there is always a certain tendency to dryness after intra-nasal operations. It is generally advisable however to adopt means to clear the obstructed nostril, whether the obstruction be a deflected septum, a spur on the septum, or a hypertrophy of the turbinates. As much as may be necessary, though as little as possible, should be done to clear the nose, and then it will be well to rest the

nasal mucous membrane for a short time, after which recovery will usually ensue.

(c) **Of epistaxis.**—As already indicated, the prophylactic treatment of epistaxis consists in the prevention of the formation of crusts on the septum by the application of oily preparations (see p. 284), and in the avoidance of trauma, such as picking the nose, etc. By the assiduous employment of such remedies epistaxis may be entirely prevented. Should a case be seen while the bleeding is still active, it will probably be found to come from a spot on the septum. The bleeding may be at once arrested by inserting a strip of gauze or wool, covered with ointment, into the affected nostril and firmly closing the anterior nares over it; thus direct pressure will be made upon the affected part. The patient may be instructed to carry this out for himself. When the bleeding is only slight, and the means are at hand, the electric cautery may be applied to the bleeding point and the vessel sealed. In all cases of repeated epistaxis, in which enlarged veins are seen traversing the excoriated area of the septum, it is well to obliterate them by a few touches of the cautery.

(d) **Of perforating ulcer of the septum.**—When ulceration of the septum has occurred, the treatment of the rhinitis must be energetically carried out on the lines already laid down, in order to induce it to heal, and to prevent perforation occurring. When once a perforation has formed nothing can be done to make it close; on the other hand, it will continue to spread unless the dryness and crusting of the mucous membrane be prevented. In these cases the crusts have a special tendency to adhere to the edges of the perforation, and therefore the patient must be carefully instructed to apply the oil or ointment to the margin of the ulcer with a brush, and this must be continued regularly, until the edges of the perforation have soundly healed.

**ATROPHIC RHINITIS.**—The essential features of atrophic rhinitis or *ozæna* are an intensely *fetid, crusty, muco-purulent* nasal discharge, and *abnormal patency* of the nasal fossa, due, in most cases, to the small size or almost complete disappearance of the inferior turbinate bodies.

**Causes.**—The etiology of the disease is by no means agreed upon. This much however is certain that the secretion, as it forms, is fluid, and the formation of crusts depends upon its prolonged exposure to the air current, aided by the extreme patency of the nostrils. The fœtor entirely depends upon the decomposition of this discharge, due to its long retention in the nose and exposure to the action of putrefactive bacteria. The retention of the discharge in the nose is due partly to the abnormal patency of the nostrils diminishing the *vis a tergo* in blowing the nose, partly to the adhesiveness of the crusts, and partly to pathological changes in the mucous membrane, and especially in the ciliated epithelium, as described below. The abnormally large size of the nasal fossæ is probably in part congenital, for the disease is often hereditary and associated with a peculiar physiognomy; the patient's head and face are broader than

normal, the cheek bones high, the nose broad and stumpy, scarcely projecting at all in profile, and the wide, round nostrils look forward as well as downwards. The extreme patency of the nostrils is further increased by the small size of the inferior turbinates: this is due to the fact that, as the disease usually commences in early life, the turbinates never develop properly, but retain their infantile characters, and in part may be due to actual atrophy. The discharge, in the majority of cases, is mainly derived from the general mucous membrane of the nose. In a few cases ozæna is complicated by suppuration in one of the accessory sinuses, but the latter must be regarded as a supplementary and not as the main source of the discharge.

It is most probable that the affection starts in infancy or early childhood as a purulent rhinitis, probably of an infectious nature. Careful inquiries show that the disease may be often dated back to one of the specific fevers, such as measles, scarlet fever, etc. These forms of rhinitis in childhood are accompanied by a rapid proliferation of the ciliated surface epithelium, which in consequence tends to revert to an original simpler type, gradually losing its cilia and becoming squamous. An abnormally wide nasal fossa increases the difficulty in removing the discharge both by diminishing the *vis a tergo* in blowing the nose and by aiding the tendency of the discharge to dry and become tenacious. The crusts adhering firmly still further damage the mucous membrane and also form an excellent nutrient medium for the development of organisms: the latter by their growth cause decomposition and the formation of irritating products, which still further excite secretion and thus a vicious circle is established.

Various predisposing circumstances probably play an important part in the development of the disease, the most important of which are impairment of the general health due to the severity of the original infection, total neglect of the nasal disease in its early stages and an inherited tendency to the affection. This is the etiology in the large majority of cases, but in a few the affection may be the result of inherited or tertiary syphilis. Extensive ulceration and necrosis of the inferior turbinate will leave an abnormally wide nose lined by scar tissue and squamous epithelium, and in it purulent crusts may accumulate.

**Pathology.**—The changes of chief importance are those occurring in the inferior meatus of the nose. The mucous membrane over the inferior turbinate is shrunken, firm and adherent to the bone, and in many cases the bone itself is very small and may form a mere ridge along the outer wall of the nose. The histological changes in the mucous membrane must be briefly referred to as they probably account for the intractability of the disease. The columnar ciliated surface epithelium is found to be almost entirely replaced by the squamous form. The mucous glands are partly destroyed, are few in number, and those remaining are frequently degenerated. The vascular plexuses are for the most part obliterated and the entire mucous

membrane is much more fibrous than normal, and is infiltrated with masses of round cells. The bone itself shows no changes. The middle turbinate may appear shrunken, but is usually normal: on the other hand it is occasionally hypertrophied or polypoid. The general health is often robust, but in most adults there will be found some degree of anæmia or dyspeptic troubles. In others there is evidence of inherited or acquired syphilis. Remote local troubles, such as ear and throat affections, are not uncommon.

**Treatment.** (a) **Local.**—The first essential in the treatment of ozaena is to thoroughly cleanse the nose and to prevent the re-formation of the crusts. The nose should be syringed, and, to ensure the thoroughness of the cleansing, this is best performed, at any rate for the first few days, by the surgeon himself. It matters little what lotion is used for this purpose: perhaps the best is a solution of ordinary salt (a drachm to the pint), with the addition of one part in twenty of sanitas, or of about twenty grains of permanganate of potash to the pint. After the nose has been syringed, its interior should be illumined and every part carefully inspected. If crusts still remain, the washing must be repeated, or if there be only a few crusts they may be gently removed with a pair of forceps, or detached with a pledget of wool on a probe. If the wool be dipped in peroxide of hydrogen solution (1 vol. in 10) it will be found very effectual in loosening the crusts. It is well after thoroughly syringing the nose to gently rub the surface all over with pledgets of wool; this is slightly irritating to the mucous membrane and increases the secretion; also it is probable that the orifices of the glands are emptied by gently rubbing the membrane, and thus a more effectual cleansing is obtained.

The nose must now be packed with a long strip of cyanide gauze, the gauze being first washed in sterilised water or salt solution. The packing should be left in position for from eight to twelve hours, when it may be removed by the patient, the nose again syringed and the packing re-applied. It is essential that the surgeon himself should carry out or supervise this treatment until the patient or an attendant has learnt to carry it on satisfactorily.

The mouth-breathing necessitated by this treatment is at first often very unpleasant, especially at night, and may prevent the patient sleeping: he will soon however tolerate it, and will then gladly persist in the treatment on account of the great relief which it affords.

Many patients experience great difficulty in thoroughly packing the nose, but, providing that they will insert enough gauze to entirely obstruct the nostril and prevent the entrance of air, the treatment will be effectual, although it is better to thoroughly fill the nose. In most cases there will be sufficient secretion to prevent the gauze from becoming adherent; but should there be any difficulty in removing it, or should the removal produce bleeding, the nose may be sprayed with oil before the packing is

introduced, or the gauze itself may be moistened with oil or glycerine. For this purpose eucalyptus oil (one part to twenty of almond oil), may be used.

If treatment be carried out in this way it is immaterial what lotions are used. In spite of the numerous drugs which are daily being recommended, ordinary salt solution is as effectual as anything. Neither does it matter what wool or gauze is used to plug the nose, and the addition to it of various medicaments, such as iodoform, boracic acid, ammonium-chloride of mercury, etc., apparently makes no difference.

So long as this treatment is carried out, the secretion as it forms is and will remain fluid, and consequently can easily be washed away by the patient, and the fœtor, which depends upon the decomposition of the secretion, will be entirely prevented. Thus, from the very commencement of treatment the patient is freed from the worst symptoms of the disease.

This treatment requires to be continued for many weeks, or more often for many months. Then the packing may be tentatively abandoned, and, if the symptoms do not recur, may be entirely left off, but the daily washings can rarely be omitted. In a few cases, especially in the more recent cases in children and in those in whom the nostrils are not very wide, a complete cure may be obtained, but in the majority of cases alleviation alone is possible. In well-marked cases the nose will always remain wide and dry, and there will be a tendency to the return of the symptoms at any time, should the patient be exposed to infection or take cold. But, as a rule, even in those cases in which there is almost complete atrophy of the mucous membrane, the symptoms can be entirely kept in check or limited to a mere dryness of the mucous membrane with the formation of small mucous non-fœtid crusts, by the daily use of an alkaline nose-wash.

The various methods of stimulating the mucous membrane, as by the application of irritating ointments or powders, or the use of electrolysis, are probably useless. The last mentioned has been highly extolled, but its value is not yet definitely established. The only treatment of this kind which apparently does good is the rubbing of the mucous membrane—the so-called “Massage”—with pledgets of cotton wool on a probe, and this probably acts by producing a more thorough cleansing of the nose rather than by increasing the nutrition of the mucous membrane.

In some cases of atrophic rhinitis the disease is unilateral. In all these cases the septum will be found deflected to the opposite side, or the affected nostril blocked in some other way. If the obstruction be complete, an operation may be undertaken for its removal, care being taken not to make the nostril too wide, or the disease may arise on this side also. But, if one nostril be very wide and the other completely blocked, by clearing the obstructed nostril the widened one may be relieved of part of its double duty and thus its cure assisted. Also should polypi, or great enlargement

of the middle turbinate be present, they should be removed. It has often been objected to this that such obstructions are beneficial, since the nostril is already too wide, but inasmuch as they are products of disease and may be sources of irritation and may maintain the discharge they should always be removed.

In all cases of ozæna in which there is the least reason to suspect suppuration in any of the accessory sinuses, these cavities should always be explored. The maxillary and the sphenoidal sinuses are by far the most commonly affected. There is never any harm in puncturing the antrum from the inferior meatus, and in many cases the opening of the sphenoidal sinus can be seen through the widened nostril, and a suitably curved cannula can be introduced into the opening and the sinus washed out. Should such a complication be found suitable treatment should be adopted (see p. 341, *et seq.*).

(b) **Constitutional.**—Constitutional remedies are generally required. Of these, change of air, especially to a bracing seaside resort, is probably of the greatest benefit; cod-liver oil, iron, etc., are also frequently indicated. But it is a fact that children with this disease are commonly in robust health. Where tertiary syphilis is present, or even suspected, anti-syphilitic treatment must be adopted. The disease may be the result of inherited syphilis, and although specific treatment will have no direct effect upon it in its later stages, still it may often be adopted with advantage in cases in which the inherited taint has never been eradicated.

**NASAL POLYPUS.**—The ordinary mucous polypus of the nose is of inflammatory origin. It is essentially an œdematous infiltration of the mucous membrane, due to disease in the underlying bone.

**Structure.**—Polypi mainly consist of a loose, reticulated tissue which in parts may have undergone myxomatous degeneration. The meshes of the tissue are distended with serum. Throughout the growth are masses of round-celled infiltration and numerous blood-vessels, glands, etc., similar to those in the normal mucous membrane. Its surface is more or less completely covered by epithelium, and at its edges the growth passes imperceptibly into the normal mucous membrane.

**Site of origin.**—Polypi generally spring from the concavity of the middle turbinate, from the lower part of the infundibulum, the uncinatè process or the bulla ethmoidalis. Next in frequency they arise from the long free border of the middle turbinate. Very rarely indeed are they attached to the roof of the nose or to the septum, and never do true polypi arise from the inferior turbinate.

**Tendency to recur.**—These growths have a most marked tendency to recur after removal. This depends in part upon the fact that their site of origin is commonly very inaccessible, and consequently, after all the visible polypi have been removed from the nose, others may still be packed away in the recesses under the middle turbinate and may rapidly enlarge and develop after pressure has been removed. I believe, however, that

true recurrence is at least equally common, and depends upon the fact that polypi are only symptoms of bone disease.

**OSTEITIS AND PERIOSTITIS OF THE ETHMOID.**—The mucous membrane of the nose in the ethmoidal region being practically continuous with and inseparable from the periosteum, the latter is always affected in any acute inflammation of this region, especially in the severer forms met with in the specific fevers, influenza, erysipelas, etc. When this occurs the cells in the deeper layer of the periosteum proliferate, the membrane becomes thickened, and the subjacent bone is attacked by large cells (osteoclasts) which gradually eat it away. In places periostitis may be producing thickening of the bone, while in other places absorption is taking place. If the middle turbinate be affected, there is seen in the early stage an enlargement at part of the bone chiefly due to œdema and hypertrophy of the overlying soft parts. Simple removal of this œdematous tissue is rapidly followed by recurrence, but if a large piece of the underlying bone be also removed a cure will be effected. This localised œdema of the mucous membrane passes by insensible gradations into a typical nasal polypus.

When the disease spreads, the middle turbinate may be entirely disorganised, and the greater part of the ethmoid may be broken up. An examination in this stage will show the whole upper part of the nose filled by a large gelatinous mass of polypi, polypoid growths and degenerated mucous membrane, in which crumbling fragments of bone may be detected. Frequently, but by no means invariably, this is accompanied by suppuration, most usually in the ethmoidal cells, sometimes also in the other sinuses.

**Clinical features.**—Polypi may occur at any age, but are rare in children and are most common between 20 and 30. They may affect one or both nostrils, and vary from the size of a pea up to a mass two or three inches long, which may entirely fill and distend the nostril and project both into the anterior and posterior nares. Commonly three or four, and occasionally six or even more polypi will be found in one nostril. They may be completely pedunculated or broadly sessile; in fact, there is every gradation between a simple swelling or localised œdema of the mucous membrane and a well-developed pedunculated nasal polypus. The most prominent symptoms are the nasal obstruction with its remote effects upon the throat and ear, headache and inability to fix the attention, and commonly a profuse nasal discharge, in some cases clear and watery, in others, purulent. In the latter case accessory sinus disease must always be suspected.

**Treatment.**—It is obvious that the treatment of the polypi cannot be dissociated from that of the disease of the bone, and for purposes of description it is convenient to recognise three stages—(1) the stage of commencing bone disease, with simple œdema of the overlying mucous membrane, such as causes enlargement of the anterior end of the middle turbinate and turbinal cysts; (2) the stage of simple polypus-formation



with a limited extent of osteitis: and (3) the stage of extensive polypoid degeneration of the mucous membrane with extensive disintegration of the ethmoid.

**1. In simple cases of enlargement of the anterior end of the middle turbinate,** it is best to remove the affected part and thus to cut short the disease. The application of the cautery, so commonly recommended, is calculated to do only harm. Amputation of the anterior end of the middle turbinate is thus effected:

The nose having been thoroughly cleansed and cocainised (see p. 284), a good light is thrown into it and the middle turbinate is divided behind the part to be removed. This may be accomplished with a pair of nasal scissors, such as Symonds's, or better still with Grünwald's punch forceps (see Fig. 116). One blade of the forceps is applied under the middle turbinate and the other passed between the latter and the septum, and thus a large notch is made in the free border of the bone (see Fig. 117, *A*).

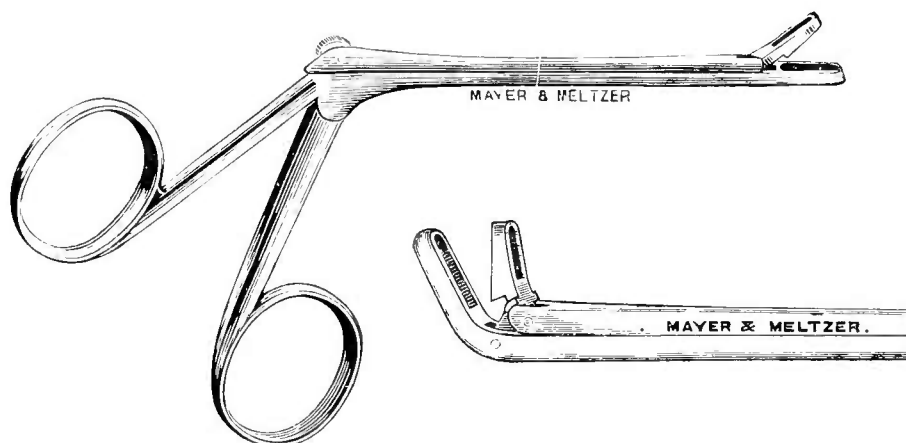


FIG. 116.—GRÜNWARD'S NASAL CUTTING FORCEPS for opening the ethmoidal cells, etc.

Into this notch the wire of a snare is passed; the tip of the snare is pressed well up against the anterior end of the middle turbinate and the wire tightened. In this way, half, or more if required, of the anterior part of the bone may be easily and safely removed. It is sometimes recommended to divide with curved scissors the attachment of the anterior end of the bone to the outer wall of the nose, and to complete the operation by removing the isthmus thus produced with the snare, as in anterior turbinectomy (see p. 304), but this is a far more difficult manipulation than the proceeding just advocated.

When it is desired to remove the posterior end or the whole of the middle turbinate it is best to use the spokeshave, and to operate under general anæsthesia; nitrous oxide is usually sufficient for this purpose. The operation is very easy, and is similar in all essentials to that already described for removal of the inferior turbinate (see p. 307). As much of the bone as possible should be taken away, as there is in this case no risk of leaving a too patent nostril.

In cases in which there is troublesome bleeding, the nose should be packed, but generally hæmorrhage, although rather brisk at first, soon ceases, and there is no need to adopt any special means to arrest it. After the first 24 hours the nose should be irrigated daily until healing has taken place. The result of this operation, provided it be done in suitable cases, is extremely satisfactory; healing is complete in from ten to twenty days, and, the whole of the disease being removed, no further trouble ensues.

**2. In the second stage,** it is well to remove the polypi with the snare. This operation, done under local anæsthesia, is extremely simple, and is far less painful than any other method of removing polypi. There

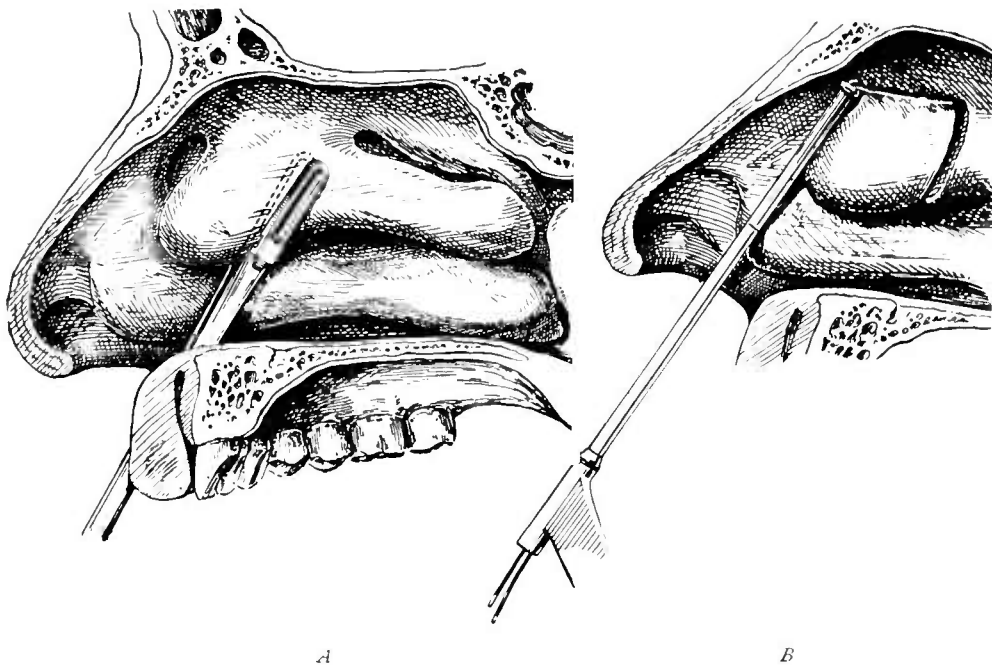


FIG. 117.—REMOVAL OF THE ANTERIOR END OF THE MIDDLE TURBINATE. *A* shows the application of the cutting forceps and the position of the incision; *B* shows the position in which the snare is applied to the isthmus formed by the use of the forceps.

is a large choice of instruments, most of which have some special advantage. MacKenzie's snare (see Fig. 118) works steadily and therefore painlessly and is easy to manipulate, but has the great disadvantages of being very difficult to sterilise or clean; it makes a disagreeable clicking noise; it is somewhat tiresome to replace the wire, which is damaged after being used once or twice; further it will only act well with a thin wire. Another excellent snare is Blake's (see Fig. 119), which is especially valuable in nervous patients as it works quietly and quickly, and in cases of small polypi situated high up in the nose. It is a slender instrument and not strong enough for tough growths. It should be threaded either with very fine wire or with gimp, and causes the least pain of all. Krause's snare (see Fig. 144), or the one recommended previously with its slender shaft attached (see p. 303), may also be used. The two last have the advantages

of being very strong; the wire loop can be easily withdrawn and replaced; a thick wire can be used, and the operation can be rapidly completed. The shaft of Krause's snare is a little clumsy.

In passing the wire of a snare round a polypus, the loop should be inserted vertically, either between the polypus and the septum or between

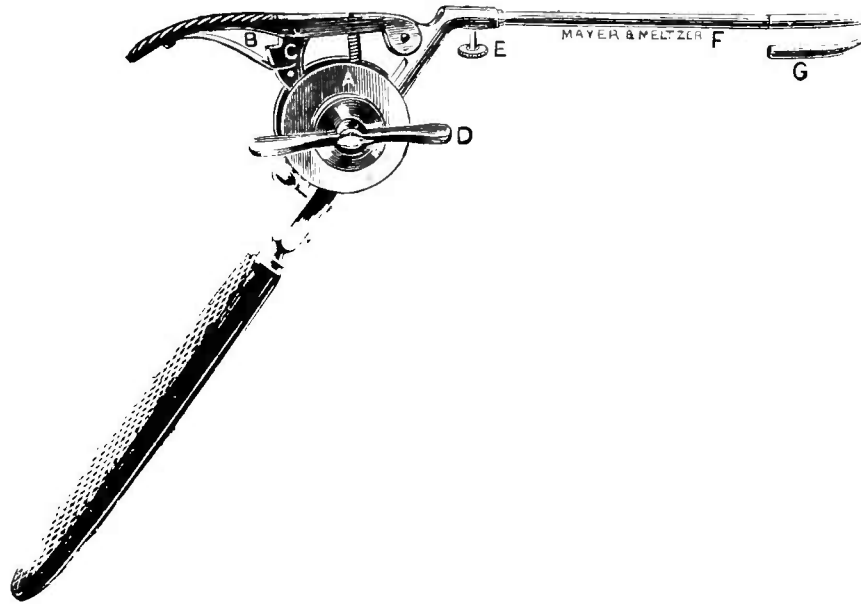


FIG. 118.—MORELL MACKENZIE'S SNARE (modified by Hovell). The wire is wound round the drum *A*, and is rapidly tightened by the handle and ratchet *B* and *C*. *D* is a more powerful handle for the last few turns. *E* is the screw releasing the tube *F* for cleaning, and *G* is a second beak to the instrument.

the polypus and the outer wall of the nose, as may be most convenient. The lower part of the loop should then be carefully manipulated round the lower edge of the polypus, and the tip of the snare and the loop pushed well up round the base of the growth, the wire being slowly tightened as

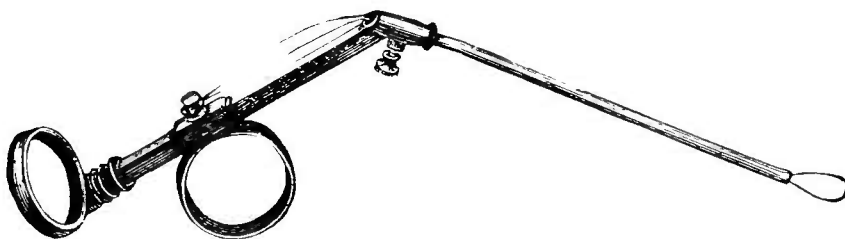


FIG. 119.—BLAKE'S SNARE FOR NASAL POLYPI.

this is done. The wire may be pulled tight and the polypus thus cut through: but it is usually better, although a little more painful, to use a fairly thick wire, to tighten it firmly round the base of the growth, and then to pull the whole mass away. In doing this, a piece of the surrounding mucous membrane, and sometimes a second polypus, may be removed. Wherever possible, an attempt should be made to enclose a piece of bone in the snare, and if the polypus be growing from the middle turbinate this can usually be accomplished. If the wire be round the bone, a firm resistance will be at once detected, and then it is better to cut it through rather

than wrench it away. Similarly, in nervous patients and in those who dread pain, the growths should always be completely divided by the wire.

When one or two polypi only are present, and are of long standing, it is probable that the initial bone disease has completely passed off. In such cases simple removal with the snare, as above described, will probably be sufficient to effect a cure. It is a matter of everyday experience that recurrence in this condition is rare.

More usually, however, further treatment will be required, and when all the polypi have been removed, the bony parts from which they grew should be carefully examined and cut away. If necessary to gain access to the part, the anterior extremity or a large piece of the middle turbinate may be removed. The affected area of bone should be completely cut away, and if this cannot be accomplished with forceps such as Grünwald's, which is very difficult when the polypi spring from the neighbourhood of the hiatus semilunaris or infundibulum, it is better to operate with a ring-knife under gas or some other general anæsthetic.



FIG. 120.—MEYER'S ORIGINAL ADENOID CURETTE.

The large ring-knife is passed up into the affected region, under illumination, or it may be guided by the finger, and the diseased bone is thoroughly and firmly scraped away. For this purpose an ordinary sharp spoon is quite useless, and a large ring-knife, such as Meyer's original adenoid curette (see Fig. 120), is essential. The operation having been completed, it is better to pack the nose with a strip of gauze for a few days, and subsequently to irrigate it regularly until healing has taken place. The results of this operation are very good when it is thoroughly done.

**3. When there is extensive ethmoidal disease.**—Where there are many polypi but the extent of the bone disease is unknown, it is well to commence treatment by removing some of the larger growths with the snare. Although such a method is rarely effectual in clearing the nose for more than a short time, it enables a better view of the parts to be obtained, and a more accurate estimate of the extent of the disease to be formed. When it is ascertained that extensive bone disease is present, a radical operation should be at once proceeded with. This consists in thoroughly exploring the diseased region by digital examination under a general anæsthetic, and in thoroughly clearing out the whole affected part. The method of operating is essentially similar to that recommended for cases of suppuration in the ethmoidal cells, which is commonly associated with polypi, and, as it will be fully described later, it need not be further alluded to here (see pp. 346-348). The treatment is just the same

whether suppuration be present or not, although in the former case operation is probably associated with less risk and gives better results.

The danger to life in this operation will also be more fully considered later. Experience shows that, if performed with moderate care, it must be very slight (in the writer's experience no dangerous symptoms have ever occurred) although the region is undoubtedly a dangerous one, and the blade of a forceps or similar instrument could be easily pushed up through the cribriform plate with the probable result of producing fatal meningitis or other cerebral complications. The inner wall of the orbit may be removed without producing other ill result than a temporary black eye. In one case, however, in which polypi were complicated by extensive *accessory sinus suppuration* an orbital abscess accompanied by necrosis occurred some weeks after the operation. Otherwise no ill results have occurred. The danger however must be borne in mind, and the direction in which such instruments as forceps are passed should be carefully watched, and no wrenching or tearing practised. A large ring-knife is probably the safest instrument to use in this region, and the operation may be completed if need be by a smaller ring-knife used with greater gentleness.

The prognosis as regards recurrence of polypi after this operation as compared to that after the usual methods of removal is extremely good. Recurrence is the exception and not the rule, even in cases in which polypi have been present for ten or twenty years in spite of frequent operations. When successful, there will usually be seen a large dry cavity in the upper and outer part of the nasal fossa, lined by thin, adherent mucous membrane. If the finger be passed up into this cavity the bone will be found very firm and dense, and this sclerosis seems to be the natural result of cure. Should recurrence take place, the operation may be repeated, but as a rule recurrences are very slight and the growths may be successfully removed by the snare. In any case, a second operation easily remedies them.

If the nose be not packed after the operation, or if the packing be omitted for a short time, or in rare cases even in spite of packing, numerous exuberant granulations spring up on all sides and look like a rapid and profuse recurrence of the polypi. In most cases however these are simply granulations, and will shrivel up and disappear spontaneously if the operation has been thoroughly performed. In spite of them the patient states that he experiences great relief and that his nose feels quite clear; and usually after about two months the growths will have entirely vanished and the patient will be quite well.

One other point may be mentioned as showing the necessity for this operation. If, in a severe case of nasal polypi, the growths be removed with the snare, the nose may seem almost clear and only a few small growths can be seen. However, in a week the nose is again full of polypi, and the same result follows a second operation; but, if instead of

waiting, the above-described operation be performed at once, the amount of large polypi which come away is quite surprising, the fact being that the polypi are to a large extent packed away in inaccessible regions of the nose and only come into view after the presenting masses have been removed. This observation shows conclusively the great and usually unappreciated extent of the disease and the uselessness of snaring polypi one by one, and it also explains the immediate relief that the patient experiences after the above operation, although the nose may still seem to contain growths.

## CHAPTER XXIX.

### CHRONIC INFECTIVE DISEASES OF THE NOSE.

*SYPHILIS: TUBERCLE: LUPUS: LEPROSY: RHINOSCLEROMA.*

#### SYPHILIS OF THE NOSE.

**PRIMARY SYPHILIS.**—In a few extremely rare cases a chancre has been seen in the anterior part of the nose, usually on the septum. It may be produced by picking at the nose with infected fingers, or by using an infected Eustachian catheter, etc. The sub-maxillary glands on the same side are always enlarged and corroborative evidence will subsequently appear.

**SECONDARY SYPHILIS.**—This affection rarely gives rise to any characteristic signs in the nose, but a chronic, obstinate form of rhinitis associated with marked congestion of the nasal mucous membrane is not infrequently seen accompanying the ordinary signs of secondary syphilis. Mucous patches and condylomata are practically never met with in the nose.

The treatment of these two conditions is that of syphilis in general (see Part I. p. 230) and no special treatment beyond ordinary measures for cleansing the nose is required for the local manifestations.

**TERTIARY SYPHILIS.**—Tertiary syphilis of the nose is not uncommon and may appear at a very early or a very late stage of the disease. It may assume the form of a gumma or of a gummatous infiltration. A gumma is most commonly observed on the anterior part of the septum, at first as a diffuse swelling, but later on appearing more localised and prominent and closely resembling an abscess. More usually, when the case comes under observation the gumma has broken down and a large ulcerating surface is seen. This is accompanied by considerable swelling of the mucous membrane and red fleshy granulations, which may entirely block the affected nostril and conceal the ulcer from view. There is also a copious purulent fœtid discharge.

The soft parts are first involved, but the affection commonly extends

to the bone and results in necrosis. The disease most frequently attacks the bony or cartilaginous septum, and usually results in a perforation or a more or less complete destruction of it. The inferior turbinate is more rarely the seat of disease, but the middle turbinate, the nasal bones, or any part of the nose or its bony framework may be involved. If the nasal bones be affected there is usually considerable external swelling and redness of the nose, and the overlying skin may be inflamed and even ulcerate. The *alæ nasi* and the *columella* may also be attacked and undergo rapid ulceration and destruction. In some cases almost the whole of the interior of the nose is affected and extensive necrosis results: the inferior turbinates, the septum and almost the entire ethmoid may come away as sequestra.

**Results.**—If the disease be limited and be properly treated, a healed perforation of the septum or a scar on the outer wall of the nose may alone remain. When a larger area has been affected and especially when the inferior turbinate has necrosed, the interior of the nose appears as a large cavern, very much resembling the condition in a bad case of atrophic rhinitis. This cavity is lined by scar tissue covered by squamous epithelium: it is commonly filled with fœtid crusts which are extruded with great difficulty: in fact the condition must be considered one of atrophic rhinitis or *ozæna* due to syphilis. Sometimes a sequestrum may be found in the nose, and this is always accompanied by profuse purulent discharge and an intense characteristic fœtor of the breath.

When the external parts of the nose have been destroyed, healing will always be followed by considerable deformity. If the nasal bones be affected, the bridge of the nose sinks in and may assume a saddleback deformity. In other cases the *alæ nasi* or *columella* may be more or less extensively destroyed, or various other distortions result.

**Treatment.**—The treatment is similar to that of tertiary syphilis elsewhere (see Part I., p. 235), the constitutional treatment consisting in large doses of iodides with or without mercury. In cases which do not yield readily to iodides, mercurial inunction should certainly be tried, and success will frequently follow it in cases in which the iodide alone apparently produces no effect. In addition to this, local applications are usually required. It is essential that the nose should be kept clean by frequent washings with mild antiseptics, such as boracic acid or better still *sanitas*. In obstinate cases insufflations of calomel<sup>1</sup> may be tried locally.

Under this treatment healing usually takes place rapidly, but, if the mucous membrane has been extensively destroyed, the nose will be left in a dry condition, and there will be for many months a tendency to the formation of crusts which are extruded with difficulty and which may lead

<sup>1</sup>Two or three grains of calomel are placed in the bulb of a special porcelain insufflator, which is heated by a spirit lamp. As soon as the vapour appears, it is blown into the nose by a small hand-bellows attached to one end of the tube; at the opposite end the tube is flattened for insertion into the nose.



to excoriation of the mucous membrane and small hæmorrhages as in rhinitis sicca.

When a sequestrum is present it must always be removed. This may usually be effected by grasping it with a pair of ordinary nasal or polypus forceps, but when the piece is too large to be extracted easily through the anterior nares, it is necessary to crush it by means of a strong pair of forceps or to reduce it in size by clipping off small fragments with scissors or Grünwald's forceps. These sequestra are often composed of very dense bone.

**INHERITED SYPHILIS.**—This appears at first as a simple mucopurulent catarrh in the noses of infants from one to two months old, and at first cannot be distinguished from a simple catarrh. It soon, however, becomes more purulent, the nose becoming obstructed and the breathing noisy, giving rise to the name "snuffles" by which the disease is most commonly known. If the condition be neglected it may lead to very serious consequences; the septum, the nasal bones and the mucous membrane may become extensively destroyed, and the bridge of the nose may collapse, giving rise later on to the typical "saddle-backed" nose.

**Treatment.**—The treatment must be both local and constitutional. The latter need not be alluded to here (see Part I., p. 236), but it is very essential to cut short the disease in the nose as rapidly as possible, and nothing is so efficacious for this purpose as systematic syringing. This must always be carried out by the surgeon or by a properly trained nurse, and it is best to use a mild non-poisonous antiseptic solution such as boracic acid, sanitas, or permanganate of potash lotion (see p. 297). The nose must be syringed regularly twice daily until all the discharge has ceased. At the same time the feeding of the infant must be carefully conducted. It is usually necessary to give food with a spoon, as, on account of the complete nasal obstruction, there is considerable difficulty in suckling.

#### TUBERCULOSIS OF THE NOSE.

This may occur as a large tuberculous tumour, usually attached to the cartilaginous septum, but it is more common in the form of lupus.

**Symptoms.**—*Lupus* of the nose is generally associated with a similar affection of the neighbouring skin or of the pharynx and larynx. As a rule it presents no very characteristic points, but a slowly progressive chronic ulceration accompanied by somewhat profuse pale granulations which may almost entirely obstruct the nostril should always excite suspicion. It most commonly appears first on the septum whence it may spread to the floor of the nose and to the inferior turbinate. It is much more common in the inferior meatus, but any part of the nose may be attacked. In places cicatricial processes are at work simultaneously with the spread of the ulceration. It is very rare for necrosis of bone to occur, but perforation of the cartilaginous septum is not uncommon, and

in advanced cases the alæ, columella or tip of the nose may be extensively destroyed. The disease may remain limited to the interior of the nose for years, but more usually extension takes place after a time on to the face, into the throat, or in both directions.

**Treatment.**—If there be any doubt about the nature of the affection it is always best to administer anti-syphilitic treatment in the first instance. Should this fail, a large piece of the granulation tissue should be removed and examined microscopically to make certain of its tuberculous nature before any active treatment is adopted. When the diagnosis is definitely established, the affected parts must be thoroughly scraped away: for this a general anæsthetic is necessary. The post-nasal space must be firmly plugged with a large sponge attached to a tape, and then all granulations and lupous areas must be firmly scraped away under good illumination by means of a sharp ring-knife. The nose is then packed with iodoform gauze to arrest the hæmorrhage. It is a good plan to remove the gauze two or three days later and to thoroughly cauterise all the affected parts with the galvano-cautery or with chromic acid. Under this treatment healing will usually take place, although fresh outbreaks are liable to occur.

Combined with this treatment, arsenic should always be given internally in increasing doses; this drug does not seem to have quite the same effect upon lupus in this region that it has in lupus of the throat, but it undoubtedly has a decidedly beneficial action; it should be given in doses of two to three minims three times a day after meals, gradually increased until ten or fifteen minims are being administered. At the same time tonics such as cod-liver oil, good feeding and change of air must not be neglected. In these cases also the thyroid extract, which enjoys so great a reputation in lupus of the skin, might be well worth a trial.

#### RHINO-SCLEROMA.

This is an affection involving both the skin and mucous membrane of the nose and thence usually spreading downwards into the pharynx and larynx. It is extremely rarely seen in this country; in fact the cases seen here are almost entirely imported from Austria or Russia, where the affection is not uncommon. The disease is usually more or less symmetrical, and, commencing as a sort of nodular infiltration, spreads until the whole of the nose becomes increased in size, the alæ distended and the nostrils occluded, while the tip of the nose becomes broad and rigid. There is usually a little ulceration, and occasionally fissures appear in the growths. The disease is due to a definite micro-organism, a short, rather broad, encapsuled bacillus.

**Treatment.**—Very little can be done. The parts may be excised, the cautery may be applied, electrolysis or chemical caustics may be resorted to. In the majority of cases improvement is obtained for a time, but a relapse invariably occurs when the treatment is left off.

## TUMOURS OF THE NOSE.

**PAPILLOMA.**—Simple tumours of the nose, other than polypi, which have already been dealt with, are extremely uncommon. The most frequent are simple papillomata, which are generally seen on the anterior part of the septum and occasionally on the inferior turbinate. They are usually quite small and unimportant, and may be easily removed either with a snare or the cautery.

**FIBRO-ANGEIOMA OF SEPTUM.**—Another tumour, more rarely met with but of considerable importance, is the so-called bleeding polypus of the septum or fibro-angioma. This tumour grows from the anterior part of the septum from a broad base, readily gives rise to hæmorrhage, frequently recurs after removal, and is consequently often regarded as a sarcoma, although it is essentially an innocent growth. It is seen most commonly in young adults. The surface is sometimes ulcerated, but its edges are always sharply defined, and it never gives rise to perforation of the septum.

**Treatment.**—The treatment consists in thorough removal: this does not involve an external operation. The best plan is to operate under local anæsthesia (see p. 284), but in nervous people a general anæsthetic may be advisable. The mucous membrane just wide of the growth is first divided all round, with the galvano-cautery as far as it can be reached. The bulk of the growth can then be snared, or it can be detached from the cartilage of the septum along with the perichondrium by means of a blunt dissector. In any case, the base of the growth should be thoroughly scraped, and then packing applied for a few minutes until the hæmorrhage is arrested. The cautery should then be used again, or powerful chemical caustics, such as nitrate of silver, well rubbed in until the whole base of the tumour has been seared. In this way the tumour may be radically removed, and recurrence will not as a rule take place.

Should, however, recurrence occur, the tumour must not be regarded as malignant, but the same treatment must be repeated. In some cases there has been recurrence three or four times, but the treatment has been successful in the end.

**FIBROMA.**—In very rare instances a fibroma has been met with, most often attached to the septum or to the roof of the nose, and it may attain an enormous size, filling and expanding the nostril, and involving the antrum or some other accessory sinus.

**Treatment.**—If small, the growth may be snared off or treated in the same way as the fibro-angioma (*vide supra*), but in many instances an external surgical operation, such as temporary resection of the nose or partial resection of the superior maxilla has had to be performed. These operations will be described later.

**MALIGNANT NEOPLASMS.**—These are not very uncommon, and may be either sarcomata or carcinomata. Formerly they were generally considered as being sarcomata, but this is probably an error, the most common form of malignant growth being a *cylindrical-celled carcinoma*. This usually commences in the upper part of the nose in the mucous membrane covering the ethmoid. It may, however, commence on the septum, the floor of the nose, or the inferior turbinate. It is most common in old people, is of very slow growth, and produces no constitutional effects until very late. Secondary glandular involvement is also extremely rare. In the earlier stages the case may greatly resemble one of nasal polypus, with which it is indeed not unusually complicated; soon, however, the growth becomes unusually large, the surface often ulcerates, and very free hæmorrhage occurs on touching it or on attempts to remove it. Spontaneous epistaxis is not uncommon. If the growth be left untouched it fills and expands the nose and extends through the walls, producing considerable deformity. The nasal bones may be pushed out, or the orbit or frontal sinuses may be invaded resulting in proptosis, pressure on the optic nerve or other ocular disturbance.

**Treatment.**—These growths appear to be less malignant than similar growths elsewhere, and much less extensive operations may be successfully undertaken than would be justifiable in other regions.

Of the actual methods of operation nothing need be said here, but the object in all these cases should be to remove the growth as thoroughly and as widely as possible; even in cases in which the growth is apparently very extensive, operation may be performed. In many cases simply scraping the whole of the apparently affected region, drying it and applying the cautery has apparently proved successful. Also even after recurrence has taken place, the treatment may be successfully repeated.

*A sarcoma of the nose* is most frequently of the spindle-celled variety, and most often commences in the ethmoidal region. As the growth enlarges it invades the accessory sinuses and air cells. These tumours also commonly have a low degree of malignancy, and, if they can be thoroughly removed, the prognosis is not bad.

Of other tumours, such as epithelioma and rodent ulcer occurring in the vestibular region, nothing need be said here.

## CHAPTER XXX.

### NASAL NEUROSES.

*HAY FEVER: PAROXYSMAL SNEEZING RHINORRHŒA: NASAL  
ASTHMA: PAROSMIA AND ANOSMIA.*

#### HAY FEVER.

THE etiology and pathology of this affection are by no means understood: all that is certain in connection with it is that the pollen of certain grasses is the commonest exciting cause of the symptoms.

**Symptoms.**—In a severe case these consist of watering at the eyes, with congestion of the conjunctiva, swelling of the eyelids, a profuse watery discharge from the nose, with constant sneezing and complete nasal obstruction. The whole nose appears to be red, swollen and hot, the patient's throat becomes dry, he suffers from severe headache and occasionally from considerable embarrassment of the respiration,—a kind of *hay asthma*. These symptoms commence quite suddenly in an apparently healthy person soon after exposure to the exciting influences, and slowly pass off when the latter have been removed. Many persons have periodical attacks lasting from three to four weeks during the season of the flowering of the grasses, and in some years the attacks are much more severe than in others. The patient is frequently quite free from the disease if he spends the hay-fever season at the seaside or in a large town. In other cases the affection lasts the whole of the summer. Strangely enough it is unknown in the tropics.

**Pathological changes.**—Examination of the nose in many cases reveals some abnormality. There may be a deflected septum, or a spur on the septum in contact with the inferior turbinate: swelling or hypertrophy of the inferior turbinate with a peculiar, greyish, sodden-looking mucous membrane: or hypertrophy of the middle turbinate with or without small polypi. In many of these cases peculiarly sensitive spots may be found on the upper part of the septum near the anterior end of the middle turbinate, the mucous membrane being abnormally thick and pale. In some cases

the patient is run down, in others, he is distinctly of a neurotic temperament, but the large majority are in robust health and have no constitutional affection.

**Treatment.** (a) **Prophylactic.**—The exciting cause of the disease being recognised, the preventive treatment follows as a matter of course. If the patient be in a position to spend the months of the year in which the affection comes on either at sea, at the seaside or abroad, the symptoms may never appear. In many cases, where this is not possible, much may be done by treating the nose, but precisely how much improvement will follow treatment in a given case it is impossible to predict with certainty.

(b) **Local.**—The first object of local treatment is to remove any abnormality of the nose, whether it be a hypertrophied turbinate or a spur on the septum, etc. It is remarkable how much relief may be occasionally obtained by a little operation such as the removal of an apparently insignificant cause of nasal obstruction.

Failing this, the best and most reliable treatment seems to be cauterisation of the nasal mucous membrane. In many cases systematic examination of the interior of the nose with a probe or a small pledget of wool dipped in cocaine solution will bring to light, perhaps on the already described area of the septum, some very sensitive spots contact with which immediately sets up sneezing and rhinorrhœa; such spots should always be carefully sought for. If found, the sensitive area should be anæsthetised and freely destroyed by the electric cautery. As a rule it is not necessary to destroy the mucous membrane deeply, but the whole superficial area of the mucous membrane should be burned with a flat cautery-end. Should no sensitive spots be found, the nose may be washed out daily with an alkaline lotion (see p. 282) and its interior coated with oil, such as almond oil, by means of an atomiser (see p. 284) in fact, for a time the nose may be treated exactly on the lines already laid down for the treatment of chronic rhinitis (see p. 300). Should this fail, the effect of cauterising the inferior turbinates should be tried. The flat-ended cautery should be taken and, under cocaine, three or four longitudinal lines should be drawn along the whole length of the inferior turbinate. By this purely empirical means the majority of the cases may be cured and practically all of them considerably relieved. In many cases however the disease will return in a bad hay-fever season, and the treatment may even require to be repeated yearly. In addition to these local measures, tonics, especially arsenic, should be administered.

(c) **During an attack.**—Relief or temporary relief of this affection during the actual attack may be obtained by the use of cocaine. A solution of 2% or 4% may be occasionally sprayed into the nose, and a drop or two may be instilled into the conjunctivæ. This will usually produce complete relief from all the symptoms in two or three minutes, but if the patient remain exposed to the source of the irritation, it will require to be repeated every hour or so. Consequently the remedy is a very

dangerous one, and especially so because in time it loses its effect. Stronger solutions are then resorted to and these may produce severe constitutional depression, insomnia, loss of appetite and mental disturbances. In spite of this, the patient may continue to use the drug because of the great temporary relief he experiences, and this may originate the cocaine habit. Its continual use also apparently aggravates the local condition and renders it far more obstinate to curative treatment.

#### PAROXYSMAL SNEEZING OR RHINORRHEA.

This affection appears to be somewhat analagous to hay fever. The symptoms of the acute attacks are similar, the nasal condition is similar, but the actual exciting cause varies.

**Symptoms.**—The symptoms in most cases come on regularly every morning, varying in intensity, sometimes lasting half an hour, sometimes five or six hours; sometimes the patient has two bad attacks a day, or may pass three or four days without experiencing an attack. The affection is usually worse in the winter and in damp, cold weather. In other cases it varies according to unknown circumstances.

**Causes.**—The *exciting causes* are numerous, varying in each instance. The attacks may be set up by inhaling ordinary dust, by various smells, such as those of roses, violets, etc., by the dust emanating from carpets or various fabrics, by draughts, by the change from a warm room into a colder one, by going out of doors, etc. This affection apparently has a tendency to cause hypertrophy of the mucous membrane of the nose, and is not rarely accompanied by disease of the middle turbinate and by polypi.

**Treatment.**—The affection should be treated on principles exactly similar to those for hay fever, but as the disease is a much more persistent one, many of the patients are much run down, and consequently tonics are especially needed. If it can be tolerated, arsenic should be prescribed, but in many cases, it is first of all necessary to treat the digestive disturbances. Not a few of these cases seek treatment on account of redness of the tip of the nose, and aperients are then especially indicated; some of the natural aperient waters such as Apenta or Hunyadi Janos are the most useful.

#### IDIOPATHIC RHINORRHEA.

The pathology of the cases included under this term is not understood. The affection consists of a constant or more or less intermittent dripping of a clear watery fluid from the nose, unassociated with nasal obstruction, sneezing or irritation. In many cases the source of the discharge is unknown; in some it is probable that the fluid comes from one of the accessory sinuses, where it first collects and then suddenly empties itself with a gush into the nose. In other rare cases the fluid comes from the arachnoidal space and is pure cerebro-spinal fluid.

**Treatment.**—The treatment depends essentially upon the cause of the affection. If the antrum or other of the accessory sinuses be suspected, it should be thoroughly washed out and if necessary drained (see Chap. XXXI.). The antrum is the sinus far most likely to be affected, but the sphenoidal sinus also may be the source of trouble. In cases in which the dripping is more or less continuous, the fluid should be carefully analysed. Cerebro-spinal fluid may be recognised by its low specific gravity, by the absence of proteids and by the presence of a reducing substance which is not sugar. In these cases other nervous symptoms may be present, such as optic neuritis, severe headaches, (which usually appear just before the onset of the flow and are relieved by it) and neuralgic pains. No effective treatment has as yet been suggested.

#### NASAL ASTHMA.

As already seen, a form of asthma, commonly called “hay asthma” may occur in connection with hay fever, but the treatment directed to the cure of the latter condition has usually no beneficial effect on the asthma; on the contrary, the latter often appears to be aggravated by operations to establish free nasal respiration.

There has been great dispute as to whether a true *nasal* asthma exists; that is, as to whether asthma is ever a purely reflex condition resulting from some pathological change in the nasal mucous membrane. Some observers actually consider all asthma due to a nasal origin. Without assenting to this proposition and without expressing any opinion on the etiology of asthma in general, it is a fact that, by treating the nose alone, a large number of cases of asthma may be considerably improved and a few apparently quite cured.

The possibility of a case of asthma being dependent upon nasal trouble is increased if any definite sensitive area or “cough spots” (spots which when touched by a probe provoke fits of coughing) can be discovered in the nose, or if any well-marked pathological condition be present. Also if, as is not very uncommon, the asthmatic attack is preceded or accompanied by a sudden onset of such symptoms as sneezing, nasal obstruction and rhinorrhœa.

**Treatment.**—The particular treatment required depends upon the conditions found. The following propositions may be laid down:

- (1) In all cases of asthma a thorough and systematic examination of the nasal chambers should be instituted, and any pathological conditions found should be appropriately treated.
- (2) Nasal polypi should be removed, hypertrophied turbinates reduced and septal deflections or spurs remedied, and any sensitive spots in the nasal mucous membrane should be destroyed by the cautery.
- (3) Post-nasal growths if present should be removed, since asthma in children is not by any means unusually benefited by this operation.



- (4) If no objective abnormality be found but yet the onset of asthma be preceded by nasal obstruction, sneezing, etc., the inferior turbinates should be cauterised, as in cases of rhinorrhœa.
- (5) If, on the other hand, the nasal mucous membrane be perfectly healthy, and there is no clear history of nasal disturbance preceding the asthmatic attack, nasal treatment should not be carried out.

The results obtained are very uncertain. In rare cases great benefit, amounting in some to a complete cure, is obtained; more often the patient experiences considerable benefit to the asthma quite apart from the relief he gets by the removal of the nasal trouble; but in the majority of cases no benefit whatever is obtained. There is no means of determining beforehand which cases of asthma will benefit by intra-nasal treatment, and the most successful cases may be those in which there is no marked disease in the nose. But in all cases in which there is some definite objective pathological condition in the nose, nasal treatment is justifiable. Of course, in addition to this, the ordinary medical treatment of asthma should be carried out.

#### ANOSMIA.

Anosmia or loss of the sense of smell may arise from a large variety of causes. It is most commonly the result of diseases of the nose which act either by preventing access of the odoriferous particles to the olfactory region *e.g.* polypi, hypertrophied middle turbinates, etc., or by preventing proper contact between the particles and the olfactory sense-organs, *e.g.* excessive dryness of the mucous membrane, as in ozæna, rhinitis sicca, etc. Again, in catarrhal conditions all sense of smell is commonly lost, possibly from direct involvement of the olfactory organs in the catarrh. Further, the olfactory region may be extensively destroyed, as in syphilis, or there may be some cerebral affection, absence, disease or injury of the olfactory centre, lobes, or nerves.

Apart from these, many cases of anosmia are met with in which no objective lesion can be discovered. Such cases are commonly the sequelæ of influenza, diphtheria, or other fevers. Anosmia is frequently accompanied by more or less complete loss of taste, that is, of the power of appreciating the aroma of foods.

The prognosis depends entirely upon the cause and upon the possibility of removing it. In cases of nasal polypi for instance, their complete removal may result in a restoration of the power of smell after considerable intervals even after as much as from ten to twenty years, and the same result may more rarely follow the cure of an ozæna. In other cases the prognosis is much less favourable and, generally speaking, the longer the duration the less is the likelihood of cure.

**Treatment.**—This consists in ascertaining the cause and adopting the appropriate treatment. When no cause can be found, and especially

when the affection follows influenza, etc., the internal administration of strychnine should be tried. The liquor strychninæ may be given in increasing doses of from 5-10 minims three times a day. Should this fail, quinine may be given, but commonly no beneficial effect will be obtained.

#### PAROSMIA.

Parosmia is a perversion of the sense of smell which always results in a subjective sensation of an unpleasant character. The patient comes complaining of a more or less constant and disgusting odour in the nose. In such cases the presence of a local cause, and more especially a sinus suppuration, should always be most carefully sought for. This or an ordinary severe coryza, such as accompanies influenza, is by far the most common cause. Other cases may depend upon syphilis, especially when necrosis is present, upon the presence of a foreign body, on ozæna, etc. A few cases are of cerebral origin, while in some no cause may be found.

The prognosis depends upon the possibility of ascertaining and removing the cause. In cerebral cases recovery is rare.

The treatment is to ascertain and remove the cause, and employ generally the treatment described above in speaking of anosmia.

## CHAPTER XXXI.

### INFLAMMATORY AFFECTIONS OF THE ACCESSORY CAVITIES OF THE NOSE.

#### ACUTE INFLAMMATION AND SUPPURATION.

**Etiology.**—Acute catarrh of the accessory sinuses and air cells of the nose is a frequent accompaniment of *acute rhinitis*, more especially when the latter is purulent or is the result of a severe specific infection, such as measles, scarlet fever, influenza, etc. In severe cases of *ordinary coryza* pain and tenderness in the region of an accessory cavity commonly points to an acute infection of it, and this may quite well have occurred, and yet the secretion formed may be entirely removed by natural means if no other pathogenic agent be at work. If, however, in the course of the catarrh, the opening of the sinus into the nose be blocked by inflammatory swelling, acute suppuration results. The acute inflammation alone may cause sufficient œdema of the mucous membrane to completely obstruct the orifice of the cavity, but it is obvious that this is more liable to occur if there be any pre-existing cause of obstruction, such as polypi, hypertrophy of the middle turbinate, etc. Again, severe or repeated attacks of inflammation may destroy the ciliated epithelium of the lining mucous membrane, or so weaken its action that it is unable to remove the increased secretion which thus accumulates in the cavity and rapidly becomes purulent.

Another, but rarer, cause of acute suppuration is the presence of a *foreign body*. Thus, bullets or pieces of sharp instruments may lodge in the antrum, frontal sinus or ethmoidal cells; blades of grass, straw, etc., may be inhaled into the nose and work their way into a sinus through its natural opening; and occasionally maggots or larvæ have been found, most often in the frontal sinus.

Suppuration in the antrum may result from *injury*, such as maladroit attempts at tooth extraction, and in any sinus and especially in the frontal sinus from such forms of trauma as kicks, stabs, etc.

Finally, in the case of the antrum, acute infection commonly arises in connection with *carious teeth*, the roots of the molars and bicuspid being

in close relation with the interior of the cavity. Thus, an abscess at the root of any of these teeth may easily burst into and infect the antrum.

**Symptoms.**—A patient with an acute rhinitis, simple or associated with influenza, etc., experiences a sudden increase of the nasal symptoms, with a feeling of burning heat and great fulness or tension in the nose and over the region of the affected cavity. There is pain in the affected region and often very severe neuralgia, shooting along the branches of the trigeminal nerve. In the more severe purulent cases there are constitutional disturbances, fever, anorexia, etc., and the walls of the affected cavity are tender on pressure or percussion, and the soft tissues overlying them may become swollen, red and œdematous. On examining the nose, besides the evidences of acute rhinitis, there is often to be seen bulging of the wall, or œdema over the site of the affected cavity and especially in the neighbourhood of the ostium. After a few hours or days of increasing suffering there is a sudden discharge from the nostril on the affected side, consisting of mucus, muco-pus or pus mixed in the majority of cases with more or less blood, and the symptoms are immediately relieved. In some cases all symptoms disappear after the initial discharge, or there may be for a few days an intermittent discharge gradually decreasing in quantity. In other cases, after a brief interval, all the symptoms return and increase in severity until a second discharge takes place. This cycle of events may be repeated once, twice, or even oftener and then result in complete recovery. On the other hand the case may become one of chronic empyema.

**Treatment.**—The great object of treatment in a case of acute catarrh in any of the accessory cavities is to cut short the inflammation in the nose and to reduce the swelling around the opening of the cavity so as to allow a free escape for the pent-up discharge. This is best attained by employing both constitutional and local measures. The disease tends towards a spontaneous cure, but much can be done to hasten this and to minimise the danger of any secondary changes occurring in the affected cavity which might lead to chronic suppuration.

**Constitutional measures.**—The patient should be confined to a warm room, preferably in bed, and a brisk purge followed by a diaphoretic mixture should be administered as already prescribed for acute rhinitis (see p. 295).

**Local treatment.**—In the first place the nose should be washed out by means of a simple, alkaline lotion, such as Dobell's (see p. 282), which should be either sniffed up the nose or introduced by means of a nasal irrigator, and its use should be continued until all catarrh has ceased.

In the second place, special measures must be adopted to reduce the swelling and remove the obstruction around the outlet of the affected cavity. For this purpose nothing acts so well as the solution of cocaine and suprarenal extract, which should be applied on pledgets of wool (see p. 285). When the tissues have been anæsthetised and rendered completely anæmic, any polypus or hypertrophy of the mucous membrane in the affected region

should be removed. When the middle turbinate is swollen or enlarged, it may be necessary to amputate the anterior part of it, or a free incision into it may first be tried. The approach to the ostium of the cavity having been thus cleared, the discharge may at once commence to escape, or its evacuation may be effected by bending the patient's head forward in the case of the antrum or by attempting to introduce a probe or cannula through the ostium into the cavity: the means of doing this will be described later under the diseases of the separate cavities.

Should the discharge escape, the astringent effect on the mucous membrane may be kept up by various applications which are best applied in the form of sprays. Of these, a solution of menthol, five to ten per cent., dissolved in almond oil is one of the most useful, and has the additional advantage of being very soothing to the patient. Other astringents such as antipyrine, hazeline, etc., are used by many for a similar purpose, but none are very satisfactory. The objection to the use of cocaine and suprarenal extract is that the swelling recurs directly the effect of the drug passes off, and is usually even more severe than before. Often, however, it sufficiently reduces the swelling to allow the discharge to escape and thus gives temporary relief.

In conjunction with these methods of treatment hot fomentations should be applied externally over the region of the affected cavity, as they relieve the pain and are very grateful to the patient.

Should these means of treatment prove ineffectual, it will be well to try the effect of local blood-letting. A free incision, after cocainisation, should be made along the middle turbinate and along the outer side of the nose as high up as possible. These incisions should be made under good illumination with a sharp knife, and the bleeding should be allowed to continue. In other cases small pieces of mucous membrane may be removed with punch forceps, but it is better to avoid the removal of bone if possible, as this may be followed by osteitis and increased swelling and œdema of the mucous membrane. This method of treatment is especially indicated in cases of suppuration in the ethmoidal cells and in the frontal sinus: in the case of the maxillary antrum it is simpler and better to puncture the cavity in the way about to be described.

If these measures fail, more active means must be adopted to secure the evacuation of the cavity. Thus, in the case of the *maxillary antrum*, this cavity should be punctured and the contents washed out. The methods of doing this will be described later. It is very rare in cases of acute suppuration not to obtain a cure by these means. A single irrigation is usually sufficient, but it may have to be repeated in a day or two. Should these measures fail, the case must be treated as for chronic suppuration (see p. 341).

If the *ethmoidal cells* are affected, there is always œdema of the middle turbinate or of the tissues in its concavity, and the parts are very tender to the probe. The treatment is to open the cell or cells affected at once

by cutting away the floor, preferably with a pair of cutting or punch forceps, such as Grünwald's (see p. 317).

If the *frontal sinus* be involved, it is necessary to obtain free access to the lower end of the infundibulum by removing the anterior end of the middle turbinate and any polypi or swelling of the adjacent part of the outer wall of the nose that may be present. This usually allows free escape for the discharge. A cautious attempt may also be made to wash out the sinus through a cannula passed up through the infundibulum (see p. 351). Should acute symptoms be present, such as frontal headache, tenderness and swelling over the sinus, and be unrelieved or increased by these measures, an external operation is required (see p. 352). In other cases it is best to leave the case to nature for a time. The frontal sinus however, owing to the dependent position of its opening, commonly recovers under this treatment.

The treatment of an acute suppuration of the *sphenoidal sinus*, should it ever be recognised in this stage, must be conducted on exactly similar lines as for chronic suppuration, namely, by irrigation through its natural opening, which is situated high up in the anterior wall of the sinus above and behind the middle turbinate and near the median line (see p. 274, and Fig. 98) the approach to which is first cleared by removing the posterior end or as much of the middle turbinate as may be necessary (see p. 306).

#### CHRONIC SUPPURATION.

**Etiology.**—Chronic suppuration is most commonly met with as a sequel of acute. Although acute suppuration usually terminates in speedy and complete recovery, certain circumstances render it liable to become chronic. These conditions are partly the anatomical relations of the cavities and partly depend upon pathological processes. Thus :

1. The natural openings of the cavities are small and very badly placed for drainage. The frontal sinus alone has a dependent exit and this is through a long, narrow and tortuous canal which is consequently very liable to be obstructed. If the ciliated epithelium lining the sinuses be damaged by the intensity of the inflammation, it is obvious that the secretion will accumulate until it overflows.

2. The outlet of the cavity may be partially obstructed, and consequently the secretions do not obtain a free exit. The mucous membrane around the various ostia rapidly becomes œdematous, and, being very loosely attached, is thrown into folds which continue to obstruct the opening even after the inflammatory exudation has subsided.

3. The severity of the original infection or the continuance of the suppuration from some of the above causes may so injure the walls of the cavities that spontaneous recovery is impossible. The epithelium may be destroyed and the infiltrated mucous membrane may be covered with

granulations. Sometimes large polypi are found in the cavity, and cysts, arising from the distension of the glands in the mucous membrane, are often met with, especially in the antrum. Changes in the bone, caries or necrosis, are also not uncommon, and sometimes new bone is irregularly deposited as the result of periostitis, giving rise to great roughening of the walls or even to large osteophytes.

4. The causes may continue in action. For example, the cavity may contain a foreign body which in the case of the antrum may be a carious tooth. In *ozæna* also there is a constant fœtid and decomposing discharge from the nose which may infect a sinus, usually the antrum or sphenoidal sinus, and set up chronic suppuration.

5. One cavity may become infected from or may act as a reservoir for pus coming from another. Thus, pus from the frontal sinus or from the ethmoidal cells may enter the antrum through its natural opening or through a perforation of its wall in the vicinity of the infundibulum, and the ethmoidal cells may be affected in a similar way by pus coming down from the frontal sinus. This is more likely to occur if the free escape of the discharge be prevented by swelling or polypi or by cotton wool or gauze tampons. Thus, there is always danger in packing the nose for hæmorrhage following operations for polypi associated with sinus suppuration. Occasionally, perhaps, infection may be spread by violent attempts at blowing the nose.

6. Lastly, sinus suppuration may be secondary to diseases such as tuberculosis, syphilis, or malignant disease, causing caries or necrosis of their walls. These openings allow pyogenic organisms to enter the cavity, but fortunately are generally large and allow of free drainage, and therefore chronic suppuration from such causes is rare.

**Symptoms.**—In the large majority of cases, the most prominent or the only symptom is the purulent nasal discharge. These cases, in which the opening from the sinus into the nose is free enough to allow the pus as it fills the cavity to overflow, are commonly described as “latent empyemata.” When the outlet of the cavity becomes temporarily obstructed acute symptoms, such as intense pain, swelling, tenderness, redness, and œdema over the site of the affected cavity and severe constitutional disturbance set in. In other cases, even of latent empyema, as the result of slowly progressive caries or necrosis the pus may find its way through the walls of the sinus and infect the surrounding tissues. Thus, pus from the antrum may burst outwards and cause an abscess in the soft tissues of the cheek, upwards and give rise to an orbital abscess, backwards into the sphenopalatine fossa, or downwards beneath the muco-periosteum of the hard palate, etc. From the frontal sinus the pus may find its way out externally, usually at the inner angle of the orbit, or perforation may take place through the posterior wall of the cavity giving rise to meningitis or abscess in the frontal lobe of the brain. Similarly, pus from the ethmoidal cells may give rise to an abscess in the inner wall or floor of the orbit or to

meningitis or cerebral abscess. Sphenoidal disease may also spread to the cerebral cavity, one of the earliest symptoms of this being progressive blindness from involvement of the optic tracts which are in close relation to the body of the sphenoid bone. Extension of disease from the cavity may also take place through the lymphatics, and perhaps also through the veins without any definite sign of bone disease; bacterial infection through these channels is probably the most common cause of the various cerebral affections resulting from sinus suppurations.

**Treatment.**—In chronic suppuration of any accessory cavity of the nose spontaneous recovery is practically impossible, and thus in every case operative interference is required. In the first place this should consist in irrigating the cavity through its natural or an artificial opening, and washing out the pus: the cause, if still present, must be removed and special efforts made to obtain free access to the nasal opening of the cavity by the removal of polypi, œdema, or any other hypertrophic condition.

Should these means fail, a further operation must be undertaken: the cavity must be freely opened and all pathological conditions set up by the suppuration and tending to maintain it, such as polypi, caries, or necrosis of its walls must be removed. Moreover, means must be taken to prevent re-accumulation of the pus, either by providing permanent free drainage or by entirely obliterating the cavity. Further, although surgical treatment is essential, every other means, medical and dietetic, must be adopted to maintain the general health.

Again, the cavities must be treated in a definite order, for, as has already been seen, one cavity may act as a reservoir of pus coming from another, and also the diagnosis depends to a large extent upon the result of treatment. In most cases it is possible to ascertain whether the purulent discharge in the nose comes from the anterior set of accessory sinuses, namely, the antrum, the anterior ethmoidal cells and the frontal sinus, or whether it is derived from the posterior set of cavities, the sphenoidal sinus and the posterior ethmoidal cells. In the former case, if polypi, œdema of the middle turbinate, or caries of the ethmoid be present the ethmoidal cells should be attacked. After the ethmoidal cells have been treated it is advisable to puncture the antrum, and finally, if there be still a considerable amount of discharge, the frontal sinus must be opened. In other cases in which there is no definite evidence as to which of the anterior set of cavities is involved, the antrum must first be attacked, then the ethmoidal cells, and lastly the frontal sinus. If the posterior set of cavities be affected, it is generally advisable to remove the posterior end of the middle turbinate and to open the posterior ethmoidal cells, and subsequently if necessary to attack the sphenoidal sinus. In a few cases, as for instance in *ozæna*, the opening of the sphenoidal sinus can be seen from the front, and in such cases this sinus may be explored first. *In every case of chronic suppuration in the nose it is necessary to explore the cavities one by one until all sources of suppuration have been*



*discovered.* The treatment of each sinus presents such different problems that it will be considered separately.

(a) **Of chronic suppuration in the maxillary antrum.**—In the first instance mild measures should always be tried. The cavity should be opened by a simple puncture, as described below, and its contents washed out by irrigation: this serves to complete the diagnosis and may affect a cure.

**Simple puncture and irrigation.**—The particular method of puncturing and the site to be adopted depend on various circumstances, which may be briefly considered.

(1) *Through the alveolus.*—If carious teeth be present, they should be extracted and the antrum perforated through a socket with a small antrum drill (see Fig. 121). This little operation can be easily done under gas. The first molar is the site of election, as its roots are separated by a very thin plate of bone from the floor of the antrum, and sometimes even protrude into the cavity, which is here reached at its lowest point. Should the first molar be healthy it is quite easy to reach the antrum through



FIG. 121.—ANTRUM DRILL.

the socket of the second molar or of either of the bicuspid teeth. If the site of the first molar be selected, the drill should be inserted into the inner root socket and pushed in an upward and slightly inward direction towards the inner canthus of the corresponding eye. If the second molar or the bicuspids be selected the drill should in addition be inclined slightly forwards or backwards respectively. In the case of the bicuspids especially great care must be taken to keep the drill in the exact direction aimed at, as the floor of the antrum anteriorly is often very narrow and may be easily missed. Care must be exercised to prevent the drill slipping when the teeth have been long removed, as the alveolar border tends to become dense and very narrow. The antrum may be missed in the few very rare cases in which it is very small (see Fig. 94), and the drill may perforate the inferior meatus of the nose.

Having established an opening, the nozzle of an antrum syringe is inserted and the cavity washed out with a solution of boracic acid, boiled salt solution or other unirritating fluid, bending the patient's head well forward so that the solution may flow out by the nose. After cleansing the cavity, a small tube of silver or gold is inserted, and this is best fixed by a dentist to a neighbouring tooth. The tube should be about  $\frac{1}{2}$ - $\frac{3}{4}$  inch long, so as just to reach above the floor of the antrum, should exactly fit the perforation, and should be provided with a small projecting rim, so that it cannot slip up into the antrum, as frequently happens with ill-

devised appliances. The irrigation should be repeated twice daily until the discharge lessens considerably, then once daily. If after a time no discharge is seen, the irrigation may be omitted for a few days, and if then no pus be found the tube may be removed, and the hole allowed to close.

Should this simple method succeed in greatly reducing the amount of the discharge but fail to produce a cure, the dry treatment may be tried. Having washed out the discharge any lotion remaining in the cavity is drawn off by using the syringe as an aspirator, and then a little dry powder, such as boracic or iodoform powder or a mixture of equal parts of the two, is insufflated. This treatment is repeated daily and occasionally, though it rarely is successful in producing a cure after irrigation alone has failed.

*The advantages* of the method of alveolar puncture are that after a day or two the irrigation may be safely entrusted to the patient, who rarely experiences any trouble in carrying it out, and thus it may easily be continued for a prolonged period; that the extraction of the carious teeth is always advisable as they may be a source of irritation to the antrum even if they are not the actual cause of the trouble; that the antrum is opened at its lowest point; and that the operation is easy, especially if the puncture be made through the socket of the first or second molar.

Another advantage is that no ill effects follow the operation: the only trouble ever met with is hæmorrhage; this may arise from extraction of the tooth or from the drilling of the antrum, and if troublesome can be controlled by pressure or by packing the wound.

The method has *the disadvantages* of establishing a communication between the antrum and the mouth, which provides a possible entrance for sepsis or for particles of food into the antrum, and moreover the plug may interfere with mastication, but these latter objections may be prevented by a suitable adjustment of the tube. Further, the pus entering the mouth gives rise to an unpleasant taste and may, if swallowed, upset the patient's digestion.



FIG. 122.—LICHTWITZ'S TROCHAR AND CANNULA.

(2) *From the inferior meatus.*—When no carious teeth or vacant spaces are present and the case is obviously of nasal origin, puncture from the inferior meatus of the nose should be performed. The nose is anæsthetised by packing a large pledget of wool soaked in a solution of cocaine (see p. 284) beneath the inferior turbinate. A small trochar and cannula, such as Lichtwitz's (see Fig. 122) is passed into the inferior meatus, and is directed strongly outwards about half an inch behind the anterior extremity of the inferior turbinate so as to bring it in contact with the antro-meatal septum at its thinnest part, the trochar being concealed

within the cannula. The trochar is then extruded from the cannula and the instrument is forcibly pushed onwards in an outward, backward, and slightly upward direction into the antrum and, the trochar being withdrawn, the cavity can be washed out through the cannula. The operation is usually easy if care be taken to make the puncture just a little above the thick ridge of bone which occurs at the junction of the external wall with the floor of the nose. In a few cases difficulty may arise if the antrum be very small, if the outer wall of the nose curve strongly outwards, if the inferior turbinate be very large or if the septum be strongly deflected.

This method has the *advantages* that it does not entail the sacrifice of a healthy tooth where no carious tooth or vacant space is present; that it only requires local anæsthesia; and that it does not establish a communication between the nose and the mouth. It has however the great *disadvantage* that the opening cannot be maintained and that the operation

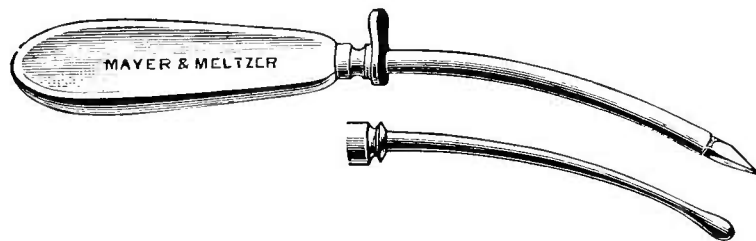


FIG. 123.—KRAUSE'S ANTRUM TROCHAR.

has therefore to be repeated daily, or as often as may be necessary; this renders prolonged treatment practically impossible. This disadvantage however may sometimes be overcome by enlarging the opening with a large trochar, such as Krause's (see Fig. 123), or by the use of a drill or burr, a small portion of the anterior end of the inferior turbinate being previously removed to allow freer access to the part. This larger opening may show little tendency to close and the patient can be taught to irrigate the cavity himself.

(3) *Through the canine fossa.*—In a few cases in which it seems probable that secondary pathological changes have occurred in the antrum, which will keep up suppuration, it is advisable to open the cavity through the canine fossa. The opening is made with gouge or chisel, and should be large enough to allow exploration of the interior of the cavity with the probe or finger, and thus the cases in which a simple opening and irrigation will be obviously insufficient to effect a cure can be at once submitted to a more radical procedure.

In considering the question of a cure by these means, it is safe to say: (1) that in cases of dental origin, recent or chronic, a large majority are cured; (2) that in recent cases of nasal origin a majority are cured; (3) that taking all cases together, about fifty per cent. are cured and every case is greatly relieved; (4) that the cure depends to a large extent upon the care with which the patient conducts the after-treatment.

It should be noted that if pus reappears in the nose immediately after washing out the antrum, there are such strong probabilities of other cavities being involved that they should be at once explored and treated if found diseased.

**The radical cure.**—A cure cannot be expected from the above methods when there are secondary changes in the lining membrane of the antrum, such as polypi or caries of the antral walls, when the antrum contains a foreign body or when it simply acts as a reservoir for pus coming from the other cavities. Also it may be said that the longer suppuration has persisted the less is the likelihood of a cure, but no hard and fast time limit can be fixed, for many cases have been cured after pus has been present for many months or even years. But even if these methods of treatment fail to effect a cure, the patient may yet feel so well that he prefers to remain as he is and to continue the daily irrigations rather than undergo a radical operation. In these circumstances there is probably but little danger of further trouble provided irrigation be practised regularly, and patients will often wear tubes without harm for many years. In a few cases however caries of the anterior wall of the antrum may ensue with painful swelling of the cheek and the formation of an abscess, or in other cases an abscess may form in the hard palate. Occasionally necrosis and perforation of the inner wall occurs leading to a large communication between the antrum and the inferior meatus; but this is rather an advantage than otherwise. A more frequent cause of trouble is the formation of polypi in the antral cavity rendering irrigation impossible. A patient who declines to undergo a radical operation should therefore be warned of the above risks and told that an operation may at some future time become necessary.

*Indications.*—The more radical methods of treatment of suppuration in the antrum must now be considered. A thorough operation is always to be recommended (1) When there is distension of the walls of the antrum or inflammation of the overlying tissues. (2) When an external sinus communicates with its cavity. (3) When polypi are present, or caries of the walls of the antrum. (4) When the above-mentioned simpler methods fail to effect a cure. In connection with this last point it is safe to say that if the discharge does not greatly diminish after the first few washings, and if it continues in any quantity after three months' treatment, a cure can hardly be expected. It is true that a case is occasionally reported in which irrigation is successful after having been continued for six months or even a year, but this is quite exceptional.

In all operations devised for the radical cure of suppuration in a large bony cavity like the antrum the points to remember are that the rigid walls will not collapse, that the cavity is too large to fill with granulation tissue and that the natural opening will not allow of efficient drainage. Obliteration being therefore impossible, the aim of surgical measures must be to provide suitable permanent drainage. Thus the old method of

making a large opening into the mouth is not to be recommended, for a permanent opening in this position is by no means desirable.

The best method of obtaining permanent free drainage in all cases of chronic suppuration in the antrum is to establish a large opening between that cavity and the inferior meatus of the nose, which shall be permanent and large enough to prevent subsequent accumulation of pus in the cavity. The operation consists of the following steps. 1. An incision about 1 inch long is made over the canine fossa at the reflection of the mucous membrane from the alveolar border on to the cheek and carried at once right down to the bone, and the periosteum is reflected both above and below

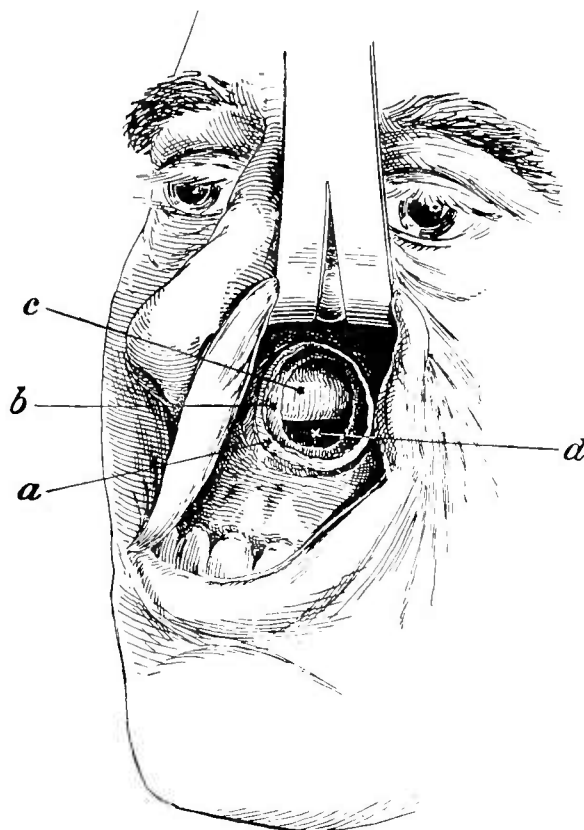


FIG. 124.—THE RADICAL OPERATION UPON THE MAXILLARY ANTRUM. *a*, Outer wall of antrum; *b*, inner wall, the removal of this should be much more complete than is here shown; *c*, outer surface of inferior turbinate; *d*, inferior meatus.

the incision. 2. A large opening is next made in the anterior wall of the antrum, preferably by chiselling, through which the finger is passed and the interior of the cavity thoroughly explored. 3. All polypi and granulations are removed and carious spots of bone thoroughly scraped, taking care not to remove the lining membrane of the cavity for, as has been said above, the antrum is generally too large a cavity to fill with granulation tissue. 4. Finally a large opening is broken into the inferior meatus of the nose by puncture with a large trochar or by a burr. The whole of the septum between the antrum and the inferior meatus is then chipped away piece by piece with the bone forceps or chisel (see Fig. 124). After the completion of the operation the outer opening is allowed to close and all subsequent treatment is conducted from the nose. The opening into

the nose is usually permanent, does not require a drainage tube or packing to maintain it, does away with the necessity of any special after-treatment, and lastly, it gives rise to no subsequent inconvenience. The external wound falls naturally together and sutures are useless.

The *after-treatment* consists in washing out the nose with boracic acid solution once daily or oftener if necessary until all discharge ceases. When there is much discharge or the antral cavity is much diseased, a syringe with a suitable nozzle should be passed under the inferior turbinate into the antrum and this cavity also washed out. A suitable syringe may be easily improvised by attaching a Eustachian catheter to the end of a small ball nasal syringe with or without an intermediate piece of tubing. By these means a cure is almost invariably obtained in the course of a few weeks, and even in cases in which the antrum acts as a reservoir of pus the large opening will prevent its accumulation in the cavity.

The whole point of the operation is the establishment of a large opening from the antrum into the inferior meatus of the nose, and attempts have been made to effect this without making the opening through the canine fossa as above described. The operation through the nasal fossa without extensive damage to the inferior turbinate is extremely difficult and almost impossible and a preliminary Rouge's operation although rendering it easier has disadvantages which more than outweigh those attaching to the canine fossa route.

**(b) Of suppuration in the ethmoidal cells.**—Free access to the larger part of these cells cannot be obtained by an external operation, unless it be very extensive and one which would probably result in considerable disfigurement. Operation, therefore, entails the difficulty of working through a long narrow passage where the limits of safety cannot be accurately seen: in fact it means to some extent working in the dark. One would think that operation ought to be somewhat dangerous in such a region under such conditions, and no doubt untoward results have occasionally occurred, but it seems probable that these have been due to the methods commonly adopted, and that a radical operation can really be comparatively safely performed. Moreover, the risks must be balanced against the danger and inconvenience entailed by leaving the disease alone, for in this region suppuration is extremely liable to extend not only to the antrum and frontal sinus but also to the orbit and perhaps the cranial cavity. It must be remembered, too, that polypi are a very frequent result of ethmoidal disease, and when due to this cause the simple removal of polypi will fail to give a satisfactory result. There is rapid recurrence which necessitates repeated operations, and the patient's life becomes a burden. These patients are frequently debilitated and are quite commonly incapacitated from earning their living, especially if this involves mental labour. Head-ache, inability to fix the attention, and eye troubles are all common results of ethmoidal disease. This serious inconvenience quite justifies a more radical operation, even if it be attended by some slight risk. At the

same time, complete removal of these cells leads to no ultimate ill result, and an intra-nasal operation entails no risk of facial deformity.

The treatment of suppuration in the ethmoidal cells consists in the removal of all polypi, etc., and in opening and curetting the affected cells, or, in the more severe cases, in practically destroying the whole of the ethmoidal cavities. The operation to be performed varies somewhat with the number of cells affected and with their position, and the treatment will therefore be discussed under the following three heads: (1) When only a few of the more readily accessible cells are affected; (2) when the whole or greater part of the ethmoidal region is involved; and (3) when the anterior set, or fronto-ethmoidal cells, are affected.

1. *When a few cells only are affected*, as shown by the small amount of discharge and the limited extent of caries, polypi and œdema, a small operation only is required. The polypi if present are first removed with the snare (see p. 318), then later, either with local or nitrous oxide anæsthesia, the affected cells are opened and their walls cut away. When passing the snare round the polypus it is a good plan to include as much bone as possible, and in the subsequent treatment more bone should be cut away with Grünwald's forceps or with the ring-knife, the latter being generally the more useful instrument. The cavity opened is then packed with cyanide gauze for a few days, and complete recovery should ensue. When necessary, in order to gain access to the affected part, a portion of the middle turbinate may be removed (see p. 317).

2. *When there is a more extensive affection of the ethmoidal region* it is better to give a general anæsthetic and to do a radical operation at once, for under these circumstances the removal of the polypi, which are always present, is useless, recurrence being rapid and continuous. When the patient is anæsthetised, a finger is passed up into the nose and the ethmoidal region is thoroughly examined. Having determined as far as possible the extent of the disease, the finger is withdrawn and a large ring-knife, such as Meyer's original adenoid curette or a spokeshave, is passed up through the nose. The finger is then introduced into the post-nasal space, and, guided by it, the curette is hooked round the posterior end of the middle turbinate, when, by dragging the knife forward, the whole bone can be removed, often in one piece. The lateral mass of the ethmoid is then repeatedly and firmly scraped, large masses of polypi, degenerated mucous membrane and bone being removed. From time to time the finger is introduced into the anterior nares to observe the progress, to feel for loose spicules of bone and any soft patches, and the scraping is continued until all friable tissue has been thoroughly removed, which is often best completed by using a smaller ring-knife. On completion of the operation the nose is packed with a strip of gauze to prevent hæmorrhage.

The anæsthetic naturally requires great care. In the less severe cases nitrous oxide may be used, but ether, or ether followed by chloroform, is usually necessary and is always to be preferred. The ring-knife of Meyer

is much more effectual than any sharp spoon. The amount of tissue to be removed varies with the extent of the disease. In many cases some parts of the ethmoidal region seem healthy to the touch and should then be left alone. These healthy parts are at once distinguished by the finger and even by the curette, for they are firmer and smoother and give little hold for the knife. The diseased parts on the other hand feel like soft, gelatinous masses containing crumbling bone, and are very easily curetted away.

In some cases the whole lateral mass of the ethmoid must be scraped away until a large portion of the periosteum lining the orbit is exposed. If the posterior part of the ethmoid seems unaffected, a large sponge should be pushed up into the post-nasal space to prevent blood entering the throat during the operation. If the whole ethmoidal region is affected this cannot be done, and in these circumstances the operation should be performed with the patient lying on his side so that the blood flows freely from the mouth and nose. The gauze used for packing is soaked in glycerine and iodoform emulsion to prevent it adhering and to render its removal less painful and difficult. It should be changed every second or third day for a fortnight, and then omitted and the nose simply irrigated. For a time granulations are seen in the field of operation and may even become exuberant. If however the operation has been thoroughly performed, as above directed, these will as a rule disappear spontaneously in a few weeks, and in the meantime they seem to cause very little discomfort. The discharge diminishes at once and finally disappears when healing is complete and the headaches as a rule immediately cease. The ultimate results are extremely good. In a few cases hæmorrhage is severe but it is always easily controlled by packing with gauze: in a few cases a "black eye" is produced, especially when the orbital plate has been injured. The majority of the cases run an afebrile course, and I have never seen any cerebral trouble result.

In cases of purely ethmoidal disease a cure is obtained as a rule after one operation, but if gas be used and the operation be not thoroughly done a second operation may be necessary. Polypi thus removed do not recur, the purulent discharge ceases and a large dry cavity lined by healthy mucous membrane results in the upper part of the nose and all bare bone heals over.

Of course when frontal sinus or other trouble is present this must be treated before the discharge from the nose will cease, but even then polypi are in most instances cured by a single operation. Thus, when ethmoidal disease is present, this proceeding forms an indispensable preliminary to operations on both frontal and sphenoidal sinuses. The repeated small nibbling operations commonly recommended for the treatment of this disease may undoubtedly result in success ultimately but there are very considerable objections to the method. It is extremely tedious and discouraging to the patient who derives little or no benefit from the earlier



operations and often decides to abandon the treatment; the constant pain and the nervous dread of it causes general ill-health; and each operation exposes a raw surface over which pus flows so that there is necessarily a certain amount of septic infection. Fatal results have followed from meningeal affection apparently directly due to the minor operation. The operations do not at once cut short the disease, which meanwhile may spread and involve other nasal cavities. Finally, cocaine is in these cases a very imperfect anæsthetic and consequently the repeated operations are extremely painful. It therefore seems probable that these small operations are more dangerous than a single severe but curative measure.

In all cases of suppuration in the ethmoidal cells it is particularly to be remembered that other sinuses may be simultaneously or subsequently affected. Therefore the antrum should be explored before or during the operation, and the frontal and sphenoidal sinuses at some later date should the discharge still persist.

3. *The fronto-ethmoidal cells* are those forming the nasal floor of the frontal sinus and surrounding the infundibulum. From a surgical standpoint they are best regarded as forming part of the frontal sinus, and the treatment of suppuration in them will be best discussed in connection with that cavity.

(c) **Of suppuration in the sphenoidal sinus.**—This is usually simple when once the diagnosis has been made. This may be accomplished by examining the anterior wall of the sinus by the finger passed through the mouth and pushed well up into the posterior choana of the affected side. In some cases caries can thus be detected on the anterior wall of the sinus and the softened bone may give way on pressure being applied. In such cases the finger should be slipped into the cavity and its interior examined, and then a sharp spoon or small ring-knife should be passed through the anterior nares and guided by the finger, all carious bone should be removed and the interior of the cavity scraped out.

An example may be quoted. A general anæsthetic was given for the removal of several large gangrenous polypi associated with an intensely fœtid discharge from the left nostril. The left forefinger was passed well up into the posterior choana and guided by it many polypi were removed by the forceps, the posterior end of the middle turbinate was scraped away with a large ring-knife and the posterior ethmoidal cells freely opened. Whilst exploring and curetting this region a large carious patch was detected on the anterior part of the sphenoid. This gave way under slight pressure and the tip of the finger suddenly entered a large cavity almost filled by numerous small, soft growths. The interior of this cavity, which careful exploration showed could only be the sphenoidal sinus, was scraped out and the opening into it was enlarged by breaking down the carious anterior wall with the curette and finger. The patient soon recovered and after healing a large irregular opening into the anterior wall of the sinus could be plainly seen from the front. The suppuration was entirely cured.

This method of diagnosis and treatment however is only applicable when there is extensive caries of the anterior wall of the sinus—probably an infrequent complication. In other instances in which sphenoidal sinus suppuration is suspected but in which no caries is detected, it is imperative that the natural opening of the sinus should be brought into view and except in a very few instances this can only be done by removing the posterior half or more of the middle turbinate. This then should be done and a probe passed into the sinus through its ostium and its interior examined as far as possible in order to detect carious bone, polypi, etc. The sinus can now be washed out by means of a suitable cannula, and if no disease of the bony walls can be detected it may be treated simply by daily irrigations for a time. Should these means fail to reduce the discharge, or if after a time a cure has not been effected, the opening should be cautiously enlarged. A hooked probe is first inserted into the sinus and rotated in various directions so as to determine its extent, and then one blade of a suitably shaped Grünwald's forceps (see fig. 116) is passed into the cavity and bits of the anterior wall cut away. This little operation is best performed under cocaine as it is necessary to thoroughly illumine the parts and to see accurately what is done. After removing the anterior wall, the interior of the cavity can be curetted if necessary and daily washed out until the discharge ceases. By these operations a cure is easily obtained, as the opening shows very little, if any, tendency to close. The operation should be perfectly safe but care must be taken not to use the curette too forcibly as serious accidents have resulted from this procedure. If there be caries of the upper wall the cavernous sinus may be accidentally opened by the curette, and therefore such a possibility must be borne in mind.

The sphenoidal sinus may also be opened with a probe-pointed, sickle-shaped knife, but in most cases considerable force is required to cut through the bony wall and the method seems neither so safe nor so convenient as that above described. The sphenoidal sinus varies very greatly in size and extent, and is rarely symmetrical; consequently no attempts should ever be made to perforate it with a trochar and cannula or with the drill, unless its extent has been previously determined with the probe. It may be noted that a large number of the cases of sphenoidal disease occur in connection with atrophic rhinitis and in consequence the widened nostrils allow a good view of the anterior wall of the affected sinus, and thus the treatment is rendered easier.

(d) **Of chronic suppuration in the frontal sinus.**—The frontal sinuses are cavities with rigid bony walls, varying greatly in size and extent, and having important relations with the brain on the one side and the orbit on the other. In order to cure suppuration within them it is necessary either to obliterate them entirely or to establish a free escape for the discharge externally or into the nose. Taking their prominent position into consideration, every endeavour must be made to avoid any operation which

might lead to deformity. The problems presented are therefore extremely difficult and the treatment of chronic suppuration in the frontal sinus is the subject of great controversy, especially with regard to the advisability of intra-nasal treatment.

**Intra-nasal treatment.**—This much however must be generally admitted, that in all cases in which suppuration in the frontal sinus is suspected, and in which no urgent symptoms are present (see p. 353) antral suppuration should be eliminated, and intra-nasal treatment should be adopted to the extent of removing the anterior end of the middle turbinate and clearing away all polypi, œdema or swelling in the neighbourhood of the infundibulum and in most cases of opening up the anterior ethmoidal cells; for in nearly every case of frontal sinus suppuration these cells will be found involved. Moreover they may be the sole source of the discharge, for in the majority of cases there is no certainty that the frontal sinus is the source of the pus until it has been laid open. These means alone may effect a cure and in any case they aid the success of subsequent operation.

This treatment having been carried out and free access having been obtained to the infundibular region, the probability is that if pus still continues to come down in any quantity it really comes from the frontal sinus. Cautious attempts may now be made to pass a suitable cannula into the sinus, and, if successful, intra-nasal irrigation may be practised.

A study of the anatomical relations of the parts (see p. 266) will readily demonstrate the great difficulty there is in passing a probe through the nose into the normal frontal sinus. It is only possible to do so in about 25 per cent. of cases and, what is more to the point, there are no means of knowing that the probe is actually in the sinus, even when it apparently passes far up along the infundibulum. The chief obstructions to the entrance of the probe arises from the prominence of the anterior end of the middle turbinate which entirely conceals the infundibular region from view, from the formation of the uncinatè process, from the prominent bulla ethmoidalis, from the presence of an abnormal hypertrophy, and in many cases from the long and tortuous course of the infundibular canal. Also in many cases the probe will enter the ostium of one or other of the anterior ethmoidal cells. But in cases of frontal sinus suppuration the fronto-ethmoidal cells are often broken down and if in addition the anterior end of the middle turbinate be removed and the approach to the infundibular region be thoroughly cleared as above described, the passage of a suitably curved probe is much facilitated and will probably succeed in about 50 per cent of cases with care and patience. An easily bent probe should be used and in each case careful measurements should be made; the course of the infundibulum, and any obstructions met with should be carefully recorded, a fine flexible cannula should then be bent to the shape of the probe and a separate instrument must be kept for each individual case.

Having inserted the cannula the sinus is washed out through it with

a mild antiseptic solution such as boracic acid. After a time other antiseptic fluids may be used, and recently formalin has been strongly recommended, but it matters very little what is used provided it be unirritating.

To carry out this treatment properly it is necessary for the surgeon to see the patient every day for from three to six weeks, and this is one of the most obvious objections to the employment of the method. Moreover it generally fails to produce other than temporary benefit. It may be that some of the successful cases are cases of suppuration in the ethmoid cells and not in the frontal sinus at all; but this can hardly be urged as an objection to the method, for if a cure results it matters nothing which cavity was affected; in either case an external operation on the frontal sinus has been avoided. In some cases of course there is danger in delaying a radical operation; namely in those in which there is caries of the posterior wall of the sinus. There is however probably very little risk when there is free communication between the sinus and the nose, and fortunately these are just the cases in which irrigation is most easy.

This method of intra-nasal irrigation itself is difficult and sometimes impossible, but with great care and the avoidance of the use of force the danger of perforating the floor of the skull is probably very slight. It seems probable however that there is a real risk of infecting a healthy sinus by passing the catheter through a suppurating region in order to reach it. In all cases in which there is difficulty in entering the sinus it is wisest to desist, as it is never right to employ force. Methods of entering the sinus by puncture from the nose need only to be mentioned in order to be condemned.

**Radical treatment.**—If the above treatment fails, the question arises if it is better to leave the patient alone or to perform an external operation. Unfortunately experience has shown that these operations are by no means free from danger and that they frequently fail to cure the suppuration. On the other hand the risk of leaving the disease alone does not seem to be great, provided free drainage be maintained. In many cases suppuration has existed for ten, twelve, or even sixteen years without affecting the patient's general health or incapacitating him from work. The frontal sinus, having a dependent opening, the discharge usually leaks away; changes in its bony walls are very seldom found and actual necrosis is very rare; and lastly cerebral complications are extremely uncommon. Therefore in cases in which no symptoms are present other than persistent nasal discharge, these facts must be clearly laid before the patient and he must decide as to operation. In these circumstances he will often decline it, in which case he should be seen from time to time so that polypi, etc., may be removed as they occur, and free drainage maintained.

In other cases, however, operation may be required for one or more of

the following reasons—1. Pain, which may be severe: in some cases it is described as maddening, and though intermittent it lasts hours or even days at a time, during which the patient is totally incapacitated. In other cases there is frequent and severe headache, rendering the patient unable to work or to attend to household duties. 2. Deficient drainage. The opening into the sinus may be small and frequently blocked and in these cases delay in operating is dangerous. 3. Bulging of the cavity or a discharging external sinus. These conditions imply disease of the bony walls and naturally demand operation. 4. Symptoms of cerebral trouble are an urgent indication for operation. 5. General ill-health, if apparently due to the disease. Probably as operative methods improve and become less risky, operation may be advised in nearly every case in order to stop the irritating nasal discharge, to prevent the recurrence of nasal polypi and granulations and to remove the liability of complications supervening.

In advising an operation for the cure of frontal sinus suppuration the great variation in size to which this cavity is liable must be considered. It may be an extremely small cavity; only the orbital or lower portion may be present, the anterior or upper portion being entirely absent; or it may be an extremely large one extending upwards from the supra-orbital margin for an inch and a half or more, outwards to the extreme outer angle of the orbit and backwards over the roof of the latter as far as the sphenoid.

It is obviously impossible owing to the situation of the sinus to establish a permanent external opening, and therefore in chronic cases in which the walls of the cavity are extensively diseased there is practically the choice of only two proceedings: either to entirely obliterate the sinus, or to remove the whole of the nasal portion of its floor and to establish a large communication between it and the nose.

*Operation.*—The following are the steps of the operation which I prefer. A large sponge with a tape attached to facilitate its removal is passed through the mouth and tightly packed up into the post-nasal space. The eyebrow having been shaved and the skin cleansed, an incision is made in the line of the eyebrow or a millimeter or so below it and parallel to the supra-orbital margin, commencing at the inner end of the eyebrow and passing outwards to the supra-orbital notch. It should be carried at once down to the bone and the periosteum thoroughly divided. A median incision is preferred by some and has the advantage of allowing the exposure of both sinuses through one incision, but it is much more liable to lead to deformity, and when both sinuses are affected it is better to make the incision described above on either side. The incision below, or in the line of the eyebrow, will ultimately become entirely concealed; it allows free exposure of both the anterior and inferior walls of the sinus, and if required may be conveniently prolonged downwards towards the inner canthus and thus allow free access to the infundibulum and anterior ethmoidal region. After the periosteum has been detached, a small opening

is made with a chisel through the inferior wall of the frontal sinus. This opening should be made at a spot on the supra-orbital margin vertically above the inner canthus, for if a frontal sinus exist it is certain to be met with here. It must be remembered that there is no diploic tissue at all in the inferior wall and only very little in the anterior. Therefore when definite diploë is exposed, it is probable that the sinus is absent and the operation must be stopped. For this reason it is safer to use a gouge or chisel rather than a trephine.

Having opened the sinus, a probe is passed into it to ascertain its extent, and the opening is then enlarged sufficiently to enable its interior to be thoroughly examined. If no pus be found, the wound is carefully sutured, and if the whole operation has been done aseptically no trouble will ensue.

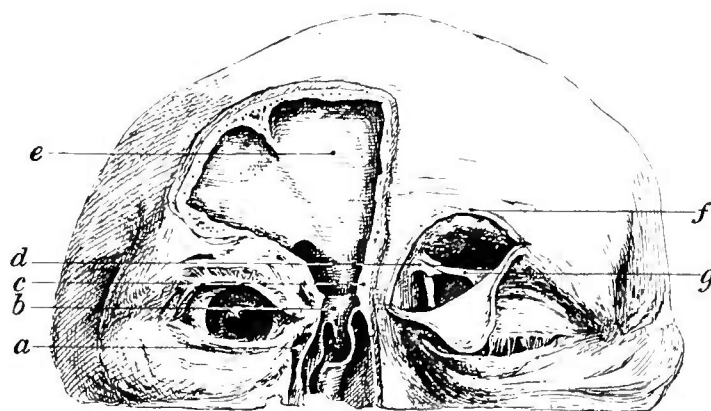


FIG. 125.—A DISSECTION TO ILLUSTRATE THE RELATIONS OF THE FRONTAL SINUS. The right frontal sinus and the infundibulum have been freely opened from the front. On the left side a flap has been turned back, as in operations on the sinus, to show the position of the pulley of the superior oblique. *a*. Lachrymal duct; *b*. commencement of the infundibulum; *c*. nasal septum; *d*. pulley of the superior oblique; *e*. cavity of the frontal sinus; *f*. line of incision in the supra-orbital margin; *g*. tendon of the superior oblique.

If pus be found, the skin incision should be extended downwards in a curved direction to the level of the inner canthus. The periosteum should then be detached downwards and backwards from the inferior wall of the sinus, in doing which the pulley of the superior oblique muscle may be displaced (see Fig. 125). This gives rise to no subsequent trouble; slight temporary diplopia may occur but soon passes off and is probably due to effusion into the orbit rather than to the interference with the muscle. The opening into the sinus is now enlarged by cutting away its inferior wall, and the inner wall of the orbit is removed as far down as it has been exposed by the incision so as to give free access to the infundibulum. If the sinus contain polypi they are removed and the bony walls carefully examined for caries, perforation, etc., which if found must be dealt with.

The question whether to attempt obliteration of the sinus or simply to procure free drainage must now be decided. Obliteration leads to a certain, and usually speedy, cure, and is always to be preferred when the sinus is

not too large. In such cases it may be done with extremely slight deformity; it is especially desirable when there is caries of the bony walls, and should always be done if possible when the posterior wall is deficient, or when brain symptoms are present. In some exceptional cases the sinus is so extensive that obliteration is impracticable; and in others it is so large that the resulting depression would be most noticeable and unsightly, and then drainage must be relied upon.

*Obliteration of the cavity.*—To obliterate the cavity the entire anterior and inferior walls of the sinus must be removed; this may be done with the chisel or bone forceps. The probe is then passed down the infundibulum to serve as a guide, and all the bony cells anterior to it, between it and the lower part of the wound, which form the floor of the frontal sinus, are entirely removed, and the infundibulum is also enlarged posteriorly: in this way the whole nasal portion of the floor of the sinus is removed and the anterior ethmoidal cells are freely opened. A finger passed up from the nose is a good guide whilst curetting the infundibulum, and the hole should be made sufficiently large to enable the finger in the nose to touch a finger in the wound. The mucous membrane lining the sinus is then thoroughly scraped away, special care being taken to empty any recesses. Any bony excrescences must also be chipped away.

A large drainage tube is then passed down the infundibulum, its upper end fixed to the skin at the inner angle of the wound and the lower end brought out through the anterior nares. The rest of the wound is now sutured with some non-absorbent material such as silkworm gut, the skin and periosteum being carefully united and allowed to fall back in contact with the posterior wall of the sinus, and finally the wound is dressed with a pad of boracic lint which should be kept wet with a solution of boracic acid and frequently changed. This solution may be iced for the first 24 hours, the cold being exceedingly comforting to the patient and tending to prevent swelling and extravasation into the orbit. The wet dressing also seems to facilitate the healing of the wound.

Considerable œdema of the upper eyelid usually follows the operation and the patient has a black eye for a few days, but such symptoms soon disappear. The wound usually heals by first intention and the sutures may be removed by the seventh to the tenth day. The drainage tube should be syringed through daily and should be changed about the fourth day. To do this a fresh piece of drainage tube is attached by a long piece of silk to the upper end of the old tube and then this latter is drawn down out of the anterior nares. The track of the tube may now be thoroughly cleansed by syringing and then the second drainage tube can be drawn into position by means of the silk thread. If there be much discharge the drainage tube may be removed daily. After about a fortnight all dressings may be left off and the drainage tube replaced by a small solid plug of indiarubber with a flange to prevent it slipping into the sinus (see Fig. 126). The lower end of this plug should just be visible in the middle

meatus of the nose. It should be removed daily for syringing the nose and the track, and should be worn for three or four weeks until all suppuration has ceased.

The after results of this operation are excellent. The free drainage provided prevents the danger of any ill results from septic absorption or diffuse osteitis and a permanent cure of the sinus suppuration invariably follows. If the operation be reserved for selected cases, namely, those in which a small frontal sinus is present, it will not entail any marked deformity. Even when the sinus is large, the deformity is much less marked than would be expected.



FIG. 126. — INDIA-RUBBER PLUG FOR FRONTAL SINUS.

*Drainage.*—If, on the other hand, it be decided not to attempt obliteration, the sinus is first cleared of all polypi, etc., should such exist, and thoroughly cleansed, taking care to injure the mucous membrane as little as possible. Many operators advise, and presumably practise, free curetting of the lining membrane, apparently oblivious of the fact that this can only retard healing, for, if obliteration is not aimed at, a cure depends entirely upon the membrane returning to its normal condition. This will occur if all gross lesions, such as polypi are removed, and re-accumulation of pus prevented by free drainage, and all the quicker if no injury be inflicted on the mucous membrane.

Having cleansed the sinus, the infundibulum must be opened up and the anterior ethmoidal cells removed as above described. The whole success of the operation depends upon maintaining a large permanent communication between the sinus and the nose. The following method of drainage will usually be found satisfactory. A large rubber tube is passed down the infundibulum into the nose and fixed in the way just described, the rest of the wound being sutured and allowed to heal. After five or six days this tube must be replaced by a suitably curved silver one something like an ordinary tracheotomy tube. This tube should have a small collar which will prevent it slipping into the sinus and its lower end should pass well down into the nose. Such a tube may be readily removed for purposes of cleaning and to allow of syringing of the sinus and can be readily replaced in position. After the wound has healed, the patient simply wears the tube with a metal plug in it and no dressing. Such a tube may be worn, without causing any discomfort, until all discharge of pus has ceased when it may be discarded and the wound will rapidly close. This procedure, by which drainage may be continued for as long as may be necessary, will prevent any of the accidents which have followed the other methods of providing drainage and will also, by being maintained until the opening into the nose has thoroughly healed, ensure that it becomes permanent.

This question is one of the greatest importance. The general custom is to pass a large-sized ordinary rubber drainage tube down the infundibulum



into the nose bringing it out at the anterior nares and retaining the upper end of it *in the sinus* either by means of a suture passing through the edges of the wound or by a slight collar around the upper edge of the tube. The external wound is entirely closed and the sinus can be washed out by syringing up the tube. This tube, however, can only be retained in position for from five to ten days because of the irritation it produces, and therefore this method of securing drainage is inefficient as it is given up before sufficient time has been allowed for healing to take place. The external wound may indeed close, but after removal of the tube the opening into the nose rapidly fills up with granulations and commonly pus re-accumulates in the sinus. Many operators even advise that no tube should be used, but when the rapidity with which extensive œdema occurs in the nasal mucous membrane is remembered and the profusion and size of the granulations which form is taken into consideration, it is at once obvious that the largest opening that can be made will rapidly close. With this method then it is not at all remarkable that pus should form and accumulate in the sinus within a very few days. Such bad results have occurred in the experience of almost every surgeon. Sometimes the skin wound has given way and external drainage has had to be resorted to, but in a very considerable percentage of cases the presence of the pus under pressure in contact with the freshly opened diploë of the frontal bone has given rise to an acute spreading osteitis which has invariably ended fatally sooner or later. Any operation therefore not providing efficient measures for drainage must be unreservedly condemned.

A simple large opening providing external drainage is only successful in a very small percentage of cases, as success depends upon the mucous membrane of the sinus returning to a healthy condition and on the infundibulum resuming its functions. This will rarely take place when secondary pathological changes have occurred and a permanent opening in this position is very disagreeable to the patient.

To sum up the treatment of frontal sinus suppuration: (1) In all suspected cases intra-nasal treatment should be first tried, and free access to the lower end of the infundibulum should be obtained by removing the anterior end of the middle turbinate along with any polypi present. (2) Nasal irrigation should then be carried out for a few weeks and cautious attempts should be made to wash out the sinus from the nose. (3) If no improvement results, the sinus should be opened externally and no attempt should ever be made to forcibly enter it from the nose. The frontal sinus when opened externally and found to contain pus should be obliterated (*a*) in cases where the sinus is small, for then the operation is easy and the resulting deformity very slight; (*b*) when the posterior wall is carious or perforated; (*c*) when cerebral symptoms are present; and (*d*) when there is no infundibulum. In all other cases where pus is found a free opening should be made into the nose and drainage maintained until all suppuration has ceased.

## MUCOCELE OR CYSTIC DISEASE OF THE ACCESSORY SINUSES.

**Causation.**—The accessory sinuses are lined by a secreting mucous membrane, and if from any cause the opening of the cavity becomes obstructed, as from pressure or catarrh, the secretion naturally accumulates in the sinus and in time distends its walls. The affection is by far most common in the ethmoidal region. As already described (see Fig. 92) there is a small cell normally existing in the anterior end of the middle turbinate, which has a tiny opening near its apex. From the small size of this opening and the great liability of this region to become involved in any nasal catarrh, obstruction frequently results and the small cell becomes transformed into a cyst which may enlarge until it occludes the nose. When the antrum is similarly affected the inner wall commonly gives way and produces obstruction of the nostril on the affected side while the anterior wall bulges into the cheek. If the lateral ethmoidal cells are affected, there is a marked widening of the base of the bridge of the nose and the contents of the orbits are displaced outwards. The frontal sinuses usually yield at the inner portion of their inferior wall, pressing the eyes outwards and downwards and occasionally giving rise to a large boss on the forehead. The pressure may be so great, especially if the disease occur in children, that the sutures of the bones may be opened up and the lachrymal bone be displaced downwards and a large fluctuating swelling present itself at the inner angle of the orbit. The contents of the cavities vary from a clear, watery, to a more or less thick mucoid secretion.

**Treatment.**—*In the case of the antrum* the best plan is to puncture the cavity from the inferior meatus with a large trochar, such as Krause's (see Fig. 123). The opening thus made will probably be permanent and sufficiently large to effectually drain the cavity.

*In the case of the ethmoidal cells*, the affected cell usually bulges into the nose so as to resemble a polypus. The best plan is to pass a snare round it and to remove as much of its walls as possible. Should the cyst so completely fill the nose that this is impossible, a portion of its floor may be removed by cutting forceps and the walls subsequently cut away.

*In the case of the frontal sinus* the treatment depends upon the size of the cavity. If it be small, it is better to open it freely, to scrape away the entire mucous membrane and to pack it. The packing is continued until the cavity is entirely obliterated by granulation tissue. If the cavity be extremely large, and in some of these cases it may have a capacity of half an ounce, it is better to endeavour to re-establish communication with the nose. The cavity is opened in a similar way as for chronic suppuration, a large communication with the nose is made with a burr or a chisel, and a large drainage tube inserted. The mucous membrane of the cavity is left untouched as far as possible. The tube or plug must be worn for many months, until it seems certain that the new formed infundibulum will not contract.

## CHAPTER XXXII.

### DISEASES OF THE NASO-PHARYNX.

#### ACUTE NASO-PHARYNGITIS OR ACUTE POST-NASAL CATARRH.

THIS affection is usually associated with acute rhinitis, but may occur separately. It is common in children with adenoid growths, but may also be found in adults. It is accompanied by general malaise, painful feelings in the back of the throat, and is very liable to be associated with Eustachian obstruction, ear-ache, and deafness. The affection is usually a mild one, and subsides in a few days. The treatment is similar to that of an ordinary cold (see p. 295), but especial attention must be directed to the ears in order to prevent acute otitis (see 384).

#### CHRONIC POST-NASAL CATARRH.

This is a very common condition, and is associated with excessive discharge of mucus from the naso-pharynx. The mucus is especially annoying in the morning, having collected during the quiet breathing of sleep, and on rising a great quantity may be coughed or 'hawked' up. The affection is especially common among dwellers in cold damp climates, in dusty places, and in large cities. Many cases are associated with enlargement of the pharyngeal tonsil, and it also frequently occurs in adults who have undoubtedly suffered from adenoids in earlier years. It is most commonly met with, however, as the sequel of a neglected cold in the head, especially in those who are in any way debilitated. The use of tobacco or alcohol is a well-recognised predisposing cause. In some cases the secretion can be seen lying in a fold or crypt in the median line of the post-nasal space, a central depression between the lateral adenoid masses of the pharyngeal tonsil, commonly called the pharyngeal bursa. The affection is essentially a chronic one. It is always worse in winter and damp weather, and improves greatly in warm dry weather.

**Treatment.**—In the first place it is well to seek for and remove

any underlying diathesis present. Thus, excessive alcohol and smoking must be at once prohibited, and cigarette smoking especially should always be entirely given up. Attention must also be directed to bathing, clothing, and general hygiene, and especially to the state of the digestive organs: dyspepsia and constipation are constant associates of this affection, and until they are remedied a cure cannot be expected.

The local treatment consists in keeping the naso-pharyngeal space absolutely clean and free from all discharge. At least twice daily a nasal wash should be used, such as Dobell's solution (see p. 282), in the same way as already described for chronic rhinitis; this is usually quite as effectual as spraying or syringing the space directly through the mouth. Should the case resist this treatment, the post-nasal space should be painted once daily, and subsequently three times a week with a paint, of which Mandl's solution is one of the best. This solution contains iodine, grs. 5; potassium iodide, grs. 15; menthol, minims 5; and glycerine, to the ounce. A solution of silver nitrate (20 to 40 grs. to the ounce) may also be used.

In all cases in which there are the remains of adenoid growths, especially in cases associated with ear symptoms, it will be necessary to remove the growths, and, even in cases in which a very little growth is present, thorough scraping of the post-nasal space will sometimes effect great improvement. Attention should also be directed towards disease in the nose. Thus, hypertrophy of the posterior ends of the inferior turbinates should be sought for, and, if found, remedied (see p. 306). Again, some obstinate cases may ultimately be found to depend upon sphenoidal sinus disease (see p. 349).

#### POST-NASAL ADENOID GROWTHS.

These growths are common in children and tend to atrophy at the age of sixteen, but may be met with up to thirty or even later. They are by no means rare in infants and it would seem that they may even be congenital. They may be hereditary and are often associated with a peculiar malformation of the bones of the face leading to narrowing of the nasal passages and a high arched palate. They are more common in cold, damp climates and amongst certain races. The most common exciting causes are frequent nasal catarrhs, the exanthemata, diphtheria, sore throats and whooping cough.

**Pathology.**—The growth is a simple hypertrophy of the normal lymphoid tissue of the post-nasal space and forms a large mass in the vault of the naso-pharynx, usually with a median cleft; from this central mass two bands usually extend downwards and to each side and become lost behind the posterior pillars of the fauces. Isolated nodules of lymphoid tissue are also seen lower down in the pharynx and occasionally extend on to the upper part of the nasal septum. Not uncommonly masses are

found filling Rosenmüller's fossæ (the deep depressions in the lateral wall of the pharynx behind the Eustachian tubes), and these masses may be adherent to the Eustachian cushions.

**Symptoms.**—The presence of adenoid growths may be productive of various troubles, the most important of which may be briefly noted. There is a great susceptibility to colds and to repeated attacks of post-nasal catarrh, which commonly give rise to Eustachian obstruction, intermittent deafness and, in the more severe cases, recurrent attacks of suppurative otitis. The obstructed nasal respiration renders mouth-breathing necessary, and children who have adenoids may be generally recognised by the constantly open mouth and the stupid expression, which may be actually associated with ineptitude for mental exertion. Further, the obstruction to respiration is more marked during sleep, when the mouth is closed by the approximation of the tongue to the palate. Consequently the child's sleep is broken, he suffers from frequent "night-terrors," and on waking he is not refreshed, but complains of headache and giddiness. As a result of the broken sleep the general health suffers, the child becomes anæmic, wasted and stunted in growth. In infants or in growing children the difficulty of breathing may also give rise to the well-known form of "pigeon-breast" or to well-marked depressions in the epigastric or the lower sternal regions. When these symptoms are present, the removal of the adenoids by operation is invariably necessary.

Among other less frequent consequences of adenoids are the presence of a constant, irritating, short, barking cough which hardly ceases all day long, a tendency to chronic laryngitis, to bronchitis and to attacks of laryngismus stridulus. These conditions do not perhaps entirely depend upon the presence of adenoids, but in the majority of cases great improvement, and in not a few an absolute cure, may be obtained by removing them. A few other conditions, such as stammering, hay fever, hay asthma, and incontinence of urine in children have been ascribed to the presence of adenoids, but it is impossible to predict with certainty that improvement with regard to these symptoms will be obtained by operation.

**Treatment.**—The first point to decide is the question of operation—whether the case may be treated for a time with palliative remedies or whether it is better to remove the growths at once. This question must be decided by the severity of the symptoms which can be fairly ascribed to the presence of the growths, and not in any way by the amount of growth present. Very marked improvement in some cases may follow the removal of a very small amount of growth; on the other hand a large growth sometimes produces no symptoms of importance. The operation, however, is by no means severe, and if any of the symptoms above enumerated be present, it is better to remove the growths. In other cases expectant treatment may be adopted and the case watched. Should urgent symptoms at any time arise, operation can be carried out, but if the patient is able to adopt proper precautions, in many cases the necessity

for this will not arise and, as the child grows older, the growths will atrophy.

**Palliative.**—The object of this treatment is to place the child under the best hygienic conditions and to keep him free from catarrh. Under such circumstances adenoids may give rise to no symptoms. The best plan, when practicable, is to send the patient away to the seaside, to keep him as much as possible in the open air and to attend carefully to all questions of diet. A warm, bright, dry place should be chosen, cold and damp being avoided. This should be combined with the administration of suitable tonics such as cod-liver oil and the syrups of the phosphate or iodide of iron.

**Operative.**—The risk of operation is probably very slight. The dangers to be guarded against are those of the anæsthetic, of possible hæmorrhage, of asphyxia from blood entering the air passages, of subsequent pneumonia, of sepsis and especially of acute suppurative otitis with its complications.

*The anæsthetic.*—In children over ten and in adults, especially if the growths be limited to a large central pad, nitrous oxide anæsthesia is sufficient. When however the growth is filling Rosenmüller's fossa, is adherent to the posterior lips of the Eustachian tube, or when associated with the adenoids there are other hypertrophies, such as enlargement of the posterior ends of the inferior turbinates, a more prolonged anæsthesia is necessary, and for this purpose gas and ether is probably the best. A prolonged anæsthesia is always advisable when operation is undertaken for the relief of marked deafness. In the majority of cases in *children* it is best to give chloroform or ether, or one of the anæsthetic mixtures. Probably the most convenient and safest measure is to commence with the A.C.E. mixture and to complete the anæsthesia by giving pure ether which may be safely pushed until the palate is sufficiently relaxed to enable the operation to be easily carried out, but at the same time the cough reflexes should not be completely abolished and the patient should be able to swallow the blood as it accumulates in the pharynx. This method usually allows three or four minutes' good anæsthesia, and this is usually sufficient time to thoroughly remove the growth, but if necessary it may be prolonged by giving chloroform through a Jünker. In giving the anæsthetic, the existence of nasal obstruction must be remembered and therefore free mouth-breathing must be allowed, and a gag inserted if necessary.

*The instruments.*—For the removal of the growths a post-nasal curette—such as some modification of Gottstein's—and adenoid forceps are required. The points to be attended to in choosing the curette are that its top cutting edge should be fairly strong and not too thick, and that it should be attached by two bars which are parallel and which do not meet at an angle as in many of the instruments (see Fig. 127). It may be provided with a hook or cage to catch the growth, and it is well to have two currettes

of different sizes. The best forceps is some modification of Löwenberg's, such as Juracz's (see Fig. 128). These instruments should have shorter and more slender handles than those commonly used and the blades should be fenestrated and cutting so as rather to punch out the growths than to tear them away. In addition to these instruments a large powerful gag, such as Mason's, is necessary and, if gas be given, a Wingrave's gag or the ordinary dental prop.

**The operation under gas.**—In this method the patient is usually anæsthetised sitting upright in a dental chair, but the supine position may



FIG. 127.—MODIFIED GOTTSTEIN'S POST-NASAL CURETTE.

be used if preferred. The patient should face a strong light, or better still, should sit in the same position with regard to a lamp as for an ordinary laryngoscopic examination (see Chap. XXXVIII.), and the light should be reflected into the throat by means of a frontal mirror. The anæsthetic having been given, the dental prop is changed for a powerful gag and the mouth widely opened. Unless a good view of the growths has been previously obtained it is well to commence the operation by inserting the index finger of the left hand well up into the post-nasal space and to

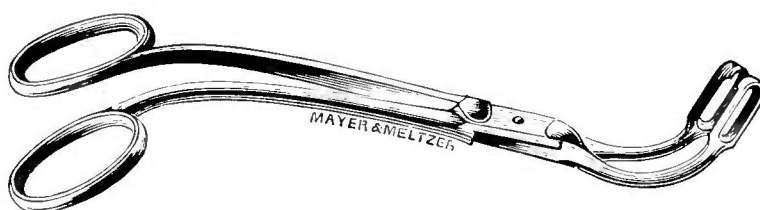


FIG. 128.—JURACZ'S POST-NASAL FORCEPS.

examine rapidly the site of the growth, to see whether or not it spreads on to the Eustachian cushions, and also to ascertain the existence of hypertrophy of the posterior ends of the inferior turbinates. The curette is passed well up behind the soft palate until it touches the lower part of the nasal septum. It is then pressed upwards and backwards, keeping the blade in contact with the bony septum, until the roof of the naso-pharynx is reached. The knife being now in position, it is necessary to see that the handle is exactly in the middle line. Now firmly pressing backwards, the handle of the instrument is sharply raised, the blade swept down over the posterior wall of the naso-pharynx, and the major portion of the growth is cut off in one piece. This curette with the growth attached is removed, the smaller instrument introduced and three or four rapid sweeps made over the post-pharyngeal wall. The finger is again introduced to ascertain that the operation is complete. In some cases the growth will be found to have

been left hanging by a small thread of mucous membrane, and directly the patient comes out of the anæsthetic this will set up violent coughing and retching; it must always be sought for and can be easily removed with a pair of forceps, aided if necessary with the scissors. The bleeding is usually free for a second or so but rapidly ceases and requires no special treatment.

**The operation under chloroform.**—This operation should be performed with the patient lying down, either on a flat table or with a small pillow beneath the head. The position with the head hanging well down over the end of the table, although commonly adopted and strongly recommended, has no advantages; it is much more difficult and takes more time to thoroughly remove the growths in this position; moreover, the chief immediate danger of the operation—*asphyxia* from entrance of blood into the upper air passages—is probably greater, as the veins in the neck are congested and the hæmorrhage is thereby increased. Also in this position the throat is much narrowed, its capacity for holding blood is less and it is more difficult to introduce the finger. With the patient lying flat, the operation can be performed easily and quickly, and upon this its safety really depends. Should any trouble arise from obstructed breathing—which will only occur when the anæsthesia has been pushed too far—the patient should be immediately rolled over on to his face, when the blood will run out of the mouth and throat and the breathing will be at once relieved.

The surgeon must stand facing and on the right-hand side of the patient, and it is well to operate upon a low couch or table so that the surgeon stands well over the patient. The left forefinger is introduced into the post-nasal space and the palate hooked well forward. The forceps are introduced closed, widely opened when in position, and the growth pressed between the blades with the finger tip. The forceps being closed, the growth is partly cut and partly pulled away, the left forefinger being pressed against the mucous membrane so as to prevent it from being torn. Piece after piece of the growth should be removed, special care being taken to clear Rosenmüller's fossæ, the Eustachian tubes and the upper part of the septum. Damage to the two latter structures must be sedulously avoided.

Having removed the greater part of the growth it is well to introduce the curette and to remove all soft projecting pieces from the back of the pharynx, as by this plan a quicker and more perfect result can be obtained than by using the forceps alone. Should the growths in Rosenmüller's fossæ be very tough or difficult to get at, their removal can often be effected by means of Meyer's original ring-knife passed through the nose, or its handle may be bent so as to allow it to be introduced through the mouth. This may be used as an ordinary curette; the cutting blade being sharp, it is a very effective instrument.

The adenoids being removed, the posterior ends of the inferior turbinates



should be examined with the finger and, if at all enlarged, a piece should be removed with the snare (see p. 306). Next the tonsils, if enlarged, as they so commonly are in association with adenoids, should be removed with the guillotine. Some surgeons prefer to remove the tonsils at the commencement of the operation, but this is not to be recommended. The removal of the adenoids is more easily accomplished during the earlier and deeper stage of the anæsthesia and the bleeding after tonsillectomy is more sudden and profuse and therefore it is better delayed until the patient shows signs of coming out of the anæsthetic. The hæmorrhage during the operation is usually free, but it soon ceases. As a rule the patient swallows the blood, but, should it accumulate in the back of the pharynx during the operation, the throat may be sponged out or, better still, the patient should be rolled over on to his side and the mouth wiped out. Should blood enter the larynx or trachea, the patient must be immediately rolled over on to his face and the head lowered; if this be done in time, and the anæsthesia be not too deep, the blood will soon be expectorated and the dyspnœa will pass off. Should the patient become cyanosed, the throat should be vigorously sponged out to excite a reflex and the finger should be pushed down into the larynx to remove any clot that may be within reach. Of course in extreme cases the child must be inverted and artificial respiration adopted, and, should this fail, tracheotomy will be necessary; this fortunately is an extremely rare event. Immediately the operation is finished, the patient is rolled over on to his face, the mouth is sponged clean and the gag loosened, as the stretching of the mouth tends to maintain the hæmorrhage.

*After-treatment.*—The patient should be kept in bed for one or two days after which he may be allowed to sit up and, if fine, may go out of doors about the third or fifth day. The first food given after the operation should always be cold for fear of exciting hæmorrhage, but after 24 hours in children, and certainly after 48 in adults, ordinary food may be given. As a rule it is not well to bother the patient with any active after-treatment, but the nose and ears should always be carefully examined. At the first sign of inflammation of the drum or of increase in deafness a blister should be applied to the mastoid region and the nose should be washed out with a simple alkaline lotion (see p. 300). Moreover, if at any time a bloody or muco-purulent fœtid discharge collects in the nose or throat it should be syringed away with a solution of boracic acid. Should there be any hæmorrhage, an ice-cloth should be applied to the face and ice given to suck; if it be really profuse or prolonged it may be necessary to check it by means of the tannic and gallic acid paste.

*Results.*—The result of the operation is always or nearly always extremely good. The difficulty in breathing usually disappears after a few days and the deafness, if due to Eustachian obstruction, also rapidly recovers. In some cases however these symptoms require further treatment. Other symptoms are more slow to go, but the habit of keeping the

mouth open, the peculiar speech, the facial expression, etc., all generally disappear in time, especially if the parent take pains to teach the child. The improvement in general health is frequently remarkable.

*If the removal be thorough recurrence will be very rare.*—After imperfect operations, such as scraping with the finger-nail or with the artificial nail, recurrence is extremely common since complete removal of the growth by these means is impossible. The younger the patient the greater is the risk of recurrence, especially if the patient subsequently suffers from one of the acute exanthemata, from repeated sore throats or nasal catarrhs. With children under the age of seven a guarded prognosis must invariably be given with regard to this point, but in patients over ten it may be stated with some confidence that the growths will not return.

## SECTION II.—AFFECTIONS OF THE EAR.

### CHAPTER XXXIII.

#### GENERAL METHODS OF EXAMINATION AND TREATMENT.

IN this chapter will be considered the methods of examining by illumination the accessible parts of the ear, namely the external auditory meatus, the membrana tympani and the pharyngeal ends of the Eustachian tubes; the means of determining the mobility of the drum and the patency of the Eustachian tubes: and the tests employed to ascertain the existence and variety of any defect in the hearing power. The complete examination of the ear requires also a thorough investigation of the condition of the Nose and Throat and of the general health, and a complete clinical history of the patient.

**Examination.**—The best sources of illumination have been already described in the chapter on the examination of the nose (see p. 276). For

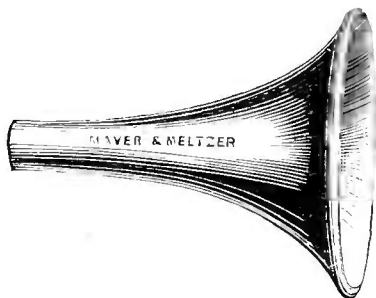


FIG. 129.—DALBY'S AURAL SPECULUM.




FIG. 130.—GRUBER'S AURAL SPECULUM.

reflecting the light into the meatus the ordinary frontal mirror (see p. 277) may be employed, but some surgeons prefer a hand-mirror with a short focal distance of five or six inches. This latter is only of use for purposes of examination and cannot be used in operating. To examine the inner part of the external auditory meatus and the drum it is convenient to employ a speculum such as Dalby's or Gruber's (see Figs. 129 and 130), the former being especially useful in operative work: those made of metal

are stronger and take up less room. The internal surface should be blackened so as to diminish the reflection of light. To introduce the speculum, the auricle is taken between the surgeon's third and fourth fingers (the left hand being employed for the right ear, and *vice versa*), and is drawn a little upwards, backwards and outwards so as to straighten the cartilaginous portion of the tube. The speculum is warmed and then gently inserted; when in position, it is retained by the thumb and fore-finger of the hand that holds the auricle. The unemployed hand should now be placed upon the patient's chin so as to move the head into any required position.

For a minute examination of the membrana tympani some surgeons prefer a Brunton's auriscope which gives a greatly magnified view of the parts and is occasionally most helpful. The size and shape of the

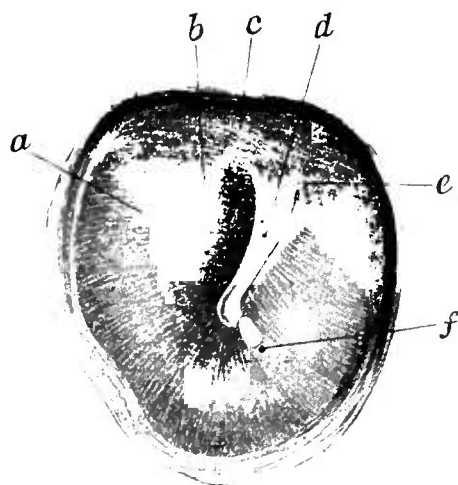


FIG. 131.—THE MEMBRANA TYMPANI. *a*, Stapedius tendon; *b*, incus; *c*, Shrapnell's membrane; *d*, handle of malleus; *e*, short process of malleus; *f*, cone of light.

external meatus vary considerably in different patients, and therefore ear specula in three or four different sizes are required. In some cases it is quite impossible to obtain a view of more than a portion of the membrane, especially when the lower and anterior walls of the meatus form a considerable projection. If, as often happens, particles of wax or débris obstruct the view, these should be removed with forceps or cotton-wool mops on a probe, using great gentleness. If much wax or secretion be present it is necessary to syringe the ear.

**The tympanic membrane.**—The drum is normally greyish, bluish or slightly pink in colour and is somewhat bright in lustre but semi-opaque. Near the upper part of its circumference is the projection of the short process of the malleus (see Fig. 131), and passing downwards and backwards from this towards the centre of the drum is the handle of the malleus. Running anteriorly and posteriorly from the short process, towards the periphery of the drum are seen curved folds which divide the membrane into two; the upper and smaller portion is called Shrapnell's membrane.

Passing from the tip of the handle of the malleus, in a downward and forward direction, is a cone-shaped reflection of light, the apex commencing just below and in front of the centre of the drum, where the light is most bright, and the base being close to the periphery, where the light gradually fades away. When the membrane is very thin, and especially when it is also indrawn, there is visible a small white or pinkish line parallel to the handle of the malleus and just above and behind it. This is the processus gracilis of the incus, and passing backwards almost horizontally from its lower end another line may be seen corresponding to the tendon of the stapedius muscle. In the posterior and inferior quadrant may occasionally be seen a deep roundish depression corresponding to the fenestra rotunda. The projection of the promontory near the centre of the drum may also be visible

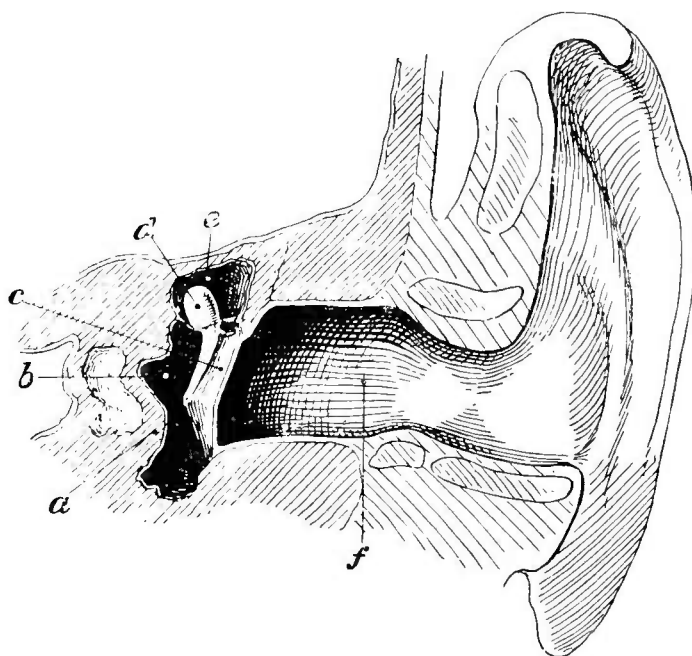


FIG. 132.—VERTICAL TRANSVERSE SECTION OF THE EAR. *a*, Promontory; *b*, tympanic cavity; *c*, membrana tympani; *d*, head of malleus; *e*, aditus ad antrum; *f*, external auditory meatus.

It must be remembered that the drum is inclined to the vertical at an angle of about  $45^{\circ}$  (see Fig. 132). When the membrane is indrawn, the short process of the malleus and the folds in the drum are more prominent; the handle of the malleus is considerably foreshortened, and the cone of light is absent or broken.

To determine the mobility of the membrane, a pneumatic speculum such as Siegle's is required (see Fig. 133). One end of this fits tightly in the meatus while the other is closed by a glass plate. The air pressure within the speculum, and so within the external meatus, can be increased or diminished by alternately compressing or relaxing an india-rubber ball attached to its side by a tube. A piece of rubber tubing may be placed over the end of the speculum so that it may fit more closely into the external meatus. When the air is condensed, the membrane moves inwards,

and when the air is rarified it is sucked outwards. The presence and extent of adhesions between the membrane and the ossicles and the inner wall of the tympanum are thus determined. The presence and extent of thin cicatrices in the drum are also shown by the undue flaccidity of the parts.

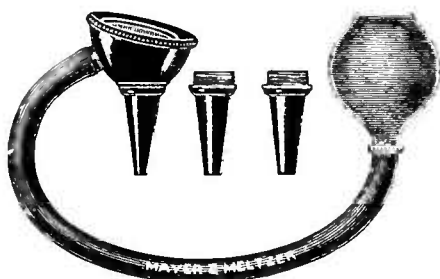


FIG. 133.—SIEGLE'S SPECULUM.

**Examination of the Eustachian tubes.**—The pharyngeal end of the tubes and the adjacent parts must be examined by illumination as in posterior rhinoscopy (see p. 279) and their patency ascertained by inflation. The chief methods of doing this are as follows:

**1. Valsalva's method.**—The patient is directed to close the anterior nares by grasping the nose tightly with the finger and thumb and then to blow forcibly into the nose. If the Eustachian tubes be patent, air will be felt to enter and distend the tympanum. In some cases a better result is obtained if the patient, having filled the nose with air, performs the act of swallowing. The surgeon can confirm this result, either by watching the membrane, which can be seen to move, or by the use of the otoscope. The latter instrument consists of a long india-rubber tube with vulcanite or ivory ear-pieces, one of which is introduced into the ear of the patient and the other into that of the surgeon. Care must be taken that the tube hangs freely and is not pressed upon or bent at a sharp angle. By its means the air entering the tympanum may be heard to impinge upon the membrane. This experiment, and indeed any method of inflating the ear, must not be repeated too frequently or the membrane is apt to become unduly flaccid.

**2. Politzer's method.**—In this method air is forcibly blown into the the naso-pharynx by means of a large air-bag, while the naso-pharynx is shut off from the pharynx by raising the patient's palate. The nozzle of the bag is fitted into one nostril and the other is closed by compression. The patient is now told to take a sip of water and slowly swallow it. At the instant of swallowing, while the palate is raised, the air-bag is suddenly compressed and thus air is forcibly driven into the Eustachian tubes. A simpler method of raising the patient's palate is to ask him to close the mouth and forcibly distend the cheeks with air. Or again the patient may be told to whistle loudly. This is the most valuable of all means of inflating the ear both for purposes of diagnosis and treatment, and it may be used with success even in cases in which acute catarrh is present.

**3. The Eustachian catheter.**—This is a silver tube about four and a half inches in length with a curve at its distal extremity. At the outer end of the catheter a ring is attached to indicate the direction of the curve when the instrument is introduced. The air is blown through it by means of a small india-rubber bag with a nozzle fitting into the funnel-shaped end

of the catheter. Before introducing the catheter, the nasal passages should be examined in order to ascertain the presence and position of any obstruction. If the patient be sensitive and the passages narrow, a little cocaine should be sprayed into the nose. It aids the introduction of the catheter not only by producing anæsthesia but by diminishing the swelling of the erectile tissue of the inferior meatus.

The patient is seated with his head resting against the back of the chair, and the surgeon stands on the right side of and facing him. The catheter is then passed along the inferior meatus, taking great care to keep its tip in contact with the floor of the nose. The greatest gentleness must be exercised and the catheter allowed to move in any direction so as to find its own way. As soon as its tip touches the posterior wall of the naso-pharynx, *the anterior end* of the instrument is slightly raised, and is withdrawn for about half to three-quarters of an inch until the beak is felt to be in contact with the posterior edge of the hard palate. The catheter is then rotated through a quarter of a circle until the beak points directly outwards. It is then pushed a little onwards and is usually felt to slip easily into the opening of the Eustachian tube. When in position, the catheter does not move when the patient swallows or speaks, and it seems to be somewhat fixed if an attempt be made to rotate or push it onward. If care be not taken to keep the tip of the catheter in contact with the floor of the nose, the instrument is apt to pass into the middle meatus, and when it reaches the post-nasal space it will be found impossible to rotate it. The above manipulation is the best for those who have acquired no special skill in this work. An experienced surgeon can with practice simply pass the catheter straight back along the inferior meatus, and directly he feels it drop over the posterior margin of the hard palate, rotate it directly into the opening of the tube. When the catheter is in position, the nozzle of the air-bag is connected with it and held in position by the forefinger and thumb. The sound of air entering the tympanum is at once recognised through the otoscope, as seeming to be quite close to the surgeon's ear. If the Eustachian tube be patent, the air impinges on the drum with a dull sound; if the tube be obstructed, the sound has a more or less whistling character. The presence of fluid in the tube or middle ear is recognised by bubbling and cracking sounds. When the drum is perforated or absent, the air seems almost to be blowing directly into the surgeon's ear and this is accompanied in the case of small perforations by a loud whistling noise.

*Difficulties in passing the catheter.*—When any difficulty is experienced in introducing the catheter into the Eustachian orifice after passing it into the post-nasal space, the instrument should be rotated a quarter of a circle *inwards* and then withdrawn so that it may come into contact with the posterior edge of the septum nasi. It must then of course be rotated a half circle outwards to bring it opposite the Eustachian tube. In other cases various expedients may be tried, such as altering the curve of the instrument,

using a smaller catheter, allowing it to completely rotate in the nose, or the nose may be thoroughly anæsthetised and the catheter inserted under direct illumination. When one nostril is completely blocked, an attempt should be made to reach the tube by passing the catheter through the opposite nostril. The beak of the catheter must then be longer and more strongly curved.

*Dangers in passing the catheter.*—If the catheter be employed carelessly or with force, there is a risk of producing *emphysema*. This can only happen if the mucous membrane be injured by the point of the catheter, and therefore is more likely to occur when there is inflammatory swelling or ulceration. If a catheter be used in such a case, and the air be forced through it before it is certain that the instrument is in its proper position, very extensive emphysema of the throat, or even of the whole neck and head, may be produced. As a rule it passes off rapidly and produces no ill effect, but it is an accident which ought never to occur, as it means that unnecessary force has been employed, or that the air passages in the neighbourhood of the Eustachian tube are inflamed or ulcerated, in which case the catheter should not have been used.

Comparing these three methods of inflation, the catheter should be used when the other methods are ineffectual or when it is designed to obtain more accurate information as to the condition of the Eustachian tubes or of the presence or absence of fluid in the tympanum. It is also valuable when one ear alone is involved and it is not desirable to inflate the healthy ear. Politzer's method is the most simple and generally useful for treatment, and the patient can be easily taught it. Valsalva's method is only sufficient in cases of very slight obstruction. No method should be frequently used or employed for a long time unless under the careful supervision of the surgeon, as forcible inflation is apt to produce flaccidity of the membrane.

**Eustachian bougies.**—These are very fine flexible rods, best made of celluloid. They are inserted through the Eustachian catheter after the latter has been placed in position. They are used in cases of obstruction of the Eustachian tube which do not yield to catheterisation. Care must be taken not to pass the bougie too far into the tube, the length of which varies, the average being about an inch and a half. The method is one capable of producing serious mischief; it must always be employed with the greatest care, and it is very doubtful if any permanent good results can be obtained by it.

**Estimation of the hearing power.**—The hearing power may be tested by more or less constant sounds, such as the tick of a watch or specially made acoumeters, by the loud or whispering voice and by means of tuning forks. *The watch* is the most convenient test, as its tick is of constant intensity and affords a ready means of recording the progress of a case. *Politzer's acoumeter* may be used when the watch is not heard. *The human voice* is however the most important test of hearing power, as



the patient naturally seeks advice chiefly because he is unable to hear conversation. A large room is generally required: the patient is placed at one end and the examiner taking his stand at various distances, repeats certain words, such as the numbers, in a loud tone, and measures the distance at which the patient can hear and repeat them correctly. It is necessary that the patient should not see the lips of the speaker, and also to remember that some words can be heard normally at longer distances than others. With a little practice it is easy to regulate the loudness of the voice. The hearing should also be tested by means of whispered speech, which is much more likely to be uniform.

**The tuning-forks.**—These are used for the purpose of ascertaining the cause and location of the deafness. The most generally valuable test is Rinne's. If the vibrating tuning-fork be placed in contact with the mastoid process until the sound is no longer heard and is then brought near to the external auditory meatus of the normal ear the sound is again perceived. This is called a *positive* result or positive Rinne. If, on the other hand, the sound is not again perceived, the result is called *negative*. In deafness solely due to an affection of the middle-ear or of any part of the conductive apparatus the hearing power by bone conduction is increased and therefore Rinne's test is negative. In many cases of old-standing middle-ear disease there is also some associated affection of the labyrinth, and in old people bone conduction is often diminished: even in these cases however it will be usually found that the hearing power by bone conduction is greater than by air conduction if a tuning-fork of about 512 vs. be used.

In cases of unilateral deafness, Weber's test may be employed. It consists in placing a vibrating tuning-fork upon the middle line of the vertex when in cases of pure middle-ear deafness the sound will be louder in the affected ear.

The use of a series of tuning-forks, the lowest about 25 vs. and the highest 30,000 vs., also yields valuable information. In internal-ear deafness the higher notes are badly heard or even lost, while considerable hearing power for the lower notes is retained. In middle-ear disease the reverse is the case, the lower notes being badly heard while good hearing power is frequently retained for the higher notes. In doubtful or mixed cases also, this series of tuning-forks may be employed in Rinne's test. If some internal-ear affection be present in a case of middle-ear disease the forks lower in the scale will often give a positive result while with the higher notes a negative result is obtained. If this change occurs at or below a tuning-fork of 512 vs. the case may be considered one of middle-ear disease.

## CHAPTER XXXIV

### AFFECTIONS OF THE EXTERNAL AUDITORY MEATUS.

**IMPERFORATE MEATUS.**—This is a rare deformity and is almost always associated with malformations of the auricle. The obstruction may be osseous or fleshy, but even in the most extreme cases there is a dimple or a cul-de-sac over the site of the meatus. Usually the deformity is associated with almost complete deafness, but occasionally there may be fair hearing by bone conduction.

**Treatment.**—It is impossible to rectify the deformity of the auricle by any operative procedure. The most that can be done is to restore the auditory meatus, and this is only advisable in a few selected cases where there is a considerable amount of hearing power by bone conduction associated with some hearing by air conduction, especially when both sides are affected. A crucial incision should be made over the site of the dimple or cul-de-sac above mentioned, the flaps should be reflected and an attempt made to find the auditory meatus. Should the obstruction turn out to be osseous, the operation must be abandoned, as it is very dangerous to proceed, and failure is almost certain. When the stricture consists of soft parts only, these should be cut away freely and the canal enlarged as much as possible by removing a slice of the bone from its posterior and upper surface. The canal should then be firmly packed until granulation is established, when the whole of the raw surface should be skin-grafted by Thiersch's method. The packing should be continued until healing is complete, and subsequently it may be necessary for the patient to wear a small ivory or silver tube to prevent recurrence of the stricture.

**Traumatic stricture of meatus.**—In very rare cases an imperforate or greatly constricted meatus is met with as the result of an injury, such as a burn or the insertion of corrosives into the ear, etc. In these conditions the attempt to restore the meatus should always be made and will generally succeed. As the amount of injury and deformity vary, no definite directions for operation can be given. In some cases a flap may be dissected up from the stricture, the latter excised and the flap used to cover some

of the resulting raw surface. In others where much deformity is present it can be considerably reduced by turning in a flap from the neighbouring tissues. Also skin-grafting, if required, may be carried out at the time of the operation. By these methods a complete recovery is commonly obtained, but in the more severe and intractable cases operation and after-treatment must be carried out as for the congenital deformity just described.

**FOREIGN BODIES IN THE EXTERNAL MEATUS.**—Almost any variety of foreign body may be found in the external auditory meatus of children, the most common being boot-buttons, beads, cherry-stones, peas or beans, etc. These if neglected not uncommonly set up very acute inflammation and may lead to perforation of the membrana tympani; this is most likely to occur when the foreign body is sharp or jagged. Considerable trouble may be caused if the foreign body consist of a substance liable to swell up and to decompose after introduction, such as beans and similar vegetable bodies. In adults a mass of cotton-wool is not uncommonly met with, which has been put into the meatus, has slipped further in and been forgotten. This usually becomes soaked in discharge, which decomposes and sets up violent inflammation.

**Treatment.**—This consists in removing the foreign body and subduing the inflammation. If the body be loose, easily seen and but recently introduced, there is little difficulty in effecting its removal either with a pair of aural forceps or, more simply still, by means of a small hook such as Lister's ear-hook (see Fig. 134). If the patient be very nervous or sensitive,



FIG. 134.—LISTER'S EAR HOOK.

and always if the foreign body be tightly fitting or embedded, an anæsthetic should be given. The greatest care must then be used to avoid pushing the body further in or injuring the external meatus; in unskilled hands the membrane may be easily punctured, and even the ossicles have been removed through carelessness. When the foreign body is simple and unirritating, it may be quite easily and painlessly removed by means of syringing, and this method should always be adopted by those who have no special skill or training in aural surgery. After the foreign body has been removed the auditory meatus should be syringed out with a mild warm antiseptic such as boracic acid solution, and any inflammation present should be carefully treated until a cure has been obtained (see p. 378).

**OBSTRUCTION OF THE EXTERNAL AUDITORY MEATUS.**—This may arise from accumulations of wax or epidermic scales or a mixture of the two, together with hairs, pus, etc., in varying proportions. Accumulations of cerumen are more likely to occur when the external meatus is narrowed or encroached upon, and when the wax is deficient in watery constituents. In some persons these accumulations recur periodically. The epithelial debris may form large, compact, leathery masses, and most

commonly occur in patients who have suffered from old middle-ear disease or from some affection of the external auditory meatus such as eczema. The flakes are extremely adherent and very difficult to wash away. As a rule these accumulations produce deafness only when they fill the meatus, and this commonly occurs suddenly from rapid swelling when a little fluid has been allowed to enter the ear. In a few cases vertigo or tinnitus may be present.

**Treatment.**—When wax is present, the first essential is to remove it, which may be accomplished by syringing the ear immediately or after a previous use of instillations to soften the plug. For this latter purpose glycerine or almond oil, with one part in twenty of carbolic acid, may be used, a few drops being warmed and poured into the ear night and morning. A simple method is to heat a teaspoon, put three or four drops of the oil into it, and then, while the patient lies on the opposite side, to pour the drops from the teaspoon into the ear. After three or four days the wax is usually softened sufficiently to be easily washed away. To syringe the ear, a large brass syringe with a fine nozzle should be used with which the water can be injected with considerable force. The patient should sit opposite a strong light and the meatus should be straightened by drawing the auricle upwards, backwards and slightly outwards. The water or lotion used for syringing should be as hot as the patient can comfortably bear it. The stream should be directed at various angles along both the floor and the upper part of the meatus and continued with occasional intermission for inspection of the ear until all the wax has been removed. Occasionally syringing excites giddiness, when it must be stopped and the wax thoroughly softened before it is again gently repeated. After cleansing the ear, it is better to wear cotton-wool for a few hours or at least until the patient reaches home. He should be cautioned always to remove the wool and not allow it to be forgotten and retained in the ear. In oldish people or in those subject to such accumulations, the ears should be examined periodically and if necessary washed out. No attempt should ever be made to remove plugs of wax with the forceps or with the hook.

*The masses of epithelium* (or cholesteatomata) are much more difficult to deal with. As much should be syringed away as possible and then under good illumination the scales should be carefully detached from the walls of the meatus by means of a fine probe or scoop. Small pieces may sometimes be removed with the forceps and then the syringing should be repeated. It may be necessary to repeat this treatment on several occasions and in the intervals the patient should be instructed to syringe the ears two or three times a day. The greatest care must be used to avoid injury of the meatus or of the drum, as these plugs are generally adherent to the latter. In children an anæsthetic is invariably necessary, and even then only a little can be accomplished at one time. With care and patience however the whole mass can be ultimately removed, and then any resulting inflammation must be treated as for otitis externa (*vide infra*).

**CIRCUMSCRIBED INFLAMMATION** or **FURUNCLE**.—Furuncles are most commonly seen in the cartilaginous portion of the meatus and have a great tendency to recur periodically. The exciting cause is that of boils in general, namely, the entrance of micro-organisms and consequent inflammation in the sebaceous glands. The predisposing causes are usually indefinite.

**Symptoms**.—The affection commences with intense pain in the ear followed by tenderness and swelling of the meatus, tragus and sometimes of the parts in front of, behind, and below the ear. The constitutional disturbance is often severe, and the case may resemble an acute mastoid abscess. After a few days the swelling in the meatus becomes localised, points and bursts; there is a little discharge or bleeding and the pain quickly subsides. This is the general mode of termination, but in a few cases the boil apparently disappears without rupture, or more commonly the inflammation partly subsides and again recurs.

**Treatment**.—The best mode of treatment, if the patient be willing to submit, is an incision into the most prominent part of the swelling, which will give immediate relief to the pain even if no pus be evacuated. This little operation may be performed with any narrow-bladed knife, such as a tenotomy knife, under good illumination, and being intensely painful should always be performed under nitrous oxide anæsthesia. The meatus should then be syringed out with a hot solution of boracic acid, the ear and the surrounding parts bathed with hot water, and a piece of boracic lint wrung out of boiling water applied over the ear. These syringings and fomentations should be frequently repeated, every hour if the pain be severe, and will soon give relief. They should be continued until all the acute symptoms have subsided.

In the less severe cases, or when the patient refuses incision, a blister may be applied over the mastoid region, or leeches used; the latter give relief more quickly. In an adult two leeches should be applied in front of the tragus, one below and one behind the ear. These should be followed by syringing with hot boracic lotion and the application of boracic fomentations. When the acute symptoms have passed off, the following should be used:

R	Ung. hydrarg. nitratis,	ʒi.
	Paroleini,	
	Ol. amygdalæ, }	āā ʒss.

A few drops to be warmed and poured into the ear from a teaspoon twice daily.

This is especially useful when there is a tendency to frequent recurrence or when the inflammation does not completely resolve. It also allays the irritation which is commonly present in the meatus after the attack.

Constitutional remedies may also be called for. At the commencement a brisk purge is often useful, and narcotics may be required to allay the pain. Any predisposing cause must be sought for and removed,

and any errors in diet corrected. In many cases tonic treatment is required.

**ACUTE DIFFUSE INFLAMMATION.**—Acute otitis externa is most frequently seen in association with acute suppuration in the middle ear. It may also be due to erysipelas, which not uncommonly commences in the meatus, but generally spreads subsequently to the auricle and to the surrounding skin. In other cases the condition may result from septic wounds or injuries of the external meatus

**Symptoms.**—The affection is accompanied by considerable pain referred to the meatus and front of the ear, the whole of which may be swollen and acutely tender. Examination with the speculum is difficult, almost impossible, on this account. There is commonly a thin watery discharge from the meatus, but, if marked deafness and purulent discharge be present, middle-ear disease must be suspected.

**Treatment. General.**—The patient's general condition is usually such as to confine him to bed, and he should be kept upon a fluid diet: mastication, owing to the pain of moving the jaws, is commonly impossible. The pain in the ear must be relieved by hypodermic injections of morphine if necessary. It is best to commence the treatment by a purge followed by the administration of full doses of perchloride of iron and quinine. The strength must be maintained by giving plenty of nourishment and stimulants as required.

**Local.**—In the severer cases relief is most quickly afforded by leeching the ear, four or five leeches being applied in an adult in the positions above recommended (see above). In the less severe cases a good blister over the mastoid may be substituted. The external meatus should be syringed with boracic lotion as hot as can be borne, the ear and the surrounding skin well bathed with hot water and hot boracic fomentations applied and changed frequently. These should be repeated hourly or every two hours as required until the pain has passed off and sleep is obtained. The subsequent treatment is similar to that of furuncle (see above). When suppurative otitis media is present this must also be appropriately treated (see p. 384).

**ECZEMA OF THE EXTERNAL AUDITORY MEATUS.**—This common affection may be caused by an irritating discharge from the ear, by the presence of a decomposing foreign body, by mycosis, cholesteatoma, etc. In other cases it is dependent upon some constitutional cause, such as gout, when it is commonly associated with a similar condition of the skin.

**Treatment.**—The ear should be syringed, the meatus thoroughly dried and the instillation of oil adopted. In acute cases pure almond oil may be used, a few drops being warmed in a teaspoon and poured into the ear twice or three times daily. In chronic cases the fluid ung. hyd. nit. dil., as above prescribed (see p. 377) should be used, and this should be continued until the affection has entirely disappeared. In the cases associated with

suppuration of the middle ear, which are more common in children, the ears must be frequently syringed and kept free from discharge. They should then be dried, and a little boracic ointment applied to the affected parts: subsequently boracic powder should be blown in.

**OTOMYCOSIS.**—This is a somewhat rare affection, and is due to the presence of a fungus which gives rise to more or less acute inflammation of the external ear. The meatus is usually filled with flakes of epithelium, looking like damp blotting-paper, in which black spots can be seen. Under the microscope amongst this epithelium may be seen a network of mycelium with numerous hyphæ and fructifications. The most common fungus is *aspergillus niger*, the fructifications of which are large and black. *Aspergillus fumigatus* and *aspergillus flavus* are both rare; the fructifications are smaller than those of *niger*; in the one they are described as sooty and in the other they are yellow.

**Treatment.**—All that is necessary is to cleanse the meatus thoroughly by frequent syringing with weak antiseptic solutions, inflammation if present being treated on the lines already indicated (see p. 378). In many cases it is necessary to soften or detach the epithelium by means of oily instillations. Glycerine with carbolic acid (1-20), or nitrate of mercury ointment diluted with oil (see p. 377) may be used. When the inflammation has subsided, the ear is filled up with rectified spirit, which should be retained for about ten minutes. This may be repeated daily for a short time until the meatus is quite healthy.

**TUMOURS OF THE EXTERNAL AUDITORY MEATUS.**—These are all rare, and therefore may be briefly dealt with. The most important of the benign growths are the exostoses, papilloma, fibroma, angioma, and cysts. Polypi and granulations are best considered in connection with suppuration in the ear. The benign growths, with the exception of exostoses, present nothing peculiar in the treatment, and should be dealt with on ordinary surgical principles.

**Exostosis.**—Exostoses are met with in two distinct varieties:

1. *A single pedunculated tumour*, which usually springs from the outer edge of the bony meatus, and especially from the upper or posterior wall. It may be large enough to completely occlude the meatus and to produce deafness, but rarely causes pain or any other symptom. In general appearance the growth resembles a polypus, but it is hard to the probe, pale in colour and not very sensitive.

**Treatment.**—The removal of the tumour is extremely simple, and therefore should always be advised: it is especially urgent if suppuration be present. A general anæsthetic is required, and the external meatus should be cleansed by syringing. Where the growth does not completely fill the meatus it may be removed per vias naturales. A dental elevator or periosteum detacher may be pushed down the meatus past the growth, when it can be easily broken off and extracted. In the majority of cases however, and especially if the tumour be large, it is better to make an incision over the mastoid process.

about a quarter of an inch behind and parallel to the attachment of the auricle. This incision should be carried at once down to the bone and the periosteum divided. The flap, together with the auricle, is displaced forwards, and the cartilaginous part of the meatus entirely detached.

The base of the exostosis now comes into view, and it may be chipped off with a chisel or gouge and extracted. The wound is sewn up, and for a few days a plug of gauze should be placed in the external auditory meatus. Beyond this there is nothing special in the after-treatment. The wound will heal by first intention and complete recovery will ensue. There is no tendency to recurrence.

2. *Sessile or diffuse exostosis*.—In these cases the osseous part of the meatus is more or less occluded by one or more smooth, rounded, usually pale and glistening swellings of ivory consistence, and varying in size from a millet seed to a split pea. More rarely they may be irregular on the surface and pinkish in colour. They are broadly sessile, of an extremely slow growth and very rarely entirely occlude the canal; but they favour accumulations of wax, and so not uncommonly give rise to deafness. When accompanied by suppuration in the middle ear, especially if there be a liability to swelling of the soft parts of the meatus, they may form a very serious obstruction to the exit of pus, and the condition is then grave. The cause of the trouble is doubtful. In some cases these exostoses undoubtedly follow long-standing otorrhœa, and probably depend upon osteoplastic periostitis.

**Treatment.**—*Palliative*.—In the majority of cases it is sufficient to remove periodically by syringing any accumulation of cerumen, as the growths rarely completely occlude the meatus and consequently they give rise to no symptoms unless wax be present.

*Operative*.—Removal may be required when the growth or growths are large enough to completely fill the meatus, or when suppuration is present. In the latter case, especially if associated with swelling of the mucous membrane of the external meatus, or if pain, pyrexia, or any other symptom be present, operation should be performed without delay, and no time should be wasted in previous attempts to treat the otorrhœa. In these cases, the mastoid should be opened up and the complete post-aural operation performed (see p. 404). When there is no suppuration, it is usually recommended to remove the growth through the external auditory meatus by means of a dental drill or trephine, and this may be accomplished if the growth is in the outer part of the meatus and not too near the membrane. The operation is somewhat difficult and tedious, as the drill has a great tendency to slip off the dense growth, and the hæmorrhage constantly obstructs the view. The greatest care must be taken to watch carefully what is being done, and to proceed very cautiously, as otherwise the ear may be permanently injured. If the growth be large and close to the drum, it is probably better to make a curved incision behind the auricle and to completely detach the cartilaginous meatus, and then, having a



clear view of the parts, to use the chisel or gouge. The meatus may be enlarged by removal of a considerable portion of the upper and posterior walls, including the growth, right down to the tympanum. Subsequently the meatus should be lightly packed with a strip of cyanide gauze which is changed daily, and irrigation with boracic lotion employed until healing is complete.

**Malignant Disease of the Ear** has already been dealt with (see p. 182).

## CHAPTER XXXV

### AFFECTIONS OF THE MIDDLE EAR.

#### INJURIES OF THE TYMPANUM.

THE membrana tympani may be injured by the insertion of a pointed instrument into the ear, or occasionally by the entrance of a sharp foreign body such as a splinter, which may occur in falls without the true cause being recognised. The drum may also be ruptured by sudden compression of the air in the external auditory meatus, such as is produced by a loud explosion, or by a blow on the ear, but this rarely happens unless there is disease of the tympanum or Eustachian obstruction. In such cases there is a mere rent in the drum, usually in the posterior half, with slight separation of its edges. The drum may also be partly destroyed by irritating substances, such as caustics, which sometimes are poured into the ear for earache or toothache. Rupture of the drum may also occur together with extensive injury to the ear in cases of fracture of the base of the skull.

**Treatment.**—The external meatus must be thoroughly purified by syringing with a warm, mild antiseptic solution, dried with wool, a little boracic powder blown in, and a plug of absorbent cotton-wool inserted. The ear should be carefully watched, but in the majority of cases healing will take place rapidly and no other treatment is required. If, when seen, the incision is already closed by clot, a little powder should be blown in and the case left to nature. Should infection take place it is evidenced by acute earache and signs of inflammation in the drum. In such circumstances it is best to immediately apply a blister, or in severe cases leeches, to the mastoid, and to re-open the wound in the drum. This is of course necessary if suppuration is taking place, but even in cases where serous fluid alone has accumulated, immediate relief will be given by evacuation. This treatment is usually effectual, and complete recovery ensues. Should suppuration take place, careful search must be made for a foreign body, and the treatment for acute suppurative otitis adopted.

## ACUTE OTITIS MEDIA.

This disease is the result of infection of the middle ear by micro-organisms which in a very large majority of cases gain access through the Eustachian tubes.

**Causation.**—The infectious fevers, and especially scarlet fever, often give rise to acute otitis of a severe type. Unless great care be taken these cases will go on to suppuration, and may result in grave complications, such as mastoiditis, meningitis, etc. Any septic condition of the throat, such as tonsillitis, secondary syphilis, etc., and also diseases of the nose, such as acute rhinitis, and post-nasal catarrh, are liable to extend to the Eustachian tubes and middle ear; but in the case of a common cold, the resulting otitis is usually of a much less severe type than that following an acute septic process. In such cases, and in those associated with adenoids, the affection is often limited to a tubal catarrh with simple congestion of the middle ear. Another frequent cause of otitis is the entrance of fluids through the Eustachian tubes. For example, lotions injected into the nose with too much force are very liable to pass into the Eustachian tube and to set up acute otitis. This danger is greater in children, in whom the tubes are abnormally short and patent, and who are very likely to resist the syringing and to cough and splutter, and it is also more liable to occur if the patient should open the tubes by involuntarily swallowing during syringing. Again, when vomiting occurs in infants, some of the ejected matter is almost certain to pass through the nose, when it may either lodge in the post-nasal space and set up acute inflammation, or may actually enter the Eustachian orifices. Lastly, during operations on the nose and throat, blood may enter the tubes, and this probably accounts for the otitis which occasionally follows the removal of adenoid growths, etc.

**Pathology.**—The first effect of an acute inflammation spreading from the post-nasal space along the Eustachian tube is swelling of its lining mucous membrane, which completely obstructs it. The lining membrane of the tympanum is also congested and the drum is indrawn. Soon fluid, at first serous or mucous, is poured out and, the tube being obstructed, accumulates in the tympanic cavity and the drum bulges. As a rule the collection of fluid is limited to a part of the tympanic cavity by adhesions between the drum and the inner wall of the tympanum. In the milder cases resolution may occur at this stage. The swelling diminishes, the Eustachian tube becomes patent, the fluid partly escapes or is absorbed, and complete recovery may ensue, though occasionally the adhesions between the drum and the inner wall of the tympanum may become permanent.

In the more severe cases however the fluid in the tympanum becomes purulent. The drum becomes deeply congested, bulges, ulcerates, and ultimately ruptures, and pus and blood escape into the meatus. The patient may now quickly recover, the perforation heal, and the tube again become

patent. In other cases permanent damage, such as intra-tympanic adhesions, permanent perforation of the drum, and occlusion or narrowing of the Eustachian tubes may result. Finally, the suppuration may become chronic.

**Symptoms.**—The chief symptoms are acute deep-seated pain in the ear accompanied by a sense of fulness and throbbing, tenderness over the tip of the mastoid process and below the auricle, and in severe cases over the whole mastoid region and along the sterno-mastoid. There is always more or less deafness and occasionally severe pulsative tinnitus. There is marked febrile disturbance, and in children the general symptoms may be very severe and closely resemble meningitis. On examining the ear with a speculum, great congestion and swelling of the lower part of the bony meatus is found rendering the examination difficult and painful, and in children a general anæsthetic is commonly required, for it is most important to determine if suppuration be present. When this has occurred there is usually a marked localised bulging of the membrane, often with a yellowish spot in the centre, with intense surrounding congestion. This bulging spot is usually situated in the upper posterior quadrant of the membrane.

**Treatment** —In the early stages, when simple catarrh is present, associated with congestion of the tympanum and Eustachian obstruction, vigorous treatment must be adopted to cut short the affection.

*Local.*—The most important measures consist in the appropriate treatment of the septic condition of the nose or throat, the restoration of the patency of the Eustachian tube, and counter-irritation over the mastoid region. The whole area of skin over the mastoid process should be painted with liquor epispasticus, or a blister may be raised by means of the emplastrum cantharides (1-2 ins.). In mild cases the linimentum iodi may be painted on behind the ear and repeated once or twice a day. In the more severe cases and when great pain is present, four or five leeches should be applied to each ear, two over the mastoid, one in front of the tragus and the others over the upper part of the sterno-mastoid. This usually gives immediate relief. To open the Eustachian tube, Politzer's method of inflation should be tried: if used gently and with care it will relieve the pain and perhaps even allow the evacuation of a certain amount of discharge through the tube. It should be repeated twice or three times daily, but should not be persisted in if it cause pain. If unsuccessful at first it should be tried again after a few days. The Eustachian catheter should never be used. In the majority of cases warmth applied to the ear will relieve the pain and is very soothing to the patient. If one ear alone be affected the patient should lie on the affected side, and rest his head upon a rubber bag containing hot water. In other cases moist warmth is more effectual and may be applied by means of linseed meal poultices—encased in gauze to prevent the meal getting into the ear—or the whole ear and side of the face may be bathed with hot water and then hot boracic fomentations applied. When these are removed the ear should be covered with hot cotton-wool and a bandage. Nasal irrigation and other appropriate remedies for the particular causal condition

present must also be regularly employed. Under such treatment in the majority of cases the whole of the symptoms will pass off.

Should the case however be more acute or should suppuration have already occurred, leeches should be applied as above recommended, and in addition the drum should be incised and the pus evacuated as soon as possible if perforation has not already occurred spontaneously. Incision or paracentesis is indicated whenever the drum is bulging, unless the pain be so slight as to be at once relieved by blistering or leeching combined with Politzer's inflation. Further, the drum should be incised, more especially in infants, when there is intense pain and constitutional disturbance, even though it does not bulge markedly. Again, this measure should always be adopted in the first instance if there be any sign of complications, such as mastoid trouble, meningitis, etc. This especially applies to young infants with symptoms of meningitis even if there be only a suspicion of fluid in the ear, as meningitis commonly follows suppurative otitis without perforation or even bulging of the drum. Puncture is also indicated in those rare cases in which facial paralysis occurs.

The pain of this little operation is extremely sharp although of very brief duration. In infants and young children chloroform must therefore be given: in adults the operation is often performed under cocaine, but a general anæsthetic is to be preferred. The knife or myringotome employed has a fine shaft attached to a handle at an angle of  $60^{\circ}$  with a spear-pointed blade, and must be extremely sharp. (See Fig. 138). The external meatus should be thoroughly cleansed by irrigation with boracic lotion, then dried and a good light thrown into the ear. When the drum is bulging or pointing in some particular region, the incision should completely traverse the bulging part. In the majority of cases the upper part of the posterior half of the drum is bulging and then the incision should commence in the posterior and inferior quadrant and be carried up right through Shrapnell's membrane, and in the more severe cases further continued outwards for a short distance ( $\frac{1}{8}$ -inch) along the postero-superior wall of the external meatus dividing the soft parts right down to the bone. The incision should always be made in this region also when the drum is not bulging in any particular spot. After the incision has been made, the fluid in the tympanum will commonly escape, but it may be extremely tenacious and require to be evacuated. With a Siegle's speculum the discharge can be sucked out through the perforation; and then the meatus should be wiped clean with pledgets of wool and the exhaustion repeated until no more discharge escapes. This having been done, the ear should be gently syringed with warm boracic lotion, a little boracic powder insufflated, and hot boracic fomentations applied and frequently renewed until all the acute symptoms have subsided: the syringing and insufflations must be continued until the discharge ceases. At first the ear may require cleansing every hour or every two hours, as the discharge should never be allowed to accumulate in the external meatus.

Moreover, if the lotion be used as hot as can be comfortably borne, the syringing is very soothing to the patient. When the discharge becomes scanty and thick, it is better to omit the powder, as it may form a crust and hinder the escape of the discharge. Occasionally the incision in the drum heals too quickly and then it is necessary to re-open it. Should the discharge continue in spite of this treatment, the case must be treated as for chronic suppurative otitis (see p. 393). When the acute inflammation has subsided the Eustachian tube must be opened and kept patent by daily inflations by Politzer's method, (which also tend to prevent adhesions forming in the tympanum,) and the nasal irrigations, etc., should be continued until this has been accomplished.

*Constitutional.*—At the commencement of the affection it is advisable to give a brisk purge. Children should be given one or two grains of calomel followed by castor oil or a Seidlitz powder; for an adult calomel and colocynth or equal parts of mercury and rhubarb pill should be ordered, to be followed up if necessary by a dose of sulphate of magnesia or effervescing saline. If the pain be very severe, narcotics such as morphia will be required. When the acute attack has passed off, quinine and iron or cod-liver oil should be given. The diet should be light and nutritious, and at first should consist chiefly of fluids, as mastication in the acute stages is painful. Alcohol should be avoided entirely, at any rate in the early stages.

*Results.*—The prognosis is always good unless complications such as mastoiditis, meningitis and cerebral affections occur. The prognosis is worst in the cases of otitis occurring during the course of the specific fevers, varying somewhat according to the severity of the original affection. It is more dangerous also in the young, owing to the great tendency there is in them to meningitis. The results as regards hearing are also good, recovery being as a rule almost perfect. The perforation in the drum commonly heals and the cicatrix left is often imperceptible.

**Recurrent Acute Catarrh.**—Some patients, children especially, are subject to frequently recurring attacks of acute suppurative otitis. The attack commences as an acute affection, the pain, earache, etc., increasing for one or two days, followed by rupture of the drum and rapid subsidence of the affection. In two or three weeks or so the attack is repeated, each attack lasting from two or three days to a week. These cases are invariably associated with some affection of the naso-pharynx or of the nose, the large majority of them being due to the presence of adenoids. The treatment therefore essentially consists in the adoption of the proper remedies for the naso pharyngeal disease.

#### CHRONIC NON-SUPPURATIVE CATARRH.

This affection may occur at any age but is most common in adults between 15 and 35. It is usually the sequel of repeated attacks of catarrh

of the Eustachian tubes and middle ear, which have stopped short of suppuration. Thus it is often associated with such conditions as chronic pharyngitis, post-nasal catarrh, and nasal troubles of all kinds. It is also very common in persons who have apparently suffered from adenoids in childhood, although the growths may have practically disappeared when the ear affection attracts attention. The tendency to many of the above conditions is hereditary and thus partly accounts for the belief in the heredity of deafness.

**Pathology.**—The tympanic membrane is usually indrawn, and may be closely applied to the inner wall of the tympanum. Its folds, and especially the posterior one, are greatly exaggerated, and the handle of the malleus is frequently almost horizontal and displaced backwards; and thus may be concealed beneath the prominent posterior fold. The drum may be thickened in parts or extensively thinned and flaccid. The Eustachian tubes are invariably narrowed; the extent and degree of the stenosis may be most conveniently determined by means of the Eustachian catheter and the otoscope. The most marked changes in the tympanum are: 1. extensive adhesions binding together the chain of ossicles; 2. adhesion of the tympanic membrane to the inner wall of the tympanum; 3. adhesions or fibrous thickening round the fenestra rotunda and the foot-plate of the stapes. The extent of these adhesions varies much: they may be limited to the ossicles, producing more or less irregular displacement, or the entire membrane may become adherent to the inner wall of the tympanum. Their extent and also the existence of flaccid portions of the membrane may be seen by watching the drum during inflation of the ear by Valsalva's method, or better still by the use of Siegle's pneumatic speculum.

In a few cases serous fluid may be present in the tympanum where it is usually confined to some particular locality by adhesions between the drum and the inner wall. It is most common in the attic, producing a bulging of the drum in the upper and posterior quadrant. It is generally thin and serous, but may be a thick tenacious mucus.

**Symptoms.**—Deafness is always present but varies considerably, especially in the early stages of the disease, being worse in cold damp weather, when the patient is tired, or is suffering from nasal catarrh, etc., and it may almost completely pass off in the intervals. A permanent and distressing symptom often noticed even before loss of hearing is severe tinnitus. In well-marked cases the deafness and tinnitus may produce considerable neurasthenia and mental depression which is often increased by the loss of sleep when the noise is severe. In the earlier stages the middle ear alone is usually involved, but in old-standing cases the labyrinth is also more or less affected.

**Prognosis.**—A rough guide may usually be obtained as to the amount of improvement that is likely to result from treatment by carefully testing the effect of inflation of the middle ear. The greater the improvement, the better is the prognosis. Further, the prognosis is better in cases

associated with serous exudation, than in those which are of a purely dry type. It is much better in the young than in the old, although progressive cases advance more quickly in the young. The most unfavourable signs are the existence of extensive adhesions, marked unyielding occlusion of the Eustachian tube and long duration of the affection.

**Treatment.**—The first point to be attended to is the condition of the upper-air passages and especially of the nose and naso-pharynx. Any catarrhal affection of these regions must be energetically treated. Adenoids or any excess of lymphoid tissue in the post-nasal space must be removed by operation. Also it is advisable to correct any nasal defect, such as deflections of the septum, or hypertrophies of the turbinates whenever they give rise to actual symptoms of nasal obstruction, or if they are apparently keeping up catarrh in this region. At the same time excessive operative zeal in this direction must be guarded against. The removal of small growths not giving rise to definite symptoms will not be followed by any beneficial effect upon the ear trouble.

*Of the Eustachian obstruction.*—The second point is to restore if possible the patency of the Eustachian tubes and in the first place the catheter should always be employed. The inflation may be repeated every other day for a week to ten days, when, should no improvement, even temporary, be produced, it should be discontinued. Should however improvement occur the catheterization should be continued regularly at increasing intervals, so long as the improvement is maintained. In some cases its effect may be increased by injecting a drop or two of paroline by means of a pipette into the catheter and driving it sharply into the ear with the air douche. Other fluids may be used, such as a 10% sterilised solution of bicarbonate of soda or potassium iodide, but as a rule they produce little benefit. If, as the result of treatment, the tubes become more patent, or if the case be not severe, Politzer's method of inflation may be substituted for catheterization. This is specially useful, as it may be carried out by the patient himself; he must be cautioned however not to use it oftener than two or three times a week. When the obstruction of the tube does not yield to simple inflation, the regular use of Eustachian bougies has been recommended: the greatest care is required, and the bougie should not be passed further than half an inch into the tube. Temporary benefit may undoubtedly follow, but no permanent advantage is likely to be obtained.

*Removal of fluid.*—This may occasionally be accomplished by Eustachian inflation. The air entering the tympanum forcibly distends the membrane and may break down soft adhesions, thus setting the fluid free and allowing it to escape down the tube. If this manœuvre be unsuccessful the drum should be incised through the most prominent bulging part (see p. 385). Where the whole membrane is distended the posterior-inferior quadrant should be selected for puncture. The opening should always be free, as in this way the fluid is more completely evacuated and the incision, healing quickly, leaves no permanent damage. When the fluid is tenacious it may not escape



even after incision and then it must be evacuated by means of suction with a Siegle's speculum, aided if necessary by inflation through the Eustachian catheter. When this has been accomplished the ear should be gently syringed with a mild antiseptic solution such as boracic acid, dried and a little boracic powder insufflated. If the fluid be very tenacious it may even be advisable to wash out the tympanum by means of a tympanic syringe. The fluid is not at all unlikely to re-form after the incision in the drum has healed and in such cases repeated evacuation may be necessary.

*Treatment of the adhesions.*—In the early stages the frequent use of the Eustachian catheter may be sufficient to prevent adhesions or even partially to loosen them if they have already formed. Subsequently the mobility of the drum and ossicles may be increased by the regular use of Siegle's speculum—the so-called “massage” of the drum. The massage should be practised once daily by the surgeon himself and if improvement is produced its use should be continued. The improvement at first obtained is usually temporary but lasts longer and longer each time. This treatment should be combined with the use of the Eustachian catheter and continued with increasing intervals as long as improvement is produced. Occasionally considerable improvement may also be obtained by ordinary massage applied to the skin over the mastoid and to the auricle. The mastoid and the part below the ear are firmly rubbed in a downward direction by the thumbs and in a few cases permanent improvement may thus be produced.

Where the above treatment has failed and the adhesions are very dense and extensive, operative interference has been recommended. The results are very uncertain and may even make the condition worse, and therefore such treatment must always be regarded as experimental and should only be carried out in very marked cases in which both ears are affected and in which the patient suffers considerably from the tinnitus. If operative treatment is decided on, local anæsthesia should be used. The knife is entered about the centre of the posterior half of the drum near its margin, carried upward parallel to the tympanic ring to the posterior fold, forward just below this fold and downward along the handle of the malleus, and the large flap of membrane thus marked out is turned downwards. The hearing should then be tested with voice and watch. Occasionally this operation may produce considerable benefit, but relapse almost invariably occurs when the perforation has healed. Under these circumstances, complete removal of the membrane and ossicles may be carried out. The steps of this operation are practically the same as when performed for suppurative otitis (see p. 396).

When the operation is concluded, the parts should be dried and packed lightly with a small strip of iodoform gauze. This may be removed at the end of 24 hours and a little boracic powder insufflated, a small plug of wool being placed in the external meatus. In a few days the parts commonly become quite dry. It is not at all uncommon for the drum to be replaced by an adventitious membrane, but as a rule this new-formed

structure is much thinner than the old one and does not interfere with any good effects that have been obtained from the operation. If it does so, it may be removed a second, or even a third time.

The results of this operation are disappointing. The majority of cases experience no improvement, and it is possible that the condition may be made worse. The effect of making the temporary perforation as above described should always be first tested and the more extensive operation proceeded with only when marked improvement has resulted.

#### SCLEROSIS OF THE MIDDLE EAR.

This affection, commonly known as chronic dry catarrh, is one of the most common and the most intractable forms of middle-ear disease. It attacks people of all ages, but is especially common in young women of from twenty to thirty. The patient may present symptoms of anæmia or of general debility, but is generally in otherwise good health. In some cases the affection seems to be hereditary. It may be dated from, or may be increased by a severe illness or by parturition, etc. It is usually unassociated with any naso-pharyngeal or nasal trouble.

**Pathology.**—The exact nature of the changes is perhaps unknown. In the majority of cases there is supposed to be fibrous thickening which binds the ossicles together, and is especially abundant around the plate of the stapes. There may also be fibrous thickening of the membrana tympani and of the membranes covering in the fenestræ. This and the preceding affection cannot always be sharply differentiated.

**Symptoms.**—The deafness comes on very slowly and is usually intermittently progressive but it never becomes absolute. The membrane as a rule appears nearly normal and is not particularly indrawn; the Eustachian tubes are open, often abnormally patent; the external meatus is frequently dry and glistening, with an absence of hairs and of cerumen. The hearing by bone conduction is exaggerated unless, as is common in advanced cases, some labyrinthine change is present. The field of hearing is altered, diminution being most marked for the low notes, such as the human voice. Most patients hear better in a noise. Tinnitus is usually present and may be extremely distressing. It commonly commences in the earlier stage of the affection and is the first thing to which the patient's attention is directed. Arrest and occasionally slight improvement is all that can be hoped for from treatment. On the other hand the affection is likely to be increased by any illness, anxiety, overwork, etc., and more rapidly in young people.

**Treatment.**—Most success will be obtained by measures directed to the maintenance of the general health. In neurasthenia, strychnine should always be given together with an abundance of food and suitable exercise. If the patient can afford it, a prolonged residence, especially during the winter months, in a warm, dry climate is to be recommended. The experi-

mental use of the catheter and of Siegle's speculum may be tried, but it is usually unsuccessful. Operative treatment either on the nose, unless well-marked disease is present, or on the middle ear, is to be deprecated as it much more commonly does harm than good. All other treatments such as the administration of iodide of potassium, of pilocarpin, or the ammonium-chloride inhaler are almost uniformly disappointing.

#### CHRONIC SUPPURATION OF THE MIDDLE EAR: ITS COMPLICATIONS AND SEQUELÆ.

Chronic suppuration of the middle ear is most commonly the sequel of acute suppuration, especially when the latter follows one of the more severe specific infections. An acute suppuration may also become chronic when neglected or when the structures of the middle ear have been permanently damaged as the result of repeated catarrh. Certain affections of the nose and throat and especially post-nasal adenoid growths are liable to produce chronic suppuration in this way. Among the changes which tend to maintain a chronic otitis, the commonest are those which lead to insufficient drainage, as for example a very small perforation of the drum, the collection of pus in pockets formed by adhesions either between the folds of mucous membrane or between the membrana tympani and the inner wall of the tympanum, the existence of extremely viscid or inspissated pus and the occurrence of complications such as extension of the disease to the attic or antrum, the presence of polypi, carious bone, etc.

An essentially chronic otorrhœa is also met with as the result of a tuberculous deposit in the structures of the middle ear. It is most common in patients with phthisis or tuberculosis elsewhere or in those who have a tuberculous history. The affection commences insidiously, the first symptom being a purulent discharge from the ear; on examining the drum, changes obviously chronic are seen. The deposit of tubercle may be in the mucous membrane alone, but most commonly there is also a deposit in the ossicles or in the bony walls of the tympanum. It is quite possible also that some cases originating in an acute suppuration may in time become tuberculous.

**Pathology.**—The membrana tympani is always perforated, the aperture varying from the size of a pinhole to almost complete destruction of the drum. A common form, namely a large perforation in the posterior-inferior quadrant, is well situated for drainage, usually indicates disease in the tympanum and is therefore of favourable import. A small perforation in the posterior-superior quadrant often communicates with the attic and indicates disease of the incus, while a small perforation in Shrapnell's membrane points to disease in the attic and is often associated with caries of the head of the malleus. The edges of the perforation may be free or partly adherent to the inner wall of the tympanum. When a perforation is healing its edges appear to be pink, with finely injected vessels, and

gradually encroach on the opening. In neglected and tuberculous cases the edges of the perforation are commonly thickened and granular.

*The mucous membrane* of the tympanum is reddened, thickened and velvety in appearance. In old-standing cases it may in part become covered by squamous epithelium and then appear dry and shiny. The drum or its remains may be extensively adherent to the inner wall of the tympanum and these adhesions may form large pockets in which the discharge accumulates. In chronic suppuration other than tubercular the first changes invariably occur in the mucous membrane, but in long-continued suppuration the bone is commonly affected secondarily.

*Small granulations* are often seen in the tympanum, especially in tuberculous disease and in neglected cases. Should a granulation become greatly enlarged and pedunculated, it forms a *polypus*, and these are most commonly met with springing from the inner wall of the tympanum, from the edge of the drum or from the inner part of the external auditory meatus. In the earlier stages polypi consist of simple granulation tissue, but later they may undergo myxomatous degeneration or become hard and fibrous, and the surface may be covered by epithelium. It is most probable that polypi are generally associated with changes in the underlying bone, and, if granulations or polypi constantly recur after removal, the existence of bone disease is certain.

*Caries and necrosis.*—The ossicles have a very precarious blood supply, and therefore when the attic is involved in chronic suppuration they are very liable to become necrosed, the incus being most frequently attacked. Caries of the ossicles is also common, the neck or head of the malleus being most often affected, except in tubercular cases, when there may be a deposit of tubercle in any part of the bones.

The temporal bone may also be attacked by caries, or more rarely a small sequestrum may form. The outer wall of the attic is most commonly affected and may be completely destroyed, leading to a large communication between the attic and the external auditory meatus above the membrana tympani. In disease of the antrum the plate of bone forming the posterior wall of the external auditory meatus and separating that canal from the antrum may be destroyed. The inner wall of the tympanum is rarely affected except in tuberculous disease. The roof of the tympanum is more commonly destroyed and leads to a large perforation into the middle fossa.

*Facial paralysis* from involvement of the nerve is rare, but may occur when necrosis of the aqueduct of Fallopius or some developmental anomaly has left the facial nerve exposed.

*Cholesteatoma.*—This peculiar condition occurs only in very chronic cases and when the perforation of the drum is near its margin or situated in Shrapnell's membrane. The squamous epithelium lining the external auditory meatus apparently extends through the opening in the membrana tympani, and rapidly proliferates and desquamates. As a result large masses

of epithelial cells accumulate in the tympanum and sometimes in the antrum also, become tightly packed together and ultimately form a large irregular mass which distends the cavities in which it lies. In extreme cases the attic, tympanum, antrum, and external meatus are thrown into one cavity which may be as large as a walnut, and both the middle and posterior fossæ of the cranium may be opened.

*Suppuration in the antrum and mastoid cells.*—This is most commonly met with when the discharge from the attic is unable to obtain free exit. In other cases, from the intensity of the primary inflammation the antrum may have been involved from the commencement.

*Adventitious sinuses.*—In rare cases in children the discharge from the ear will find an exit down the Eustachian tube or pass along the sides of it into the tissues at the back of the pharynx or in the neighbourhood of the tonsil.

**Symptoms.**—The most prominent symptom is a purulent discharge from the ear, which may be thin or thick, profuse or scanty. If thick and scanty, the discharge may dry into a scab in the deeper part of the meatus, and cause retention of pus in the ear, when the patient may complain of frequently recurring attacks of otitis whilst asserting positively that there is no discharge. The discharge may be fœtid, and sometimes produces dermatitis of the auricle, or even a pustular eruption on the face and neck. When polypi or granulations are present, the discharge is commonly tinged with blood. Pain is usually absent unless there is temporary obstruction to the outflow of the discharge. The deafness varies from a slight impairment of hearing, only noticeable on careful testing, up to complete loss of hearing if the inner wall of the tympanum and the labyrinth become affected. Tinnitus is as a rule not marked.

**Treatment.—Of the otitis.**—In simple cases the ear should be cleansed by syringing, followed by drying and the insufflation of boracic acid. The best fluid for cleansing is a mild antiseptic such as a saturated solution of boracic acid diluted with equal parts of hot water, a solution of 1-8000 to 1-5000 perchloride of mercury, or weak solutions of sanitas or permanganate of potash, to each pint of which one drachm of common salt should be added. The fluid should be comfortably warm, as extremes of heat and cold are apt to cause pain. The surgeon may employ an ordinary ear syringe, but it should be used gently, and, if the treatment be entrusted to the patient or an attendant, a small rubber ball-syringe is the safest. About four to six ounces of fluid should be used at each sitting. When a large perforation is present, syringing is apt to give rise to giddiness, unless the fluid be injected very gently and slowly, and the patient be gradually accustomed to it; in some cases it is found necessary to abandon it on this account. In children also, the lotion may pass from the tympanum down the Eustachian tubes, and therefore poisonous fluids must be used with extreme care.

After syringing, the ear should be carefully dried by repeatedly intro-

ducing pledgets of wool rolled up so as to form a long cone (see Fig. 135). The patient can be easily taught this method, which is both safe and effective, and he should never be allowed to wrap wool around the end of a stick or probe, as is commonly done. When the ear has been dried, boracic powder should be blown into the deeper part of the meatus. This can be easily accomplished by filling the end of a glass tube or quill with powder, inserting it in the ear and blowing through the other end. By means of a rubber tube the patient can do this for himself. A small pledget of wool is then inserted into the meatus. Iodol, iodoform and other powders have been recommended to be used in a similar way,



FIG. 135.—COTTON-WOOL MOP. This is also useful as an artificial drum, when the roll should be shorter so as not to project from the meatus.

but, being insoluble, they are extremely apt to be retained in the ear, to form large crusts and to hinder the outflow of the discharge. Much harm may therefore result from them and they should never be used except under the personal supervision of the surgeon.

As soon as the powder or wool becomes moist, the cleansing should be repeated, and pus should never be allowed to accumulate in the external meatus. If the discharge be profuse, syringing every two hours may be necessary, but as it diminishes twice and finally once a day will be sufficient. In some cases, when the discharge is becoming scanty, syringing seems to produce irritation and to keep up the discharge. In these circumstances and also when the above treatment fails to completely stop the discharge the syringing should be discontinued and the dry treatment adopted. The ear should be simply mopped out with wool in the way above described and a very little boracic powder insufflated; this will commonly be successful.

Where this treatment fails, instillations should be tried. These consist of various solutions, a few drops of which are warmed and poured into the ear after it has been thoroughly cleansed and dried. A most useful instillation is rectified spirit, which may be used in gradually increasing strengths, starting at about thirty per cent. and increasing it if no pain beyond momentary stinging is produced. The good effect of this is often increased by adding twenty grains of boracic acid to each ounce of spirit. Another useful solution is nitrate of silver, which should be used at first not stronger than five grains to the ounce, and increased up to twenty as it can be tolerated. Chloride or sulphate of zinc may be used in similar strengths, and when the perforation is small they are best injected through the perforation into the middle ear by the surgeon himself with an intra-tympanic syringe. A little cotton-wool should be worn in the external meatus.

*Constitutional treatment.*—Many patients are debilitated, and tonics, such as cod-liver oil and syrup of the iodide or phosphate of iron, are required, especially in children. Careful examination must also be made of the nose

and throat and adenoids, post-nasal catarrh or any disease of this region must be appropriately treated.

*Prognosis.*—The *discharge* can always be stopped in simple cases, and the importance of doing this, even where it is very scanty, should always be insisted upon, for, so long as it is allowed to continue, disease of the bone or extension of the infection to the inner ear, to the cranium or to the lateral sinus is liable to occur. The danger to life in cases properly treated is very slight, but no life can be considered a good one until all discharge has ceased for at least two years. With regard to hearing, a guarded prognosis must be given. In some cases the cicatrization following healing may cause an increase in the deafness, but this should never be regarded as a contra-indication to treatment, for the continuance of the discharge will invariably cause deafness sooner or later. In the majority of cases the subsidence of the inflammation is accompanied by an increase in the hearing power.

**Of the complications.**—These have been already referred to, and their treatment must now be briefly considered.

*Of small-sized or ill-situated perforation of the drum.*—The effect of this in hindering the escape of the discharge and preventing the application of remedies need not be insisted upon. The best treatment is to enlarge the perforation with a small probe-pointed knife (see Fig. 138). The drum should be anæsthetised by the application of a saturated solution of cocaine, and then, under good illumination and with a very sharp knife, the perforation should be enlarged, preferably in a downward direction, to the periphery of the drum. In most cases this is best accomplished by means of a V-shaped flap. The tympanum should then be washed out by means of a tympanic syringe and the antiseptic treatment discussed above should be adopted. In cases in which a pocket has been formed in the middle ear similar treatment should be adopted.

*Of attic disease.*—Owing to the presence of the ossicles and various folds of mucous membrane, this region is divided up into numerous cavities which are extremely difficult to cleanse thoroughly and from which drainage is imperfect. The importance of this will be seen when it is remembered how closely the attic is connected with the cerebral cavity and also with the tympanic antrum. Disease of this region is therefore serious and often intractable, and prolonged suppuration is almost certain to lead to further complications.

When first seen an attempt should be made to cleanse the cavity by means of the tympanic syringe. This must of course be used by the surgeon and to be efficient the patient should be seen every day. In the intervals the meatus should be kept cleansed by the patient himself in the way above described. Where it is impossible for the surgeon to personally treat the case daily, the patient may be simply instructed to syringe out the meatus and to insufflate powder. If this fails, as it generally will do in old-standing cases, operative treatment is indicated, and this is especially necessary if the patient

be subject to repeated attacks of pain, headache and increased deafness. These attacks indicate that the discharge is locked up in a cavity in the attic, and if free exit for it is not obtained danger will result. The most reliable treatment in such cases is complete removal of the membrane and larger ossicles, and the necessity for this is commonly emphasised by the fact that the bones themselves are necrosed or carious. The malleus or incus alone may be removed, but the complete operation gives better results.




FIG. 136.—DELSTANCHE'S MALLEUS HOOK.



FIG. 137.—LAKE'S ATTIC CURETTE.

*Operation.*—A general anæsthetic is always to be preferred. The instruments required are a small probe-pointed knife, a pair of fine forceps, a Delstanche's hook, an incus hook and an attic curette (see Figs. 136-138). The meatus having been cleansed by syringing and dried, an incision is made all round the periphery of the drum. It is best to commence the incision in

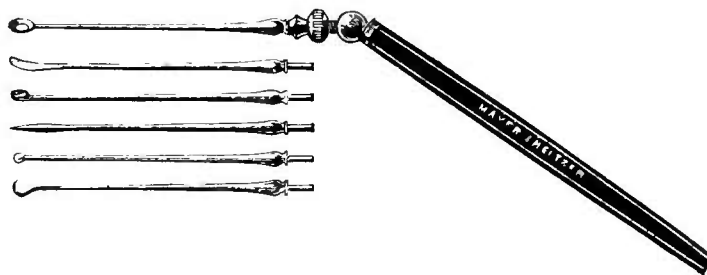


FIG. 138.—SET OF MINOR EAR INSTRUMENTS. From above downwards the instruments are, an aural curette, probe-pointed knife, sharp spoon, myringotome, probe, and hook. These all fit in the one handle.

Shrapnell's membrane and to divide the posterior part of the drum first and then to reverse the knife and divide the anterior folds. The malleus and membrane should now be seized and extracted with forceps. When the membrane is destroyed and the malleus is adherent to the promontory, the best plan is to pass a Delstanche's hook over the handle of the malleus up to the short process, when by gentle traction the bone can be easily removed. Any bleeding should be arrested by mopping with pledgets of cotton-wool. Then the attic curette is passed well up into the roof of the tympanum and gently swept round, by which means the incus will usually be brought away.



If not, it should be sought for first posteriorly and then anteriorly by means of the incus hook. This hook should always be kept close to the tympanic ring. The whole cavity should next be gently but thoroughly curetted and the existence of a carious spot of bone on the inner wall or roof should be felt for with the probe. The stapes is best left, and care should be taken not to disturb it with the curette. The ear should then be thoroughly washed out and the tympanum and attic lightly packed with a thin strip of cyanide gauze soaked in glycerine and iodoform emulsion. This strip should be removed at the end of 24 hours at the latest and then the treatment by syringing, drying and powdering with boracic acid should be carried out until healing is complete. This treatment will have to be continued for many weeks. If the discharge completely ceases, the inner wall of the tympanum gradually loses its red velvety appearance and becomes white and glistening. This is probably due to the spreading inwards of the epithelium from the margins of the membrane which in time may completely cover the inner wall of the tympanum. This is the most favourable result that can be obtained and is usually not complete for five or six months. In cases in which the lower part of the drum is cicatrised and adherent to the inner wall it should be left untouched, as the epithelium rapidly spreads from this over the tympanum.

The results of this operation are frequently good. Attic suppuration is always stopped provided there be no carious bone and the antrum or mastoid cells be not affected. The hearing in many cases is improved, in a few it is somewhat worse, but by removal of the malleus and incus alone it is never destroyed. If, in spite of this operation, much pus continues to form, it almost certainly comes from the antrum, and the complete post-aural operation (see p. 404) must be performed. If after many months a slight discharge still continues, it either comes from a small sclerosed antrum or indicates the presence of diseased bone in the roof or inner wall of the tympanum and in both of these cases also the complete post-aural operation is indicated.

*Of granulations and polypi.*—Granulations, if small, are best destroyed by means of chemical caustics, the actual cautery being somewhat difficult to manipulate in the ear. The best caustics are chromic acid or nitrate of silver, which should be fused upon the tip of a fine probe. The ear being cleansed and the granulations carefully dried, the caustic should be applied directly to them. Any excess should be mopped away with a pledget of wool and then insufflation with boracic acid should be carried out. The application may require to be repeated once or twice. Where numerous granulations are present, the instillations of spirit are often more effectual than the dry treatment. In cases in which the attic is affected or caries of the tympanic walls is present the granulations should be removed by means of the curette preferably under general anæsthesia; some caustic should be subsequently applied to their bases.

A large granulation should be removed by means of a fine, sharp curette.

Cocaine is first thoroughly applied, some of the powdered drug being dusted over the growth, which is then cleanly cut off, and its base is dried and cauterised. Larger growths or polypi are best removed by means of a fine snare, such as Politzer's or Wilde's, threaded with gimp. A general anæsthetic is always advisable. The loop of the snare is slipped well over the growth and tightened; the growth should then be pulled away rather than cut through. If the bleeding can be arrested, the stump of the polypus should be cauterised, or curetted. When polypi and granulations frequently return in spite of this treatment, the presence of carious bone may be confidently diagnosed, and further operation is required. In the first place, removal of the ossicles, if not already performed, should be carried out, and the attic thoroughly curetted. Where this is not effectual the complete post-aural operation should be adopted.

*Of caries and necrosis of the ossicles.*—This can usually be detected by the situation of the perforation, or by means of a probe. The treatment is removal as above described (see p. 396).

*Of caries of the temporal bone.*—This is generally recognised by the persistence of the discharge after removal of the ossicles, by recurrences of granulations or polypi, or carious spots may be felt with the probe. In the simpler cases where no cerebral symptoms are present, and where the caries does not seem to be extensive, removal of the ossicles should be first tried, and the carious parts thoroughly curetted, all granulations and polypi being removed. If this treatment be ineffectual, or if an extensive necrosis be present, the complete post-aural operation is required.

*Of cholesteatoma.*—The epithelial masses must first be entirely removed from the external auditory meatus, as already described (see p. 376), and if the drum be extensively destroyed, the same measures may be adopted to remove them from the tympanum. Great care and time are usually required, and a general anæsthetic is necessary. Sometimes a large mass in the anterior part of the tympanum may be dislodged by the injection of fluid through the Eustachian catheter. Where only a small perforation is present it will be necessary to enlarge it, and the best method is to remove the whole drum together with the incus and the malleus, as already described (see p. 396). Then, by syringing and curetting, the tympanum can be thoroughly cleared, but should cholesteatomatous masses also be present in the antrum, as is not unlikely in a severe case, or should the bony walls of the tympanum be carious, the complete post-aural operation should be carried out.

*Of facial paralysis.*—Paralysis of the facial nerve occurs either from pressure of exudation in the middle ear or from direct involvement in an inflammatory process, when either the canal of the facial nerve is opened by caries of its walls or there is some congenital anomaly. The treatment is to secure free evacuation of the contents of the tympanum, but the greatest care must be taken not to use the instruments, and especially the curette, with too much force. Should this treatment fail, or should extensive caries

be found, the complete post-aural operation, carried out with extreme caution owing to the exposure of the facial nerve, should be adopted (see p. 404).

*Of suppuration in the antrum.*—When, in spite of the above treatment, a considerable amount of discharge still comes from the ear, it is obvious that it must come from the antrum or mastoid cells; it may be possible to observe the actual outflow of pus into the tympanum from the antrum. In these circumstances the mastoid antrum, and the cells also, if involved, require to be opened and dealt with in the manner to be presently described (see p. 404).

**Sequelæ of suppuration.**—As the result of chronic suppuration in the ear, complete recovery and restoration of function is usually impossible. In most cases either a permanent perforation of the drum or more or less extensive adhesion between the ossicles or the membrane and the inner wall of the tympanum, or a combination of these conditions, will remain.

**Permanent perforation of the membrane.**—There may be a small perforation or more or less complete destruction of the drum. In such conditions any catarrh of the ear leads to a certain amount of serous discharge which drains into the external meatus. Unless the catarrh results from an acute septic infection or the discharge becomes contaminated it will remain serous; should infection occur, acute suppurative otitis follows. Again, if water be allowed to enter the ear, as in bathing, it is apt to penetrate into the tympanum and to set up an acute inflammation.

*Treatment.*—When simple catarrh is present the meatus should be gently syringed out with a mild antiseptic such as boracic acid, dried, a little powder insufflated, and a pledget of wool worn in the ear.

Should the affection develop into suppurative otitis, it must be treated on the lines already given for that disease. Repeatedly recurring attacks should always direct attention to the post-nasal space and upper air-passages generally, and any morbid condition in this region should be remedied. Patients with perforation should be warned against the dangers of bathing, and if they persist in it should be warned not to put the head under water, and the affected ear should always be previously plugged with cotton-wool. In a few cases and especially in those in which a large perforation is present, through which the stapes is exposed, considerable benefit may be obtained by the use of the artificial drum.

*Artificial drums.*—Artificial drums should only be used when the discharge has completely ceased or is reduced to a little serum. The best form is a simple cone of cotton-wool, which can easily be rolled up with the fingers (see Fig. 135). This should be moistened with a little glycerine before applying it. The large end of the cone should be placed in contact with the stapes, or if this be absent, in the position of the fenestra ovalis. The drum not only serves as a protection to the delicate lining membrane of the tympanum but in many cases noticeably improves the hearing. It should be worn at first not more than two hours at a time, but if it does

not excite any inflammation or irritation the time may be gradually increased until it is worn for twelve or more hours at a time: it should be invariably removed at night. The patient can be easily taught to apply the drum for himself and will quickly succeed in doing it even more skilfully than the surgeon. In place of these cotton-wool pads small discs of paper or linen, such as Ward Cousins' ear-drums, may be used.

*Small perforations.*—If a small perforation only be present and frequent attacks of acute otitis occur, an attempt should be made to heal it. For this purpose it is necessary to refresh its edges, which may be done either with a knife or by the application of caustics. The best plan is to apply a little trichlor-acetic acid with a fine probe to the extreme margins of the perforation. If necessary the application may be repeated. The method usually succeeds only with very small perforations.

**Intra-tympanic adhesions.**—Adhesions may be found binding the various ossicles together or uniting them and the membrane or its remains to the inner wall of the tympanum. Extensive thickening may form around the foot-plate of the stapes. The resulting deafness varies considerably, but it is rarely progressive and may even improve, especially in the young. The prognosis is better when there is no labyrinthine involvement. Where labyrinthine changes have occurred, Rinne's test in the lower scale commonly becomes positive, and the prognosis depends upon the position in the scale at which this conversion takes place (see p. 373).

*Treatment.*—The general health should always be attended to and the post-nasal space and upper air-passages examined and any morbid condition rectified. Inflation with the Eustachian catheter or by Politzer's method should be carried out and often gives improvement even where a large perforation is present. When the hearing is much impaired and especially if severe tinnitus be present, operative interference is often beneficial. A common condition is to find the lower part of the drum almost completely destroyed, while the membrana flaccida and the posterior and anterior folds are converted into a mass of fibrous tissue which binds down the ossicles or their remains into the upper part of the tympanic space. For this condition, when the labyrinth is not involved, complete removal of the remains of the ossicles and the membrane may be carried out, but the uncertainty of the result must always be fully explained to the patient.

*Operation.*—The external meatus should be purified by syringing for a few days with a mild antiseptic such as boracic acid, and instillations of rectified spirit, to which twenty grains to the ounce of boracic acid are added, should be practised once daily for three days at least before the operation. In the intervals a small plug of wool should be worn in the external meatus. It is better to operate under general anæsthesia. The steps of the operation have already been described (see p. 396). As a rule very little reaction follows and the ear is quite dry by the end of a week. In a few cases marked, and in the majority slight improvement in hearing is obtained, but a relapse is frequent. This plan is much better than the

attempt to divide adhesions, by which also temporary good results may be obtained, but relapse is almost invariable.

When firm adhesions exist around the foot-plate of the stapes, numerous operations have been devised to secure the mobility of this ossicle. These consist essentially in removing as much of the fibrous tissue as can be cut away, and subsequently in making radiating incisions around the foot-plate. Then, by means of a small pledget of wool on a probe, attempts are made to move the ossicle by pressing its head first in one direction and then in another. These procedures, as well as removal of the ossicle, often give slight temporary relief, but are invariably followed by relapse and no permanent good is effected.

## CHAPTER XXXVI.

### SUPPURATION IN THE ANTRUM AND MASTOID CELLS.

#### SUPERFICIAL MASTOID ABSCESS.

THIS is an abscess occurring beneath the periosteum of the mastoid process and is most common in children. It is due to extension of suppuration beneath the soft parts either from the tympanum or the antrum. The pus passes outwards through the segment of Rivini.

**Treatment.**—The treatment consists in the evacuation of the pus through a free incision behind the ear right down to the bone. If no sinus can be found leading into the bone this may be all that is required, but if the case be one of chronic suppuration of the middle ear it is better to proceed to the complete mastoid operation (see p. 404).

#### ACUTE SUPPURATION IN THE MASTOID ANTRUM.

This most commonly occurs in connection with chronic suppuration in the antrum or middle ear as the result of some impediment to the free escape of the discharge. Less frequently it is met with in acute suppurative otitis, and especially when the latter is due to one of the acute infectious fevers, particularly scarlet fever, diphtheria or influenza. In chronic cases the pent-up discharge spreads through the lining membrane of the cavity into the bone which rapidly becomes carious or necrosed. Thus the walls of the antrum may be perforated, allowing the pus to burst through externally and form an abscess over the mastoid process behind the ear. Less frequently the pus finds an exit through the anterior wall of the antrum into the external auditory meatus or through its lower wall into the digastric fossa. The posterior wall or roof of the antrum may also be carious and lead to intra-cranial complications.

**Symptoms.**—There is acute pain with marked tenderness on pressure, redness and œdema over the site of the antrum and behind the ear and the auricle is displaced outwards and downwards. A prominent symptom of antral suppuration is bulging of the postero-superior wall of the external

auditory meatus at its extreme inner part concealing the posterior and upper part of the drum. When perforation of the antrum occurs into the digastric groove a large, tender, deep-seated swelling occurs under the upper part of the sterno-mastoid. A communication with the middle or posterior fossa may lead to cerebral complications or to pyæmia. The temperature is always raised and the constitutional disturbance severe, especially in the cases in which perforation occurs into the digastric groove or into the cranial fossæ.

**Treatment.**—This depends upon whether acute mastoiditis is associated with acute or chronic suppurative otitis, the affection being of much more serious import when chronic ear disease is present.

*When complicating acute otitis.*—The early symptoms of mastoiditis must be energetically treated, but operation is not always necessary. If the symptoms are not severe, leeches should be applied (two or three in children and five in an adult), the ear should be syringed with hot boracic lotion, hot fomentations should be applied and any hindrance to the free escape of discharge from the tympanum should be met by free incisions in the drum. The incision should commence near the lower margin of the drum and be carried quite across it, through Shrapnell's membrane and the tympanic ring and also for a short distance outwards along the postero-superior wall of the meatus, dividing the soft tissues right down to the bone. The case is then treated as for acute suppurative otitis (see p. 384). If the pain be severe, morphia may be given. In most cases this treatment may be safely persevered in for from 24 to 48 hours, unless severe symptoms occur, such as great œdema over the mastoid, the occurrence of fluctuation behind the ear, or signs of cerebral complications. If no improvement is obtained within 24 hours, or if severe symptoms are present or supervene, further operation is imperative.

*The operation* consists in the entire removal of the outer wall of the antrum, thus freely exposing that cavity (see p. 404), and in thoroughly cleansing the parts by syringing with boracic lotion. It is usually found possible to syringe from the meatus into the tympanum and out through the antrum, which ensures a thorough washing of the whole track. The parts should then be dried, a small strip of cyanide gauze soaked in glycerine and iodoform emulsion should be placed in the cavity in the bone, and a similar plug inserted in the external auditory meatus. The wound in the soft parts should be left open, but need not be packed. A cyanide gauze dressing is now applied. By this operation immediate relief to the symptoms is given.

*The after-treatment* consists in renewing the packing, at first every day and subsequently every other day as the discharge lessens. At each dressing the ear and the wound should be thoroughly cleansed by syringing. After two or three weeks the discharge has usually entirely ceased, and the bone is covered by pink granulations. The packing may now be gradually omitted and the wound allowed to close about the fourth or fifth week.

*The prognosis* after this operation is extremely good. The wound usually

heals soundly and all discharge ceases, the perforation in the drum may close, and the hearing power be almost completely restored. In a few cases a sinus persists behind the ear, or may re-open after apparent healing, or the discharge from the ear may continue. The case then becomes one of chronic mastoid abscess.

*When complicating chronic suppuration of the middle ear.*—In these circumstances symptoms of mastoid involvement are of much more serious import. If the patient urgently desires to postpone an operation and the symptoms be not severe, the treatment just prescribed for mastoiditis in acute suppurative otitis may be first tried, but in the majority of cases it fails. The only treatment which really offers a chance of success is operation, and if severe symptoms be present this should never be delayed. In the majority of these chronic cases extensive changes occur in the antrum, in the attic and the deeper parts of the ear, involving the mucous membrane and the bone. Large cholesteatomatous masses may be present, the antrum may be filled with polypoid mucous membrane, there may be extensive caries or necrosis of the temporal bone, the dura mater or lateral sinus may be exposed without any definite symptoms to indicate the extent of the mischief. These considerations show the necessity for immediate operation, and also that it is essential to open and explore not only the antrum but the whole of the tympanum, attic, and aditus so as to thoroughly inspect those parts. This is called the radical or complete post-aural operation.

*Operation.*—The patient must be prepared in the usual manner; all hair for a space of at least three inches round the ear must be removed by shaving and the parts purified in the usual way (see Part I., p. 161). The external meatus should also be cleansed as far as possible by repeated syringing with boracic acid or a weak solution (1-5000) of perchloride of mercury. The instruments required are the ordinary dissecting instruments, some small chisels and gouges, small sharp spoons, and one or two pairs of slender forceps. The gouges should be used with a mallet, and they should be square ended and sharpened from the concave side, so that the back of the instrument is straight. Long, narrow strips of gauze should be prepared for drying the deeper parts of the wound when the bone has been opened up.

The patient's head should be turned over to the opposite side and supported upon a firm sandbag. A good light is essential, and for those accustomed to work with it, a light reflected by means of an ordinary frontal mirror is very useful when completing the operation.

*The incision.*—A curved incision should be made over the mastoid process about a quarter of an inch behind the ear, extending upwards from the tip of the mastoid process parallel with the attachment of the auricle until it is vertically above the external auditory meatus. This incision should be carried at once down to the bone and the periosteum freely divided. With the periosteum detacher or with the handle of the knife the anterior flap carrying the auricle with it is now turned forward until the posterior and superior walls of the osseous meatus come into view, the cartilaginous and soft parts lining



the meatus being freely detached (see Fig. 139, *A*). All bleeding points should now be clamped and the general oozing arrested by sponge pressure.

The bared bone should be carefully searched with a probe to ascertain the existence of a sinus. If one be found, the probe should be passed in to

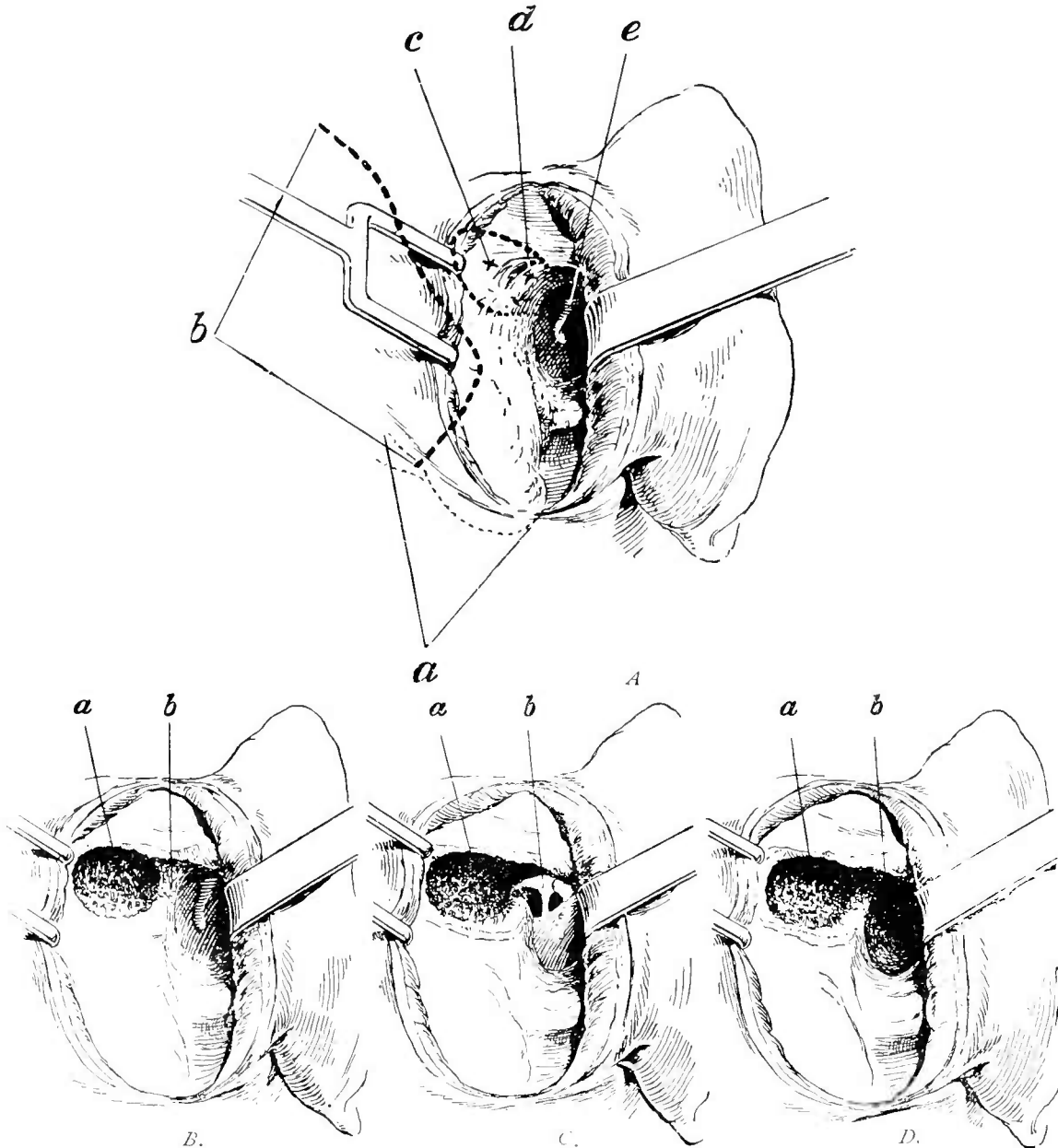


FIG. 139.—THE COMPLETE POST-AURAL OPERATION ON THE MASTOID.

*A.* Shows the incision and the auricle displaced forwards to expose the external meatus. *a.* Outline of mastoid process; *b.* anterior limit of lateral sinus; *c.* centre of antrum, the dotted line round this shows the area of bone to be removed; *d.* supra-meatal spine; *e.* handle of malleus.

*B.* Shows the antrum opened and its outer wall removed. *a.* Antrum; *b.* bridge of bone between antrum and external meatus.

*C.* Shows the aditus exposed by removal of the bridge of bone. *a.* Antrum; *b.* malleus.

*D.* Operation completed by removal of the outer wall of the attic, the membrane, and the ossicles. *a.* Antrum; *b.* aqueductus Fallopii containing the facial nerve.

ascertain its direction, and it should then be enlarged by means of a gouge or sharp spoon. It will almost invariably be found to lead into the antrum. Should no sinus be found, the next step of the operation is to lay open the antrum. This cavity lies on a level with the superior margin of the auditory

meatus and about two-fifths of an inch behind it (see Fig. 139, *A*). To open it the chisel or gouge should be applied about half an inch behind the external auditory meatus on a level with its upper margin, and held slantingly so as to be almost *parallel* with the surface of the skull. The chisel is then driven in a forward and slightly downward direction until it enters the external auditory canal, and by proceeding in this way successive thin layers of bone are removed; great care must be taken to deepen the hole in the bone in a direction absolutely parallel to the external auditory meatus. The temporal ridge which marks the level of the floor of the middle fossa is generally a sufficient guide for the upper limit to which the bone may be removed. When the wound gets deep sponging should be carried out by means of the prepared strips of gauze, and its limits should be contracted until the opening in the bone is funnel-shaped and does not extend more than a quarter of an inch backwards from the auditory meatus. If a cavity is met with, a probe should be passed in to ascertain if it be the antrum; this may always be recognised by the probe passing through it in a direction forwards and slightly upwards into the tympanum. The antrum should be reached at a depth of not more than half an inch (see Fig. 139, *B*).

As a rule after a superficial layer of dense bone has been removed bone of a more cancellous structure is met with, but in some cases of old-standing disease the mastoid becomes very hard and sclerosed and the antral cavity may be extremely small or almost entirely obliterated. In such circumstances if the opening in the bone is made too low the canal of the facial nerve may be opened and the nerve damaged. In these circumstances if the antrum has not been reached by proceeding as above, the following method is advisable. The soft parts lining the external auditory meatus should be entirely detached and turned right out of the meatus. A probe with a bent tip can then be passed into the attic and aditus. The inner part of the superior posterior wall of the meatus should now be removed with a fine chisel, and then the probe can be passed into the antrum and by following its direction more bone can be removed until this cavity is opened.

When the antral cavity has been opened, a bent probe should be passed in to ascertain its extent and its whole outer wall should be cleanly removed. Then by inspection and with the probe the interior should be examined and any carious spots removed with the curette. Careful exploration should be made to ascertain the existence of a sinus leading towards the mastoid cells and if found this should be followed up. In some cases the whole of the mastoid process is diseased and then the outer cortex of the bone should be entirely chipped away and the cells removed with a gouge or sharp spoon. The greatest care must be taken to reach the furthest limit of the disease. It is now necessary when not already done to remove the bridge of bone which forms the posterior and superior wall of the auditory meatus and which separates the latter from the antral cavity (see Fig. 139, *B*). A probe is passed through the antrum into the tympanum

to ascertain the position of the aditus, and guided by it the bridge of bone is removed by carefully chipping it away with a chisel. It should be remembered that this passage leads inwards in a slightly forward and upward direction and great care must be taken not to go too low or the facial nerve will certainly be injured. The operation must be continued till the whole outer wall of the attic is removed. This is best ascertained by passing a probe into the attic with its end bent upwards, and then by drawing it outward the existence of a ledge of bone in this position can be ascertained. When this has been completed the ossicles and remains of the membrane if present come into view and should be removed (see Fig. 139, C). The entire lining membrane of the tympanum should be freely but gently curetted, and the aditus and antrum thoroughly scraped out and cleaned.

The soft parts now require to be dealt with. The best plan is to pass a director down the external auditory meatus and out through the mastoid wound. Along this the soft parts are divided for the entire length of the auditory canal, and a short transverse incision should be made at the outer end so as to unfold the funnel-shaped process and allow the parts to come into contact with and partly line the large wound which has been made. A suture is now passed through the outer angles of these two flaps and deeply through the skin behind the posterior incision so as to hold the flaps well apart and allow the mastoid antrum to be freely reached through the external auditory meatus. The wound behind the ear is now completely closed by a few interrupted sutures, which should be of some non-absorbent material such as silkworm gut. Free drainage is obtained through the external auditory meatus which should be lightly packed with a strip of cyanide gauze soaked in glycerine and iodoform emulsion. The ordinary dressings may now be applied.

The *chief dangers* of the operation are wounds of the lateral sinus, of the middle fossa and of the facial nerve. The lateral sinus lies immediately behind the antrum and may be exposed if the opening in the bone be made too far back or if the sinus lie in an abnormal position. If care be taken by removing thin strips of bone, as above recommended, the sinus will only be exposed and not punctured and no harm will ensue. Should it be accidentally opened the bleeding is usually profuse, but it may be easily arrested by lightly packing the hole with a strip of gauze, and the operation may be continued. The middle fossa of the skull may be entered if the opening in the bone be made too high up, but unless this be carelessly done the dura mater will not be opened and no harm will ensue. Should the dura mater be accidentally wounded the opening in it should be thoroughly cleansed and closed by a fine catgut suture. The facial nerve may be damaged when removing the bridge of bone between the antrum and the auditory meatus, if the chisel be applied too low; or, when the last strand of bone is cut through, if too much force be used, the chisel may injure the aqueduct as it lies on the inner wall

of the aditus. If facial paralysis is found immediately after the operation it usually implies a severe injury, perhaps complete division of the nerve, and recovery rarely ensues, but some improvement may be obtained by the use of the faradic current and facial massage. When paralysis supervenes three or four days after the operation it is usually incomplete and under appropriate treatment will pass off in a few days or weeks. The external semicircular canal may also be wounded should the chisel slip when completing the operation. It lies on the posterior wall of the aditus just above the aqueduct.

*After-treatment.*—In most cases the packing may remain untouched for three to five days when it should be removed, the parts cleansed by syringing with boracic lotion and the plug and dressing re-applied. The post-aural wound commonly heals by first intention and the sutures may be removed about the seventh day, but the packing must be continued for three or four weeks. At the end of this time all the exposed bone should be covered by fine healthy granulations and the epithelium from the meatus beginning to grow over. The packing may now be discontinued and the ear treated by daily syringing, drying and the insufflation of boracic acid. If the discharge diminishes, this treatment may be continued, but should exuberant granulations form accompanied by discharge it is better to resume the packing. Healing is usually complete in from two months in children to from three to five months in adults, when the entire surface of the wound becomes covered by smooth glistening epithelium and all discharge ceases. Should large granulations occur at any spot they may require to be dealt with in the way already recommended by means of the application of caustics (see p. 397), but if exuberant and frequently recurring the existence of a carious patch of bone may be suspected, and it may be necessary to give the patient an anæsthetic and to thoroughly curette the part.

*Results.*—In the majority of cases the results of this operation are extremely good. In about eighty per cent. complete healing and cessation of the discharge occurs and in the remainder all fear of dangerous complications is at an end. The most troublesome cases are those associated with the formation of cholesteatomata and those in which tuberculous disease is present. Sometimes however exfoliation of the newly formed epithelium takes place and masses accumulate in the deeper parts which require to be syringed away from time to time. If this be not done they set up irritation and a condition resembling acute eczema, which may be accompanied by a considerable amount of discharge. This usually yields readily to cleansing by irrigation with boracic lotion, drying, and powdering with boracic powder.

The results as regards the hearing power vary. In some cases it is improved; in the majority it is unaffected and in a very few the hearing is made worse or may even be completely destroyed. Even where both ears are affected therefore there need be no hesitation in performing this

operation on both sides, and in most of the cases in which this has been done one or other ear has shown slight improvement.

Attempts have been made to shorten the after-treatment by the adaptation of Thiersch's method of skin-grafting. About ten days after the original operation the surface of the bone is usually pink and granulating and ready for grafting. The wound behind the ear is re-opened, all bleeding is arrested and then a large graft, some two inches long by one broad, is cut from the arm (see Part I., p. 50). This is carefully manipulated into position so as to completely line the antrum, tympanum and all the uncovered parts of the bone. It is better to use one piece of skin for this purpose, but if necessary a second may be applied. The wound behind the ear is again sewn up and the packing applied through the external auditory meatus. This has to be done with the very greatest care to avoid displacing the graft, and in most cases it is advisable to cover the graft with a piece of gold leaf. The meatus should then be lightly but thoroughly packed so as to hold the graft in contact everywhere with the bone, and this packing is best left undisturbed for a week if no discharge be present. It should then be removed by syringing combined with gentle traction with the forceps: if adherent, a piece only should be removed at a time. In this way the plug may not be entirely removed for three or four days, in which case the graft will usually be found to be firmly adherent. Subsequently the packing may be renewed every three or four days until the entire wound is covered by epithelium. In this way complete healing may often be obtained within five weeks.

For the success of this method it is essential that the bony parts at the original operation should be made as smooth as possible, all irregularities being carefully removed with a sharp spoon or burr. In some cases also the graft may be quite readily applied at the first operation and thus do away with the necessity for subsequently administering a second anæsthetic and re-opening the mastoid wound.

#### CHRONIC SUPPURATION IN THE MASTOID ANTRUM.

In this condition the lining membrane of the antrum is secreting pus, but, the cavity communicating freely with the middle ear, the discharge escapes and gives rise to none of the symptoms of acute mastoid disease. The condition is usually recognised by a process of exclusion. In chronic suppuration in the middle ear, if the membrane and ossicles be removed and the attic curetted and if the parts as far as can be seen appear healthy, it is obvious that if pus continues to form it must come from the antrum. Further a bead of pus is almost constantly present in the posterior and upper part of the tympanum. Sometimes there is bulging of the postero-superior wall of the external auditory meatus. Although the affection is characterised by the absence of symptoms, with the exception of the constant discharge, considerable pathological changes may have occurred in

the cavity. The mucous membrane may be extensively thickened and polypoid, the bone may be carious, the mastoid cells may be extensively involved and the walls of the cavity perforated, exposing both the dura mater and the lateral sinus.

**Treatment.**—The membrane and ossicles will of necessity have been removed before the diagnosis of chronic antral suppuration has been made. If, in spite of this proceeding, suppuration continues and does not diminish under treatment, a more radical operation should always be advised, for although the patient may be in no immediate danger, grave symptoms may at any moment supervene. Operation should always be carried out at once if there is bulging of the postero-superior wall of the external meatus, if the discharge is profuse, and especially if it be blood-stained, if the patient is liable to headache or if there is any tenderness on pressure over the antral cavity. In other cases there is no immediate hurry, but the operation should always be recommended if a purulent discharge persist in spite of treatment three months after the ossicles have been removed and the attic curetted. The complete post-aural operation should invariably be done (see p. 404).

#### CEREBRAL COMPLICATIONS. PYÆMIA.

The most important and grave result of chronic suppuration of the middle ear or antrum is the occasional occurrence of cerebral complications, such as extra-dural abscess, lepto-meningitis, cerebral abscess and of pyæmia and thrombosis of the lateral sinus. These may result either from caries or necrosis and perforation of the bone allowing direct extension of the disease to the dura mater and the brain or the infection may be carried by the perivascular lymphatics which accompany the numerous veins passing through the roof of the tympanum and antrum. This danger is especially great in children owing to the large number of the veins passing through the tympanic roof (which are subsequently obliterated) and to the thinness of the bony walls of the cavity. These affections are dealt with in Div. I. (see Chap. IV.).

## CHAPTER XXXVII.

### AFFECTIONS OF THE INTERNAL EAR AND PERCEPTIVE APPARATUS OF HEARING.

THE most prominent symptoms of labyrinthine affections are the diminished hearing by bone conduction, the marked lowering of the upper tone limit with comparatively slight interference with the lower notes, while extraneous sounds greatly interfere with the hearing power for conversation. In recent and acute cases other symptoms known as Menière's group of symptoms are present and probably depend upon interference with the semicircular canals. These are vertigo, with rotatory sensations and consequent staggering and reeling on attempting to walk, a tendency to fall towards the affected side, severe tinnitus, nausea and vomiting. The variety of the rotatory symptoms and the consequent movements depend upon which of the semicircular canals is affected.

When complete loss of hearing is present it is impossible to decide definitely if the labyrinth or the auditory nerve or centres are involved, except by the previous history and by the concurrent symptoms which the patient presents. As but little is definitely known of the pathology of these affections, and as in the majority of them very little benefit is obtained from treatment, they will be very briefly dealt with.

#### AFFECTIONS OF THE INTERNAL EAR.

**1. Hyperæmia and pressure on the labyrinthine fluid.**—A foreign body, a plug of wax, etc., may press upon the membrana tympani and this pressure may be transmitted through the ossicles to the fluid in the labyrinth and be more than the normal bulging of the fenestra rotunda can relieve, especially if the latter be thickened. In cases of catarrh of the middle ear adhesions may force back the ossicles on to the stapedial plate and thus produce pressure in the labyrinth which is increased by the fibrous thickening of the membranes closing the fenestræ. Syringing, especially if force be used and a large perforation be present, may pro-

duce symptoms of labyrinthine disturbance. In other cases hyperæmia of the labyrinth associated with general plethora is generally assumed to be responsible.

*Symptoms.*—The most prominent symptom is tinnitus which may be severe and is increased by lowering the head, straining, etc., but all the symptoms above enumerated as characteristic of internal ear disease may be present together with the symptoms due to the particular cause in action.

*Treatment.*—This consists in as far as possible ascertaining and removing the cause. In cases due to hyperæmia the most effective treatment is local blood-letting. Tinnitus in plethoric individuals is very commonly relieved spontaneously by epistaxis and in such cases an incision into the inferior turbinate, the bleeding from which should be encouraged, is the best treatment. Subsequently such patients should be properly dieted and a daily aperient such as a dose of Carlsbad salts, Apenta water, or sulphate of magnesia should be prescribed.

**2. Drug deafness.**—Certain drugs, such as quinine and salicin and their salts, if given in large doses or to especially susceptible patients, may produce deafness and tinnitus. This is usually temporary and ceases on discontinuing the use of the drugs, but it may become permanent if their use be persisted in. This is most likely to be the case when quinine is taken in large doses for a long time as is not unusual in malarial districts. The mode of action of these drugs is not understood, but it is possible that quinine acts by producing anæmia of the labyrinth.

*The treatment* obviously consists in removing the cause and subsequently in attention to the general health. In persistent cases the liquor strychninæ (℥ v. t.d. s.) should be administered.

**3. Labyrinthine hæmorrhage or Menière's disease.**—In this affection the acute symptoms above detailed, namely, tinnitus, vertigo, nausea, etc., attack a patient suddenly and without warning. The tinnitus may occur so suddenly that it seems as if a pistol-shot went off in the ear. The patient tends to fall over towards the affected side, but the symptoms are rarely severe enough to cause him to actually fall and he can generally manage to save himself by clutching some support. After a short time feelings of nausea usually accompanied by vomiting occur. The attack will last a few minutes or several hours and usually recurs. Such attacks may occur daily, weekly, or every three or four months, and the patient is fairly well in the intervals. In the early stage the patient may be only slightly deaf or may even not notice the deafness, but in the later attacks deafness is always present, and although subsiding somewhat in the intervals is increased after each attack. Should both ears be involved not only is the hearing lost, but the patient has also impaired power of equilibration. The disease may be arrested after a time, in which case the hearing will remain stationary, or more rarely may slightly improve. In the majority of cases if left untreated however the affection will progress until complete



deafness is established, when the other symptoms usually subside. These symptoms must be carefully distinguished from bilious attacks with which they are often confused. The disease is most common in old people, and its suddenness of onset while often in comparatively good health forcibly suggests that the cause is a sudden hæmorrhage into the labyrinth. Sometimes general debility seems a predisposing cause, but in the majority nothing will be found, and the exact pathology cannot be determined.

*Treatment.*—In the acute stages nothing gives so much relief as counter-irritation to the mastoid especially in the form of wet cupping or leeching. Should this be deemed too severe, blisters may be applied. In the intervals between the attacks the best treatment is the internal administration of hydrobromic acid, in doses of thirty to forty minims of the dilute acid three times a day and gradually increased until a drachm or even a drachm and a half is being taken as a dose. If preferred bromide of potassium may be given, but is more depressing. These drugs usually at once relieve the frequency of the attacks and diminish the severity of the tinnitus, and in the majority of cases effect a cure. The disease however always tends to relapse, especially if general debility occurs, and then the treatment must be repeated. Where bromides fail, quinine in one to three grain doses three times daily may be tried. In other cases salicylate of soda or salicin in full doses has apparently done good, but its action must be carefully watched. When the symptoms have subsided tonic treatment must be carried out and any constitutional ailment remedied.

**4. Acute inflammation of the internal ear.**—This affection is rare but may result from the spread of purulent otitis media, especially in connection with chronic suppuration of tuberculous origin in which necrosis of the inner wall of the tympanum has occurred. It also occurs as a result of very acute infections, such as scarlet fever.

*Symptoms.*—Pain is very acute and deep-seated in the ear and constitutional disturbance is usually severe. In addition there is marked tinnitus and deafness together with giddiness, staggering, nausea and vomiting. There is great danger of cerebral complications ensuing. If recovery ensues, complete deafness will probably result but the other symptoms pass off.

*Treatment.*—This is similar to that for acute middle ear suppuration. A good purge should be given and the constitutional treatment attended to, and at the same time energetic counter-irritation should be employed over the mastoid region. In the first place four or five leeches should be applied all round the ear and subsequently the mastoid repeatedly blistered. In acute otitis media the membrana tympani should be punctured and free escape provided for the discharge (see p. 385). In chronic cases the complete post-aural operation should be adopted (see p. 404).

**5. Syphilis of the internal ear.**—(a) *Inherited syphilis.*—This affection is usually bilateral, is most frequent in females between the ages of ten and twenty and seems almost invariably to follow interstitial keratitis, the ear affection commencing as the disease in the eye subsides. Deafness

gradually sets in without pain or any other symptom and occasionally is arrested spontaneously, but in most cases after the affection has progressed slowly for one, two or even more months, suddenly complete deafness sets in.

*Treatment.*—In cases where interstitial keratitis is present the commencement of slight deafness should always be carefully watched for, as in the early stage good results may be obtained by active treatment. But even if complete deafness be present and is not of more than two months' duration treatment should always be tried. The best results are obtained by repeated blistering over the mastoid and as soon as one blister has healed another should be applied. It is better to apply fresh blisters than to maintain an open sore. In addition to this, anti-syphilitic remedies should be prescribed; the patient should be placed under the influence of mercury as rapidly as possible, which is best done by means of inunction (see Part I., p. 233). Potassium iodide may also be given and rapidly pushed to full doses. In the later stages when the affection has partly subsided and especially if the general health be not good the solution of perchloride of mercury should be prescribed together with full doses of perchloride of iron. Good food, tonics, and change of air must also be ordered as required.

If the patient be seen early the deafness may commonly be arrested by these means, and even if complete deafness be present the hearing may occasionally be restored to a large extent. If improvement is obtained the treatment should be continued for three, four or five months. When absolute deafness has been present for two months treatment is of no avail, and a good result is extremely rare if the hearing has been lost for more than fourteen days.

(b) *Acquired secondary syphilis.*—Very rarely indeed a similar affection to the above may occur in acquired syphilis, usually in the late secondary period one to two years after infection. In these cases also the affection is bilateral, but one ear is not uncommonly affected one, two or three months before the other. The prognosis and treatment are exactly the same as for the inherited form and improvement and even a cure may be obtained in recent cases.

(c) *Tertiary syphilis.*—In very rare cases it is probable that a gumma may form in the internal ear. The symptoms are similar to those of acute inflammation of the internal ear: the pain is usually less severe but associated with nocturnal exacerbations. The diagnosis is made from the history and from other signs of syphilis and confirmed by the result of treatment.

*Treatment.*—The treatment is that of acute inflammation, energetic counter-irritation, etc. (see p. 413), together with the administration of iodide of potassium and other anti-syphilitic remedies (see Part I., p. 235).

**6. Mumps and specific fevers.**—In very rare cases complete internal ear deafness follows an ordinary attack of infective parotiditis. The deafness is usually absolute, but most commonly one ear only is attacked. The attack may commence with deep-seated pain in the ear accompanied by tinnitus, vomiting and vertigo. Occasionally signs of

inflammation are present in the middle ear, but this rarely goes on to suppuration.

*Treatment.*—The best treatment is repeated blistering over the mastoid region, and occasionally good results follow. If the case be of old-standing no treatment is of any avail.

A similar affection may occur in the course of both typhus and typhoid fever, which may pass off during convalescence or may produce permanent deafness. This may be due to a peripheral neuritis. The treatment is similar to the above.

**7. Boilermakers' deafness.**—This affection is produced by the action of a continual loud noise. The terminations of the auditory nerve may apparently be paralyzed by over-stimulation in somewhat the same way as the retina is affected by sunlight. As the name of the affection implies, it occurs among boilermakers or in those following similar occupations in which the constant noise of hammering is literally deafening, but as a rule it is only seen in those who have followed such occupations constantly for ten or more years. The middle ear may also be affected from loosening of the ossicles and membrane by the continual jarring.

*Treatment.*—The affection usually improves if the patient be seen in the early stages and consents to change his occupation. This is the essential point, but the administration of liquor strychninæ (five to six minims ter. die.) will also be found of much service.

**8. Senile deafness.**—This may be partly due to senile changes in the tympanic cavity, but is usually chiefly dependent upon labyrinthine affection. The deafness may commence at any age after about 45 and is usually progressive but may be arrested temporarily. Obviously treatment other than that directed to the maintenance of the general health is out of the question.

#### AFFECTIONS OF THE AUDITORY NERVE AND CENTRES.

Any lesion involving the auditory track from the centre to the termination of the nerve will of course result in deafness with or without impaired power of equilibration. The auditory nerve is not uncommonly involved in meningitis, especially in the simple basic form and in cerebro-spinal meningitis, and if recovery occurs the patient may be left completely deaf. In some cases the inflammation may actually spread from the meninges along the sheath of the auditory nerve and produce acute inflammation within the labyrinth. Again, tumours or gummata occurring along the course of the nerve will produce deafness, generally unilateral. In fractures of the base of the skull the nerve may be torn across or may be pressed upon by blood-clot or inflammatory effusion. Deafness may also arise from any form of brain disease, tumours or gummata, etc., affecting the centre, or from congenital lesions such as defective development of the

brain; in the latter case there are usually infantile convulsions or obvious mental defects.

*Treatment.*—This depends upon the cause and no special directions can be given. Where complete deafness is present lip-reading must be taught as soon as the child becomes old enough, but where congenital mental defects are present speaking by signs must be resorted to.

In meningitis the deafness is usually permanent. In fractures recovery may occur, in which case there is usually improvement within six months. In congenital deafness the prognosis is very bad unless there are signs of hearing by the time the child is five years old. This occasionally occurs and gradually improves until fair recovery may result and the patient will learn to talk.

#### NEURASTHENIA.

Persons suffering from overwork or brain fatigue, or who have been subjected to much worry and anxiety, are occasionally subject to tinnitus without any sign of middle ear disease and without any impairment of the hearing. The noise is generally not severe and may be uni- or bi-lateral. Not uncommonly it is referred to the top or back of the head rather than to the ear. It may prevent sleep and add to the depression of the patient, and this is especially important in that these patients almost invariably suffer from insomnia and general depression. In some cases there is also impairment of hearing which examination shows to be internal ear or nerve impairment.

*Treatment.*—This must consist in complete rest from work, in change of air and tonics. Good food with a fair amount of exercise should be tried, but in the more severe cases the Weir Mitchell treatment is indicated. Unless energetically treated in the early stages the tinnitus very commonly becomes permanent, although the general health may be completely restored.

### SECTION III.—AFFECTIONS OF THE LARYNX.

## CHAPTER XXXVIII.

### GENERAL METHODS OF EXAMINATION AND TREATMENT.

#### METHODS OF EXAMINATION.

**Laryngoscopy in adults.**—The illuminants applicable have already been described (see p. 276), and the position of the patient, of the surgeon, and of the light are well shown in Fig. 140. The patient sits upright, with the head slightly inclined backwards, the mouth widely open, and the tongue protruded. The surgeon holds the tongue between his thumb and middle finger in a small cloth, whilst the index finger is rested upon the upper lip to keep back the moustache, etc. The patient should on no account pull against the surgeon, or the tongue is extremely likely to be cut against the front teeth. Also, the tongue should be pulled upwards rather than downwards, so as to prevent arching of the dorsum. The patient is asked to breathe rapidly and noisily, in and out, so as to raise the soft palate. The laryngeal mirror is warmed and introduced into the back of the pharynx, with the glass surface parallel with the tongue, and placed immediately below the uvula. It is then raised slightly so as to lift up the uvula, and slowly rotated until the larynx comes into view. In most cases the epiglottis, arytenoids, and parts of the interior of the larynx can be seen readily, but in order to examine the anterior parts of the vocal cords and to raise the epiglottis, if it overhang and obstruct the view of the interior of the larynx, it is necessary to make the patient phonate while the mirror is in position. The production of the sound "Ah" usually brings the posterior ends of the cords into view; "Eh" exposes the greater part of the larynx, but if the epiglottis be very pendulous and the anterior ends of the cords are not yet visible, the patient should be made to say "Ee," which raises the epiglottis to its utmost extent. These acts of phonation are also necessary to ascertain the mobility of the parts.

When the patient tolerates the mirror badly, a view of the larynx may often be obtained by pulling the tongue well forward and asking the patient to phonate, when the mirror can be quickly introduced and need not touch the soft palate or uvula at all. In the majority of sensitive patients, however, steady firm pressure is better borne than light tickling, and it is best to hold the mirror firmly against the pharyngeal wall. If the patient be very intolerant, the pharynx must be cocaineised; a 5%—10% solution of cocaine is brushed over the uvula and adjacent parts, the tongue being

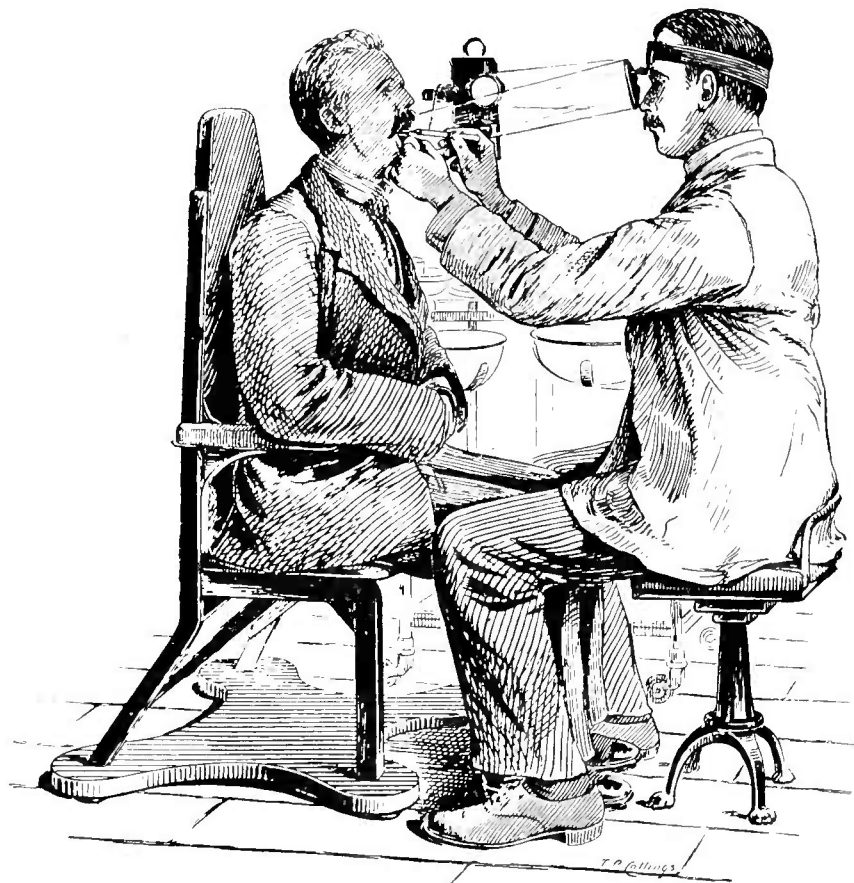


FIG. 14.—METHOD OF EXAMINING THE LARYNX.

meanwhile protruded and the patient instructed to breathe rapidly. When this has been done, special care must be taken not to overheat the mirror.

Should examination not be possible at the first sitting, the patient will require training, and the mirror should be frequently introduced for very short periods until the patient is accustomed to its presence, and generally in a short time a view will be obtained. In dyspeptics and alcoholic patients the throat is often extremely irritable, and even protruding the tongue excites uncontrollable retching. In such circumstances a course of mild purgatives and attention to diet will often render the throat much less irritable. The examination should always be made before and not after a

meal. In irritable patients the mirror should never be held in place for more than five or ten seconds, especially in untrained patients. It is much more satisfactory to introduce the mirror a greater number of times.

**The laryngeal image.**—The laryngeal image is reversed, just as is that in an ordinary mirror. The first point to be observed is the general appearance and colour of the mucous membrane for evidences of inflammatory action, and it is necessary to remember that cocaine produces anæmia, and similarly congestion may be due to previous struggling or retching. The general contour of the parts must next be noted, and especially the existence of swellings or small gaps and irregularities from loss of tissue. Finally, the movements of the vocal cords, both in phonation and respiration, must be observed. The vocal cords should approximate perfectly in the middle line during phonation, abduct equally and readily in inspiration, and the movements on the two sides should be symmetrical. With regard to this latter point, it must be borne in mind that the epiglottis is frequently twisted to one side, and that therefore it is not a safe guide to the median line of the larynx.

A useful view may often be obtained of the epiglottis and in favourable circumstances of the arytenoids or even of the interior of the larynx by means of a tongue depressor. The surgeon stands in front of the patient who is seated with the head thrown well back, and introduces a strong tongue-depressor well over the back of the tongue, pressing that organ forwards so as to straighten the oro-laryngeal cavity and allow a direct view into the larynx. To effect this, much force is usually required, and it is impossible to see more than the upper parts of the larynx even in favourable circumstances.

**Laryngoscopy in children.**—In most children of three years of age and upwards a view of the larynx may be obtained by the ordinary methods, although some training is often necessary before this is accomplished. The younger the child the longer and the more patient the training must be, but not only is it possible in almost every case to obtain a view, but the child can be taught to tolerate instrumental interference. In infants some other method must be tried and the following is the most generally effective. The child is held in front of the surgeon wrapped up in a blanket which restrains its arms, and the head is steadied by an assistant who may also hold the mouth open with a gag if necessary. A tongue-depressor with a curved end (see Fig. 103) is then introduced over the base of the tongue and hooked round the hyoid bone. The base of the tongue is depressed and at the same time pulled forward; if this be done very gently it frequently excites no resistance. A small laryngeal mirror is now introduced in the ordinary way and a view of the larynx can usually be obtained. It is better to proceed very gently and not to alarm and excite resistance on the part of the infant, so as to examine the larynx under normal respiration; if the child resists, the mirror should be held steadily in position until he is forced to take a breath, when a momentary

glimpse of the larynx is obtainable. By this method, with one or two trials on different occasions if necessary, a good view can always be obtained.

When it is imperative to obtain a view of the larynx at once and these methods are unsuccessful, an attempt may be made under an anæsthetic. This is a somewhat risky proceeding when laryngeal stenosis is present and should therefore not be attempted unless the diagnosis be a matter of importance. The child must be wrapped in a blanket and held upright in the nurse's arms. Chloroform, or a mixture of chloroform and ether, is administered until the reflexes are abolished. Two assistants are usually required, one to steady the head and to hold the mouth open with the gag, the other to pull forward the tongue. The soft palate, and if necessary the larynx, are then painted with a 4% solution of cocaine. This diminishes the amount of chloroform required to abolish the reflexes but its toxic action must be borne in mind and only a very little used. The mirror is now introduced in the usual way and, aided if necessary by the tongue-depressor, a good view of the interior of the larynx can usually be obtained. Not only is this method available for examination, but, should the laryngeal affection be removable by an intra-laryngeal operation, this may be at once proceeded with. Thus a foreign body, a papilloma, or a benign tumour of the larynx may be diagnosed and at once removed with laryngeal forceps.

#### GENERAL METHODS OF TREATMENT.

**Anæsthetisation of the larynx.**—This is best done with cocaine; in adults a 10%, in children a 2%—4% solution should be used. A very little solution is sprayed into the larynx with a suitable spray-producer under the guidance of the laryngoscope. Great care must be exercised to prevent the solution entering the pharynx, as if swallowed it is rapidly absorbed from the stomach and may produce dangerous symptoms; whereas it is much less liable to be absorbed from the laryngeal mucous membrane. After one or two preliminary sprayings, in which a few drops only of the solution should be used, the cocaine should be applied with a brush or by pledgets of wool on laryngeal forceps. The drug can thus be accurately applied to the desired spot, there is less danger of any entering the pharynx, the patient becomes accustomed to the introduction of the instruments and no more cocaine is used than is necessary to abolish the laryngeal reflexes.

The mixture of cocaine with extract of suprarenal capsule has already been described (see p. 285), and is also extremely useful; its full effect is obtained in about fifteen minutes, and will last from five to ten minutes longer than that of cocaine alone.

**Cleansing the larynx.**—To wash out the larynx a warm alkaline solution<sup>1</sup> should be used in a laryngeal spray. By means of the laryngo-

<sup>1</sup> A useful formula is five grains each of salt, borax, and soda, with a little glycerine, to the ounce of water.



scope the curved nozzle of the spray is directed well over the epiglottis, the patient is asked to phonate, and a vigorous spray is directed on to the vocal cords. This often produces spasm and cough, and mucous crusts, etc., are detached and come away with the solution. The spraying can usually be accomplished by the patient himself or by an attendant. The patient must draw his tongue forward, pass the curved nozzle of the spray well back into the pharynx and tilt it somewhat forwards as well as downwards. If now he draws a long breath at the same time that the ball of the spray producer is pressed, a large amount of the spray will be inhaled into the larynx. The larynx may also be cleansed by means of a Siegel's steam spray.<sup>1</sup>

**Steam inhalations.**—This is a most useful method of applying local medication in catarrhal affections of the upper air passages. It is necessary to have a jug capable of holding about two pints of fluid, round the top of which a towel is wrapped. The upper end of the towel is folded to form a cone, into which the patient's mouth and nose can be introduced; or a special inhaler, such as a Maw's, may be used. Into the inhaler a pint of nearly boiling water is introduced; it should then be left to stand for about five minutes, when any drug that it is wished to employ, such as compound tincture of benzoin, may be added. The steam should be inhaled for five to eight minutes by means of long, deep inspirations taken alternately through the mouth and the nose. It is very important that the vapour should be at a temperature of about 130° to 140° F. It is a common fault with patients to use inhalations too hot, when all the good effects are lost and the throat may be much irritated or even scalded. It is especially pernicious to keep on adding boiling water and to continue the inhalation too long. Eight minutes should be the maximum, but the inhalation may be repeated three or four times daily.

These inhalations relax the mucous membrane and render the patient susceptible to cold; therefore he should remain in the same room for at least half an hour after using them. When it is necessary for the patient to be out of doors during the day, the inhalations should be used only at night and in the bedroom.

**Insufflations.**—Various powders, such as morphine, orthoform, etc., may be introduced into the larynx by means of suitable insufflators guided by the laryngoscope. A minute quantity of powder should be diluted with some innocuous substance so as to diffuse it. For this purpose starch is useful as it forms a sticky mixture which adheres to the larynx. The application should be made whilst the patient is phonating and immediately after it he should be directed to close the mouth and inspire deeply through the nose, so as to prevent cough and allow the powder to remain in position. Astringents or strong solutions of any kind are best applied

<sup>1</sup> With this apparatus a coarse spray is produced, and the patient opens his mouth widely so as to allow the jet to play on to the back of his pharynx. By inhaling, the spray is drawn down into the larynx.

to the larynx with small, soft, camel's hair brushes mounted upon long metal handles bent at right angles two or three inches from the point. These should always be introduced by the surgeon himself with the aid of the laryngoscope. Caustics, such as chromic acid, should be applied in a similar manner, fused upon a probe or a special carrier.

**Intubation of the larynx.**—In cases of stenosis of the larynx from whatever cause arising, if dyspnoea be produced or asphyxia threatened, relief may be obtained by one of two procedures, namely tracheotomy or intubation. The former operation is described elsewhere (see p. 248). Intubation is most often employed in acute laryngeal stenosis in children, as in diphtheria, acute œdematous laryngitis, etc

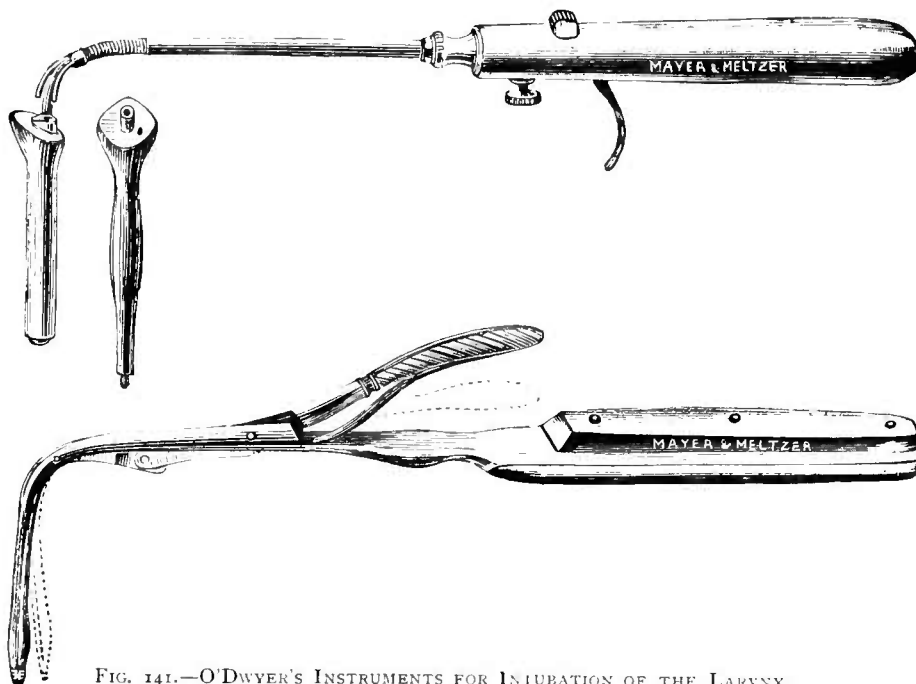


FIG. 141.—O'DWYER'S INSTRUMENTS FOR INTUBATION OF THE LARYNX.

**Instruments.**—The instruments required are a set of O'Dwyer's tubes of varying sizes, an introducer, extractor, gag and a scale (see Fig. 141). The tube is an irregular cylinder bulging at the centre so as to prevent its being expelled from the larynx by coughing, and with an expanded rounded head to rest upon the ventricular bands. Anteriorly there is a small perforation in the head to which is attached a loop of silk. The introducer is a rod with a separate jointed extremity for each tube. A sliding tube manipulated by a button on the handle fits over this rod and allows the tube to be detached when it has been placed in position in the larynx. The extractor somewhat resembles a pair of laryngeal forceps, but its two short blades open outwards when the lever in the handle is pressed.

**Method.**—The child is wrapped round with a blanket to restrain its arms, and firmly supported in the sitting position by a nurse. An assistant

steadies the patient's head and introduces the gag far back on the left side of the mouth. The surgeon then passes his left index finger back over the tongue until he feels the epiglottis and the laryngeal aperture. The tube attached to the introducer is slipped back along the finger until its tip is over the larynx; the handle of the introducer is then raised, the tube directed vertically downwards and carried sharply into position.

The success of this manoeuvre is ascertained by the finger, and the tube is then detached by pressing down the button in the handle of the introducer and held in position by the finger while the introducer is withdrawn. The gag should now be removed and a short interval allowed for the child to recover and to see if the dyspnoea has been relieved. If the operation has been successful, the gag is again introduced, the silk loop cut and withdrawn, the finger meantime retaining the tube in position. For the success of this operation considerable dexterity is essential: it is by no means easy in a young infant to feel the epiglottis or to ascertain the position of the upper aperture of the larynx, while rapidity in inserting the tube is essential. No attempt should last for more than five to eight seconds, and if unsuccessful the surgeon must wait before making a fresh attempt, for if the operation be prolonged asphyxia may be produced. In any case tracheotomy instruments should always be at hand.

*Accidents.*—While introducing the tube in cases of diphtheria a piece of the membrane may be detached and pushed down in front of it. In such circumstances the tube must be immediately withdrawn by means of the silk cord, when the membrane may be expelled, otherwise immediate tracheotomy may be necessary. Secondly, the soft parts may be lacerated, but this will never occur unless excessive force be used. The tube may easily be passed down the œsophagus, but this is of no importance if it be immediately withdrawn by means of the silk cord.

While the tube is *in situ* the following accidents may occur:—It may become occluded by secretion or membrane when it is usually at once expelled by coughing and the dyspnoea may return unless the tube be promptly re-inserted. In some cases this accident persistently recurs and renders tracheotomy necessary. If retained too long in position the tube may cause ulceration. But the most serious result is the interference with deglutition which almost invariably occurs, the tube allowing a certain amount of food, especially liquids, to enter the trachea and set up coughing. The best plan is to give semi-solids or thickened fluids. Should these not be taken easily, the infant should be fed with a nasal tube. In some cases the tube has been swallowed, usually without any ill effect and occasionally the tube has slipped down the trachea. This latter accident is the result of using too small a tube and has almost invariably occurred in adults with stricture of the larynx which did not admit of the introduction of a sufficiently large tube.

**Removal of the tube.**—The tube should always be removed as early as possible. To do this, a gag is inserted into the mouth and the left index

finger passed into the larynx until the upper aperture of the tube can be felt; the extractor with the blades closed is then guided in to the upper aperture of the tube when its blades are separated and the tube grasped and withdrawn.

**Comparison with tracheotomy.**—Intubation is a simple operation giving immediate relief, and can be very rapidly carried out. It avoids a cutting operation with loss of blood, shock and the necessity for an anæsthetic and there is no open wound to become infected. It has however the disadvantages that the tube may become blocked and require immediate removal, that in some cases there is a difficulty in retaining it and, if coughed up, asphyxia may occur before there is time to re-insert it, that there is difficulty in administering food and that, if too long retained, it may cause erosion or ulceration. It gives, however, much better results in children under five suffering from acute laryngeal stenosis than does tracheotomy. Tracheotomy however is safer in older children, when a skilled attendant is not always at hand, and it is necessary when the obstruction is low down. Again, the consent of the parents is far more easily obtained to intubation. After tracheotomy more skilled nursing is required, and convalescence is prolonged, but, the tube being fixed in, there is less danger of sudden asphyxia and therefore less need for the constant presence of the surgeon.

## CHAPTER XXXIX.

### INFLAMMATORY AFFECTIONS OF THE LARYNX.

#### ACUTE CATARRHAL LARYNGITIS IN ADULTS.

**Causes.**—This affection usually forms part of a general catarrh of the upper air passages such as arises from catching cold and is then commonly associated with tracheitis or bronchitis. It occurs in many general affections, such as the exanthemata, more especially measles: it may also result from violent functional efforts such as shouting, or from the administration of drugs such as iodide of potassium. In individuals subject to recurring laryngitis some predisposing cause will invariably be found: the most common is chronic laryngitis maintained by an unhealthy condition of the upper air passages, by breathing an unhealthy atmosphere, general ill-health, etc.

**Pathology.**—There is general congestion of the mucous membrane of the larynx with thickening and infiltration of the vocal cords: the latter point is important, as the exudation may extend into the muscular fibres of the thyro-arytenoideus internus and interfere with the action of that muscle, causing deficient tension of the cords.

**Symptoms.**—These are briefly hoarseness or aphonia and a tendency to excessive cough and constant clearing of the throat.

**Treatment.**—In itself the affection is not serious, and special treatment is therefore rarely called for except in the case of singers, public speakers, etc., in whom a speedy recovery is desirable.

**General.**—The patient should be confined to a room at a temperature of about 65° F., the air of which is kept moist by means of a steam-kettle. He should be strictly enjoined to rest the voice: whispering only is permissible and even this should be avoided as far as possible. The diet should consist chiefly of warm fluids. A brisk saline purge, such as a full dose of sulphate of magnesia, should be given and the general treatment already described for acute rhinitis should be carried out (see p. 295).

**Local.**—This consists in the employment of steam inhalations such as

vapor benzoin. comp.<sup>1</sup> used as already described (see p. 421) three or four times daily for about five minutes at a time. If in spite of this the cough is troublesome, morphine (gr.  $\frac{1}{4}$ ) should be insufflated into the larynx or small doses of tincture of opium given internally. In simple laryngitis this treatment suffices to obtain a cure, often in 48 hours. If bronchitis be present it must be treated accordingly. As the affection subsides, a more stimulating inhalation, such as the vapor pini sylvestris, may be used, and later still it may be necessary to apply astringent paints as for chronic laryngitis.

In the severer cases in which inflammatory infiltration into the thyro-arytenoidei interni has occurred, a weak voice, due to deficient tension of the vocal cords, is apt to remain. This is best combated by continued rest of the voice and the application of astringent paints, and later, if necessary, by the use of the Faradic current (see p. 453). When the attack has subsided, the attention should be directed towards the removal of any of the predisposing causes above described, and especially any abnormal condition of the upper air passages.

#### ACUTE LARYNGITIS IN CHILDREN.

Besides the mild form of acute laryngitis similar in all respects to the disease in adults, children, especially infants from one to four years of age, may suffer from a much more severe form of the affection. This is apparently due to involvement of the glottic and sub-glottic regions of the larynx, when, in addition to the loss of voice and croupy cough, there may be considerable dyspnoea, which commonly occurs in paroxysmal attacks, most often at night—whence the affection is commonly spoken of as “spasmodic laryngitis.” The glottic, and especially the sub-glottic, region of the infantile larynx is extremely narrow; consequently slight swelling is liable to produce alarming dyspnoea, and this is aggravated should any secretion accumulate there during sleep. In the majority of these cases some disease of the upper air passages, such as enlarged tonsils or adenoids is present.

**Symptoms.**—The child, who perhaps has been out of sorts and hoarse for a few days, or has suffered from a croupy cough, suddenly awakens at night with a severe spasm of dyspnoea. This, though very alarming, commonly passes off in five or ten minutes; it may be repeated again in a few hours, and similar attacks will occur on four or five succeeding nights. In rare cases the dyspnoea may prove fatal.

<sup>1</sup>This is prepared by adding one teaspoonful of compound tincture of benzoin to a pint of hot water (about 140° F.).

<sup>2</sup>The following formula may be used

R	Ol. pini sylvestris,	m. 40
	Magnes. carb. levis,	gr. 20
	Aquam,	ad $\bar{3}$ j

A teaspoonful in a pint of hot water for each inhalation.

**Treatment.**—The infant should be confined to bed in a warm, well-ventilated room at a temperature of about 70° F., and should be placed in a croup tent, and the atmosphere kept moist by means of a croup kettle. The steam may be medicated by the addition of tinct. benzoin. comp. The diet should consist of plenty of warm fluids. A brisk purge, such as one to two grains of calomel should be ordered together with a diaphoretic expectorant mixture.<sup>1</sup> If the cough be very troublesome, small doses of tinct. camph. co. or bromide of potassium should be given.

The best remedy for the attack of spasm is the immediate application of a hot fomentation, a poultice, or a sponge wrung out of hot water to the front of the neck; if possible, the child should be immediately placed in a hot bath to which a little mustard may be added. Should an attack be anticipated, the application of hot fomentations or poultices over the larynx will probably prevent it. One of the oldest and best remedies is the induction of vomiting either by the administration of vini ipecac. or mustard and water or by tickling the fauces with the finger or a feather. In very rare cases intubation or tracheotomy may be required.

When the acute attack has passed off, attention should be directed to the upper air passages; enlarged tonsils and adenoids, if present, should be removed, and the child placed under the best possible hygienic conditions. In most cases also benefit will be derived from the administration of the syrup of the iodide of iron and cod-liver oil.

#### CHRONIC LARYNGITIS.

This occurs as the sequel of the acute form, especially when the voice has not been rested and the affection has been neglected. It may also occur as the direct result of prolonged over-use of the voice. It may be due to the inhalation of impure air or to the inhalation of dust. In the large majority of cases an abnormal condition of the upper air passages is present, such as atrophic or obstructed conditions of the nose, chronic rhinitis, post-nasal catarrh, etc., and the affection is especially common during the period of rapid development of the larynx which takes place at puberty.

**Pathology.**—The affection leads to a chronic thickening and congestion of the mucous membrane of the larynx. The edges of the cords become rounded and approximate imperfectly. In the more chronic cases various hypertrophic changes may occur, the most common of which is called

<sup>1</sup> The following may be used:

Liq. ammon. acet.,	m. 10
Vini ipecac.,	m. 2
Ammon. carb.,	gr. ss.
Syrup. tolu.,	m. 10
Aquam,	ad ʒ i

Sig.—One teaspoonful every four hours for a child of two.

*pachydermia of the larynx*, which consists essentially of a hypertrophy of the papillary layers of the mucous membrane, and may lead to the formation of a considerable mass in the inter-arytenoid fold or over the vocal processes entirely preventing approximation of the posterior ends of the cords. These masses constantly coming into forcible contact during phonation may undergo ulceration, which may even extend deeply and give rise to extensive destruction of the cord and even necrosis of the cartilage.

Another result of chronic laryngitis is the production of *Singers' Nodules* or *Trachoma* of the vocal cords. These are small, rounded, symmetrical growths on the edges of the vocal cords situated almost invariably at the junction of the anterior with the middle third. They occur especially in singers and teachers, and are produced by using the vocal cords when slightly thickened.

More rarely a *Hæmorrhage* may occur on the vocal cord. This takes the form of a small blood cyst, and occurs suddenly as the result of violent use or straining of the voice while the larynx is congested; it is very persistent.

**Treatment.**—**The local treatment** must first of all be directed to the condition of the upper air passages and especially to the nose and nasopharynx. It is especially important to establish free nasal respiration.

For the laryngitis, steam inhalations may be used with advantage, the best being the vapor creosoti,<sup>1</sup> or the vapor pini sylvestris used as above directed (see p. 421). Where there is a tendency to dryness of the mucous membrane, the vapor cubebæ<sup>2</sup> may be used. When there is much sticky mucus in the pharynx and larynx, the parts should be cleansed by the application of an alkaline spray (see p. 420) or by Siegel's steam spray producer.

*In very chronic cases* with much thickening of the mucous membrane and paresis of the tensors, the best results are obtained by the application of astringents, which should be applied to the vocal cords with a brush. Chloride of zinc or nitrate of silver (30 grains of each to the ounce) may be applied on alternate days for a fortnight, and subsequently twice a week. The treatment is greatly aided if the patient is able to rest the voice. He may be allowed to whisper, but not to phonate.

When all inflammation has subsided and weak tension of the vocal cords alone remains, the Faradic current may be tried, in the first place, externally over the larynx, using a mild current for five to ten minutes

<sup>1</sup>R

Creosoti,	m. 80
French chalk,	gr. 30
Water,	oz. 1

A teaspoonful to a pint of hot water for each inhalation.

<sup>2</sup> Ol. cubebæ,	m. 40
Mag. carb. levis,	gr. 20
Water,	oz. 1

Used as above.



only. In more obstinate cases the inter-laryngeal electrode may be used as for functional paralysis (see p. 453). Systematic voice exercises may be prescribed, but should never be persisted in if the voice becomes tired or hoarse. When the laryngitis essentially depends upon the over-use of the voice the patient should have lessons in voice-production, as a faulty method is usually the cause of the trouble.

**General treatment.**—The predisposing causes above enumerated must be carefully sought for and as far as possible removed. General tonics and change of air are often particularly beneficial.

*Of pachydermia.*—This condition is extremely chronic and intractable. The best plan is the persistent use of the remedies above described, together with prolonged rest to the voice. At the same time any tendency to alcoholism should be corrected, the diet should be regulated, and any morbid diathesis, such as gout, should be treated. Occasionally benefit is obtained by the administration of iodide of potassium in small doses (gr. 5) thrice daily.

Where there is much thickening in the inter-arytenoid fold, operative interference may be necessary. The best plan, having thoroughly cocaineised the larynx, is to punch out a piece of the growth with a strong pair of cutting forceps such as Krause's or Lake's (see Fig. 144). Electrolysis has been recommended, but is extremely painful and tedious. The growths in the neighbourhood of the vocal processes may be similarly treated, the best instrument for the purpose being Krause's cutting forceps. In spite of removal, the growths commonly recur, and in advanced cases little improvement can be obtained. In the milder cases, especially those depending upon disease of the upper air passages, if the cause can be removed and if the treatment for chronic laryngitis be persisted in, a cure will commonly result.

*Of singers' nodes.*—These little growths will usually subside if the patient be able to completely rest the voice, and this is the only treatment that should be adopted with singers. In other cases, where rapid recovery is required and long rest is impossible, and where a perfectly fine voice is not essential, the growths may be removed with laryngeal forceps, but the greatest care must be taken not to injure the vocal cords. The voice should be rested for a short time after the removal, when complete recovery commonly ensues; there is no tendency for the growths to recur. *Hæmorrhages*, if persisting after the laryngitis has subsided, should be treated on similar principles,—prolonged rest in singers, removal with forceps in other cases.

#### LARYNGITIS SICCA.

This affection consists essentially in dryness of the mucous membrane of the larynx with considerable congestion followed by hypertrophy.

**Causes.**—The exciting causes may be exposure to cold or to irritating

inhalations, excessive smoking or alcoholism. The most common predisposing cause is an atrophic condition of the mucous membrane of the upper air passages and especially ozæna, or some obstructive lesion leading to buccal respiration and deficient moistening of the inspired air.

**Symptoms.**—The mucous membrane of the larynx is extremely congested and covered by small black mucous crusts which excite a constant irritating cough and may prevent approximation of the cords. There is also often thickening of the mucous membrane, especially in the inter-arytenoid region and over the vocal processes,—the condition known as *pachydermia*. The affection may be acute or chronic.

**Treatment.**—**Local.**—The first step consists in thoroughly cleansing the larynx with a spray. A warm alkaline solution should be used in the way above described (see p. 420) and repeated once daily by the surgeon himself or, if this be impossible, by the patient or an attendant. Immediately the larynx is cleansed, the patient experiences a great sense of comfort, and the voice returns, unless there is hypertrophic thickening of the mucous membrane. In addition the predisposing causes should be removed, especial attention being directed to any disease in the upper air passages. Alcohol and smoking should be strictly prohibited.

If the larynx cannot be cleansed by sprays, and in some of these cases the throat is extremely irritable and any application immediately excites retching or vomiting,—steam inhalations may be tried, such as the vapor creosoti or the vapor cubebæ (see p. 428). As the condition subsides, the larynx should be brushed over daily with a solution of nitrate of silver (20-40 grs. to the oz.) or of chloride of zinc (50-60 grs. to the oz.), should there be any tendency for the mischief to become chronic or should hypertrophic thickening of the mucous membrane be present. The laryngeal mucous membrane will tolerate very strong solutions.

**Constitutional.**—This always requires attention. Errors of diet must be corrected, alcohol strictly forbidden, and any tendency to gout appropriately treated. The majority of chronic cases will derive great benefit from a course of aperient waters, such as Carlsbad or Apenta, and from attention to the digestive functions. In anæmic cases iron, etc., may be necessary.

#### ACUTE ŒDEMATOUS LARYNGITIS.

**CAUSES.**—Acute œdematous laryngitis may result from several distinct conditions, and several varieties are met with. In the simplest form a small portion only of the larynx is affected, usually the epiglottis or aryteno-epiglottic folds or the arytenoids, apparently as the result of a cold, some slight septic condition or iodism. Secondly, a severe form of acute inflammation of the larynx may occur as the result of some acute infection such as the invasion of pyogenic organisms. It involves the sub-mucous tissues and not uncommonly the deeper structures of the larynx, and results in

very extensive and marked œdema of a large part of the laryngeal mucous membrane. This may be a primary affection starting in the larynx, or secondary to an acute inflammation of adjoining parts, such as tonsillitis or Ludovic's angina. Whether starting primarily in the larynx or spreading to it from adjoining parts an acute spreading cellulitis or an acute abscess may result. A third form of œdematous laryngitis is due to trauma; it may be caused by any injury, but is most commonly seen in children as the result of scalds of the larynx, either from actually swallowing boiling water or from inhaling boiling steam. A similar condition may result from swallowing corrosive poisons. This form not uncommonly ends in gangrene.

**Symptoms.**—In the milder form the disease simply gives rise to the sensation of a lump in the throat with slight soreness. Deglutition may be difficult if the epiglottis be much swollen. If the œdema be very extensive and especially if the glottic region be affected (which is luckily rare) there will be dyspnoea, which often occurs in severe paroxysms and may prove fatal. The œdematous parts appear as large red semi-translucent masses, the epiglottis and arytenoids being especially affected.

*The prognosis* depends almost entirely upon the cause. In the simplest cases there is practically no danger except in children in whom sudden asphyxia may occur. In scalds of the larynx, should the child not be suffering severely from shock, a good recovery may usually be expected. The septic cases associated with extensive cellulitis are very often fatal from exhaustion, septicæmia or lung complications. When the laryngeal cartilages are involved in the inflammation, necrosis may result and, should the patient survive, the tracheotomy tube may be permanently required.

**Treatment.**—The milder cases should be treated strictly according to the rules laid down for acute laryngitis (see p. 425). The patient must be kept in an equable temperature and, if the affection be at all severe, he should be placed in bed. A brisk purge should be administered and the diet should be light and not stimulating. All food should be given cold. If *steam inhalations* be ordered, great care must be taken that the patient does not use them too hot, and their action must be carefully watched to see that the œdema does not increase.

If there be any increase in the œdema, the application of *leeches* over the larynx may be tried; three or four are required in an adult and they usually act well in the mild cases. Should the steam inhalations seem to be increasing the œdema, they should be at once abandoned and the constant sucking of ice substituted.

Should the œdema threaten asphyxia, *scarification* may be tried. This is carried out by means of Mackenzie's laryngeal lancet or by Heryng's knife: both instruments require to be used with great care and should always be guided by the laryngoscope, consequently the method is unsuitable for children. Attempts to guide the instrument by the finger are

unscientific and dangerous. If there be much dyspnœa, especial care is required, for, should any of the blood enter the larynx, it may produce spasm and suffocation.

A little cocaine should be sprayed into the pharynx and a very little also applied to the laryngeal region. Then, guided by the laryngoscope, two or three small incisions are made into the œdematous parts. It is better to make definite incisions a quarter to half an inch long and a sixth of an inch in depth rather than simple pricks. In order to prevent blood entering the larynx it is advisable whenever possible to make the incisions to its outer side, thus, if the epiglottis be involved, the incisions should be made on its glossal surface and similarly a long incision may be made into either aryteno-epiglottic fold on its outer surface. The blood then tends to flow into the throat or mouth and not into the larynx. After the incisions have been made, hot water should be gargled to increase the bleeding. When this has ceased, the patient should again suck ice. In suitable cases this operation is very successful, but should it fail and dyspnœa supervene tracheotomy will be required.

*Tracheotomy* is indicated when dyspnœa is severe or increasing in all cases in children; and when the above treatment has failed, it is usually necessary in adults, and should therefore be performed early in all the more acute infections above described. The low operation (see p. 253) should be preferred when the dyspnœa is not too urgent to allow it to be deliberately undertaken.

*The constitutional treatment* must also be attended to. In the septic cases perchloride of iron in large doses (30-40 minims every four hours) should be given in adults and may be combined with quinine in one or two grain doses. In children, in whom there is a great tendency to laryngeal spasm, small doses of bromide of potassium may be administered, if there be not much dyspnœa between the attacks. In all the more severe cases the greatest attention must be paid to the nourishment of the patient; a fluid, very nutritious diet, such as milk and eggs and meat essences, must be given; occasionally brandy in large doses is required to meet the depression.

#### ŒDEMA OF THE LARYNX.

Besides the above acute œdematous laryngitis, œdema of the larynx may occur in two well-defined conditions.

(1) It may be secondary to other diseases of the larynx, such as acute or chronic perichondritis, and is very common in tuberculosis, syphilis, and malignant diseases. The treatment of this form will be described under the various primary conditions.

(2) Œdema of the larynx may be simply a local symptom of a general disease, such as renal or cardiac disease, or it may arise from pressure on the effluent laryngeal vessels at some distance from the larynx as in

aneurisms or tumours in the neck. There is also a peculiar affection which has been called acute angio-neurotic œdema, which occurs in connection with a similar disease of the skin.

**Treatment.**—The cause must be sought for and, if possible, removed. Otherwise the treatment is similar to that of œdematous laryngitis (see p. 431). The patient must be confined to bed in a warm equable temperature. Occasionally moist air is beneficial, but as a rule scarification is required and must be carried out with all the precautions above described; should it fail, tracheotomy must be performed.

PERICHONDritis, NECROSIS OF CARTILAGE, AND LARYNGEAL  
ABSCESS.

**ACUTE PERICHONDritis.**—This is usually of septic origin. It may result from traumatism, such as the lodgment of a foreign body, the passage of an œsophageal bougie, and especially the retention of a hard feeding tube in position for some days or weeks, or it may occur in connection with fevers, such as typhoid, or in spreading inflammation of the adjoining regions. Thus an abscess in the neck may spread and expose the laryngeal cartilages.

**Symptoms.**—The affection is very acute, and is accompanied by considerable pain, dysphagia, and loss of voice. There is tenderness and swelling in the laryngeal region; dyspnœa and severe constitutional disturbance. When the affection occurs in the course of diseases such as typhoid, the laryngeal symptoms are often masked by the general condition. Laryngoscopic examination reveals swelling and œdema of the affected part or sometimes of almost the entire larynx, and marked *impairment of movement*. An abscess may be seen, and is recognised by a yellowish prominent spot in the centre of the inflammatory region.

**Treatment.**—In the early stages the treatment is similar to that for œdematous laryngitis (see p. 431) for which the affection is often mistaken. When it is obvious that perichondritis is present, and especially when there is any sign of external swelling of the larynx, it is well to make *an external incision* right down to the laryngeal cartilages. In children it will usually be necessary to do a preliminary tracheotomy, but in adults this is often avoidable. The incision may usually be made under local anæsthesia, such as freezing with ethyl-chloride, and should be in the middle line extending from just below the hyoid bone nearly to the lower border of the thyroid cartilage, unless there be bulging in any particular region, when the incision should be made there. The incision should be left open, a small strip of cyanide gauze being inserted, and as a rule immediate relief will follow, especially if pus be evacuated. Should, however, the dyspnœa continue to increase, *tracheotomy* must be performed. Leeches may be applied over the larynx, but are not nearly so efficient as the incision above recommended. Should the affection go on to necrosis of

cartilage, the question of further operative procedure will arise (see chronic perichondritis).

**CHRONIC PERICHONDRITIS.**—This affection is usually associated with tuberculosis, syphilis, and carcinoma of the larynx, and may also result from acute perichondritis when necrosis of cartilage has occurred and a sequestrum remains; this is especially likely to occur in perichondritis due to trauma or occurring in connection with typhoid.

Another form of chronic perichondritis, which results in the formation of a large chronic abscess, is generally described as idiopathic, but the affection is really tuberculous. It results from a localised deposit of tubercle, and occurs quite apart from phthisis.

**Symptoms.**—The symptoms are similar to those of acute perichondritis, but come on much more slowly. A large indolent abscess may form and point in the neck, or more rarely in the larynx or throat. On opening the abscess, a large extent of cartilage is found bared and often necrosed. If the abscess point into the larynx, acute dyspnoea will be present, and, should it burst, it may suffocate the patient.

**Treatment.**—The treatment in cases of laryngeal phthisis, syphilis, and carcinoma is that for the latter affections. In chronic tuberculous abscess, operative treatment is indicated and *tracheotomy* should be done when severe dyspnoea is present and sometimes as a preliminary to operative interference within the larynx. The abscess should be opened if possible from the outside, but a small abscess pointing in the larynx, *e.g.* one in connection with an arytenoid, may with advantage be opened by the laryngeal lancet. If opened in the neck, it should be treated as a tuberculous abscess elsewhere (see Part I. p. 247).

When a sinus is seen in the larynx and a probe passed into it leads to a sequestrum, or if a sequestrum be found at the bottom of an abscess opened externally, the question of *thyrotomy* has to be considered. If there be definite evidence of the presence of a sequestrum, it will usually be best to cut down upon it from outside, or if its position be not accurately determined, to do an exploratory thyrotomy and to thoroughly examine the condition of the larynx and to remove all necrosed cartilage. The abscess cavity should be thoroughly curetted and packed with iodoform gauze, but no more cartilage than is absolutely necessary should be removed.

The operation itself is not a dangerous one, but, as a result of the disease, much distortion of the larynx may occur and lead to great narrowing of its lumen; in fact it may be impossible to dispense with the tracheotomy tube.

When there is extensive disease of the larynx, an endeavour should be made to prevent cicatricial contraction by the insertion of a T-shaped cannula (see p. 444), but in spite of all methods of treatment, in the majority of cases a permanent tracheotomy tube will be required.

## CHAPTER XL.

### TUMOURS OF THE LARYNX.

#### BENIGN TUMOURS.

**PAPILLOMA.**—This is the most common of all. There may be a single small growth, or large cauliflower-like masses may almost fill the larynx. They may grow from any part but are especially common on the vocal cords, the ventricular bands and the parts below. Their structure is that of the ordinary branching papilloma.

**FIBROMATA** come next in order of frequency; they form 8 to 10% of benign laryngeal growths and almost always occur in adults. They are usually single, pedunculated growths of smooth outline.

**CYSTS** are most commonly seen on the glossal surface of the epiglottis and especially the glosso-epiglottic ligament. They form smooth, roundish, semi-translucent swellings, which yield on puncture a glairy mucous fluid. They result from obstruction to the duct of a mucous gland with consequent distension of its alveolus.

**MYXOMA** is extremely rare; it forms a bright pink transparent-looking growth with a smooth surface and usually springs from a vocal cord.

**ANGIOMATA**, also excessively rare, may occur in any part of the larynx. Occasionally they give rise to severe and repeated hæmorrhages.

**CHONDROMA.**—This rare growth usually springs from the inner side of one of the laryngeal cartilages, and slowly pressing inwards may almost entirely fill the larynx.

**LIPOMA** may occur as a pedunculated tumour attached to the epiglottis.

**Symptoms.**—The symptoms caused by the benign growths depend entirely upon their position and size; if in the region of the vocal cords, alteration in voice is early noticed, and, if multiple or large, dyspnoea will occur. Occasionally paroxysms of dyspnoea are met with, apparently from a pedunculated growth suddenly changing its position and exciting laryngeal spasm. The tumours should be examined by the probe so as to ascertain exactly their size, density and place of origin which is frequently deceptive

in the mirror, and further information may sometimes be obtained by means of a tongue-depressor (see p. 419) or by the finger passed into the upper aperture of the larynx.

**Prognosis.**—*As regards life.*—In adults there is very slight danger, but rare cases of large growths completely filling the larynx may require tracheotomy. In children the disease is much more serious, as dyspnoea is common and may occur suddenly, necessitating urgent tracheotomy. This is always a serious matter in a young child especially as the tube may have to be worn a long time.

*As regards the voice.*—A good voice may usually be gained if intra-laryngeal removal be possible and especially when the growth is single; the chances become less in proportion to the number of the growths and their liability to recur. In children complete intra-laryngeal removal is more difficult and the commonest tumours, the papillomata, are usually multiple and recur rapidly and persistently; in time however this tendency to recur usually wears itself out and with care and patience a good result is usually possible.

**Treatment.**—**Papillomata.**—*In adults.*—The best method of treatment wherever practicable is undoubtedly intra-laryngeal removal under cocaine anæsthesia. The operation being done under good illumination carefully and quietly, there is no risk of injuring the laryngeal structures or of causing severe laryngeal spasm. Before operating it is usually necessary to give the patient a short course of preliminary treatment. Any disease of the upper air passages or pharynx, such as enlarged tonsils, elongated uvula, etc., should be attended to as it increases the difficulty of the manipulations. The larynx should be carefully anæsthetised with cocaine and suprarenal extract in the way already described (see p. 420). The probe should be repeatedly passed into the larynx in order to accustom the patient to its presence and this should be repeated on one or two occasions before the removal is attempted. On the first occasion also very little cocaine should be used, but the quantity may gradually be increased as the patient becomes more tolerant.

To remove the growths, two or three pairs of laryngeal forceps, such as Mackenzie's cutting forceps, are required; these may be made with a rounded or an obtuse angle (see Fig. 142) in place of the right angle, as pressure on the epiglottis can be tolerated under cocaine and that structure can thus be kept back out of the way. The forceps are warmed and introduced into the larynx closed; the blades being opened, a piece of growth is grasped and pulled away, care being taken to see that the laryngeal mucous membrane is not caught up. Papillomata being soft and friable are usually removed without any trouble; their evulsion excites a certain amount of hæmorrhage, but the operation can be continued as long as the surgeon can obtain a view of the larynx and the anæsthesia persists. If multiple growths be present, several sittings may be necessary.



When complete removal has been effected, the patient should be kept under observation in order that any recurrence may be at once dealt with. Any slight irregularities left after removal will gradually shrink up without any further treatment, provided the patient entirely rests the voice. The various applications for preventing recurrence or producing shrivelling of the growths, such as salicylic acid in alcohol, perchloride of iron, etc., that have been highly recommended are all unreliable. Chromic acid applied very carefully by means of a probe or carrier may hasten the disappearance of a small nodule, but it is liable to excite irritation. The internal administration of arsenic rarely has any effect.

Should a large mass of growths be situated below the vocal cords, attempts may be made to reach it with a long pair of forceps or a snare, but in some cases of this kind intra-laryngeal methods will fail. As however a growth in this position produces no effect upon the voice it

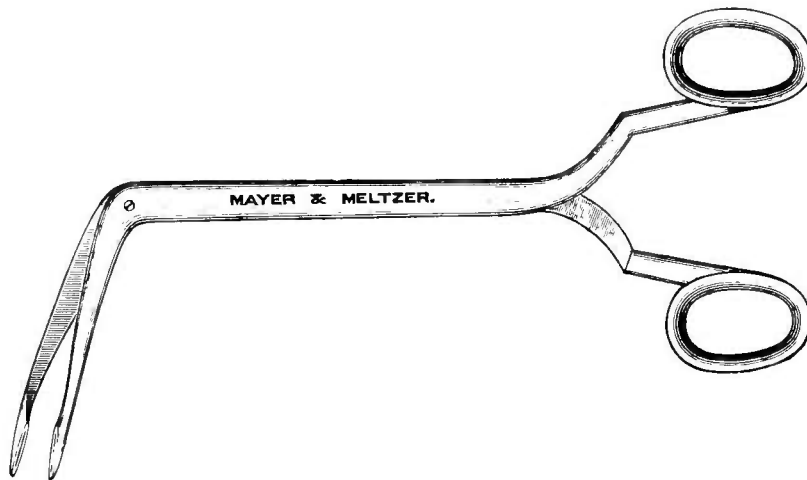


FIG. 142.—MACKENZIE'S CUTTING LARYNGEAL FORCEPS (modified).

need not be removed unless from its size it obstructs the lumen of the larynx sufficiently to cause dyspnoea. In such cases a high tracheotomy (see p. 248) should be done, the wound in the trachea held open, and the growth removed from below with a small pair of laryngeal forceps. This is usually quite readily accomplished, but, should it be necessary, the cricoid also may be divided to obtain freer access and a better view of the growth. The wound may be allowed to close at once as after thyrotomy (see p. 258), and the operation is attended by very little if any risk. If the incision into the wind-pipe be limited to the trachea or at the most to the cricoid, there is no danger of interference with the voice.

*In children.*—If the child can be trained to submit to the operation above detailed, this method should certainly be attempted, even if months are spent in the preliminary training, for the operation is free from risk and, if the child be once trained, it can be repeated as often as necessary. With sufficient care and patience this will usually succeed in patients over four years of age. In younger children, in those who cannot be trained,

and especially if dyspnoea be present, making the removal of the growths an urgent matter, other methods must be adopted.

The best plan is to operate under combined chloroform and cocaine anæsthesia (see p. 420). The operation is extremely tedious, but it may be continued for half an hour or even an hour, and the entire larynx may be freed from growths at one sitting. When dyspnoea is present this operation may also be attempted, but tracheotomy instruments should be at hand, and it is advisable only to remove a single large mass of growth and to complete the operation later. Of course, if there be much obstruction, it will be necessary to perform preliminary tracheotomy. The operation is certainly not free from danger, especially when there is laryngeal obstruction, as it entails administering chloroform in the erect posture, and the subsequent application of cocaine may produce alarming collapse unless used with the greatest care. It is therefore only to be used when the first method is impracticable, and then it is far preferable to the haphazard use of the forceps under chloroform guided only by touch; this can only be carried out safely after tracheotomy has been performed, and even then it is extremely difficult to remove all the growth without injury to the larynx.

When all the growths above the cords have been removed, should stridor or dyspnoea be present there are almost certainly other growths situated in the lower part of the larynx. These must be dealt with in the manner already described, a high tracheotomy being performed, the cricoid divided only if necessary, and the growths removed with the forceps from below.

Tracheotomy is necessary when severe dyspnoea is present or is excited by attempts at intra-laryngeal operation. It has been recommended as a curative measure as tending to induce atrophy of the growths; even if this were true the risks to the child meanwhile are considerable, as all respiratory affections are common and very dangerous in tracheotomised patients. Therefore, should tracheotomy be necessary to relieve dyspnoea, the growths should be subsequently removed and the cannula dispensed with as soon as possible.

Thyrotomy must be entirely condemned. It is by no means free from danger, it may leave permanent impairment of the voice or stenosis of the larynx, and no patient should be exposed to such risks for a disease which can be far better treated by other methods.

**Of fibromata and myxomata.**—These growths, occurring chiefly in adults, may always be removed by forceps under cocaine in the way above described (see p. 436). If the growth occurs in the anterior commissure, it is sometimes more convenient to use the snare. There is usually no tendency to recurrence.

**Cysts** of the epiglottis are best punctured with the electric cautery. It is well to burn a large hole in the cyst wall, when there will be no attempt at refilling. Simple incision is useless.

**Of angiomata.**—As these tumours usually involve a considerable depth of the laryngeal tissues, they are best left alone unless they give rise to serious symptoms. Should hæmorrhage occur, it must be arrested by applying the galvano-cautery to the bleeding spots. Should repeated hæmorrhages occur, it will be well to perform thyrotomy, opening the larynx, if possible, at a distance from the seat of the growth. Removal, if possible, is then accomplished, otherwise electrolysis may be used as for angiomata in other situations (see Part I., p. 266).

**Of chondromata.**—These cases frequently call for tracheotomy, which should be followed by thyrotomy, and the entire growth with the cartilage from which it springs should be cut away.

**Of lipomata.**—These growths, usually springing from the epiglottis, can be brought into view by means of the tongue-depressor and completely removed with an ordinary nasal snare.

#### MALIGNANT TUMOURS.

Both carcinoma and sarcoma are met with, the former being by far the commoner. It usually takes the form of a squamous-celled epithelioma, but glandular carcinoma is not unknown. Epitheliomata most frequently commence on the vocal cords or on the ventricular bands, but may be met with on any part of the larynx. Sarcomata more often commence in the infra-glottic region, while glandular carcinoma is most common in the epiglottis. The most valuable classification of cancer of the larynx from the point of view of treatment is into intrinsic and extrinsic growths.

**Intrinsic growths** are those in which the vocal cords and ventricular bands or the parts below are involved. In this situation the growth increases extremely slowly, displays little tendency to spread beyond the limits of the larynx, glandular involvement is extremely rare, and only occurs very late in the disease; secondary growths are almost unknown. At the same time the growth from its situation produces hoarseness at an early stage, and, later, dyspnœa, so that the attention is drawn to its presence, and consequently both early diagnosis and early treatment become possible.

**Extrinsic** laryngeal growths are those involving the epiglottis, the arytenoids, or the ary-epiglottic folds. They may commence in these parts or may spread from the surrounding regions, and especially common is a growth spreading from the lateral or anterior walls of the pharynx on to the arytenoids. The growth usually spreads rapidly over a large surface. Glandular enlargement occurs early, in fact, quite commonly a large hard mass of malignant glands in the neck is the first symptom to attract the patient's attention, and the case often comes under observation too late to admit of radical treatment.

**Treatment.**—The treatment of the two classes of cases is essentially different; in the intrinsic cases, there is always the possibility of complete

extirpation of the growth; in the extrinsic form this is usually impossible.

**Of intrinsic laryngeal cancer.**—When first seen, unless the diagnosis be absolutely certain, the patient should be treated with anti-syphilitic remedies and especially by means of inunctions of mercurial ointment (see Part I., p. 233). If the case seem suitable for operation, a piece of the growth should be removed for microscopical examination so as to absolutely verify the diagnosis; but this should never be done unless the surgeon intends to follow it up by extirpation, as it usually excites increased activity in growth.

**Operative.**—In carcinoma all intra-laryngeal methods of removal may be at once condemned as inefficient; the choice lies between thyrotomy and partial or complete extirpation of the larynx. When the growth involves extensively both sides of the larynx and the patient seems a suitable subject for a major operation, *extirpation of the larynx* (see p. 261) may be undertaken. If a small growth be present and especially if it be limited to one side of the larynx, *thyrotomy* (see p. 258) may be performed. It is better to prepare the patient for the major operation and then to open the larynx and proceed according to what is found. These operations are fully described elsewhere.

**Palliative.**—Should the patient decline operation, or should the case be unsuitable, palliative measures must be adopted. These consist in attention to the general health and especially the administration of a suitable amount of food, in the relief of pain, and in the performance of tracheotomy as soon as dyspnoea occurs. The pain and dysphagia may be relieved by the insufflation of *orthoform*. This powder is non-poisonous, and therefore the surface of the growth may be freely dusted with it. It usually gives complete relief from pain for at least twenty-four hours, when the insufflation should be repeated; its application may be entrusted to a trained nurse. Should it fail, the pain must be relieved by the administration of opium or morphine. The difficulty in swallowing may sometimes be aided by posture (see p. 449). The patient can often swallow soft solids or thickened fluids better than liquids, which excite spasm from entering the larynx; all fluids should then be thickened, and in extreme cases food must be administered per rectum. Should obstruction be present from spread of the growth to the pharynx, the patient must be fed by means of an œsophageal tube, or the question of gastrostomy must be considered. When dyspnoea is present from stenosis of the larynx, *tracheotomy* must be performed, and the cannula should always be inserted as low as possible in order that the tracheotomy wound may not be subsequently involved in the growth.

**Of extrinsic laryngeal cancer.**—These growths can only be successfully extirpated in the early stages. The operation to be performed depends upon the situation of the growth, and no general directions can be given. In some cases it can best be reached by dividing the thyroid

cartilage as in thyrotomy, in others a sub-hyoid operation must be performed, whilst again in others the growth can be best reached by means of a lateral pharyngotomy. In most cases an incision should also be made to expose the glands in the anterior triangles of the neck. Even if no glands can be felt, there will almost always be some enlargement discovered on operation. These operations will be fully described in Part VI. In the large majority of cases the growths are too extensive and the secondary deposits are too large to admit of successful extirpation and in these cases the palliative measures above detailed must be adopted.

## CHAPTER XLI.

### SYPHILIS OF THE LARYNX.

MANIFESTATIONS of syphilis in the larynx are most frequent in men ; primary syphilis is practically unknown and the tertiary forms are more often seen than the secondary.

**Secondary syphilis** usually manifests itself as an obstinate form of laryngeal congestion associated with a peculiarly hoarse voice ; dusky, bluish-red congestion, especially if it be mottled in character and very chronic, always points to syphilis. Occasionally mucous patches or even condylomata may be seen associated with a similar condition of the pharynx ; superficial ulcerations are not uncommon in the late secondary period. All these conditions tend to heal in a few weeks under treatment, and leave no marked deformity behind them.

**Treatment.**—The treatment of secondary syphilis in the larynx is that of syphilis generally (see Part I., Chap. XII.). No special local treatment is required.

**Tertiary syphilis.**—The earliest, but a somewhat uncommon, manifestation of tertiary syphilis is obstinate *superficial ulceration*, which has a great tendency to relapse. The vocal cords and the inter-arytenoid folds are most often affected. A *gummatous* tumour is very rarely seen. It is usually single, but there may be two or more ; they are usually situated on the brim of the larynx, especially in the neighbourhood of the arytenoids.

The form of tertiary syphilis most often seen is *deep, destructive ulceration*, which leads to great loss of tissue and subsequent distortion of the larynx. When the epiglottis is attacked it becomes greatly thickened and œdematous, and then is rapidly destroyed. In the earlier stages this produces severe dysphagia, which passes off as the swelling subsides and the ulcers heal, although the epiglottis may be entirely destroyed. If the arytenoids or the aryteno-epiglottic fold be affected, there is also dangerous dysphagia and occasionally dyspnoea. In the interior of the larynx the mucous membrane, the muscles, and the cartilages may all be affected ; the latter may necrose and the whole interior of the larynx may be ulcerated and distorted beyond recognition.

*Cicatricial contraction* is an almost constant result of deep ulceration, and may lead to stenosis of the larynx. If the vocal cords be affected permanent aphonia results. Cicatricial bands may form between the cords or other parts of the larynx, or between the larynx and the pharynx; even the epiglottis may contract adhesions to the posterior pharyngeal wall. Even in the milder cases fixation of one or both vocal cords often remains. Not uncommonly also fleshy fibromatous excrescences are left behind and may persist in spite of anti-syphilitic treatment.

**Treatment.**—The medicinal treatment is the same as that for tertiary syphilis elsewhere (see Part I., p. 235), but a few special points must be carefully attended to. If there be dyspnoea or œdema of the larynx, great caution is necessary in administering potassium iodide. The first effect of this drug is to increase the œdema, and this may give rise to fatal dyspnoea unless the patient be under observation. Therefore all cases of laryngeal syphilis should be kept in bed, put upon a diet of soft foods (chiefly milk taken cold) and carefully watched. If there be much œdema at the brim of the larynx, scarification should be resorted to and the patient encouraged to suck ice. Hot steam inhalations should be avoided. It is well to commence the treatment in these cases by *mercurial inunction*, which will often sufficiently diminish the swelling to allow the iodide to be administered without danger. Many obstinate cases will yield to the administration of mercury by inunction, either alone or combined with iodides internally, much better than to the latter alone. There is always the possibility of tracheotomy being urgently required.

When there is an ulcer in the larynx accompanied by exuberant granulations, or when there are fleshy outgrowths, *calomel insufflations* should always be used. One or two grains of calomel are placed in the bulb of a special porcelain insufflator. This is heated by a spirit lamp until the calomel commences to vaporise. The insufflator is then introduced into position by means of a laryngoscope and the vapour blown down into the larynx. It will usually be found to produce a white film all over the laryngeal surface.

The general treatment of the patient must also be attended to. Dysphagia must be relieved by giving ice to suck, giving all foods cold, and if necessary insufflations of orthoform or morphia (see p. 421). If there be great difficulty in drinking, all fluids must be thickened or, in extreme cases, given per rectum (see p. 449). All severe cases must be kept in bed in an equable temperature and stimulants should be prohibited. Later on tonics and change of air are required.

If stenosis of the larynx supervene, tracheotomy must be performed, and the low operation (see p. 253) is advisable as the tube must usually be worn permanently. *The treatment of cicatricial contractions* is as a rule unsatisfactory. If there be a broad band of adhesion or if there has been extensive perichondritis and necrosis treatment is almost certain to fail. Also adhesions in the upper part of the larynx or between the larynx and

the pharynx are best left alone as their division is usually followed by more severe contraction.

If on the other hand there be but a thin web-like adhesion which has so much reduced the lumen of the larynx that tracheotomy has become

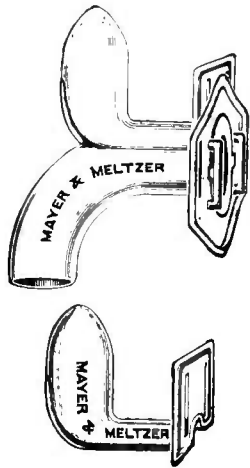


FIG. 143.—DILATOR FOR LARYNGEAL STENOSIS. The dilating plug when in position does not interfere with the air-way through the tube.

necessary an attempt should be made to remove it so as to dispense with the tube. The best method is to wait until active symptoms have subsided and then to perform thyrotomy, to excise all the obstructing tissue and subsequently to keep the parts separated until healing has taken place. The thyrotomy wound is sutured, but the tracheotomy tube is retained in the tracheal wound and a metal plug (see Fig. 143) is passed upwards from the lower wound through the constricted part of the larynx and retained in position for four or five months. A solid plug is preferable to a tube as it is more easy to introduce and does not collect secretion and thus does not require to be so often removed for cleansing. By this means the dilatation of the stricture can be maintained until all fear of contraction has passed off, without producing much inconvenience to the patient. On the other

hand dilators introduced through the mouth are generally ineffectual and cause great distress to the patient, and the same may be said of intubation.



## CHAPTER XLII.

### TUBERCULOSIS OF THE LARYNX.

#### LARYNGEAL PHTHISIS.

**Varieties.**—Several varieties of this affection are met with which, although they pass from one to the other, it is convenient to describe separately.

**1. The pre-tuberculous stage.**—In most cases of phthisis there is marked local or patchy anæmia of the larynx. Persistent or repeated attacks of laryngeal catarrh are also not infrequent and may lead to excoriation of the weakened laryngeal mucous membrane. These conditions are important because, from the anatomical irregularities of the larynx, accumulations of sputum tend to occur in its recesses, and the tubercle bacilli which swarm in the sputum are arrested and gain an entrance at any weak spot.

**2. The single tuberculous tumour.**—This is usually met with in cases of early or chronic phthisis in patients who maintain fair general health. One or occasionally two nodules may be seen, most commonly in the inter-arytenoid region but occasionally growing from the ventricular bands and more rarely from the vocal cords.

**3. Superficial ulceration of the vocal cords or adjacent parts.**—This is a purely intrinsic laryngeal disease and in this region the ulceration is at first commonly superficial and tends to spread but very slowly. Later it may extend in depth and even give rise to perichondritis and necrosis of cartilage. From its situation this form of the disease if accompanied by swelling or overgrowth is prone to produce laryngeal stenosis.

**4. Extensive tuberculous infiltration.**—The commonest and most distressing form of tuberculosis is that in which the upper aperture of the larynx, the arytenoids, the ary-epiglottic folds and the epiglottis are involved. In this region the mucous and sub-mucous tissues are extremely lax and are very liable to become œdematous; the tuberculous infiltration is usually deep and the cartilages are often involved. The epiglottis is swollen, of a dirty greyish-yellow colour and somewhat translucent. The

arytenoids are more or less symmetrically affected in a similar way, and under the semi-translucent mucous membrane are whitish or yellowish miliary tubercles which soon reach the surface and ulcerate. These little ulcers spread, coalesce and give rise to the worm-eaten, irregular ulceration on the surface of the œdematous swelling which is so characteristic of laryngeal phthisis.

**Symptoms.**—In the first three varieties described the symptoms are often slight. The voice may be hoarse or completely lost; if ulceration be present there is pain on speaking or coughing, but usually there is not much dysphagia, and the general health may be fair. In the fourth variety the patient's condition is usually extremely miserable. There is difficulty in swallowing, especially liquids, because the œdematous structures prevent complete closure of the superior aperture of the larynx. Where ulceration occurs swallowing becomes extremely painful, the saliva dribbles from the mouth, and patients frequently prefer to starve rather than to take food. If the condition goes on to perichondritis, abscesses may form either in the larynx or in the neck, and are accompanied by necrosis of cartilage. The œdema and swelling rarely give rise to dyspnoea, partly because the part affected, the upper aperture of the larynx, is the widest part of the tube, and partly because ulceration takes place early and rapidly.

**Treatment.**—**1. Of the pre-tuberculous stage.**—Bearing in mind the fact that laryngeal phthisis is invariably a complication of pulmonary tuberculosis and results from infection of the laryngeal mucous membrane by the bacilli in the sputum, the importance of preventive treatment is obvious. The simple laryngitis, so frequent in the course of phthisis, must therefore be vigorously treated. At the same time the general treatment of phthisis must be carried out, tonics, change of climate, etc., being prescribed as necessary. Especial care must be taken to prevent too frequent or too violent coughing, which may damage the laryngeal mucous membrane. The voice should be rested as much as possible and the sedative applications recommended for acute laryngitis (see p. 425) must be assiduously applied.

If the condition becomes chronic it must be met by stimulating or astringent paints, frequently applied (see p. 428). In many cases the inhalation of creosote (see p. 428, footnote) is especially useful. The patient should, if possible, live in a suitable dry and bracing climate, and should always give up smoking entirely, take only a small amount of alcohol, well diluted, and soft and unirritating food. In this way laryngeal complications may be rendered much less common.

**2. Of isolated tuberculous tumours.**—The best treatment is removal if the patient be in fair general health. These growths usually only give rise to hoarseness or loss of voice, but this has a depressing effect upon the patient. Moreover the tumours, although stationary for years, must be considered a constant menace, whilst their removal is usually easy and free from danger. The risk of infection by the sputum of the raw surface

left after removal seems to be very slight, and probably can be prevented by suitable after-treatment.

To remove the tumours, the larynx should be thoroughly anæsthetised and the growth cleanly cut away with forceps, such as Krause's (see Fig. 144), or, if this be impossible, the growths may be scraped away with

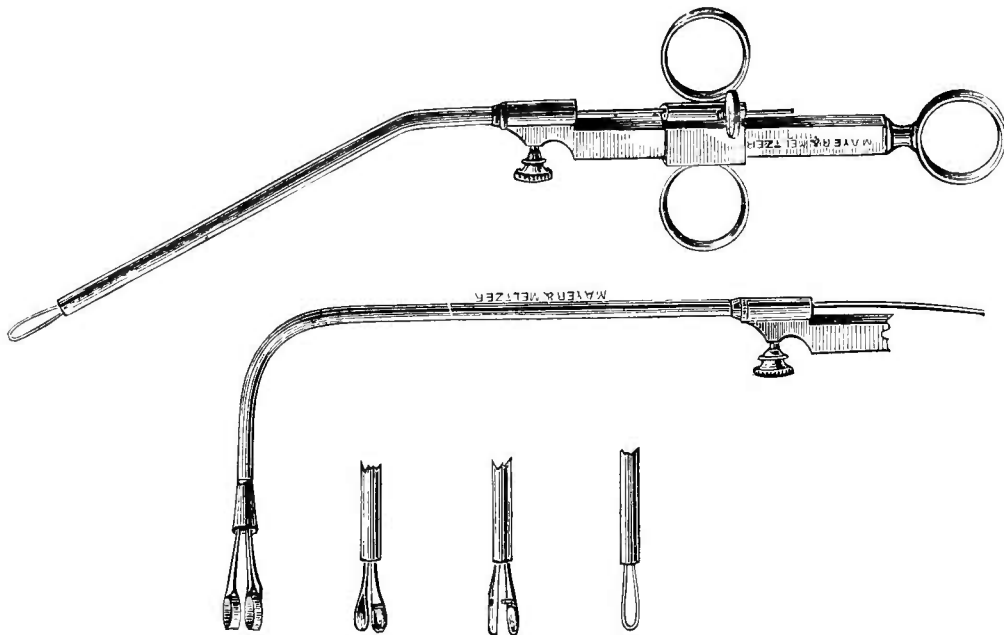


FIG. 144.—KRAUSE'S NASAL SNARE AND LARYNGEAL CUTTING FORCEPS.

a Heryng's curette (see Fig. 145). As soon as the bleeding has ceased, the surface should be dried and chromic acid fused on a probe or a special carrier thoroughly rubbed into it.

The *after-treatment* must be carefully carried out. The larynx should be inspected at least twice a week, when solutions of lactic acid (50% or

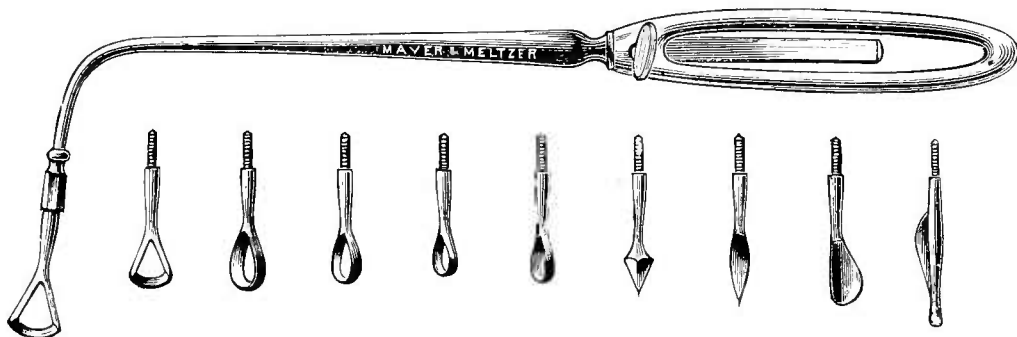


FIG. 145.—HERYNG'S LARYNGEAL CURETTES AND KNIVES.

60%) should be applied with a brush. For this cocaine is not usually necessary. If there be much secretion in the larynx it is well to wash it away every day or even oftener with an alkaline spray (see p. 420), and iodoform may be insufflated on to the wound. If there be pain on swallowing, a mixture of equal parts of orthoform and iodoform may be used until the ulcer is healed.

**3. Of intrinsic laryngeal tuberculosis.**—When superficial ulceration

of the vocal cords, ventricular bands, or the parts below is present, the important question to decide is whether active or palliative treatment should be adopted. If the affection be not too extensive, if the patient be in fair general health and the disease in the chest stationary or not rapidly progressing, and especially if the patient be fairly tolerant of laryngeal manipulations, an attempt should certainly be made to eradicate the laryngeal disease.

For very superficial, small ulcerations *the application of lactic acid* alone may be first tried, and the following method is the best. The larynx is anæsthetised, and a small pledget of wool firmly wrapped around a wool carrier or a pair of laryngeal forceps is dipped in pure lactic acid and the surface of the ulcer thoroughly rubbed over with it. This should be repeated at least twice a week. After four or five strong applications, if there be signs of healing, weaker solutions (40%—50%) may be applied with a brush.

In more marked cases and in those which do not yield to this method *the application of pure chromic acid* may be tried; this should be thoroughly rubbed into the ulcer on one or two occasions and subsequently simple painting with lactic acid carried out. In most cases of extensive ulceration however and especially when there are tuberculous granulations on the surface, it is necessary to operate more thoroughly and it is advisable to use the curette, but no operation should be attempted unless it seems possible to remove all the local disease.

*Curetting* is performed under local anæsthesia and more than one sitting may be required, but the operation should be completed in as short a time as possible. All the visible disease should be scraped or cut away with a sharp steel curette, such as Heryng's (see Fig. 145), after which the raw surface should be thoroughly cauterised with chromic acid. The operation may be repeated in a week if required. In this way the whole of one ventricular band or vocal cord may be removed. When all the disease has been removed, healing is usually rapid and once or twice a week the surface may be stimulated by the application of a 60% solution of lactic acid. If there be much inflammation or pain, iodoform or a mixture of iodoform and orthoform may be insufflated. These operations in suitable cases give brilliant results. In a few cases the voice is restored: in the majority the disease in the larynx is permanently arrested even though that in the lungs progresses.

#### 4. Of extensive disease with ulceration, œdema, perichondritis, etc.—

In these cases only palliative treatment is possible and must be directed towards relieving the chief symptoms causing distress, viz. the dysphagia, the pain, the excessive, ineffective cough, and in rare cases the dyspnœa. The disease is too deeply situated and is usually associated with too much general enfeeblement to admit of active treatment such as scarifications, the use of lactic acid, chloride of zinc or other irritants. All irritants in the food, smoking, alcohol, etc., must be forbidden, and the patient

should live in an equable temperature, in a mild dry climate and a place that is not dusty.

To relieve the *dysphagia* many methods are recommended; the best is undoubtedly to *insufflate the larynx with orthoform* daily about an hour before the first meal. Enough should be used to fairly dust over the affected parts, as the drug seems quite non-toxic. If the practitioner is not always available, a nurse, or even the patient himself, may be taught how to use it. Orthoform is but slightly soluble and adheres to the raw surface for a long time. Its anæsthetic effect lasts for six to twelve hours or more. The drug also allays the irritable cough and removes pain, enabling the patient to return to a proper diet. Orthoform is much better than cocaine, which has to be applied to the larynx about ten minutes before each meal as its anæsthetic effect is transient; moreover cocaine is toxic and must be applied by the surgeon himself, and its frequent employment seems to produce general wasting.

The *difficulty in swallowing liquids* may be relieved by thickening them with starch, thus rendering them less liable to enter the larynx, or the postural method may be tried. The patient lies prone on a chair or on a bed with his head hanging down well over the end; then he sucks up the fluid through a tube. Should this method fail, fluids may be given by enemata, a pint of salt solution (.75%) being given twice daily, or oftener if necessary, brandy being administered in the same way if desired.

If *dyspnoea* be present the question of tracheotomy arises. This complication is really only to be feared when the narrow glottic or sub-glottic region is affected, should much swelling occur and ulceration be delayed.

Tracheotomy has also been recommended as a palliative measure in severe tuberculous disease, but it has many and grave disadvantages. It materially diminishes the efficiency of the cough, the secretion from the lungs is apt to accumulate in the bronchi and alveoli and set up miliary tuberculosis. Again, the patient can often ill withstand even this slight operation; his power of speaking is diminished or lost and his mental anxiety is increased. Not rarely, also, the tracheotomy wound becomes infected with tubercle. For these reasons tracheotomy should never be performed in phthisis except for severe dyspnoea.

#### LUPUS OF THE LARYNX.

Lupus of the larynx is usually associated with a similar affection of the upper air passages and the skin. The disease is very chronic, causes very little œdema of the larynx even when affecting the upper aperture, and very rarely extends beneath the mucous membrane except in connection with the epiglottis, which latter cartilage is often partially destroyed. As a rule the epiglottis is first attacked; in time the whole larynx may become almost filled with nodular excrescences and the outline of the parts is obscured and distorted.

**Symptoms.**—The symptoms are usually slight, and the disease may progress with occasional exacerbations interspersed with long periods of quiescence for many years. Dyspnoea is rare, and occurs only when the glottic region is affected, and then generally somewhat early in the disease, that is, about its second year. Rarely phthisis may supervene, but the chief danger arises from the occasional necessity for tracheotomy.

**Treatment.—Constitutional.** *Arsenic* internally seems to act in most cases almost as a specific, and should be given as Fowler's solution in gradually increasing doses as tolerance is established, commencing at three to five minims for an adult and increased until fifteen or twenty minims of the solution are given three times a day. The effect is often almost as great as that of iodide of potassium in tertiary syphilis, and decided improvement is manifest at the end of a fortnight. The drug should be continued for two months after all signs of lupus have disappeared, and the case should be kept under observation for a year or more, so that any recurrence may be treated early. Combined with this treatment, tonics, cod-liver oil, change of air, and good feeding should always be employed.

**Local treatment.**—In certain cases as much as possible of the diseased tissues may be removed. This should be done in adults in whom there is extensive disease, who do not respond to the administration of arsenic, and who are in fair general health. The epiglottis may be treated by scraping, or a piece of it may be removed by the snare. The ventricular bands or the cords are best treated by scraping. The operation is performed as has already been described for tuberculous laryngitis (see p. 447).

Should dyspnoea necessitate tracheotomy, it is probable that the tube will require to be permanently maintained. After the disease has quite subsided, an operation on the lines already recommended for syphilitic stricture of the larynx may be attempted (see p. 444), but it is hardly likely to be successful if the stricture be a broad one.

## CHAPTER XLIII.

### NEUROSES OF THE LARYNX: MALFORMATIONS OF THE LARYNX.

#### ALTERATIONS OF SENSATION.

*Anæsthesia of the larynx* is most common in bulbar paralysis or other affections of the medulla, in diphtheritic paralysis and in hysteria. The whole larynx may be insensitive, or the anæsthesia may be unilateral. The great danger of the affection arises from septic bronchitis and pneumonia due to food, etc., entering the wind-pipe during swallowing.

*Hyperæsthesia, neuralgia, etc.*, are most commonly seen in hysterical patients, in those who habitually overstrain the voice, and as a sequel to inflammatory affections.

**Treatment.**—*In anæsthesia of the larynx* careful attention must be directed towards the feeding of the patient and if necessary this must be done with an œsophageal tube, which must be carefully guided over the larynx with the finger. The patient should always be made to phonate when the tube is in position so as to make sure that it has not entered the trachea. When the affection is unilateral, the patient may be taught to drink whilst lying upon the sound side with the head low, or the prone position (see p. 449) may be adopted.

*In cases due to diphtheria*, tonics, especially strychnine, should be administered together with the usual treatment of diphtheritic paralysis. Later, electricity, both the galvanic and Faradic currents, may be applied, first externally along the course of the superior laryngeal nerves and subsequently by means of the intra-laryngeal electrode. *In hysterical cases* this treatment by electricity should be combined with general anti-hysterical remedies. These cases usually recover in time.

*The treatment for hyperæsthesia, etc.*, must be chiefly constitutional, change of air and tonics being especially advisable. In addition the larynx should be painted at least twice a week with strong astringents as for chronic laryngitis (see p. 428) and if this fails electricity should be used.

## FUNCTIONAL PARALYSIS.

Functional aphonia depends on inefficient action of any of the muscles involved in phonation; and bilateral paralysis of these muscles is almost invariably due to hysteria.

The affection occurs chiefly in young women, especially if anæmic or phthisical, and is rare in children and men except as a sequel of acute laryngitis. When seen in men, it usually follows great mental excitement or hardship or a severe illness, and is due chiefly to paresis of the thyro-arytenoidei interni. The affection is commonly preceded by laryngitis, the whispering voice, adopted because of the pain or difficulty in phonation while the vocal cords are inflamed, persisting after they have regained their normal condition. In other cases the aphonia comes on suddenly without any cause and is often intermittent. Rarely there is complete loss of articulation—functional mutism.

In the commoner form, paralysis of the crico-arytenoidei laterales, the vocal cords remain far apart during phonation. In paralysis of the arytenoideus proprius alone, a triangular gap is left between the cords posteriorly. In paralysis of the thyro-arytenoidei interni there is an elliptical space between the cords and their edges appear slack and vibrate freely.

**Treatment.**—The cases following an attack of laryngitis must be treated for a time as described under chronic laryngitis (see p. 428), the affection often being the result of local muscular weakness. As a rule a successful result is obtained. The purely hysterical cases require both constitutional and local treatment.

**Constitutional Treatment.**—This consists in searching for and remedying any weakness which may be present; anæmia and digestive troubles especially must be enquired into. General debility must be met by the administration of tonics, such as strychnine, change of air and especially a sea voyage. In the severer cases the Weir-Mitchell treatment (see Part IV., p. 145) may be required. Those subject to recurrence of the affection, and especially if professional voice-users, should have lessons in voice-production. In many of these cases also the chest expansion in breathing is very deficient and regular breathing exercises, by which the patient is taught to distend her chest thoroughly, must be carried out.

**Local treatment.**—The best method is the application of strong astringents to the interior of the larynx by means of a brush. The solutions of perchloride of iron, etc. (see p. 428) are the most generally useful. Immediately after the brush has been removed from the larynx, the patient should be made to phonate loudly. The brush and the strong astringent produce a certain amount of laryngeal spasm, and, if the patient attempts to speak while this persists, he will usually do so in a loud voice. He should be made to repeat words rapidly until the voice is normal. This treatment should be repeated about twice a week. If the voice does not



return at once, constitutional remedies should be persevered in, the larynx regularly painted, and the patient encouraged until the voice returns, and in this way success will usually be obtained without the use of any of the violent measures so commonly recommended. Moreover, the cure will be a permanent one, which is not always the case when the voice has been forced back by strong applications of a Faradic current or by other emotional influences. In many cases the application of a spray to the larynx, the mere passage of the brush into the larynx, or even the use of the laryngoscope alone is sufficient to secure the return of the voice, but the application of the astringent pigments as above recommended is on the whole the most likely to be successful.

In the more severe cases of hysteria, and when after a thorough trial the above treatment has been unsuccessful, the application of the Faradic current may be tried. This may be done either through the skin or by means of the endo-laryngeal electrode. The former is preferable in the first instance; one pole should be placed over the back of the neck and the other applied over the larynx being moved up and down and from side to side so as to stimulate the various muscles. The current should be a mild one, such as can be easily tolerated, and it may be gradually increased. The patient should be made to phonate while the current is passing. The endo-laryngeal method consists in passing a special electrode by means of the laryngoscope into the larynx and placing it upon the various endo-laryngeal muscles, the other pole being placed as before on the back of the neck. This instrument usually excites a considerable amount of laryngeal spasm. By its means, if a sufficiently strong current be used, the voice can practically always be restored, at least momentarily, but in too many such cases a relapse occurs almost as soon as the patient has left the surgeon's room, and the case becomes a more obstinate one than ever. It is therefore better to bring the voice back gradually by gentle means, to coax it back, as it were, rather than to force it back. Very rarely all means of treatment will fail. This is especially seen when violent means to secure the return of the voice have been adopted, but even then an ultimate cure is probable, the voice returning months or even years after all treatment has been discontinued, often apparently without any cause.

#### FUNCTIONAL LARYNGEAL SPASM.

This is an extremely rare affection occurring in hysteria, and is due to tonic spasm of the adductor muscles: it gives rise to all the symptoms of bilateral abductor paralysis, but the dyspnoea, although often pronounced, is never fatal. The condition may be recognised by placing the laryngoscope in position, making the patient phonate, and encouraging her to maintain the sound until the air in the chest is completely exhausted: directly phonation ceases the vocal cords separate widely for a moment.

**Treatment.**—The treatment is that of hysteria in general, no local measures having any effect.

#### ORGANIC LARYNGEAL PARALYSIS.

Laryngeal paralysis may be caused—

1. *By disease of the cortical centres for abduction or adduction, by disease of the nuclei of the vagi or spinal accessory nerves, or of the intervening nerve tracts.* The most important of these paralyses is that occurring in tabes dorsalis, which usually results in bilateral abductor paralysis, although one side may be first attacked. This symptom may occur at the beginning of tabes or even precede the other symptoms.

2. *By disease or injury of the spinal accessory, vagi and recurrent laryngeal nerves in any part of their course,* the left recurrent being especially liable to be affected. Among the most common causes are aortic aneurysm and malignant disease in the mediastinum, the œsophagus, the thyroid gland, etc. The first result of pressure upon these nerves is to produce abductor paralysis; later, when the entire nerve becomes disorganised, adductor paralysis is superadded.

3. *By peripheral neuritis.*—The toxins of diphtheria, influenza and rarely of other exanthemata may involve the laryngeal nerves either by direct absorption or through their constitutional effects. Other poisons such as lead, arsenic, and alcohol may produce similar results. These conditions generally lead to abductor paralysis, but occasionally may result in adductor paralysis alone.

**Treatment.**—The first point is to ascertain the cause and to adopt appropriate treatment. Cases due to diphtheria and influenza should be given strychnine (Liq. strych. ℥ v.—viiij. ter die), a general tonic treatment, and later, if necessary, change of air. In obstinate cases, the Faradic current should be used, at first externally and subsequently intra-laryngeally if necessary. The diphtheritic cases usually get well, but permanent bilateral abductor paralysis has occasionally resulted. Cases due to influenza almost invariably recover after a few weeks or months.

In paralysis due to lead, arsenic, etc., the first point is to remove the cause, and the second to adopt means to eliminate the poison from the system. The subsequent treatment is that just described—strychnine internally, and electricity locally—and this is usually followed by recovery.

The treatment of the numerous other causal conditions cannot be gone into here; the large majority of them are incurable.

As a rule the local paralysis gives rise to few and unimportant symptoms, but two conditions occur in which grave symptoms arise, and therefore they must be specially considered.

1. *Bilateral abductor paralysis.*—Patients with this affection are liable to severe suffocative attacks occurring spontaneously or on slight exertion, or there may be persistent dyspnœa. Under these circumstances *tracheotomy*

(see p. 248) should be performed. The patient may be able to breathe for the greater part of the day with the tube plugged, but he usually prefers to breathe through the cannula at night. The inner tube should therefore be worn with a plug in it which can be easily removed at any time should dyspnoea occur.

When bilateral abductor paralysis arises from pressure upon the recurrent nerves it must be remembered that complete paralysis will probably supervene, and then, as the cords will be in the cadaveric position, the necessity for tracheotomy will be passed. Therefore, sometimes when complete paralysis seems supervening on abductor, tracheotomy may often be advantageously postponed in the absence of severe symptoms. In tabetic cases the tube is usually permanently required as adductor paralysis rarely follows. In the diphtheritic cases, tracheotomy is also commonly required, but the tube can be dispensed with when recovery ensues.

2. *In bilateral recurrent paralysis* other difficulties arise. As the patient cannot close the glottis he is unable to prevent food, especially liquids, entering the air passages during swallowing. In these cases the means of feeding already described must be adopted (see p. 449). If the paralysis be incomplete on one side, the patient should attempt to swallow while lying on that side, but in the most severe cases he must be fed with the stomach tube. In spite of this, saliva, etc., is sure to enter the air passages, and, as the cough is rendered ineffectual from imperfect closure of the glottis, septic bronchitis and pneumonia are sure to supervene.

#### SPASM OF THE TENSOR MUSCLES OF THE VOCAL CORDS.

This affection is met with amongst those who habitually overuse the voice, and is probably due to a faulty method of voice-production. It is a spasm of the tensors and occasionally of the other laryngeal muscles, and is probably of the nature of a trade-spasm.

**Symptoms.**—The voice first becomes a little muffled, then is often partially intercepted as if the patient were straining, and finally cannot be produced at all. After a short interval the voice again becomes clear but soon relapses.

**Treatment.**—The first essential is absolute rest to the voice. This may be combined with the administration of tonics and the local application of a mild galvanic current. Subsequently the patient should be taught elocution, and any fault in the method of production must be remedied. Under this treatment the patient will readily improve, but relapse is almost certain to take place if overuse of the voice be again permitted.

#### SPASM OF THE GLOTTIS IN INFANTS.

**LARYNGISMUS STRIDULUS.**—This affection occurs especially in the second and third years of life. The infants almost invariably suffer

from rickets, and it is probable that the unstable nervous system which is the result of this disease is the most important factor in the causation, but heredity seems to have some influence. The exciting cause is often a slight attack of laryngitis or some cause of reflex irritation such as dyspepsia, teething, etc.

**Symptoms.**—The attack usually comes on in the early morning hours. Suddenly a stridulous inspiration or two may occur or the child may wake up in terror and not a sound be heard. The face, at first flushed, becomes livid, the eyes are staring, the head is thrown back, there is often opisthotonos, and occasionally general convulsions. After a few seconds to a minute the attack subsides, inspiration being accompanied by a loud crowing stridor, and the child is left exhausted. Very rarely a sudden soundless and quickly fatal spasm may occur. The attacks may be repeated at intervals or occur every night or in a much less severe form on any slight excitement.

**Treatment.**—During the actual attacks the patient is usually best sitting up, and various household remedies such as slapping on the back, the application of a cold-water douch, or the inhalation of ammonia may be tried. If the attack persists or be repeated, the best treatment is to place the patient at once in a hot bath, the effect of which may be aided by splashing cold water on the face. Another well-known household remedy is the administration of emetics, such as *vinum ipecac.* (℞ iij.—v. on a lump of sugar), or vomiting may be produced by tickling the fauces. If at hand the inhalation of a few drops of chloroform may be tried. Only in very rare instances should tracheotomy be performed, but it may be necessary as a preliminary to artificial respiration if the spasm persists very long. If the attack has been severe, it is well to administer a dose of potassium bromide and chloral; two grains of each may be given per rectum.

In the intervals between the attacks, great care should be devoted to the treatment of the rickets. Digestive disturbances must be corrected by the administration of a purge followed by suitable remedies, and great care must be taken in the feeding of the patient, and especially the last meal before bed-time should be very light and taken at least an hour and a half before going to rest. In most cases change of air is advisable (see Treatment of Rickets, Part III, p. 208).

**REFLEX SPASM.**—Laryngeal spasm may also occur in older children as the result of reflex irritation. It is especially common in connection with mild attacks of laryngitis, especially the subglottic form to which the term *laryngitis stridulosa* is commonly applied in consequence. It also occurs in association with adenoid growths in the naso-pharynx. In these latter cases the spasm may occur constantly during sleep. As the patient goes to sleep, snoring commences, becomes louder and louder until finally a laryngeal note is distinctly to be detected and then no air enters the chest during inspiration. The patient wakes up frightened,

draws a long stridulous breath and falls to sleep again, when the cycle of events is repeated.

**Treatment.**—In all these cases the treatment consists in ascertaining and removing any cause, such as those above enumerated, which may be present.

#### LARYNGEAL VERTIGO.

This rare affection is probably due to a sudden spasm of the glottis. A tickling sensation in the larynx comes on: then a sudden, full inspiration occurs and is followed by complete glottic spasm. The vision becomes obscure the patient becomes dizzy, unconscious and falls down; in a few seconds he completely recovers. Similar symptoms may be produced by direct irritation of the larynx by small crusts as in laryngitis sicca. In these patients a violent cough sets in and continues until the patient becomes black in the face and unconscious.

**Treatment.**—This consists in the administration of the ordinary nervine tonics, such as liquor strych., and in the removal of the cause when any direct source of irritation can be discovered. The attacks are practically never fatal and the prognosis is usually good.

#### MALFORMATIONS OF THE LARYNX.—CONGENITAL LARYNGEAL OBSTRUCTION.

This affection, also known as Congenital Laryngeal Stridor, Infantile Respiratory Spasm, etc., is due to a congenital malformation of the superior laryngeal aperture; the epiglottis is curled upon itself until its posterior edges may be in contact and the ary-epiglottic folds are closely opposed. In infancy these parts are very flaccid and on inspiration this deformed superior laryngeal aperture closes like a valve giving rise to marked stridor and occasionally dyspnoea.

**Symptoms.**—The stridor commences at or immediately after birth, increases for a few months and gradually subsides at about the second year. The stridor accompanies nearly every inspiration and usually persists during sleep. There may be retraction of the chest walls and occasionally cyanosis but the patient rarely exhibits any sign of distress. The disease often seems to produce no effect upon the general health, but occasionally the children are ill-nourished, and should respiratory affections occur cyanosis and collapse of the lung bases is apt to take place adding an increased gravity to these troubles. In a few cases deformity of the chest may result or actual asphyxia may occur.

**Treatment.**—The affection subsides as the child grows, apparently because the parts becomes less flaccid and the arytenoids move freely and become further apart. The curling of the epiglottis persists throughout life. The treatment consists in supporting the general health and in taking

special care to avoid all risk of colds or respiratory troubles. Tracheotomy should only be performed when absolutely necessary to avoid asphyxia.

#### CONGENITAL WEB OF THE LARYNX.

This malformation usually takes the form of a web at or just below the free edges of the vocal cords. If small it exists only anteriorly and gives rise to aphonia; a larger web extends further back between the cords and then may cause dyspnœa.

**Treatment.**—Removal of the web may usually be accomplished by means of the laryngeal forceps as it is commonly very thin. Occasionally the application of the galvano-cautery may be cautiously tried. In rare cases it may be necessary to perform tracheotomy and subsequently thyrotomy and to excise the web. The after-treatment is similar to that for strictures of the larynx (see p. 444), but the results are usually satisfactory.

# INDEX.

## PART V

- ABSCESS, acute mastoid, 402  
  alveolar, 208  
  cerebellar, in otitis media, 57  
  extra-dural, 52  
    treatment of, 60, 65  
  in fracture of lower jaw, 195  
    treatment of, 200  
  laryngeal, 434  
  mastoid, acute, 402  
    chronic, 393  
    superficial, 402  
  of the brain, 56  
    treatment, 66  
  of nasal septum, 291  
  of parotid gland, 188  
  orbital, from nasal polypi, 321  
  sub-dural, 54  
  superficial mastoid, 402  
  tuberculous, of skull, 32
- Accessory cavities of the nose, cystic disease of, 358  
  inflammatory affections of, 335  
    acute inflammation and suppuration, 335  
    treatment, 336  
    of ethmoidal suppuration, 337  
    frontal sinus suppuration, 338  
    maxillary antrum suppuration, 337  
    sphenoidal sinus suppuration, 338  
  chronic suppuration, 338  
    treatment, 340  
    in frontal sinus, 350  
    ethmoidal cells, 346  
    maxillary antrum, 341  
    sphenoidal sinus, 349  
  mucocoele, 358
- Accessory sinuses of the nose, 269  
  ethmoidal cells, 272  
  frontal sinus, 271  
  maxillary antrum, 269  
  sphenoidal sinuses, 274
- Actinomycosis of the jaw, 211
- Acute aural catarrh, recurrent, 386  
  catarrhal laryngitis, 425  
  cellulitis of scalp, 9  
  inflammation of accessory nasal sinuses, 335  
  laryngitis, 425, 426, 430  
  mastoid abscess, 402  
  mastoiditis, 402  
  naso-pharyngitis, 359  
  œdematous laryngitis, 430  
  osteo-myelitis of the jaw, 209  
    of the skull, 30  
  otitis externa, 378  
    interna, 413  
    media, 382  
  perichondritis of the larynx, 433  
  periostitis of the skull, 30  
  post-nasal catarrh, 359  
  suppuration of accessory nasal sinuses, 335  
    of mastoid antrum, 402
- Adenoid growths, post-nasal, 360  
  in cleft palate, 170
- Adhesions between septum and inferior turbinate, 291  
  in chronic catarrh of middle ear, 389  
  intra-tympanic, 400
- Air-passages, foreign bodies in, 242  
  wound in, in cut throat, 239
- Air-tumours of the scalp, 11
- Ala of the nose, partial losses of, 157  
  broadening of, in hare-lip, treatment of, 166
- Alæ nasi, collapse of, 292
- Alveolar abscess, 208
- Alveolus, cleft of, in hare-lip, 162, 166  
  partial fracture of, 193
- Anæmia, labyrinthine. due to quinine, 412
- Anæsthesia, in cleft palate operations, 170  
  in laryngoscopy, 420  
  of the larynx, 451  
  nasal, 284  
    antipyrine, 285  
    cocaine and eucaine, 284  
    supra-renal extract, 285

- Anæsthesia  
in tumour of the brain, 90
- Anchylosis of the jaws, 204
- Aneurysms of scalp, 14
- Angiomata of the larynx, 435
- Anosmia, 333
- Anterior ethmoidal cells, position of, 272  
fossa of skull, fractures of, 28  
rhinoscopy, 278  
turbineotomy, 304
- Antipyrine as nasal anæsthetic, 285  
in trigeminal neuralgia, 125
- Antisepsis, nasal, 285
- Antial suppuration in chronic otitis, 393, 399
- Antrum drill, 341  
mastoid, acute suppuration in, 402  
chronic suppuration in, 409  
opening of, 59, 60  
maxillary, 269  
acute suppuration in, 337  
chronic suppuration in, 341  
mucocele of, 358
- Arbuthnot Lane's gag, 172
- Artificial drums, 399
- Arsenic in lupus of the larynx, 450  
in trigeminal neuralgia, 125  
in tuberculosis of the nose, 326
- Ashe's forceps, 289
- Asphyxia from cut throat, 236, 238
- Asthma, hay, 329  
nasal, 332
- Atheromatous cysts of scalp, 12
- Atrophic rhinitis, 311
- Attic curette, Lake's, 396  
disease of, in chronic otitis, 395  
removal of outer wall of, 407
- Auditory meatus, external, diseases of, 374  
nerve and centres, affections of, 415
- Auricle, deformities of, 182  
malignant disease of, 182
- Auriculo-temporal nerve, neurectomy of, 129
- BACILLI in fibrinous rhinitis, 298
- Bandage, in fractures of lower jaw, 198  
elastic in hæmatoma of scalp, 3
- Base of skull, fractures of, 26
- Bilateral abductor laryngeal paralysis, 454  
dislocation of lower jaw, treatment, 201  
recurrent laryngeal paralysis, 455
- Blake's snare for nasal polypi, 319
- Boilermakers' deafness, 415
- Boils on scalp, 10
- Bosworth's saw, 288
- Bouchard's theory of concussion, 40
- Bougies, Eustachian, 372
- Brain, abscess of, 56  
cicatrix of, treatment, 84  
compression of, 41  
complicating fracture, 27  
due to intra-cranial hæmorrhage, 42  
from vessels of pia mater, 49  
middle meningeal, 42  
other vessels, 50  
concussion of, 39  
contusion and laceration of, 41  
tumours of, 85
- Bronchus, foreign bodies in, 246
- Browne's nasal speculum, 279
- Brunton's auriscope, 368
- Bulla ethmoidalis, the, 266
- Bursa, thyro-hyoid, enlargement of, 233
- CALCULUS, salivary, 189
- Cancrum oris, destruction of cheek from, 146
- Carbuncles on the scalp, 10
- Carcinomata, of the face, 107  
of the nose, 328  
larynx, 258, 439  
skull, 38  
upper jaw, 214
- Caries of temporal, in chronic otitis, 392, 398
- Carmalt Jones's spokeshave, 307
- Carotid, division of, in wounds of parotid gland, 184
- Cartilages of larynx, fractures of, 234
- Catarrh, acute post-nasal, 359  
chronic of middle ear, 386  
chronic post-nasal, 359  
recurrent aural, acute, 386
- Catarrhal rhinitis, chronic, 300
- Catheter, Eustachian, the, 370  
dangers and difficulties in passing, 371  
in chronic catarrh of middle ear, 389
- Caustics, in chronic rhinitis, 301  
for aural polypi, 397  
perforated drum, 400
- Cauterisation for facial lupus, 101  
of nasal mucous membrane, 330
- Cautery for hypertrophy of inferior turbinate, 303
- Cavernous sinus, thrombosis of, 74
- Cellulitis, acute of scalp, 9  
in fractures of nasal bones, 110  
of neck complicating cut throat, 241  
complicating tracheotomy, 255  
complicating laryngectomy, 259
- Cephalhæmatoma, 1
- Cerebellar abscess in otitis media, 57
- Cerebral abscess, complicating middle-ear disease, 57, 410  
treatment of, 66  
complications of middle-ear disease, 410  
injury in fracture of lower jaw, 196  
in fractures of the nose, 113  
sinuses, hæmorrhage from, 50  
tumours, 85
- Cheek, plastic operations on, 145
- Chiene's method of localising fissure of Rolando, 89
- Cholesteatomata, 376, 392, 398
- Chondromata of the larynx, 435
- Chromic acid in laryngeal tuberculosis, 448
- Chronic catarrh of middle ear, 386  
catarrhal rhinitis, 300  
infective diseases of the nose, 323  
rhino-scleroma, 326  
syphilis, 323  
tuberculosis, 325  
tumours, 327  
osteitis of skull, 34  
otitis media, non-suppurative, 386  
otorrhœa, 391  
perichondritis of larynx, 434  
post-nasal catarrh, 359  
rhinitis, 338



- Chronic  
suppuration of accessory nasal sinuses, 338  
of middle ear, 386
- Cirroid aneurysm of scalp, 14
- Cleft palate, 161, 169  
complicating hare-lip, 162  
treatment, 169  
mechanical, 180  
operative, 170  
after-treatment, 177  
age for operation, 169  
anæsthesia, 170  
complications, 179  
treatment, 180  
Davies Colley's operation, 177  
flaps, formation of, 173  
suturing of, 174  
gags, 171  
Langenbeck's operation, 172  
lateral tension, relief of, 176  
paring edges, 172  
voice training after, 180  
preliminary measures, 170  
varieties, 169
- Cocaine in anterior rhinoscopy, 278  
in hay fever, 330  
nasal anæsthesia, 284  
tuberculous ulcers of lip, 116
- Cod-liver oil in tuberculosis of the nose, 326
- Colley's operation for cleft palate, 177
- Coloboma facialis, 169
- Compression of the brain, 41  
from intra-cranial hæmorrhage, 29
- Concussion of the brain, 39
- Condyle of the jaw, fracture of, 195, 199
- Contusion of the brain, 41
- Cooper Rose's nasal plug, 286, 304
- Coronoid process, fracture of, 195, 199
- Coryza, acute, 295
- Cranio-tabes, 35
- Croupous rhinitis, 298
- Curette, attic, Lake's, 396  
Gottstein's post-nasal, 362  
Meyer's original adenoid, 320
- Curettes, laryngeal, 447
- Curetting in laryngeal tuberculosis, 448
- Cut throat, 236  
treatment, 237  
of complications, 241  
when air-passages are involved, 238  
after-treatment, 240  
when air-passages are not involved, 237
- Cystic disease of accessory nasal cavities, 358
- Cysts, of the brain, 85  
dental, 212  
dermoid of face, 103  
of the epiglottis, 438  
of the larynx, 435  
of the lips, 118  
of the scalp, atheromatous, 11  
dermoid, 13  
sebaceous, of the face, 103  
thyro-glossal, 233
- DALBY'S aural speculum, 367
- Davies Colley's cleft palate operation, 177
- Deafness, boilermakers', 415  
in chronic otitis media, 387  
due to affections of auditory nerve, 415  
due to drugs, 412  
in Meniere's disease, 413  
in mumps and specific fevers, 414  
in sclerosis of middle ear, 390  
senile, 415  
after typhoid fever, 415
- Deflections of the nasal septum, 288
- Deformities, of the auricle, 182  
of the eyelids, 151  
of the nose, 153, 286, 287, 292  
syphilitic, 323  
traumatic, 113  
of the septum, 286
- Delstanche's malleus hook, 396  
nasal clamp, 289
- Dental cysts, 212  
nerve, inferior, neurectomy of, 128  
neuralgia in fracture of lower jaw, 196
- Dentigerous cysts, 212
- Depressed fracture of skull, 18
- Dermoid cysts, of the face, 103  
of the scalp, 13
- Diffuse exostosis, 380  
lepto-meningitis, 55
- Diphtheria, rhinitis in, 297  
tracheotomy for, 256
- Diploë, removal of, in osteo-myelitis of skull, 31
- Diplopia in focal epilepsy, 83
- Disinfection of scalp wounds, 7
- Dislocation of the jaw, 201
- Dobell's solution, 282, 360
- Drainage in tuberculous meningitis, 75, 76
- Drug deafness, 412
- Drums, artificial, 399
- Dura mater, opening, in cerebral tumour, 92  
removal of, in tuberculosis of skull, 33
- Durham's tracheotomy tube, 250
- EAR, diseases of, 367  
of auditory nerve, 415  
cerebral complications of otitis media, 403, 410  
chronic suppuration in mastoid antrum, 409  
of external auditory meatus, 374  
injuries of tympanum, 382  
of internal ear, 411  
of middle ear, 382  
neurasthenia, 416  
pyæmia, 403, 410  
superficial mastoid abscess, 402  
suppuration in antrum and mastoid cells, 402  
examination of, 367  
of the Eustachian tubes, 370  
Eustachian bougies, 372  
Eustachian catheter, 370  
Politzer's method, 370  
Valsalva's method, 370  
of the hearing power, 372  
of the tympanic membrane, 368
- Ear-hook, Lister's, 375  
internal, affections of, 411  
middle, affections of, 382

- Echinococccous cysts of the brain, 85  
 Ectropion, of eyelid, operations for, 151  
   of lips, operation for, 142  
 Eczema of external auditory meatus, 378  
 Electrolysis, in facial naevi, 103  
   in naevus of the lips, 118  
   in scalp naevi, 14  
   for superfluous hairs, 104  
 Emphysema, in fracture of nasal bones, 109,  
   112  
   in fractures of the upper jaw, 292  
   of scalp, 11  
   complicating tracheotomy, 256  
 Empyema following foreign body in bronchus,  
   246  
 Empyema, "latent," 339  
 Encephalocele, 77  
 Epiglottis, cysts of, 438  
 Epilepsy, focal, or Jacksonian, 83  
 Epiphora in fractures of nasal bones, 110,  
   112  
   in fractures of upper jaw, 192  
 Epistaxis, in carcinoma of the nose, 328  
   in fractures of nasal bones, 109, 112  
   resulting from rhinitis sicca, 311  
 Epithelioma, of the face, 107  
   of the jaw, 214, 223  
   of the larynx, 258  
   of the lips, 119  
   of the lower jaw, 223  
     removal of half jaw, 224  
     removal of horizontal ramus, 226  
     removal of symphysis, 227  
     removal of whole jaw, 227  
   of the nose, 328  
 Epulis, 213  
 Erysipelas, of the face, 102  
   of the scalp, 9  
 Esmarch's operation for closure of the jaws,  
   150  
 Ethmoid, osteitis and periostitis of, 316  
 Ethmoidal cells, chronic suppuration in, 346  
   inflammation of, 337  
   mucocele of, 358  
   position of, 272  
 Ethylate of sodium in facial naevi, 103  
 Eucaine for nasal anaesthesia, 284  
 Eustachian bougies, 372  
   catheter in chronic otitis media, 389  
   catheterisation, 370  
   obstruction in chronic otitis media, 388  
   tubes, examination of, 370  
 Excision of the lower jaw, 224  
   of the upper jaw, 217  
   of the parotid gland, 191  
 Exostosis of external auditory meatus, 379  
   of the skull, 37  
 External auditory meatus, diseases of, 374  
   acute diffuse inflammation, 378  
   circumscribed inflammation, 377  
   eczema, 378  
   foreign bodies in, 375  
   imperforate meatus, 374  
   obstruction to, 375  
   otomycosis, 379  
   stricture, traumatic, 374  
   tumours, 379  
 Extirpation of larynx, 440  
 Extra-dural abscess, in otitis media, 57, 60,  
   65, 410  
   suppuration, 52  
 Extrinsic cancer of the larynx, 439  
 Eyelids, plastic operations on, 151  
 FACE, affections of,  
   cleft palate, 169  
   erysipelas of, 102  
   fractures of the nasal bones, 109  
   general plastic operations on, 137  
   hare-lip and cleft palate, 161  
   inflammatory affections of, 102  
   moles, 104  
   of the lips, 114  
   perforation of the palate, 181  
   plastic surgery of, 137  
   syphilitic affections, 97  
   trigeminal neuralgia, 125  
   tuberculosis, 98  
   tumours of, 103  
   ulcers, 98  
   wounds of, 96  
 Facial lupus, 99  
   nerve, wounds of, 97, 184  
   paralysis, after mastoid operation, 407  
   in chronic otitis, 392, 398  
 Fibrinous rhinitis, 298  
 Fibro-angioma of the septum, 327  
 Fibromata of the larynx, 435  
   in naso-pharynx, 228  
   of the nose, 327  
 Fibro-sarcomata in naso-pharynx, 228  
 Fissured fractures of the skull, 18, 26  
 Fissure of Rolando, localisation of, 85  
   Chiene's method, 89  
   Reid's method, 88  
   of Sylvius, localisation of, 90  
 Fissures and cracks of the lips, 114  
 Fistula, salivary, 187  
   thyro-glossal, 232  
 Focal epilepsy, 83  
 Foreign bodies, in the air-passages, 242  
   in bronchus, 246  
     larynx, 243, 244  
     pharynx, 242  
     trachea, 243, 245  
   in external auditory meatus, 375  
   in the nose, 293  
 Fractures, of cartilages of larynx, 234  
   of hyoid bone, 233  
   jaws, 192  
   nasal bones, 109  
   skull, 16  
 Fraenkel's adjustable mirror, 280  
 Frontal sinus, 271  
   drainage of, 356  
   inflammation of, 338  
   mucocele of, 358  
   suppuration in, 350  
 Fronto-ethmoidal cells, suppuration in, 349  
 Fuller's bivalve cannula, 250  
 Furuncle of external auditory meatus, 377  
 GAGS for cleft palate operations, 171  
 Ganglion, Meckel's, ablation of, 127  
 Gangrene of the lips, 114  
 Gasserian ganglion, removal of, 131

- Gasserian ganglion, removal of  
 Hartley's method, 135  
 Horsley's method, 136  
 Rose's method, 131
- Gigli's saw, 38
- Gingivitis, 207
- Glands, removal of, in epithelioma of lip, 121
- Gliomata of the brain, 85
- Glottis, spasm of, in infants, 455  
 laryngismus stridulus, 455  
 reflex spasm, 456
- Gold-foil in brain operations, 84, 95
- Golding-Bird's tracheal dilator, 246
- Gonorrhœal rhinitis, 297
- Gottstein's post-nasal curette, 362
- Green-stick fractures of skull, 17
- Gruber's speculum, 367
- Grünwald's forceps, 317, 350
- "Gumboil," 208
- Gummata, of the brain, 85  
 of the face, 97  
 of the larynx, 442  
 of the nose, 98  
 of the skull, 34
- Gums, inflammation of, 207
- Gunning's splint, 197
- Gussenbauer's method for closure of the jaws, 148
- Gustatory nerve, neurectomy of, 129
- "Gutter fractures," treatment of, 25
- HÆMATOMA of the scalp, 1  
 sub-aponeurotic, 2  
 subcutaneous, 1  
 sub-pericranial, 5
- Hæmorrhage, arrest of, in cut throat, 239  
 in fractures of skull, 28  
 in inferior turbinectomy, 304  
 from cerebral sinuses, 50  
 in fractures of upper jaw, 193  
 intra-cranial, 42  
 from middle meningeal artery, 42  
 sub-dural, 48  
 labyrinthine, 412  
 nasal, 286  
 in staphylophary, 179  
 sub-dural, 48  
 in tracheotomy, 254, 255  
 on the vocal cord, 428, 429
- Hahn's cannula, preparation of, 260  
 in cut throat, 238
- Hammond's splint, 124  
 in fractures of lower jaw, 196  
 in fractures of upper jaw, 193
- Hare-lip, 161  
 treatment, 161  
 age for operating, 162  
 bilateral cleft of alveolus, 162  
 complete, 163  
 complicated with cleft palate, 162  
 double, 167  
 incomplete, 163  
 Mirault's operation, 164  
 Nélaton's operation, 166  
 unilateral with cleft of alveolus, 166
- Hartley's method for resecting Gasserian ganglion, 135
- "Hay asthma," 329, 332
- Hay fever, 329
- Head, surgical affections of the, 1  
 affections of the scalp, 1  
 encephalocele, 77  
 focal epilepsy, 83  
 hernia cerebri, 70  
 hydrocephalus, 79  
 intra-cranial injuries, 39  
 suppuration, 52  
 meningocele, 77  
 microcephalus, 78  
 sinus thrombosis, 74  
 tuberculous meningitis, 75  
 tumours of the brain, 85
- Hearing power, estimation of, 372
- Hernia cerebri, 70  
 primary, 70  
 secondary, 72
- Heryng's laryngeal cures, 447
- Hiatus semilunaris, 266
- High tracheotomy, 248
- Horsley's method for resecting Gasserian ganglion, 136  
 for hairy moles, 104  
 wax, 47
- Hydrocephalus, 79
- Hyoid bone, fractures of, 233
- Hyperæsthesia of the larynx, 451
- Hypertrophy of inferior turbinate, 302  
 of the lips, 114  
 congenital, 118
- Hysterical laryngeal paralysis, 453
- ICE-BAG in hæmatoma of the scalp, 2
- Ice-cap in concussion of the brain, 41  
 in hæmatoma of the scalp, 2
- Idiopathic rhinorrhœa, 331
- Illuminants for anterior rhinoscopy, 276  
 for examination of ear, 367
- Imperforate auditory meatus, 374
- Incus, removal of, 396
- Incus hook, in removal of ossicles, 397
- Indian method of rhinoplasty, 158
- Infective sinus thrombosis, 74
- Inferior dental nerve, neurectomy of, 128  
 meatus of the nose, 265  
 turbinate bone, 265  
 adhesion of septum to, 291  
 hypertrophy of, 302  
 removal of, 306, 307
- Inflation, Politzer's in acute otitis media, 384  
 Valsalva's in chronic otitis media, 387
- Infra-orbital neurectomy, 127
- Infundibulum, the, 272
- Inhalations, steam, 421, 431
- Injection in nævus of the lip, 117  
 of carbolic acid for lupus, 101
- Instillations in chronic otitis, 394
- Insufflations for the larynx, 421
- Internal ear, affections of, 411  
 acute inflammation, 413  
 boilermakers' deafness, 415  
 drug deafness, 412  
 hyperæmia of labyrinth, 411  
 Menière's disease, 412  
 senile deafness, 415  
 syphilis, 413  
 jugular vein, ligature of, 64

- Intra-cerebral suppuration, 56  
 Intra-cranial hæmorrhage, 42  
   injuries, after fissure of skull, 18, 19  
     compression of the brain, 41  
     concussion of the brain, 39  
     contusion of the brain, 41  
   suppuration, 52  
 Intra-nasal irrigation of frontal sinus, 351  
   malignant tumours, 221  
 Intra tympanic adhesions, 400  
 Intrinsic laryngeal cancer, 258, 439  
   tuberculosis of the larynx, 447  
 Intubation of the larynx, 422  
 Irrigation in cellulitis of the scalp, 9  
 Ivory exostoses of the skull, 37
- JACKSONIAN epilepsy, 83  
 Jaw, actinomycosis of the, 211  
   lower, epithelioma of, 223  
     fractures of, 195  
     removal of, in lip cancer, 122  
   upper, excision of, 217  
     fractures of, 192  
     osteoplastic resection of, 230  
 Jaws, actinomycosis of, 211  
   acute osteomyelitis, 209  
   alveolar abscess, 208  
   ankylosis, 204  
   closure of, 146  
   cysts of, 212  
   dislocations, 201  
   fractures of, 192  
     of lower jaw, 195  
       treatment, 196  
       of complications, 200  
       of fracture, 196  
     of upper jaw, 192  
       treatment, 193  
   gingivitis, 207  
   new growths of, 213  
   osteitis and periostitis, 208  
   phosphorus necrosis, 211  
   pyorrhœa alveolaris, 207  
   tuberculosis, 211  
   tumours, 212  
 Jugular internal, ligature of, 64  
 Juracz's post-nasal forceps, 363
- KÖNIG'S method of forming a new bridge to  
 the nose, 156  
 Krause's nasal and laryngeal forceps, 447  
   trochar, 343
- LABYRINTH, hyperæmia of, 411  
 Labyrinthine hæmorrhage, 412  
 Laceration of the brain, 41  
 Lachrymal duct, the, 266  
 Lack's snare, 303  
   tongue depressor, 280  
 Lactic acid, in laryngeal tuberculosis, 448  
   in tuberculous ulcers of lip, 116  
 Lake's attic curette, 396  
 Langenbeck's method of forming bridge to  
 nose, 156  
   operation for cleft palate, 172  
     for naso-pharyngeal polypi, 230  
 Laryngeal abscess, 434  
   cartilages, necrosis of, 434
- Laryngeal  
   mirror, 417  
   paralysis, organic, 454  
   phthisis, 445  
   spasm, functional, 453  
   stenosis, dilator for, 444  
   stridor, congenital, 457  
   vertigo, 457  
 Laryngectomy, complete, 262  
   unilateral, 261  
 Laryngismus stridulus, 455  
 Laryngitis, acute catarrhal, 425  
   acute œdematous, 430  
   chronic, 427  
   sicca, 429  
   spasmodic, 426  
 Laryngoscopy, 417  
 Laryngotomy, 234, 252, 257  
 Larynx, acute perichondritis of, 433  
   anaesthesia of, 451  
   anæsthetisation of, 420  
   cancer of, 258  
   chronic perichondritis of, 434  
   cleansing of, 420  
   congenital obstruction of, 457  
     web of, 458  
   examination of, 417  
   extirpation of, 440  
   foreign bodies in, 243, 244  
   fractures of cartilages of, 234  
   functional paralysis of, 452  
   spasm of, 453  
   hyperæsthesia of, 451  
   inflammatory affections, 424  
   injuries of, 233  
     cut throat, 236  
     fractures, of cartilages, 234  
       of hyoid bone, 233  
   insufflations for, 421  
   intubation of, 422  
   laryngeal abscess, 434  
     phthisis, 445  
   laryngitis, acute catarrhal, 425  
     acute œdematous, 430  
     chronic, 427  
     sicca, 429  
   lupus of, 449  
 Larynx, malformations of the, 457  
   congenital obstruction, 457  
     web, 458  
   necrosis of cartilages of, 433  
   neuralgia of, 451  
   neuroses of, 451  
   œdema of, 432  
   pachydermia of, 428, 429  
   paralysis, organic, of, 454  
   perichondritis, 433  
   steam inhalations for, 421  
   syphilis of, 442  
   tuberculosis of, 445  
   tumours of, 435  
 Larynx and trachea, affections of, 232  
   operations on, 248  
     laryngectomy, complete, 262  
       unilateral, 261  
     laryngotomy, 257  
     thyrotomy, 260  
 Lateral sinus, exposure of, 63

- Lateral sinus  
wounds of, in mastoid operation, 407
- Leeches, in acute mastoiditis, 403  
in acute otitis externa, 378  
in acute otitis media, 384
- Leontiasis ossium, 36
- Leiter's coil in fractures of the skull, 28  
in concussion, 41
- Lepto-meningitis, 55, 410
- Lichtwitz's trochar and cannula, 342
- Light-baths, for facial lupus, 102  
for facial rodent ulcer, 108
- Lip, lower, restoration of, 140  
upper, restoration of, 143
- Lipoma of the larynx, 435, 439
- Lips :  
cracks and fissures of, 114  
cysts of, 118  
ectropion of, operation for, 142  
epithelioma of, 119  
gangrene of, 114  
hypertrophy of, 114  
inflammatory affections, 114  
lupus of, 115  
lymphangioma of, 118  
mucous patches of, 117  
nævus of, 117  
plastic operations on, 140  
primary sores of, 116  
syphilitic affections of, 116  
tuberculous affections of, 115  
tumours of, 117  
cysts, 118  
epithelioma, 119  
lymphangioma, 118  
nævus, 117  
ulcers, tuberculous, of, 115  
wounds of, 114
- Lister's dressing for hare-lip, 165  
ear-hook, 375
- Longitudinal sinus, hæmorrhage from, 50
- Loop method of passing sutures in staphy-  
loraphy, 174
- Lower jaw, dislocation of, 201  
fractures of, 195
- Lupus, facial, 99  
laryngeal, 449  
of the lips, 115  
of the nose, 325  
of the scalp, 10
- Lymphangioma of the lips, 118
- MACDONALD'S lamp for laryngoscopy, 277
- MacKenzie's lamp for laryngoscopy, 277  
laryngeal cutting forceps, 436, 437  
snare, 319
- Macro-cheilia, 118
- Malar bone, fracture of, 194
- Malformations, congenital, of the nose, 292
- Malleus, removal of, 396
- Mandl's solution, 310, 360
- Mason's gag, 171  
method for fracture of the nose, 112
- Massage of drum in chronic otitis media,  
389  
of the mucous membrane in ozæna, 314
- Mastoid abscess, superficial, 402  
antrum, acute suppuration in, 402
- Mastoid  
antrum  
chronic suppuration in, 409  
opening of, 59, 60  
cells, suppuration in, 393
- Mastoiditis, acute, 402  
complicating acute otitis media, 386
- Mastoid suppuration, acute, 402  
operation, 404
- Maxilla, superior, fractures of, 192
- Maxillary antrum, 269  
acute suppuration in, 337  
chronic suppuration in, 341
- Meati of the nose, 265
- Meatus, external auditory, diseases of, 374  
imperforate, 374
- Mechanical treatment of cleft palate, 180
- Meckel's ganglion, excision of, 127
- Medical erysipelas, 102
- Membrana tympani, injuries of, 382  
perforation of, 391
- Membrane, mucous, of accessory cavities,  
275  
of the nose, 269
- Menière's disease, 412
- Meningitis, in acute otitis media, 386  
involving auditory nerve, 415  
tuberculous, 75
- Meningeal artery, rupture of, 42
- Meningocele and encephalocele, 77
- Meyer's original adenoid curette, 320
- Methylene blue, in trigeminal neuralgia,  
126
- Microcephalus, 78
- Microstoma, plastic operations for, 144
- Middle ear, affections of, 382  
acute otitis media, 382  
acute suppuration in mastoid antrum, 402  
catarrh, chronic non-suppurative, 386  
recurrent acute, 386  
cerebral complications in disease of, 410  
chronic non-suppurative catarrh, 387  
chronic suppuration of, 391  
in mastoid antrum, 409  
pyæmia, 410  
sclerosis, 390  
superficial mastoid abscess, 402  
tympanum, injuries of, 382
- Middle ethmoidal cells, position of, 272  
fossa of skull, fracture of, 28  
meatus of nose, 266  
meningeal artery, rupture of, 42
- Mirault's operation for hare-lip, 164
- Mirror, Fraenkel's adjustable, 280
- Moles on the face, 104
- Morrant Baker's india-rubber tube, 252
- Morton's fluid in hydrocephalus, 80
- Mucocele of accessory nasal cavities, 358
- Mucous membrane, of accessory sinuses, 275  
of the nose, 269
- Mucous patches on lips, 117
- Multilocular cysts of the jaw, 212
- Mumps, 189
- Mutism, functional, 452
- Myxoma of the larynx, 435
- NÆVI, of the face, 103  
of the lips, 117

- Nævi  
of the scalp, 13
- Nasal anaesthesia, 284  
anti-epistaxis, 285
- Nasal asthma, 332  
bones, fractures of, 109  
treatment, 110  
of complications, 112  
of long-standing deformity, 113  
fossæ, 205  
inflammatory affections of, 295  
acute, 295  
croupous rhinitis, 298  
fibrinous rhinitis, 208  
gonorrhœal rhinitis, 297  
rhinitis in specific fevers, 297  
simple acute rhinitis, 295  
traumatic rhinitis, 297  
chronic, 300  
atrophic rhinitis, 311  
catarrhal rhinitis, 300  
hypertrophy of inferior turbinate, 302  
nasal polypus, 315  
osteitis and periostitis of ethmoid, 316  
rhinitis sicca, 308
- irrigators, 283  
mucous membrane, cauterisation of, 330  
neuroses, 329  
anosmia, 333  
hay fever, 329  
nasal asthma, 332  
parosmia, 334  
paroxysmal sneezing, 331  
rhinorrhœa, 331  
polypus, 315  
therapeutics, 282
- Naso-pharyngeal polypi, 228  
Naso-pharyngitis, acute, 359  
Naso-pharynx, diseases of:  
acute naso-pharyngitis, 359  
chronic post-nasal catarrh, 359  
tumours of the, 228
- Neck, cellulitis of, in cut throat, 241  
Necrosis, in chronic otitis, 392, 398  
of laryngeal cartilages, 434  
phosphorus, 211  
syphilitic, of skull, 34
- Nélaton's operation for hare-lip, 166  
for naso-pharyngeal polypi, 229
- Nerve, auditory, affections of, 415  
fifth, neuralgia of, 125
- Nerve, inferior maxillary, division of, at foramen ovale, 130
- Neurasthenia, 416  
in chronic otitis media, 387
- Neuralgia,  
of the larynx, 451  
trigeminal, 125
- Neurectomy in trigeminal neuralgia:  
of auriculo-temporal nerve, 129  
of gustatory nerve, 129  
infra-orbital, 127  
of inferior dental nerve, 128  
maxillary trunk, 130  
supra-orbital, 126
- Neurectomy  
of trunk of superior maxillary and Meckel's ganglion, 127
- Neuritis peripheral laryngeal, 454
- Neuroses, nasal, 329  
of the larynx, 451  
alterations of sensation, 451  
functional laryngeal spasm, 453  
paralysis, 452  
laryngeal vertigo, 457  
organic laryngeal paralysis, 454  
spasm of the glottis in infants, 455  
spasm of the tensor muscles of the cords, 455
- Nitric acid in rodent ulcer, 107
- Nose, accessory sinuses of, 269  
anatomy of, 265  
arrest of bleeding from, 286  
chronic infective diseases of, 323  
cleansing the, 282  
deformities of, 153, 287  
depression of bridge, 110  
destruction of tip of, 156  
examination of, 276  
foreign bodies in, 293  
rhinoliths, 294  
fracture of, 111  
gummata of, 98  
inflammations of accessory cavities, 335  
lateral displacement of, 110  
loss of entire organ, 153  
loss of cartilaginous portion of, 153  
lotions for, 282  
lupus of, 325  
malformations, congenital, 292  
meati of the, 265  
nasal fossæ, the, 265  
septum, displacement of, 110  
sprays for, 283  
syphilis of, 98, 323  
syringing the, 283  
tuberculosis of, 325  
tumours of, 327  
vestibule, the, 265
- Nose and accessory cavities, examination of, 276  
rhinoscopy, anterior, 278  
posterior, 279  
trans-illumination, 282
- OBTURATORS, in cleft palate, 181
- O'Dwyer's intubation tubes, 422
- Oedema of the larynx, 432
- Oedematous laryngitis, acute, 430
- Oily solutions for the nose, 284
- Ollier's operation for naso-pharyngeal polypi, 229
- Orthoform, in laryngeal cancer, 440  
in tuberculous ulcers of the lip, 116
- Ossicles, caries of, in chronic otitis, 392, 398  
removal of, 396
- Osteitis, chronic, of the skull, 34  
of the jaws, 208
- Osteitis and periostitis of the ethmoid, 316
- Osteo-myelitis, acute, of jaws, 208  
of the skull, 30

- Osteo-plastic flaps in cerebral operations, 94  
 resection of the upper jaw, 230
- Otitis, acute, complicated by mastoiditis, 403  
 externa, acute, 378  
 media, acute, 383  
   chronic non-suppurative, 386  
 tuberculous, 391
- Otomycosis, 379
- Otorrhœa, chronic, 391
- Ozæna, 311
- PACHYDERMIA of the larynx, 428, 430
- Pachymeningitis, hæmorrhagica, 83  
 in otitis media, 57  
 interna, 83  
 tuberculous, 32
- Palate, acquired perforation of, 181  
 cleft (*see* Cleft Palate), 169
- Panza's scissors, 304
- Papilloma, of the larynx, 435  
 of the nose, 327
- Paracentesis in acute otitis media, 385
- Paralysis, facial, in chronic otitis, 392, 398  
 functional of larynx, 452  
 organic laryngeal, 454
- Parker's tracheal dilator, 254  
 tracheal aspirator, 255  
 tracheotomy tube, 250
- Parosmia, 334
- Parotid gland, suppuration in, 188  
 excision of, 191  
 inflammation of, 188  
 new growths of, 189  
   malignant disease, 190  
   "parotid tumour," 189  
 wounds of, 184
- Parotitis causing deafness, 414  
 "Parotid tumour," treatment of, 189
- Paroxysmal sneezing, 331
- "Parting tool" for skull operations, 47
- Perichondritis, in laryngeal tuberculosis, 448  
 of larynx, acute, 433  
   chronic, 434
- Periostitis, of the jaws, 208  
 of the skull, 30
- Persistent thyro-glossal tract, 232
- Pharynx, foreign bodies in the, 242
- Phosphorus necrosis, 211
- Phthisis, laryngeal, 445
- Pia mater, hæmorrhage from vessels of, 49
- Plastic operations, on the cheek, 145  
 for ectropion of eyelids, 151  
 in epithelioma of the lip, 122  
 on the face in general, 137  
 on the lips, 122, 140  
   for ectropion, 142  
   for microstoma, 144  
   for restoration of the lower lip, 140  
   of the upper lip, 143
- Pneumatocele of scalp, 11
- Pneumonia septic, in cut throat, 241
- Polypus, aural, 392, 397  
 nasal, 315  
 naso-pharyngeal, 228
- Politzer's aural snare, 398  
 method of examining Eustachian tubes, 370  
 method of testing hearing power, 372
- Politzerisation in acute otitis media, 384
- "Port wine stains," 103
- Post-nasal adenoid growths, 360  
 catarrh, acute and chronic, 359
- "Pott's Puffy Tumour," 30, 52
- Pre-maxilla, projection of, in hare-lip, 162  
 re-position of, 167
- Prolabium, treatment of, in hare-lip, 167
- Punctured fracture of the skull, 19
- Pyæmia complicating otitis media, 410
- Pyorrhœa alveolaris, 207
- QUININE, deafness, 412  
 in trigeminal neuralgia, 125
- RAMUS of lower jaw, fracture of, 195
- Reid's cerebral localisation, 88
- Respiratory spasm, infantile, 457
- Rhinitis, atrophic, 311  
 chronic, 338  
   catarrhal, 300  
 fibrinous or croupous, 298  
 gonorrhœal, 297  
 sicca, 308  
 simple acute, 295  
 in specific fevers, 297  
 traumatic, 297
- Rhinoliths, 294
- Rhinoplastic operations, 154-160
- Rhinorrhœa, 331
- Rhino-scleroma, 326
- Rhinotomy, anterior, 278  
 posterior, 279
- Rinne's test, 373, 400
- Rodent ulcer of the face, 107  
 of the nose, 328
- "Rolandometer," Horsley's, 89
- Rose's gag, 171  
 removal of Gasserian ganglion, 131
- Rouge's operation, for antral suppuration, 346  
 for nasal tumours, 222  
 for naso-pharyngeal polypi, 229
- SALIVARY calculus, 189  
 ducts, wounds of, 185  
 fistula, 186
- Salicylic plasters (Unna's), 102
- Salycin deafness, 412
- Sarcomata, of the brain, 85  
 of the nose, 328  
 of the skull, 38  
 of the upper jaw, 214
- Saucer-like depressions in skull, 17
- Scalp, acute cellulitis of, 9  
 air tumours of, 11

- Scalp  
aneurysms of, 14  
atheromatous cysts of, 11  
boils and carbuncles of, 10  
cirroid aneurysm of, 14  
dermoid cysts of, 13  
emphysema of, 11  
erysipelas of, 9  
hæmatomata of, 1  
injuries of, 1  
lupus of, 10  
navi of, 13  
tumours of, 11  
ulcers of, 10  
wounds of, 6  
Sclerosis of middle ear, 390  
Sebaceous cysts, of the face, 103  
of the scalp, 11  
Senile deafness, 415  
Septum, nasal, abscess of, 291  
adhesion to inferior turbinate, 291  
boundaries of, 267  
deflections of, 288  
deformities of, 287  
displacement of, 110  
fibro-angioma of, 327  
perforation of, in lupus, 325  
spurs and ridges on, 289  
Sequestrotomy in syphilis of skull, 34  
Siegel's speculum, 370, 387, 389  
Singers' nodes, 428, 429  
Sinus, cavernous, thrombosis of, 74  
frontal, 271  
inflammation in, treatment of, 338  
suppuration in, 350  
lateral, exposure of, 63  
sphenoidal, opening of, 350  
situation of, 274  
treatment of inflammation in, 338  
thrombosis, 74  
infective form, 74  
marasmic form, 74  
transverse, thrombosis, 74  
Sinuses, accessory, of nose, 269  
acute inflammation, 335  
chronic suppuration, 338  
adventitious, in chronic otitis, 393  
cerebral, hæmorrhage from, 50  
Skin-grafting, on the face, 137  
in ulcers of the scalp, 10  
Skull, affections of:  
acute osteo-myelitis and periostitis, 30  
cranio-tabes, 35  
fractures of, 16  
of the base, 16, 26  
complications, 27  
treatment, 28  
of the vault, 16  
of external table alone, 16  
of internal table alone, 17  
of whole thickness, of skull, 18  
depressed fracture, 18  
fissured fracture, 18  
punctured fracture, 19  
leontiasis ossium, 36  
Skull  
osteomyelitis and periostitis, 30  
syphilis of, 34  
tuberculosis of, 32  
tumours of, 37  
Smith's forceps, 289  
gag, 171  
Snare, Blake's, 319  
Krause's, 318, 447  
Lack's, 308  
Sneezing, paroxysmal, 331  
Spasm, of glottis in infants, 455  
infantile respiratory, 457  
of larynx, functional, 453  
of tensors of vocal cords, 455  
Spasmodic laryngitis, 426  
tic, 125  
Specula, aural, 367  
nasal, 278  
Sphenoidal sinuses, inflammation in, 338  
situation of, 274  
suppuration in, 349  
Spokeshave, nasal, 307  
Sprays, nasal, 283  
Spurs on septum, removal of, 289  
Stenosis, laryngeal, dilator for, 444  
Stenson's duct, wounds of, 97, 185  
Stricture, traumatic, of external auditory meatus, 374  
Stridor, congenital laryngeal, 457  
Sub-aponeurotic hæmatoma of scalp, 2  
Subcutaneous hæmatoma of scalp, 1  
Sub-dural abscess in otitis media, 57  
hæmorrhage, 48  
suppuration, 54  
Sub-pericranial hæmatoma of scalp, 5  
Superior maxilla, fractures of, 192  
maxillary nerve, neurectomy of, 127  
meatus, position of, 267  
Suppurating scalp wounds, 6  
Suppuration, acute, of mastoid, 402  
in antrum in chronic otitis, 393  
extra-dural, 52  
intra-cranial, 52  
sub-dural, 54  
Supra-orbital neurectomy, 126.  
Suprarenal extract for nasal anæsthesia, 285  
Syme's plastic operation on nose, 156  
Symphysis of jaw, fracture through, 195  
removal of, in cancer of lip, 123  
Syphilides, nodular, of nose, 98  
Syphilis, of accessory nasal sinuses, 339  
of the brain, 85  
face, 97  
internal ear, 413  
larynx, 442  
lips, 116  
nose, 98, 323  
skull, 34  
Syringing, in chronic otitis, 393  
of the nose, 283  
TAGLIACOTIAN method of forming new nose, 160  
Temporal bone, caries of, in chronic otitis, 392, 398



- Temporo-maxillary joint, dislocations of, 201  
 inflammatory affections of, 204
- Temporo-sphenoidal abscess, 57
- Tensors of vocal cords, spasm of, 455
- Thiersch's skin-grafting, for defects of face, 137  
 for facial lupus, 100  
 for facial moles, 104  
 in imperforate meatus, 374  
 in mastoid abscess, 409
- Thrombosis, septic in otitis media, 57, 410  
 sinus, 74
- Thudichum's nasal speculum, 278
- Thyro-glossal cyst, 233  
 fistula, 232
- Thyro-hyoid bursa, enlargement of, 233
- Thyroid extract, in lupus, 326
- Thyrotomy, for cancer of the larynx, 258, 440  
 in chronic perichondritis of larynx, 434  
 for foreign bodies in larynx, 244  
 in papilloma of the larynx, 438
- Tinnitus, in chronic catarrh of middle ear, 387  
 in hyperæmia of labyrinth, 412  
 in Menière's disease, 412  
 in sclerosis of middle ear, 390
- Trachea, foreign bodies in, 243, 245
- Trachea and larynx, operations on, 248
- Tracheal dilator, Golding Bird's, 246  
 Parker's, 254
- Tracheotomy, compared with intubation, 424  
 complications in, 255  
 in cut throat, 238  
 difficulties in, 253  
 for diphtheria, 256  
 for foreign bodies in air-passages, 244, 246  
 in fractured laryngeal cartilages, 235  
 high operation, 248  
 in intrinsic laryngeal cancer, 440  
 in laryngeal phthisis, 449  
 in acute laryngitis, 432  
 low operation, 253  
 in papilloma of larynx, 438  
 in perichondritis of larynx, acute, 433  
 chronic, 434  
 preliminary to thyrotomy, 259  
 tubes, 249
- Trachoma of the vocal cords, 428
- Trans-illumination of the antrum, 282
- Transverse sinus, thrombosis of, 74
- Trendelenburg's tube in cut throat, 238  
 in laryngectomy, 259
- Trephining, for depressed fractures, 20  
 in diffuse lepto-meningitis, 55  
 in fractures of base of skull, 29  
 in osteo-myelitis of skull, 30, 31  
 in punctured fractures, 25
- Trigeminal neuralgia, 125
- Tuberculosis of accessory nasal sinuses, 339  
 of the larynx, 445  
 of the nose, 325  
 of the skull, 32
- Tuberculous affections :  
 of the face, 98
- Tuberculous affections :  
 of the jaws, 211  
 of the larynx, 445  
 of the lips, 115  
 of the nose, 325  
 of the skull, 32
- meningitis, 75  
 otitis, 391  
 tumours of the brain, 85  
 of the larynx, 445  
 ulcers of the lips, 115  
 of the scalp, 10  
 of the face, 98
- Tubes, Eustachian, examination of, 370  
 tracheotomy, 249
- Tumours of the brain, 85  
 of the external auditory meatus, 379  
 face, 103  
 jaws, 212  
 larynx, 435  
 lips, 117  
 naso-pharynx, 228  
 nose, 327  
 parotid gland, 189  
 scalp, 11  
 skull, 37
- Tuning forks, 373
- Turbinate, inferior, of nose, 265  
 cauterisation of, 330  
 hypertrophy of, 302  
 removal of, 307  
 of posterior end only, 306
- Turbineotomy, anterior, 304  
 in deflected septum, 290
- Tympanic membrane, examination of, 368  
 method of determining mobility, 369  
 position of, 368
- Tympanum, changes in, in chronic otitis media, 387  
 injuries of, 382  
 perforation of, in chronic otitis, 395
- ULCER, perforating of septum, 311  
 rodent of face, 107  
 of scalp, 10  
 tuberculous, of lips, 115  
 of skin of face, 98
- Ulceration, superficial, of vocal cords, 445  
 syphilitic, of larynx, 442
- Unilateral dislocation of lower jaw, 202  
 hare-lip, with cleft of alveolus, 166 } 367  
 ozæna, 314
- Unna's plasters for lupus, 102
- Unreduced dislocation of jaw, treatment of, 202
- Ununited fracture of lower jaw, 196
- Upper jaw, fractures of, 192
- VALSALVA'S method of examining Eustachian tubes, 370
- Vault of skull, fractures of, 16
- Vertigo, laryngeal, 457
- Vestibule of the nose, 265
- Vocal cords, hæmorrhage on, 428, 429  
 spasm of tensors of, 455  
 superficial ulceration of, 445  
 trachoma of, 428

- WARD-COUSINS' ear drums, 400  
Wax in external auditory meatus, 376  
Web, congenital, of larynx, 458  
Weber's test of hearing power, 373  
Weir-Mitchell treatment in neurasthenia, 416  
    in paralysis of larynx, 452  
Whitfield on treatment of facial moles, 104  
Wilde's aural snare, 398  
Wiring fractures of lower jaw, 109  
Wounds, of the face, 96
- Wounds  
    of the lips, 114  
    of parotid gland, 184  
    punctured, of skull, 19  
    of salivary ducts, 185  
    of scalp, 6  
    of skull, punctured, 19  
    of Stenson's duct, 185
- ZYGOMATIC arch, fracture of, 104















## ORIENTAÇÕES PARA O USO

Esta é uma cópia digital de um documento (ou parte dele) que pertence a um dos acervos que fazem parte da Biblioteca Digital de Obras Raras e Especiais da USP. Trata-se de uma referência a um documento original. Neste sentido, procuramos manter a integridade e a autenticidade da fonte, não realizando alterações no ambiente digital – com exceção de ajustes de cor, contraste e definição.

**1. Você apenas deve utilizar esta obra para fins não comerciais.** Os livros, textos e imagens que publicamos na Biblioteca Digital de Obras Raras e Especiais da USP são de domínio público, no entanto, é proibido o uso comercial das nossas imagens.

**2. Atribuição.** Quando utilizar este documento em outro contexto, você deve dar crédito ao autor (ou autores), à Biblioteca Digital de Obras Raras e Especiais da USP e ao acervo original, da forma como aparece na ficha catalográfica (metadados) do repositório digital. Pedimos que você não republique este conteúdo na rede mundial de computadores (internet) sem a nossa expressa autorização.

**3. Direitos do autor.** No Brasil, os direitos do autor são regulados pela Lei n.º 9.610, de 19 de Fevereiro de 1998. Os direitos do autor estão também respaldados na Convenção de Berna, de 1971. Sabemos das dificuldades existentes para a verificação se uma obra realmente encontra-se em domínio público. Neste sentido, se você acreditar que algum documento publicado na Biblioteca Digital de Obras Raras e Especiais da USP esteja violando direitos autorais de tradução, versão, exibição, reprodução ou quaisquer outros, solicitamos que nos informe imediatamente ([dtsibi@usp.br](mailto:dtsibi@usp.br)).